Research Square

Preprints are preliminary reports that have not undergone peer review.
They should not be considered conclusive, used to inform clinical practice,
or referenced by the media as validated information.

Small Bowel Evisceration Through Vaginal Cuff Dehiscence Following Blunt Trauma in a Post-Hysterectomy Patient: A Case Report

Xin Chen
The Second People's Hospital of Neijiang
Ruyi Yu
gi_surgeon9527@163.com

The Second People's Hospital of Neijiang

Case Report

Keywords:

Posted Date: November 25th, 2026

DOI: https://doi.org/10.21203/rs.3.rs-11622255/v1

License: This work is licensed under a Creative Commons Attribution 4.0 International License.
Read Full License

Additional Declarations: No competing interests reported.

Small Bowel Evisceration Through Vaginal Cuff Dehiscence Following Blunt Trauma in a Post-Hysterectomy Patient: A Case Report

Xin Chen[1] and Ruyi Yu[2*]

Abstract

Purpose To describe the etiology and emergency management of delayed vaginal cuff dehiscence with small bowel evisceration after total hysterectomy. Methods A 61-year-old woman presented with acute small bowel evisceration from the vaginal orifice six years after surgery for endometrial cancer. The evisceration occurred after a fall from 2 meters followed by straining during defecation. Clinical features, imaging, and surgical treatment are reported. Results Computed tomography (CT) showed discontinuity of pelvic floor muscles with herniation of small bowel into the perineum. Emergency laparoscopy converted to laparotomy, adhesiolysis, reduction of herniated bowel, and two-layer vaginal cuff repair were performed. A 3 cm cuff fistula with 50 cm of herniated small bowel was found. The bowel was edematous but viable. The patient recovered without infection or recurrence. Conclusion Delayed vaginal cuff dehiscence can occur years after hysterectomy. Blunt trauma combined with sudden increase in intra-abdominal pressure is a rare trigger. Multidisciplinary emergency care and secure cuff closure are essential for a favorable outcome.

Keywords Vaginal cuff dehiscence; Small bowel evisceration; Hysterectomy; Blunt trauma; Case report

*Correspondence: Ruyi Yu

gi_surgeon9527@163.com

1 Emergency Department, The Second People's Hospital of Neijiang, Neijiang, Sichuan, China

2 Department of Anorectal, Gastrointestinal and Burn Surgery, The Second People's Hospital of Neijiang, Neijiang, Sichuan, China

Introduction

Vaginal cuff dehiscence with small bowel evisceration is a rare delayed complication after total hysterectomy. The reported incidence ranges from 0.09% to 0.28%[1]. This condition can progress rapidly to bowel ischemia, necrosis, sepsis, and death. Reported mortality reaches 8%, and 15% to 20% of patients require bowel resection[2]. Most cases occur within the early postoperative period. Median time to onset is about 3 months after laparoscopic hysterectomy and 6.5 months after abdominal hysterectomy. Common triggers include sexual intercourse, defecation, and chronic coughing, all of which raise intra-abdominal pressure[3-5]. Blunt trauma as a cause of delayed cuff dehiscence and evisceration is extremely rare. We report a 61-year-old woman who developed sudden small bowel evisceration through a vaginal cuff fistula six years after hysterectomy for endometrial cancer. The dehiscence was triggered by a fall from 2 meters followed by straining during defecation. This case documents

an unusual mechanism and its emergency management.

Case Presentation

A 61-year-old woman presented to the emergency department on September 26, 2026. She reported falling from a height one day earlier and noticed small bowel protruding from the vaginal orifice for more than one hour. Six years before, she had total hysterectomy for endometrial cancer at another hospital. The exact surgical approach and pathologic stage were not available. She received no adjuvant therapy and had regular follow-up with no evidence of recurrence. One day before admission, she fell from a ladder about 2 meters high. She landed on the perineum with moderate pain but no vaginal bleeding, hematuria, or loss of consciousness. She did not seek care. More than one hour before admission, while defecating, a loop of small bowel suddenly protruded from the vaginal orifice and became stuck. She had pelvic pain, abdominal pulling pain, nausea, and vomiting. No abdominal distension, fever, or rectal bleeding was reported.

Past medical history was unremarkable. She denied hypertension, diabetes, coronary artery disease, smoking, and alcohol use. Menarche at age 13 with cycle of 4/30 days. Menopause at age 50. One daughter. No family history of malignancy.

Physical examination: Vital signs: T 36.9°C, P 57/min, R 15/min, BP 161/82 mmHg. The abdomen was slightly distended with an old midline suprapubic scar. Mild tenderness was present throughout the abdomen, worst in the lower midline. No rebound tenderness or guarding. Bowel sounds were 5 to 6 per minute. Digital rectal examination showed intact sphincter tone. No mass was felt 7 cm into the rectum. The examining finger had no blood on withdrawal. Pelvic examination（Fig. 1）: a speculum could not be inserted. A segment of small bowel about 30 cm long protruded from the vaginal introitus. The bowel was dark red and mildly swollen. Peristalsis was visible. No active bleeding or abnormal discharge was seen.

Laboratory tests: White blood cell (WBC) count was 11.91 × 10^9/L with 67.8% neutrophils. Random glucose was 15.54 mmol/L. Coagulation profile, liver and renal function were normal. Interleukin-6 (IL-6) was 4.32 pg/mL. CT (Fig. 2)showed discontinuity of pelvic floor muscles. Small bowel loops and mesentery herniated into the perineum. The uterus was absent. Additional findings included mild inflammatory changes in both lower lung lobes, calcification, a liver cyst of 1.0 cm, and a thyroid nodule of 0.7 cm. No free fluid or bowel obstruction was seen.

Surgical Management

On admission, the prolapsed bowel was covered with warm saline-moistened gauze. In the operating room, after general anesthesia and lithotomy position, the gauze was removed. The exposed bowel was irrigated with diluted povidone-iodine. A pneumoperitoneum was created via an umbilical port for laparoscopy. A segment of small bowel was stuck to the previous incision and pelvic sidewall. A 3 cm hole was found at the vaginal cuff. About 50 cm of small bowel had come through this hole. The bowel was dark red and swollen. Mesenteric vessels pulsed well. No hole in the bowel was seen. Dense adhesions made laparoscopic completion unsafe. The incision was extended to a 25 cm lower midline laparotomy. Adhesions were cut sharply. The herniated small bowel was returned to the abdomen. No bowel injury was found. The entire small bowel looked pink with normal movement. No part

was dead or dying. A gynecologist was called in. Allis clamps were used through the vagina to hold the cuff edges. The top of the vagina was closed with a continuous double-layer stitch using 2-0 polyglactin 910 (Vicryl). The pelvis and abdomen were washed with plenty of saline. A drain was placed through the right lower abdomen. No active bleeding was seen. The abdomen was closed layer by layer. After surgery, she received antibiotics, fluids, glucose control, and was told to rest. She recovered well. No infection, fistula, or repeat prolapse occurred before discharge.

Discussion

Vaginal cuff dehiscence with small bowel evisceration is a rare but potentially fatal delayed complication of total hysterectomy, with a reported incidence of 0.09%–0.28%[1]. Delayed intervention can result in bowel ischemia, perforation, peritonitis, and sepsis, with reported mortality as high as 8%. Bowel resection is required in 15%–20% of cases[2]. The present case is notable for two unusual features. First, cuff dehiscence occurred six years after the index hysterectomy, which exceeds the median reported onset of 3 months after laparoscopic and 6.5 months after abdominal hysterectomy. Second, the precipitating event was a fall from 2 meters followed by Valsalva straining during defecation, a mechanism that has not been previously documented in the literature to our knowledge.

Several patient-specific and anatomical factors likely contributed to delayed cuff failure. Although clinical healing is expected by 6–8 weeks postoperatively, collagen remodeling at the cuff apex can continue for months. In patients with a history of pelvic malignancy, prior surgical trauma and chronic inflammation may further impair fibroblast activity and collagen cross-linking, extending the vulnerable window. The patient was 61 years old and postmenopausal. Estrogen deficiency produces thinning of the vaginal mucosa, reduced glycogen content, elevated local pH, and decreased tissue vascularity, all of which compromise cuff integrity. Most reported cases of post-hysterectomy evisceration occur in postmenopausal women, consistent with the demographic profile in this case.

Intraoperative findings included a 3 cm cuff fistula with approximately 50 cm of viable small bowel herniated into the perineum. The admission random glucose was 15.54 mmol/L. Hyperglycemia, whether pre-existing or stress-induced, impairs neutrophil chemotaxis and phagocytosis and reduces hydroxyproline synthesis, thereby delaying wound healing. After total hysterectomy, loss of cervical support alters the vaginal axis from an oblique to a more vertical orientation, directing intra-abdominal pressure directly onto the cuff apex. This permanent biomechanical change, in conjunction with the factors outlined above, created a latent structural weakness that failed six years after surgery when subjected to blunt trauma and a subsequent Valsalva maneuver.

The temporal sequence of injury is of particular interest. A fall from 2 meters onto the buttocks or perineum generates shear forces that transmit through the pelvic ring to the pelvic floor. This may cause microvascular injury or partial disruption of residual suture material at the cuff closure. The patient did not seek medical attention after the fall. During subsequent defecation, Valsalva maneuver produced a sharp increase in intra-abdominal pressure, which served as the final mechanical force displacing bowel through the weakened cuff. Pre-existing pelvic adhesions, with small bowel tethered to the previous incision and sidewall, may have restricted normal bowel mobility and facilitated anterior displacement

toward the cuff defect.

Operative management followed a staged approach. Diagnostic laparoscopy permitted rapid assessment of the abdominal cavity and bowel viability. Dense adhesions precluded safe completion by minimally invasive means, prompting conversion to a 25 cm lower midline laparotomy. This provided adequate exposure for adhesiolysis, complete reduction of 50 cm of herniated bowel, and confirmation of bowel viability. The cuff was repaired transvaginally with continuous double-layer 2-0 polyglactin 910 suture under direct visualization. A closed-suction drain was placed in the pelvis. Postoperative care included glycemic control, broad-spectrum antibiotics, and strict pelvic rest. The patient recovered without complication.

Emergency management of vaginal evisceration requires prompt recognition and multidisciplinary input. The prolapsed bowel must be kept moist with saline-soaked gauze, and forced reduction must be avoided. While transvaginal repair alone is an option in selected stable patients, it does not permit evaluation of the abdominal cavity and may fail to identify bowel injury or ischemia. Laparotomy or laparoscopy with full abdominal exploration is the preferred approach when adhesions are extensive, bowel viability is uncertain, or secure cuff closure cannot be achieved transvaginally. In this case, conversion to open laparotomy was both necessary and appropriate.

Conclusion

Vaginal cuff dehiscence with small bowel evisceration can happen years after hysterectomy. A fall combined with straining during defecation can trigger it. Fast multidisciplinary care, full abdominal inspection, and strong cuff repair give the best chance of recovery.

Declaration of Case Limitations

This case report has several limitations. First, the patient's initial hysterectomy was performed at an outside hospital, and the exact surgical approach, pathologic stage, and details of the endometrial cancer were unavailable. This limited our ability to assess whether the original cuff closure technique contributed to delayed dehiscence. Second, the patient did not seek medical care immediately after the fall. The interval between blunt trauma and bowel evisceration could not be precisely determined, and the extent of occult pelvic injury from the fall remains speculative. Third, no formal pelvic floor imaging was obtained before discharge, precluding assessment of underlying pelvic support defects that may have predisposed to herniation. Finally, as a single case report, no firm conclusions can be drawn regarding the incidence or prevention of this complication. Larger case series or registry data would be needed to validate the observations presented here.

Abbreviations

CT	Computed tomography
WBC	White blood cell
IL-6	Interleukin-6
Vicryl	Polyglactin 910 (t-0 absorbable suture)

Declarations

Ethics and consent to participate

This study is a single-center case report involving retrospective review of clinical data. Ethical review and approval were waived by the Institutional Review Board of The Second People's Hospital of Neijiang because the study used anonymized clinical data obtained during routine emergency and surgical care. Informed consent was obtained from the patient for participation in clinical care.

Consent to publish

Written informed consent was obtained from the patient for publication of this case report and any accompanying images. A copy of the written consent is available for review by the Editor-in-Chief of this journal upon request.

Availability of data and materials

Data supporting the findings of this case report are contained within the article. Additional raw clinical data are not publicly available due to patient privacy and confidentiality requirements.

Competing interests

The authors declare no competing interests.

Funding

This research received no external funding.

Authors' contributions

X.C. participated in emergency assessment and manuscript drafting. R.Y. conceived the case report, supervised clinical management, and revised and finalized the manuscript. All authors have read and agreed to the published version of the manuscript.

Acknowledgements

The authors thank the emergency department, operating room nursing team, and gynecology consultation service of The Second People's Hospital of Neijiang for their contributions to the patient's emergency care.

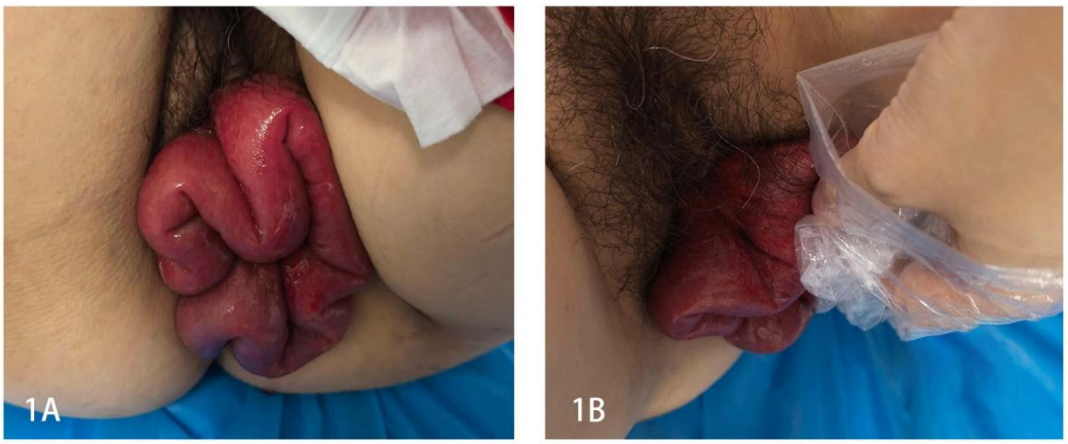

Figure 1. Intraoperative view of the small bowel protruding through the vaginal introitus, showing a dark-red, markedly edematous appearance with dusky mesentery.

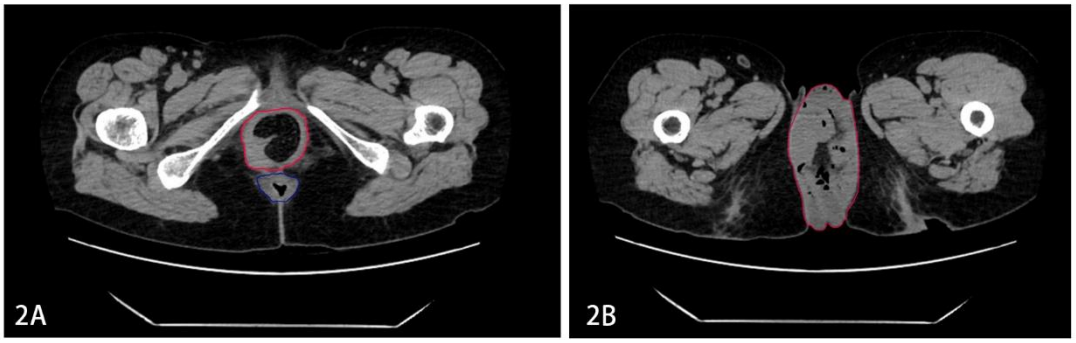

Figure 2. Axial non-contrast pelvic CT scans. (2A) The blue outline indicates the normal rectal lumen. The red outline demonstrates an incarcerated bowel loop within the vaginal canal. (2B) The red outline shows the herniated bowel protruding externally through the perineal defect.

Reference

1. Fuentes KJ, Arechavala Lopez SF, Fuentes I, et al. Atraumatic Spontaneous Transvaginal Small Bowel Evisceration: A Rare Surgical Emergency. (2168-8184 (Print))
2. Omejc A, Janša VA-O, Kobal B, et al. Spontaneous Transvaginal Intestinal Evisceration Two Years after Vaginal Hysterectomy, a Case Report. LID - 10.3390/medicina60091388 [doi] LID - 1388. (1648-9144 (Electronic))
3. Houmaid H, Sali M, Harou K, et al. Spontaneous Transvaginal Evisceration of the Small Bowel Two Years Post Laparoscopic Total Hysterectomy: A Case Report. (2168-8184 (Print))
4. Ishola AA, Ogundipe HD, Balogun RO, et al. SPONTANEOUS TRANSVAGINAL INTESTINAL EVISCERATION IN AN ELDERLY WOMAN. (1597-1627 (Print))
5. Kountouri IA-O, Giotas A, Gkogkos C, et al. Spontaneous Transvaginal Small Bowel Evisceration After Laparoscopic Hysterectomy. LID - 10.3390/diagnostics14222498 [doi] LID - 2498. (2075-4418 (Print))