Research Square

Preprints are preliminary reports that have not undergone peer review.
They should not be considered conclusive, used to inform clinical practice,
or referenced by the media as validated information.

Inflammatory cloacogenic polyp of the rectum in a 16-year-old female: a case report

Ruyi Yu

gi_surgeon9527@163.com

Second People's Hospital of Neijiang

Xin Chen

Second People's Hospital of Neijiang

Case Report

Keywords: Inflammatory cloacogenic polyp, Rectal bleeding, Adolescent, Transanal excision, Case report

Posted Date: November 26th, 2026

DOI: https://doi.org/10.21203/rs.3.rs-11622017/v1

License: This work is licensed under a Creative Commons Attribution 4.0 International License.
Read Full License

Additional Declarations: No competing interests reported.

Abstract

Background

Inflammatory cloacogenic polyp (ICP) is a rare benign lesion of the anorectal transitional zone, typically affecting adults between the fourth and sixth decades of life. Its endoscopic appearance may mimic neoplasia, and reports in adolescents are exceedingly scarce.

Case presentation

A 16-year-old female presented with a one-month history of intermittent fresh rectal bleeding. Digital rectal examination revealed two firm submucosal masses approximately 1 cm from the anal verge. Colonoscopy identified two broad-based lobulated lesions at the anorectal junction with surrounding mucosal congestion and superficial ulceration. Targeted biopsies showed only chronic inflammation with granulation tissue, and a clinical diagnosis of rectal tumour could not be excluded. Transanal local excision was performed under spinal anaesthesia using ultrasonic shears, with primary closure of the wound beds. Final histopathology confirmed inflammatory cloacogenic polyp, with no dysplasia or malignancy. The patient resumed oral intake on the same day and was discharged on postoperative day 2 without complications. Follow-up colonoscopy was scheduled at 3 to 6 months.

Conclusions

ICP should be considered in the differential diagnosis of rectal bleeding and polypoid lesions in adolescents, even when the clinical impression favours neoplasia. Transanal excision provides definitive diagnosis and treatment in a single procedure, with favourable short-term outcomes.

Introduction

Inflammatory cloacogenic polyps (ICP) are rare benign lesions of the anorectal transitional zone, first characterized as a distinct entity by Lobert and Appelman[1]. They are considered part of the mucosal prolapse spectrum, sharing overlapping clinical and histological features with solitary rectal ulcer syndrome, inflammatory cap polyps, and prolapsing mucosal polyps. The proposed pathogenesis involves recurrent mucosal trauma and ischaemia at the dentate line, triggering a cycle of inflammation, granulation tissue formation, and fibromuscular proliferation within the lamina propria[2]. Although histologically benign, inflammatory cloacogenic polyps may present endoscopically as polypoid or ulcerated masses that raise suspicion for neoplasia.

ICP typically affect adults in their fourth to sixth decades of life, with a slight female predominance. The most common presenting symptom is rectal bleeding, often accompanied by mucous discharge, tenesmus, or a sensation of incomplete evacuation. Constipation and excessive straining are frequently

reported associations, although a substantial proportion of patients deny these symptoms. Endoscopic differentiation from haemorrhoids, adenomas, or rectal carcinoma can be difficult, particularly when the lesion is solitary and located at the anorectal junction[3, 4]. Biopsy specimens are often inconclusive, showing only non-specific inflammation, which may lead to diagnostic delay or misdirection toward malignancy workup.

While inflammatory cloacogenic polyps are well recognised in adults, reports in the paediatric and adolescent population are exceedingly rare. The existing literature consists predominantly of isolated case reports, and to date, fewer than 20 cases have been documented in patients under 18 years of age. This scarcity poses a challenge for clinicians, as rectal bleeding in adolescents is more commonly attributed to inflammatory bowel disease, juvenile polyps, or haemorrhoids, making inflammatory cloacogenic polyp a diagnosis that is easily overlooked.

We report a 16-year-old female who presented with intermittent fresh rectal bleeding and was found to have two broad-based polypoid lesions at the anterior rectal wall, 1 cm above the dentate line. The endoscopic appearance raised concern for a rectal tumour, and a clinical diagnosis of neoplasia could not be excluded. Transanal local excision using ultrasonic shears was performed, and final histopathology confirmed inflammatory cloacogenic polyp. This case adds to the limited literature on ICP in adolescents and highlights the diagnostic challenge posed by its endoscopic resemblance to rectal tumours.

Case presentation

A 16-year-old female presented with a one-month history of intermittent fresh rectal bleeding. The blood was bright red, coated the stool surface, and was occasionally mixed with small clots. She reported mild anal heaviness but denied abdominal pain, diarrhoea, constipation, tenesmus, mucus discharge, weight loss, or fever. Her bowel habit was two to three motions per day. She had no prior abdominal or pelvic surgery, no chronic medical conditions, and no regular medication use. Menarche was at 13 years with regular cycles. There was no family history of colorectal cancer. Abdominal examination was unremarkable. Digital rectal examination revealed two firm, mobile submucosal masses approximately 1 × 1 cm each at 1 cm from the anal verge. The examining finger returned with fresh blood and yellow stool. Anal sphincter tone was normal. Colonoscopy performed the following day showed normal mucosa from the caecum to the sigmoid colon. At the rectal ampulla, 1 cm above the dentate line, two broad-based lobulated lesions were identified, measuring approximately 1.2 to 1.5 cm. The surrounding rectal mucosa was congested, oedematous, granular, and showed superficial erosions with whitish exudate. Targeted biopsies were taken from both lesions. Histopathological assessment reported mucosal chronic inflammation with inflammatory granulation tissue proliferation (Fig. 1). No dysplasia or malignancy was identified on the biopsy specimens. Based on the endoscopic appearance and the patient's age, a clinical diagnosis of rectal tumour could not be excluded.

After discussion at a multidisciplinary team meeting, the decision was made to proceed with transanal local excision for definitive diagnosis and treatment. The procedure was performed under spinal anaesthesia with the patient in the lithotomy position. A retractor was used to expose the anal canal. Two polypoid lesions were identified at the 3-o'clock and 9-o'clock positions, measuring approximately 2.0 × 1.0 cm and 2.0 × 1.5 cm respectively. Both were firm, mobile, and covered by intact mucosa. Using ultrasonic shears, each lesion was excised with a 5 mm margin of surrounding normal mucosa. The wound beds were closed primarily with absorbable sutures. Intraoperative blood loss was minimal, and no drain was placed. The resected specimens were sent for histopathological examination. Macroscopically, two polypoid fragments were received, the larger measuring 3.5 × 1.7 × 1.1 cm (Fig. 2A). Microscopy showed elongated and distorted crypts, superficial epithelial erosion, mixed acute and chronic inflammatory infiltrates, granulation tissue, and thickened muscularis mucosae extending into the lamina propria with fibromuscular proliferation (Fig. 2B and C). No dysplasia or malignant cells were seen. The final pathological diagnosis was inflammatory cloacogenic polyp of the rectum. The patient was allowed oral intake on the same day and was discharged on postoperative day 2 without complications. At discharge, she was advised on a high-fibre diet and stool softeners, with follow-up colonoscopy scheduled at 3 to 6 months to assess mucosal healing and exclude residual or recurrent lesions. She did not require further intervention.

Discussion

Inflammatory cloacogenic polyp (ICP) is a benign lesion of the anorectal transitional zone, first described by Lobert and Appelman in 1981[1]. Histologically, it is characterized by crypt distortion, granulation tissue, and fibromuscular proliferation in the lamina propria, findings that place it within the mucosal prolapse spectrum[3]. The condition predominantly affects women in their 40s to 60s. Reports in adolescents are scarce; a literature review identified fewer than 20 cases under the age of 18. Our patient, a 16-year-old female with two separate polyps at the anorectal junction, adds to this limited experience.

The benign nature of ICP is generally attributed to a self-perpetuating cycle of mucosal injury, reactive inflammation, and reparative fibromuscular overgrowth. Nevertheless, isolated reports document malignant transformation into cloacogenic carcinoma, which is why complete excision is recommended even for asymptomatic lesions. This risk also explains why thorough endoscopic evaluation matters. Rectal retroflexion has been proposed to improve detection of distal lesions, but prospective studies show it mainly identifies benign anorectal pathology and does not increase adenoma detection rates compared with forward-viewing examination alone[1, 5]. In practice, lesions at the anorectal transitional zone are difficult to assess from above. In our case, the polyps sat 1 cm above the dentate line. Antegrade colonoscopy offered limited views, and pinch biopsies returned only nonspecific inflammation. En bloc transanal excision was therefore both diagnostic and therapeutic.

Endoscopically, ICP can resemble hemorrhoids, villous adenoma, or carcinoma. Our patient's polyps were broad-based, lobulated, and arose against a background of congested, ulcerated mucosa, findings

that prompted a clinical diagnosis of rectal tumor. Superficial biopsy confirmed chronic inflammation but could not rule out neoplasia. This is a recognized limitation: surface sampling often misses the characteristic submucosal architecture. Definitive diagnosis requires full-thickness assessment of the entire lesion.

Why these polyps formed in a teenager is uncertain. Mucosal prolapse from repeated mechanical stress is the leading hypothesis. Our patient had no history of chronic constipation or excessive straining, but the background mucosa showed congestion, edema, and superficial ulceration. Whether this represents early prolapse-related change, transient local irritation, or an incidental finding is unclear. No underlying inflammatory bowel disease was identified on pathology.

Surgical options for low rectal polyps range from radical resection to local excision. For small, benign-appearing lesions in the distal rectum, transanal approaches are preferred when feasible. We used ultrasonic shears to excise both polyps with a 5 mm margin, closing the defects primarily. The procedure was performed under spinal anesthesia, took a single session, and achieved complete removal. This avoided the need for transanal endoscopic microsurgery or formal laparotomy. The patient was discharged on postoperative day 2 without complication. En bloc excision provided definitive histology confirming ICP, with no dysplasia or malignancy.

Declarations

Ethics and consent to participate

This study was conducted in accordance with the ethical standards of the Institutional Review Board of The Second People's Hospital of Neijiang and with the principles of the Helsinki Declaration (as revised in 2013). Informed consent for participation in clinical care was obtained from the patient’s parent/legal guardian.

Consent to publish

Written informed consent for publication of this case report and any accompanying images was obtained from the patient’s parent/legal guardian, as the patient is a minor (under 18 years of age). The consent explicitly specifies that the case details and images are published under the relevant Creative Commons license, allowing free availability on the internet. A copy of the written consent form is available for review by the Editor-in-Chief of this journal upon request.

Availability of data and materials

Data supporting the findings of this case report are contained within the article. Additional raw clinical data are not publicly available due to patient privacy and confidentiality requirements.

Competing interests

The authors declare no conflicts of interest.

Funding

This research received no external funding.

Authors' contributions

X.C. was involved in the clinical evaluation and wrote the first draft of the manuscript. R.Y. designed the case report, supervised patient management, and critically revised the manuscript. Both authors read and approved the final manuscript.

Acknowledgements

Not applicable.

References

1. Lobert Pf Fau - Appelman HD, Appelman HD. Inflammatory cloacogenic polyp. A unique inflammatory lesion of the anal transitional zone. (0147–5185 (Print))
2. Prakash N, Vyas SJ, Mohammed A, et al. Inflammatory Cloacogenic Polyp: A Rare Benign Colorectal Polyp. (2168–8184 (Print))
3. Ochiai Y, Matsui A, Ito S, et al. Double Early Rectal Cancer Arising from Multiple Inflammatory Cloacogenic Polyps Resected by Endoscopic Submucosal Dissection. *Intern Med*. Feb 15 2021;60(4):533–537. doi:10.2169/internalmedicine.5686-20
4. Kim YI, Joo JY, Yang HR. Inflammatory cloacogenic polyps in children: diagnostic yield of rectal retroflexion during colonoscopy. (1471-230X (Electronic))
5. Ferrer Martínez AA-O, Valle Rubio A, Manuel Vázquez AA-O, et al. Inflammatory cloacogenic polyp: differential diagnosis with endoscopic malignant lesions. (1130 – 0108 (Print))

Figures

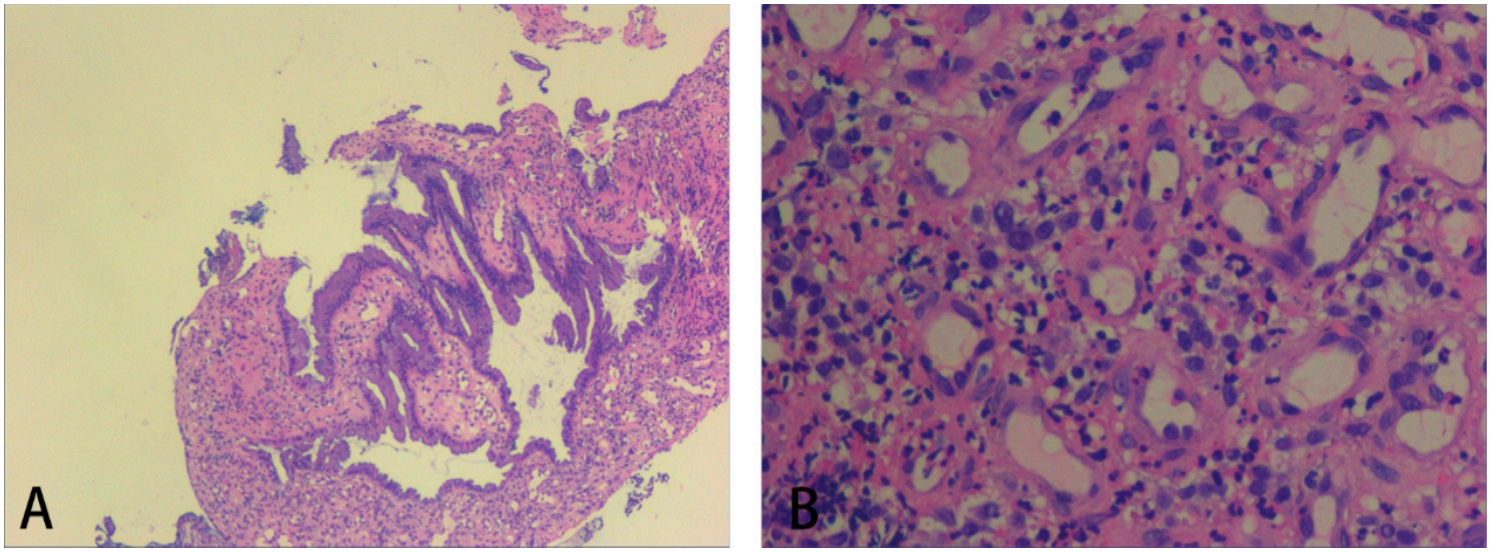

Figure 1

Initial targeted biopsy and histopathological findings. (A) Low-power view (H&E, ×40; scale bar = 500 μm) showing mucosal architecture with superficial epithelial erosion. (B) High-power view (H&E, ×400; scale bar = 100 μm) showing mixed chronic inflammatory infiltrates and inflammatory granulation tissue proliferation. No dysplasia or malignancy was identified.

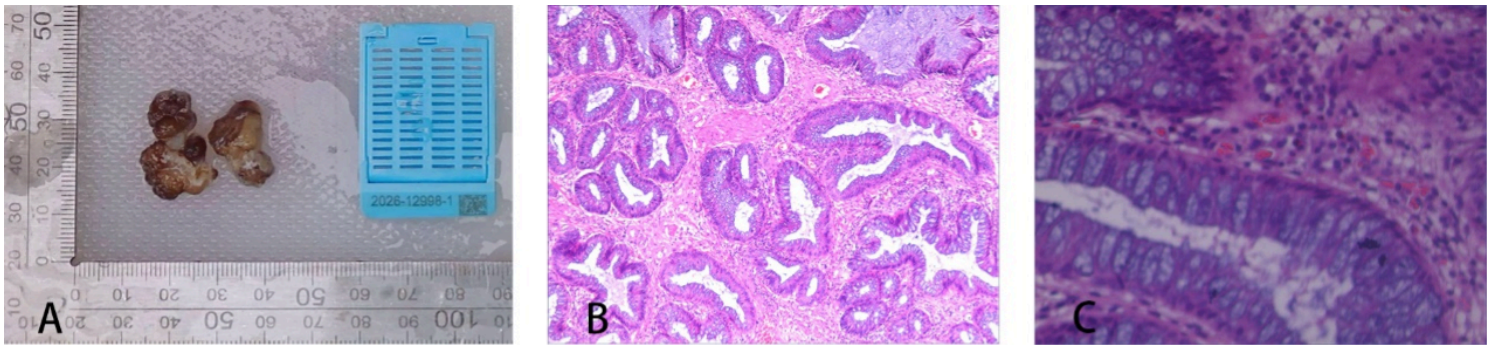

Figure 2

Resected specimen and final diagnosis of inflammatory cloacogenic polyp of the rectum. (A) Gross appearance of two polypoid fragments (the larger measuring 3.5 × 1.7 × 1.1 cm, the smaller 2.0 × 1.5 × 1.1 cm) with a ruler for scale. (B) Low-power view (H&E, ×40; scale bar = 500 μm) revealing distorted crypt architecture and superficial erosion. (C) High-power view (H&E, ×400; scale bar = 100 μm) confirming mixed acute and chronic inflammatory infiltrates and granulation tissue. Final pathology: inflammatory cloacogenic polyp, no dysplasia.