Research Square

Preprints are preliminary reports that have not undergone peer review.
They should not be considered conclusive, used to inform clinical practice,
or referenced by the media as validated information.

Early T-precursor lymphoblastic leukemia/lymphoma mimicking myelodysplastic neoplasm: A case report with a dive into early T-cell precursors

Ana P. Gaxiola
The University of Texas MD Anderson Cancer Center
Wei Wang
The University of Texas MD Anderson Cancer Center
Sa A. Wang
The University of Texas MD Anderson Cancer Center
Sabino Portugal-Portugal
Tariq Muzzafar
The University of Texas MD Anderson Cancer Center
Carlos E. Bueso-Ramos
The University of Texas MD Anderson Cancer Center
L. Jeffrey Medeiros
The University of Texas MD Anderson Cancer Center
Roberto N. Miranda
roberto.miranda@mdanderson.org

The University of Texas MD Anderson Cancer Center

Case Report

Keywords: Early T-precursor lymphoblastic leukemia/lymphoma, Myelodysplastic neoplasm, Flow cytometry, Cytoplasmic CD3, CD5, Thymic maturation

Posted Date: November 26th, 2026

DOI: https://doi.org/10.21203/rs.3.rs-11613521/v1

License: This work is licensed under a Creative Commons Attribution 4.0 International License.
Read Full License

Additional Declarations: Competing interest reported. R.N.M. is a member of the International Editorial Board of the Journal of Hematopathology, and C.E.B.-R. served on the Editorial Board of the Journal of Hematopathology from 2007 to 2024. The authors have no other relevant financial or non-financial interests to disclose.

Abstract

Early T-precursor lymphoblastic leukemia/lymphoma (ETP-ALL) is a high-risk subtype of T-ALL in which blasts express stem-cell and myeloid-associated antigens. We describe a 79-year-old man who developed cytopenias. Bone marrow examination at an outside hospital showed 12% blasts, leading to a diagnosis of myelodysplastic neoplasm (MDS) with increased blasts. The patient received 2 cycles of azacitidine with persistent disease and was subsequently referred to our institution. A repeat bone marrow examination at our institution showed multilineage dysplasia and 12% blasts in aspirate smears and 20% blasts in the core biopsy. By flow cytometry immunophenotypic analysis, blasts accounted for 25% of marrow cells and were positive for CD7, cytoplasmic CD3, CD33, CD123, CD133, and dim CD45, partially positive for CD34, CD117, HLA-DR, and TdT, and dim/partial for CD5 (52% of blasts). They were negative for CD1a, CD4, CD8, CD19, and myeloperoxidase, consistent with T-lymphoblastic leukemia with an early T-precursor phenotype (ETP-ALL). Next-generation sequencing showed somatic mutations in *DNMT3A*, *TET2*, *CBL*, *IKZF1*, and *NOTCH1*, and optical genome mapping showed a deletion of 12p13.33p12.1. This case highlights the importance of immunophenotyping of blasts in suspected myeloid neoplasms, including MDS, MPN, and MDS/MPN, even when blasts comprise less than 20%, to avoid misclassification of acute leukemias, including ETP-ALL with oligoblastic presentations.

Introduction

Early T-precursor lymphoblastic leukemia/lymphoma (ETP-ALL) is a high-risk subtype of T-ALL defined by an immunophenotype resembling that of early thymic precursors. Originally described by Coustan-Smith and colleagues in 2009 [1], ETP-ALL is recognized as an entity in current leukemia classifications [2–4]. In ETP-ALL, the blasts express stem-cell markers such as CD34, CD117, and HLA-DR as well as myeloid-associated antigens such as CD11b, CD13, and CD33; therefore, ETP-ALL can be confused with a myeloid neoplasm such as myelodysplastic neoplasm (MDS) or acute myeloid leukemia (AML). MDS is a particular concern in older adults with cytopenias, dysplastic hematopoiesis, and a blast count of less than 20% [5–7].

We report a patient who presented with pancytopenia, was diagnosed with MDS, and was treated with azacitidine with poor response. Immunophenotypic evaluation at our institution established the diagnosis of ETP-ALL. We discuss the features that led to the initial diagnosis of MDS and review thymic T-cell development and its application to this case.

Clinical history

A 79-year-old man with congestive heart failure, hypertension, and hyperlipidemia developed progressive weakness. A complete blood count showed a white blood cell count (WBC) of 2.0 × 10^9/L (normal, 4.1–10.5 × 10^9/L), hemoglobin 12.9 g/dL (normal, 13.3–17.4 g/dL), and platelets 113 × 10^9/L (normal, 160–397 × 10^9/L). Bone marrow examination at an outside hospital in February 2026 reported 12% blasts. The karyotype was diploid, fluorescence in situ hybridization studies were negative, and molecular

testing showed no mutations in *CEBPA*, *FLT3*, *NPM1*, *IDH1*, *IDH2*, or *KIT*. The patient was diagnosed with high-risk MDS and received two cycles of azacitidine; the first cycle was complicated by infection. He was referred to our institution because of a poor response.

Materials and methods

The outside bone marrow specimen was not available for review. Bone marrow aspiration and biopsy were performed at our institution after two cycles of azacitidine. Wright-Giemsa–stained peripheral blood (PB) and bone marrow (BM) aspirate smears and touch imprints, and H&E-stained aspirate clot and core biopsy sections were prepared. An iron stain was performed on aspirate smears, and reticulin and trichrome stains on the core biopsy. Immunohistochemistry was performed on the core biopsy using antibodies specific for CD3, CD4, CD5, CD7, CD8, CD34, CD99, CD117, and TdT as described previously [8].

Flow cytometry was performed on BM aspirate (stain/lyse/wash procedure; ≥200,000 events acquired on a FACSCanto II [BD Biosciences] and analyzed with FCS Express 7 [De Novo Software]) as previously described [9]. The acute leukemia screening panel included CD2, surface CD3, CD4, CD5, CD7, CD13, CD14, CD15, CD19, CD25, CD33, CD34, CD36, CD38, CD45, CD54, CD56, CD64, CD117, CD123, CD133, and HLA-DR, and a permeabilized tube for cytoplasmic CD3 (clone SK7), CD34, CD117, myeloperoxidase (MPO), and terminal deoxynucleotidyl transferase (TdT). A T-ALL add-on panel included additional antibodies specific for CD1a, CD8, and CD10. Conventional karyotyping (20 metaphases, unstimulated 24- and 48-hour cultures) and optical genome mapping (OGM; Saphyr, Bionano Genomics, San Diego, CA, USA) were performed as previously described [10]. Mutation analysis used an 81-gene myeloid NGS panel (NextSeq, Illumina, San Diego, CA, USA; sensitivity 5% variant allele frequency) as has been reported [11]. This study was approved by the Institutional Review Board.

Results

At the time of BM examination, the complete blood count showed WBC 1.9 × 10^9/L, hemoglobin 9.6 g/dL, and platelets 83 × 10^9/L, with 8% circulating blasts. BM aspirate smears showed 12% blasts on a 500-cell differential count; blasts were small to intermediate in size with agranular cytoplasm and dispersed chromatin (Fig. 1a). There was erythroid predominance (myeloid-to-erythroid ratio, 1.1). Neutrophils showed hyposegmented, dysmorphic nuclei (Fig. 1a), and erythroid precursors showed nuclear-to-cytoplasmic asynchrony. Megakaryocytes were adequate in number and included small hypolobated forms with separated nuclear lobes (Fig. 1e). Iron stain showed increased storage iron without ring sideroblasts. The core biopsy was 60% cellular with increased immature mononuclear cells, which accounted for approximately 20% of marrow cells (Fig. 1b); reticulin stain showed mild fibrosis (MF-1). By immunohistochemistry, the blasts were positive for CD7, CD34 (Fig. 1c), CD99, and TdT, with a subset positive for CD3 (Fig. 1d) and CD117 and weak CD5 expression; they were negative for CD4 and CD8.

Flow cytometric immunophenotyping identified 25% aberrant T-lymphoblasts in a discrete CD45-dim population (Fig. 2a). The blasts were positive for CD7, cytoplasmic CD3 (variable intensity), CD33, CD123, and CD133, and partially positive for CD34, CD117, HLA-DR, and TdT (Fig. 2b, c, e, h); surface CD3 was dim to negative (Fig. 2e). CD5 was partially and dimly expressed in 52% of blasts (Fig. 2f). Blasts were negative for MPO (Fig. 2g), CD1a (Fig. 2f), CD2, CD4 and CD8 (Fig. 2d), CD10, CD13, CD14, CD15, CD19 (Fig. 2h), CD25, CD36, CD38, CD54, CD56, and CD64. Flow cytometry also detected a small number of CD34-positive myeloid precursors without immunophenotypic abnormalities.

Conventional karyotyping analysis showed 46,XY[20]. OGM showed a 22-Mb deletion at 12p13.33p12.1, encompassing *ETV6* and *CDKN1B*. NGS detected somatic mutations of *DNMT3A* (p.F414V, variant allele frequency [VAF] 45%; p.V704G, 34%), *TET2* (p.I1139fs, 32%; p.Y1631*, 17%), *CBL* (c.1096-1G > T, 20%), *IKZF1* (p.S308fs, 11%), and *NOTCH1* (p.L1678Q, 6%; p.L1678P, < 5%) variants.

A follow-up BM examination 4 weeks later showed persistent T-ALL with 32% blasts, and treatment with mini-hyper-CVD plus venetoclax was initiated. Cerebrospinal fluid (CSF) flow cytometry performed for staging detected 16.7% T-lymphoblasts; brain magnetic resonance imaging showed no intracranial lesions, and the patient received twice-weekly triple intrathecal chemotherapy. He died 10 days after admission.

Discussion

Although T-ALL predominantly affects children and adolescents, ETP-ALL is more common in adults. Patients with ETP-ALL usually present with cytopenias and variable BM involvement, and respond more poorly to therapy than patients with non-ETP T-ALL [5, 6, 12]. Similar to other T-ALL subtypes, ETP-ALL expresses cytoplasmic CD3, CD7, and dim CD45, but diagnosis of ETP-ALL also requires expression of at least one stem-cell or myeloid-associated marker (CD34, CD117, HLA-DR, CD13, CD11b, CD33, or CD65) in ≥ 25% of blasts, as well as the absence of CD1a and CD8 (< 5% of blasts). CD5 is either absent or dim (< 75% of blasts) [1, 4].

In the case we present here, advanced age, cytopenias, trilineage dysplasia, and < 20% blasts in aspirate smears, both at the outside hospital and at our institution, were highly suggestive of MDS and contributed to the initial misdiagnosis [13]. In clinical practice, when acute leukemia is not suspected, flow cytometric immunophenotyping may not be performed or may be limited to an MDS panel that does not include cytoplasmic CD3 or MPO. At our institution, comprehensive blast immunophenotypic characterization is performed in all cases of suspected MDS. Of note, blasts in MDS typically exhibit an immature myeloid immunophenotype ($CD34^+CD117^+CD33^+CD13^+$) [14]. When CD34 expression is absent or only partial, as in this case, the possibility of evolving acute leukemia, including AML with defining genetic abnormalities, should be carefully excluded [15]. Furthermore, uniform CD7 expression on blasts should prompt evaluation of cytoplasmic CD3, regardless of the blast percentage. In this case, flow cytometric immunophenotyping was essential for establishing T-lineage differentiation of the blasts despite their expression of multiple myeloid-associated and stem-cell markers. The diagnoses of AML

with aberrant T-cell antigens and T/myeloid mixed-phenotype acute leukemia were excluded by the absence of MPO and monocytic differentiation markers [3]. There was no evidence of *BCR::ABL1* fusion, thereby excluding blast phase of chronic myeloid leukemia [16]. Distinguishing MDS from ETP-ALL in this patient had direct therapeutic consequences. Patients with MDS are usually managed with hypomethylating agents with or without venetoclax [17], whereas patients with ETP-ALL require ALL-directed therapy, central nervous system (CNS) prophylaxis, and intrathecal therapy; CNS involvement was present in this patient.

T-cell development occurs in the thymus. Early thymic progenitors are known to express CD7, cytoplasmic CD3, the stem-cell markers CD34, CD117, and HLA-DR, and the myeloid markers CD13 and CD33. Early thymic precursors also have incipient CD5 expression and retain myeloid, natural killer, and limited B-cell differentiation potential. *NOTCH1* signaling through Delta-like 4 on thymic epithelium [18] and BCL11B expression [19] extinguish alternative fates and establish T-cell commitment; thymocytes then acquire CD1a, CD5, CD4, and CD8 (Fig. 3) [20]. Accordingly, ETP-ALL is enriched for *DNMT3A*, *TET2*, and other myeloid-type mutations [21, 22], and 12p deletion involving *ETV6* is more frequently reported in ETP-ALL than in non-ETP ALL [23], whereas *NOTCH1* and *IKZF1* alterations support lymphoblastic leukemia. In this case, *DNMT3A* and *TET2* VAFs exceeded those expected from the blasts (20%–25% of cells), suggesting antecedent clonal hematopoiesis [24, 25]. The possibility of underlying MDS was considered given the presence of significant multilineage dysplasia, pancytopenia, and *DNMT3A* and *TET2* mutations. However, the patient had no documented history of cytopenias preceding the diagnosis to support preexisting MDS. Furthermore, flow cytometric immunophenotyping identified phenotypically normal myeloid precursors, arguing against a coexisting myeloid neoplasm.

In summary, we report a case of ETP-ALL in an elderly patient presenting with pancytopenia, low-level blast involvement, and multilineage dysplasia, closely mimicking MDS. Flow cytometric immunophenotyping demonstrated expression of the T-lineage–defining marker cytoplasmic CD3 and absence of MPO, establishing the diagnosis of ETP-ALL, which was further supported by molecular genetic findings. This case highlights the importance of comprehensive blast immunophenotyping, even when blasts account for < 20%, and emphasizes that blast immunophenotypes atypical for MDS should prompt further evaluation to establish lineage differentiation.

Declarations

Competing Interests

R.N.M. is a member of the International Editorial Board of the Journal of Hematopathology, and C.E.B.-R. served on the Editorial Board of the Journal of Hematopathology from 2007 to 2024. The authors have no other relevant financial or non-financial interests to disclose.

Ethics approval:

This study was performed in accordance with the Declaration of Helsinki and was approved by the Institutional Review Board of The University of Texas MD Anderson Cancer Center.

Consent to participate

and consent to publish: The requirement for informed consent was waived by the Institutional Review Board.

Use of artificial intelligence

Generative artificial intelligence tools were used to assist in drawing the cell illustrations in Fig. 3. The authors designed the figure, reviewed and edited its content, and take full responsibility for it. No artificial intelligence tools were used to generate or modify the clinical, morphologic, immunohistochemical, or flow cytometry images.

Funding:

No funding was received for this work.

Author Contribution

A.P.G., L.J.M., and R.N.M. wrote the main manuscript text. W.W., S.A.W., and T.M. performed and interpreted the flow cytometric immunophenotypic analysis at diagnosis and follow-up, and S.A.W. and W.W. prepared Figure 2. A.P.G. and R.N.M. prepared Figures 1 and 3. S.P.-P. contributed to the discussion of pathogenesis. C.E.B.-R. contributed to the morphologic evaluation of the case. All authors contributed to the design and discussion of the case report, and reviewed and approved the final manuscript.

Data Availability

Data supporting this report are available from the corresponding author upon reasonable request.

References

1. Coustan-Smith E, Mullighan CG, Onciu M et al (2009) Early T-cell precursor leukaemia: a subtype of very high-risk acute lymphoblastic leukaemia. Lancet Oncol 10:147–156. https://doi.org/10.1016/S1470-2045(08)70314-0
2. WHO Classification of Tumours Editorial Board (2024) Haematolymphoid tumours. WHO classification of tumours series, vol 11, 5th edn. International Agency for Research on Cancer, Lyon

3. Arber DA, Orazi A, Hasserjian RP et al (2022) International Consensus Classification of myeloid neoplasms and acute leukemias: integrating morphologic, clinical, and genomic data. Blood 140:1200–1228. https://doi.org/10.1182/blood.2022015850
4. Choi JK, Xiao W, Chen X et al (2024) Fifth edition of the World Health Organization Classification of Tumors of the Hematopoietic and Lymphoid Tissues: acute lymphoblastic leukemias, mixed-phenotype acute leukemias, myeloid/lymphoid neoplasms with eosinophilia, dendritic/histiocytic neoplasms, and genetic tumor syndromes. Mod Pathol 37:100466. https://doi.org/10.1016/j.modpat.2024.100466
5. Jain N, Lamb AV, O'Brien S et al (2016) Early T-cell precursor acute lymphoblastic leukemia/lymphoma (ETP-ALL/LBL) in adolescents and adults: a high-risk subtype. Blood 127:1863–1869. https://doi.org/10.1182/blood-2015-08-661702
6. Wood BL, Devidas M, Summers RJ et al (2023) Prognostic significance of ETP phenotype and minimal residual disease in T-ALL: a Children's Oncology Group study. Blood 142:2069–2078. https://doi.org/10.1182/blood.2023020678
7. Bensalah M, Berhili A, Slaoui M et al (2024) Diagnostic challenges of early T-cell precursor acute lymphoblastic leukemia: a case report and literature review. Cureus 16:e71615. https://doi.org/10.7759/cureus.71615
8. Khoury JD, Wang WL, Prieto VG et al (2018) Validation of immunohistochemical assays for integral biomarkers in the NCI-MATCH EAY131 clinical trial. Clin Cancer Res 24:521–531. https://doi.org/10.1158/1078-0432.CCR-17-1597
9. Khogeer H, Rahman H, Jain N et al (2019) Early T precursor acute lymphoblastic leukaemia/lymphoma shows differential immunophenotypic characteristics including frequent CD33 expression and in vitro response to targeted CD33 therapy. Br J Haematol 186:538–548. https://doi.org/10.1111/bjh.15960
10. Tang G, Reynolds A, Ravandi-Kashani F et al (2026) Comprehensive cytogenomic profiling of T-lymphoblastic leukemia using optical genome mapping, karyotyping, and next-generation sequencing. Mod Pathol 39:100986. https://doi.org/10.1016/j.modpat.2026.100986
11. Patel KP, Ruiz-Cordero R, Chen W et al (2019) Ultra-rapid reporting of GENomic targets (URGENTseq): clinical next-generation sequencing results within 48 hours of sample collection. J Mol Diagn 21:89–98. https://doi.org/10.1016/j.jmoldx.2018.08.002
12. Ye MT, Wang Y, Zuo Z et al (2023) Integrated clinical genotype-phenotype characteristics of early T-cell precursor acute lymphoblastic leukemia. Cancer 129:49–59. https://doi.org/10.1002/cncr.34515
13. Hasserjian RP, Germing U, Malcovati L (2023) Diagnosis and classification of myelodysplastic syndromes. Blood 142:2247–2257. https://doi.org/10.1182/blood.2023020078
14. Ogata K, Kishikawa Y, Satoh C et al (2006) Diagnostic application of flow cytometric characteristics of CD34 + cells in low-grade myelodysplastic syndromes. Blood 108:1037–1044. https://doi.org/10.1182/blood-2005-12-4916

15. Sameeta F, Wang W, Jelloul FZ et al (2025) The significance of detecting an unusual myeloblast immunophenotype in a presumptive clinical diagnosis of myelodysplastic syndromes. Arch Pathol Lab Med 149:717–726. https://doi.org/10.5858/arpa.2024-0228-OA
16. Xu ES, Wang J SA et al (2025) Blast phase of chronic myeloid leukemia presenting as early T-cell precursor acute lymphoblastic leukemia. Am J Clin Pathol 163:231–239. https://doi.org/10.1093/ajcp/aqae115
17. Garcia-Manero G (2023) Myelodysplastic syndromes: 2023 update on diagnosis, risk-stratification, and management. Am J Hematol 98:1307–1325. https://doi.org/10.1002/ajh.26984
18. Koch U, Fiorini E, Benedito R et al (2008) Delta-like 4 is the essential, nonredundant ligand for Notch1 during thymic T cell lineage commitment. J Exp Med 205:2515–2523. https://doi.org/10.1084/jem.20080829
19. Li L, Leid M, Rothenberg EV (2010) An early T cell lineage commitment checkpoint dependent on the transcription factor Bcl11b. Science 329:89–93. https://doi.org/10.1126/science.1188989
20. Yui MA, Rothenberg EV (2014) Developmental gene networks: a triathlon on the course to T cell identity. Nat Rev Immunol 14:529–545. https://doi.org/10.1038/nri3702
21. Zhang J, Ding L, Holmfeldt L et al (2012) The genetic basis of early T-cell precursor acute lymphoblastic leukaemia. Nature 481:157–163. https://doi.org/10.1038/nature10725
22. Neumann M, Heesch S, Schlee C et al (2013) Whole-exome sequencing in adult ETP-ALL reveals a high rate of DNMT3A mutations. Blood 121:4749–4752. https://doi.org/10.1182/blood-2012-11-465138
23. Xu X, Paxton CN, Hayashi RJ et al (2021) Genomic and clinical characterization of early T-cell precursor lymphoblastic lymphoma. Blood Adv 5:2890–2900. https://doi.org/10.1182/bloodadvances.2021004334
24. Ogawa S (2019) Genetics of MDS. Blood 133:1049–1059. https://doi.org/10.1182/blood-2018-10-844621
25. Sperling AS, Gibson CJ, Ebert BL (2017) The genetics of myelodysplastic syndrome: from clonal hematopoiesis to secondary leukemia. Nat Rev Cancer 17:5–19. https://doi.org/10.1038/nrc.2016.112
26. Hosokawa H, Rothenberg EV (2021) How transcription factors drive choice of the T cell fate. Nat Rev Immunol 21:162–176. https://doi.org/10.1038/s41577-020-00426-6

Figures

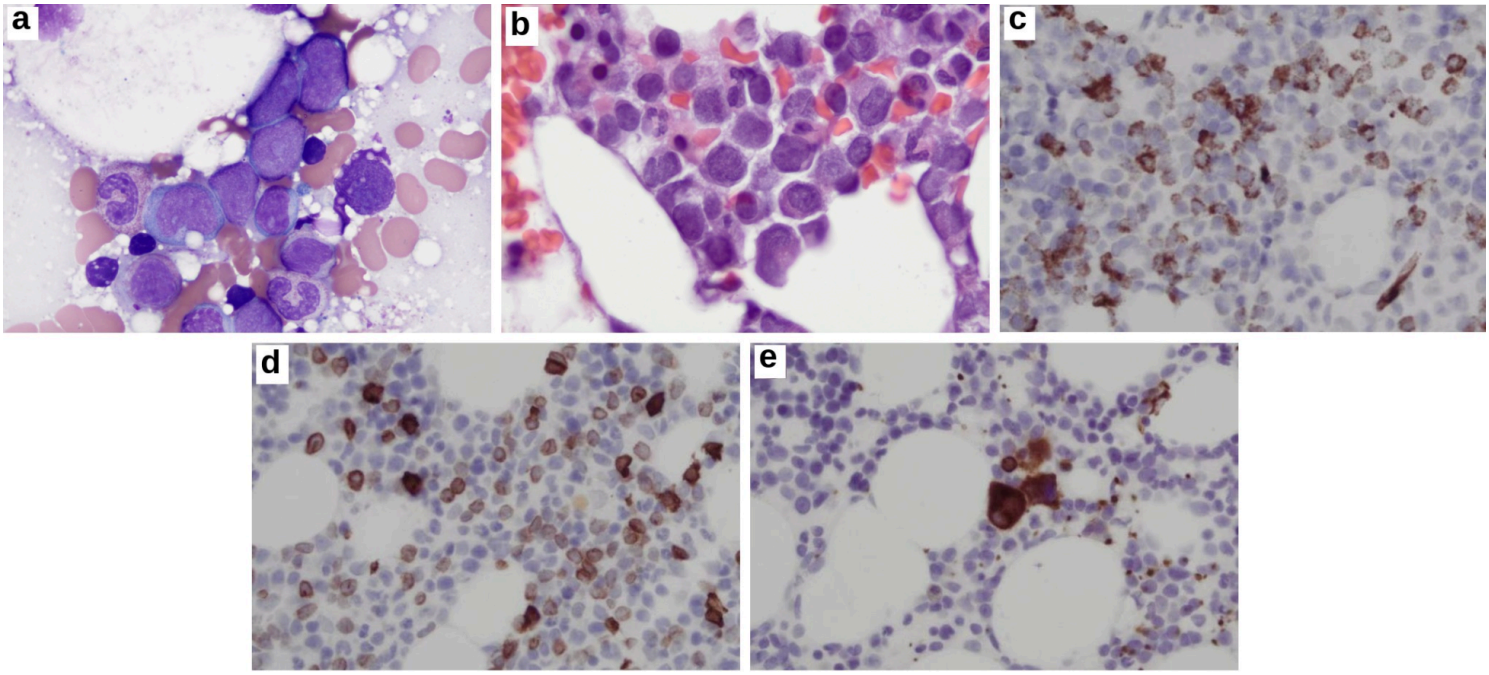

Figure 1

ETP-ALL initially diagnosed as myelodysplastic neoplasm. **a** The bone marrow aspirate smear shows small-to-intermediate blasts with a high nuclear-to-cytoplasmic ratio, agranular cytoplasm, and dispersed chromatin; maturing granulocytes show hyposegmented, dysmorphic nuclei (Wright-Giemsa, 1000×). **b** The core biopsy shows interstitial and focal aggregates of immature mononuclear cells (H&E, 1000×). **c** CD34 highlights blasts. **d** CD3 shows weak reactivity in blasts. **e** CD61 highlights small, hypolobated megakaryocytes and a rare micromegakaryocyte (c–e, immunohistochemistry with hematoxylin counterstain, 400×)

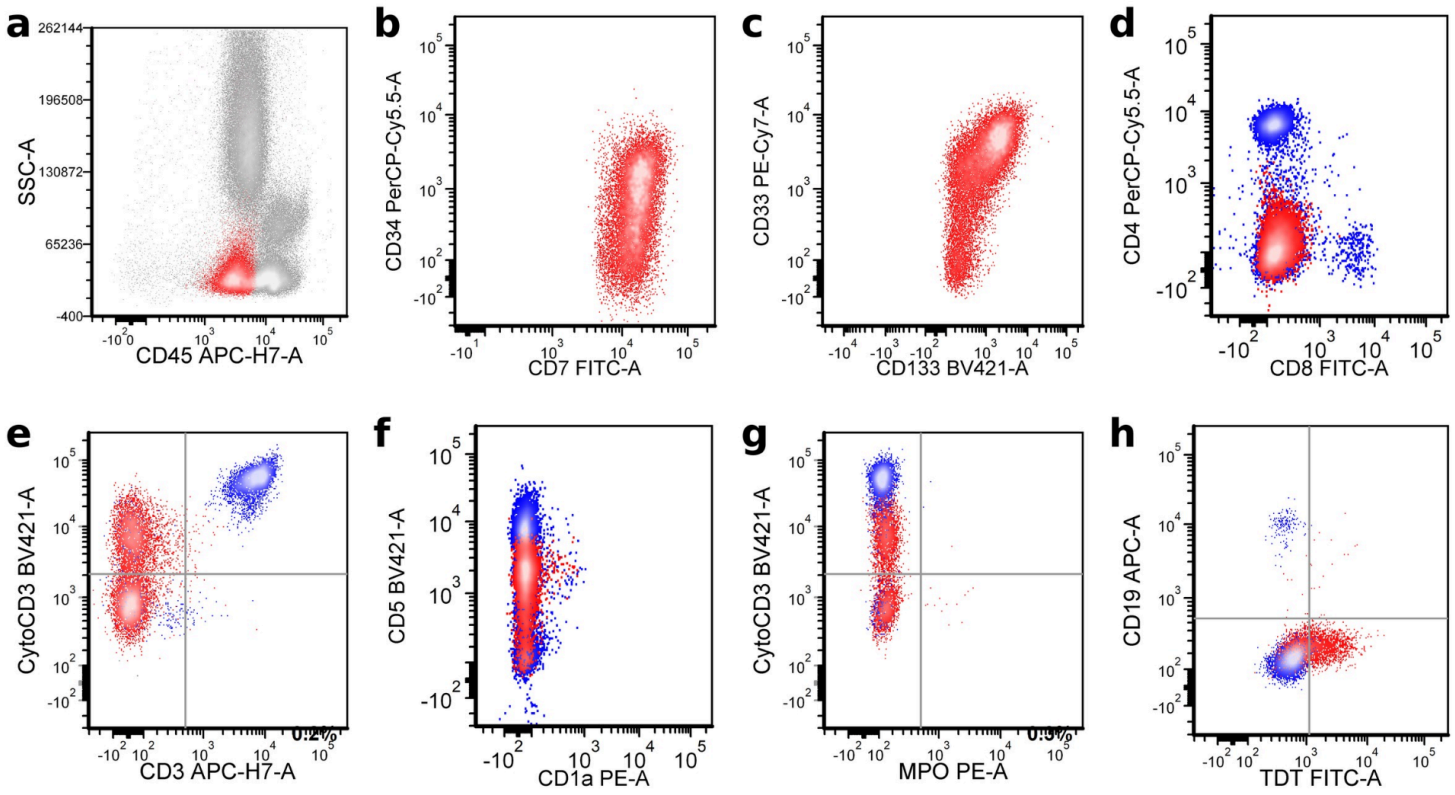

Figure 2

Flow cytometric immunophenotyping of the bone marrow aspirate. Blasts are shown in red and background lymphocytes in blue. **a** CD45 versus side scatter shows the CD45-dim blast population. **b** Blasts are CD7-positive with partial CD34 expression. **c** Blasts express CD33 and CD133. **d** Blasts are negative for CD4 and CD8. **e** Blasts are positive for cytoplasmic CD3 with variable intensity and are dim to negative for surface CD3. **f** Blasts are negative for CD1a and show partial, dim CD5 expression. **g** Blasts are negative for MPO. **h** Blasts are partially positive for TdT and negative for CD19

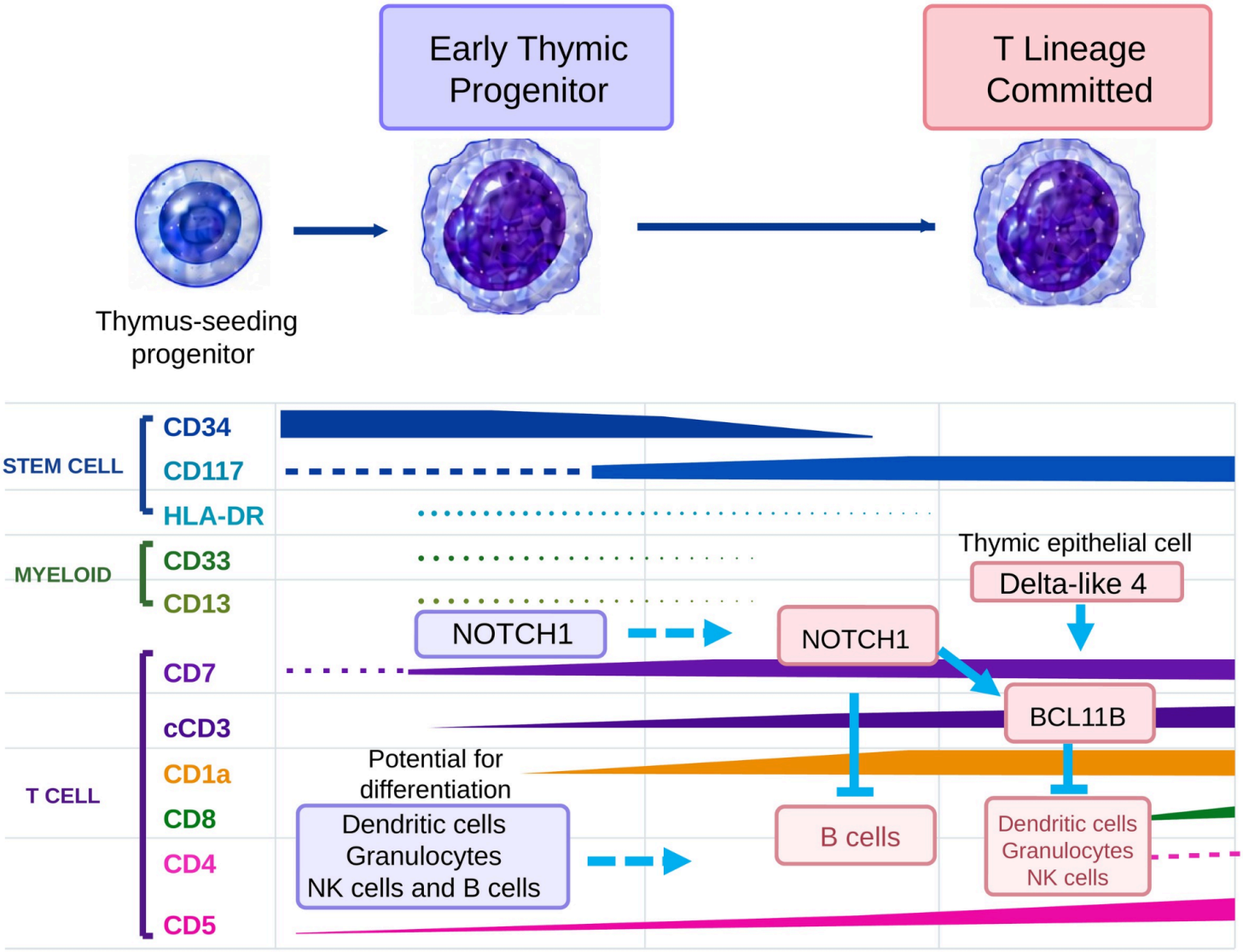

Figure 3

Normal human T-lineage maturation and the immunophenotype of early stages. After the common lymphoid progenitor leaves the marrow and seeds the thymus, it becomes the early thymic progenitor (ETP), which expresses CD7 and cytoplasmic CD3 and retains the potential for myeloid, dendritic cell, and natural killer cell differentiation. At this stage, ETP cells express the stem-cell markers CD34 and CD117, the myeloid-associated markers CD13 and CD33, and dim CD5. As CD34 and myeloid markers decline with maturation, cytoplasmic CD3+/CD7+ cells commit to the T-cell lineage, progressively acquire CD1a and CD4/CD8, and show brighter CD5. Engagement of NOTCH1 on early thymic progenitors by Delta-like 4 (DLL4) on thymic epithelial cells initiates the T-cell differentiation program and, together with other transcription factors, promotes BCL11B expression, which consolidates commitment to the T-cell lineage.