Research Square

Preprints are preliminary reports that have not undergone peer review.
They should not be considered conclusive, used to inform clinical practice,
or referenced by the media as validated information.

F18 FDG PET/CT and Urinary Bladder/Urothelial Carcinoma - Diagnostic Performance and Impact on Clinical Management: an Institutional Review

Zeeshan Sikandar

zeeshan.sikandar@skm.org.pk

SKMCH&RC: Shaukat Khanum Memorial Cancer Hospital and Research Centre https://orcid.org/0009-0009-9773-5735

Sana Munir Gill

Shaukat Khanum Memorial Cancer Hospital and Research Centre

Hajira Ilyas

Shaukat Khanum Memorial Cancer Hospital and Research Centre

Humayun Bashir

East Kent Hospitals NHS Trust: East Kent Hospitals University NHS Foundation Trust

Syed Abdul Mannan Hamdani

Shaukat Khanum Memorial Cancer Hospital and Research Centre

Khurram Mir

Shaukat Khanum Memorial Cancer Hospital and Research Centre

Research Article

Keywords: [¹⁸F] FDG PET/CT, Urothelial carcinoma, Bladder cancer, Disease staging, Treatment management, Overall survival

Posted Date: November 24th, 2026

DOI: https://doi.org/10.21203/rs.3.rs-11607829/v1

License: This work is licensed under a Creative Commons Attribution 4.0 International License.
Read Full License

Abstract

Purpose:

To evaluate the incremental value of [¹⁸F] FDG PET-CT over conventional imaging for staging and restaging urothelial carcinoma, its impact on clinical management, and its prognostic significance.

Methods:

This retrospective single-center study included 53 patients with histopathologically confirmed urothelial carcinoma who underwent [¹⁸F] FDG PET/CT between February 2011 and February 2026. PET-CT findings were compared with conventional imaging to assess changes in disease stage and clinical management. Overall survival (OS) and progression-free survival (PFS) were evaluated using Kaplan–Meier analysis.

Results:

The mean patient age was 60.8 years, and 94.4% had high-grade tumors. PET/CT was performed for restaging in 45 patients (85.0%) and initial staging in 8 (15.1%). Metabolically active disease was identified in 30 patients (56.6%). Compared with conventional imaging, PET/CT upstaged 9 patients (17.0%) and down staged 2 (3.7%). Management changed in 6 patients (11.3%): five were redirected to palliative systemic therapy, while one underwent potentially curative resection of a solitary FDG-avid lymph node. Among PET-positive patients, 14/30 (46.6%) died during follow-up, all with FDG-avid nodal or distant metastatic disease. Median OS was 94.0 months (95% CI, 58.0–not reached); estimated 3-year PFS and 5-year OS were 79% and 62.1%, respectively.

Conclusion:

18F-FDG PET/CT improves staging and restaging of urothelial carcinoma, resulting in clinically relevant changes in patient management. FDG-positive nodal or distant metastases are associated with poorer survival, supporting its prognostic value.

Introduction

Bladder cancer (BC) is the most common urothelial carcinoma (UC) and is the 4th most common tumor in men, along with upper urinary tract carcinoma which includes ureteral and renal pelvic tumors. These upper urinary tract tumors accounts for only 5–10% of urothelial carcinomas. Bladder carcinomas can be classified as muscle invasive bladder carcinomas (MIBC) and non-muscle invasive bladder carcinoma (NMIBC). In the recent years, bladder carcinoma has moved from 10th to be the 9th most common cancer world over with an increase in not only the incidence but also mortality rates (1).

Accurate staging and restaging of bladder carcinomas are important for adequate management. Radical cystectomy remains the standard treatment for localized muscle-invasive bladder cancer; however, being a major surgical procedure, it is associated with substantial perioperative morbidity and long-term effects on urinary, physical, and psychosocial functioning. Quality of life may remain significantly impaired because of urinary diversion and need for lifelong stoma or neobladder care. Therefore, careful preoperative staging is essential to ensure that patients most likely to benefit from radical surgery are appropriately selected while avoiding unnecessary cystectomy in patients with occult metastatic disease who are more likely to benefit from systemic therapy. Recent long-term quality-of-life data further emphasize the importance of appropriate patient selection before undertaking this life-changing procedure (2).

Recent advances in imaging have further improved the evaluation of bladder cancer. Multiparametric MRI with the Vesical Imaging-Reporting and Data System (VI-RADS) has become a valuable tool for standardized local staging and assessment of muscle invasion. In addition, alternative PET tracers such as ^{11}C-choline, ^{11}C-acetate, and ^{68}Ga-FAPI have been explored to overcome the limitation of physiological urinary FDG excretion. However, these tracers remain investigational or have limited availability, and [18F] FDG PET-CT continues to be the most widely used PET modality for staging and restaging urothelial carcinoma.

Recently increased interest has been in the utility of [18F] FDG PET-CT in the management of BC to rule out nodal or visceral metastases which can lead to change in management of these patients. Renee et al. in their study suggested that [18F] FDG PET-CT demonstrated high visualization rates of various histological subtypes of BC (3). [18F] FDG PET-CT provides not only anatomical but also metabolic information due to over expression of glucose transporters (GLUT-1 and GLUT-3) in these tumors (4).

Interest in using [18F] FDG PET-CT for staging and follow-up of bladder cancer patients has been steadily growing. This is largely because conventional radiological imaging often misses small metastatic lymph nodes as they rely mainly on size to identify disease, whereas [18F] FDG PET-CT detects the metabolic activity that truly reflects tumor presence. As a result, PET-CT can pick up disease that computed tomography (CT) and magnetic resonance imaging (MRI) might overlook, helping to reduce both under staging and over-staging (5).

Based on this growing evidence, major clinical guidelines have started to incorporate [18F] FDG PET-CT into the BC management algorithm in selected cases. National comprehensive cancer network (NCCN), recommend the use of CT and MRI in the staging workup of NMIBC. However, in MIBC, consideration of [18F] FDG PET-CT is suggested in selected patients with ≥cT2 disease, as it can help detect metastases and may alter treatment decisions, especially in ≥cT3 disease (category 2b recommendation). Also, it may guide the physician regarding the most favorable biopsy site (6). Similarly, guidelines from the European Association of Urology and the joint guideline by the American Urological Association, American Society of Clinical Oncology, American Society for Radiation Oncology, and Society of Urologic

Oncology recommend [18F] FDG PET-CT in selected patients particularly when conventional imaging is equivocal, metastasis is suspected or biopsy of a suspicious lesion is not feasible (7–10).

Although these major guidelines recognize the value of [18F] FDG PET-CT in limited situations, its role in the management of bladder carcinoma is still evolving. In our study we aim to explore the added value of [18F] FDG PET-CT in the staging and restaging of these tumors while exploring the impact on patient management.

Methodology

In this study, we retrospectively analyzed the data of 53 histopathologically confirmed urothelial carcinoma patients, who had [18F] FDG PET-CT scans from Feb, 2011 to Feb 2026. Study protocol was approved by Institutional Review Board (IRB) before the start of the study.

Inclusion criteria include all those patients with urothelial carcinoma who had at least one [18F] FDG PET-CT independent of the type of therapy and images from conventional studies (CECT, MRI etc.) and long term follow up clinical information after PET imaging. Patients with malignancies other than urothelial carcinoma were excluded.

Demographic data (include age and sex), clinical data (histopathology, grade of tumor, location of tumor i.e. upper urinary tract origin: pelvis, ureter or balder origin), baseline imaging and treatment type (chemotherapy, radiotherapy or surgery i.e. TURBT, nephroureterectomy or other conservative surgery), survival time and outcomes was reviewed.

Imaging method:

All patients fasted for 4–6 hours, having fasting blood glucose level of < 11.1 mmol/L according to the standard guidelines. All patients were instructed to avoid strenuous exercise, chewing or other muscular activity to minimize tracer uptake in the skeletal muscles. ^{18}F-FDG was injected intravenously (dose 0.10–0.14 mCi/kg). Post injection resting time was with an acceptable range of 55–75 minutes. CT scan (60–100 mA, 120 kV, 2.5 to 4 mm thickness) was performed before PET images. PET/CT acquisition was performed on Philips Ingenuity TF PET-CT 128 slice scanner. PET images were acquired with 3-D model acquisition (total 6–8 beds, 3 min per bed). Attenuation correction and anatomical correlation was based on low dose CT. PET and CT images were fused into transaxial, coronal and sagittal sections.

Image analysis:

[18F] FDG PET-CT images were independently reviewed by a consultant nuclear medicine physician and a consultant radiologist. Any discrepancies were resolved by consensus with a third senior consultant. Both qualitative and semi-quantitative analyses were performed. The maximum standardized uptake

value (SUVmax) of the most metabolically active lesion was recorded, and liver SUVmax was used as the reference baseline for assessing disease activity.

Treatment, management change and follow-up:

Treatment details, including surgery, intravesical bacillus Calmette–Guérin (BCG) therapy, chemotherapy, radiotherapy, and surveillance, were retrieved from the hospital information system (HIS). Comparative conventional radiological imaging studies (CT, MRI etc) were within 2–3 months of [18F] FDG PET-CT.

Change in the management were done in few patients after [18F] FDG PET-CT imaging i.e. change from local therapies (surgery or radiotherapy) to systemic therapy or from systemic therapy to palliation or surveillance.

Patients were followed according to standard follow up protocol. Clinical charts were used to trace follow-up data of selected patients. And date of last follow up were recorded to determine follow-up duration. Progression free survival (PFS) and overall survival (OS) were assessed from follow up record.

Statistical analysis:

Patient data were entered and analyzed by statistical package for the social sciences (SPSS version 27). Quantitative variables were presented as Mean ± SD while categorical variables (like sex) were presented as frequency and percentages. Progression free survival and over-all survival was analyzed by Kaplan–Meier method.

Results

A total of **53** patients were included in the study. The cohort comprised **46 males (86.7%)** and **7 females (13.3%)**, with an age range of **31–90 years** and a **mean** age of 60.8 years. Histopathological evaluation showed **high-grade urothelial carcinoma** in 50 patients (94.4%), while 3 patients (5.6%) had **low-grade urothelial carcinoma**. **MIBC** was present in 27 patients **(50.9%)**, whereas 26 patients **(49.1%)** had **NMIBC** as shown in Table 1.

The primary tumor site was the **urinary bladder** in 38 patients **(71.7%)**, while **upper urinary tract (UUT) involvement** (i.e. ureter or renal pelvis) was observed in **8 patients (15.1%)**. Both bladder and UUT involvement was present in **4 patients (7.6%)**, and **3 patients (5.6%)** had a second primary malignancy in addition to primary bladder carcinoma.

On baseline radiological imaging, **localized disease** was identified in **13 patients (24.5%)**, regional lymph node involvement in **23 patients (43.3%)**, and **metastatic disease** in **17 patients (32%)**. The most common metastatic site was **lymph nodes in 11 patients (20.7%)**, followed by **lung** in 9 patients **(16.9%)**, **liver** in 3 patients **(5.6%)**, and **bone** in 3 patients **(5.6%)**. Muscle and ovarian metastases were observed in one patient each.

Regarding treatment modalities, **22 patients (41.5%)** underwent **surgery followed by chemotherapy**, while **17 patients (32%)** received combined treatment with surgery, chemotherapy, and **radiotherapy**. Chemotherapy with intravesical Bacillus Calmette–Guérin **(BCG)** therapy was administered in **7 patients (13.2%)**. **Five patients (9.4%)** were placed on **post-surgical surveillance**, while **two patients (3.7%)** did not receive further treatment due to loss to follow-up.

[18F] FDG PET-CT was performed for **initial staging** in 8 patients **(15%)** and for **restaging** in 45 patients **(85%)**. PET-CT demonstrated **metabolically active disease** in 30 patients **(56.6%)**, including **23 patients (76.6%)** with **bladder carcinoma** and **7 patients (23.3%)** with upper urinary tract carcinoma or combined bladder and UUT involvement.

Compared with conventional imaging, **PET-CT** resulted in disease **upstaging** in 9 patients **(17%)**, while **downstaging** occurred in 2 patients (3.7%). Consequently, **treatment management was modified in 6 patients**, including five patients shifted to **palliative systemic therapy** and **one** patient undergoing curative **surgical resection** of a solitary FDG-avid lymph node.

Among the **30 PET-positive patients**, **14 patients (46.6%) died during follow-up**, all of whom had **FDG-avid nodal or distant metastatic disease**, indicating that the presence of FDG-positive lymph nodes or distant metastases was associated with poorer overall survival. In contrast, **four deaths** occurred in patients without FDG-avid disease during the course of their illness.

Kaplan–Meier survival analysis demonstrated a median overall survival of 94.0 months (95% CI: 58.0 – not reached) as shown in Fig. 1. The estimated **3-year progression-free survival (PFS) was approximately 79%**, while the **5-year overall survival (OS) was 62.1%**. These findings indicate favorable intermediate-term survival outcomes in our study cohort.

Table 1
Baseline Patient Characteristics (n = 53)

Variable	Values
Demographics	
Age (years); mean ± SD / Median (IQR)	60.8 ± 14.7 / 59 (52–72)
Gender; n (%)	
Male	46 (86.7%)
Female	7 (13.3%)
Histopathology; n (%)	
High Grade	50 (94.4%)
Low Grade	3 (5.6%)
Muscle-invasive disease (MIBC)	27 (50.9%)
Non-muscle-invasive disease (NMIBC)	26 (49.1%)
FDG PET/CT Findings	
Indication — Restaging	45 (85.0%)
Indication — Initial staging	8 (15.1%)
Upstaged by PET/CT	9 (17.0%)
Down stage by PET/CT	2 (3.7%)
Management changed after PET/CT	6 (11.3%)
Treatment Received	
Surgery performed	53 (100%)
Chemotherapy (any)	46 (86.7%)
Radiotherapy (any)	17 (32%)
Intravesical BCG	7 (13.2%)
Follow-up & Outcomes	
Alive at last follow-up	25 (47.2%)
Died (all-cause)	18 (34.0%)
Lost to follow-up	10 (18.9%)
Disease progression events	12 (22.6%)
Median OS, months	94.0 (95% CI: 58.0 – not reached)

IQR = interquartile range; MIBC = muscle-invasive bladder cancer; NMIBC = non-muscle-invasive bladder cancer; FDG = ¹⁸F-fluorodeoxyglucose; BCG = Bacillus Calmette–Guérin; OS = overall survival.

Discussion

Bladder cancer is currently the 9th most common cancer in the world. (1) It is estimated to represent 4% of all new cancers and 2.9% of cancer deaths in 2026 with a 5-syear relative survival of 79.1% (11).

The evaluation of primary bladder cancer lesions is mostly performed with direct visualization during cystoscopy followed by histopathological confirmation. Magnetic resonance imaging (MRI) has become an important part of the diagnostic pathway however in comparison the F18 FDG PET-CT usefulness in detecting localized disease remains limited mainly due to physiological urinary excretion of F 18 FDG. Although [18F] FDG PET-CT has an established role in the staging of solid cancers its role in management of urothelial cancers is yet to be defined. There has been an increased interest in the recent years assessing the impact of [18F] FDG PET-CT on the therapeutic management of urothelial cancer.

In our study we assessed the role of PET-CT in staging of UC patients, change in their management and also the prognostic significance of a positive PET-CT.

Our patients' demographic characteristics are comparable with available epidemiological data where urothelial carcinoma has been reported more commonly in older males (12). Our patient cohort had relatively aggressive tumor biology with most of them having high grade tumors and about half of them demonstrating muscle invasive disease (Table 1).

In most of our patients the primary tumor site was the urinary bladder with only a small proportion having upper urinary tract involvement. This is comparable to available data where bladder has been reported as the most common site of urothelial cancers, reported up to 50 times more common than the renal pelvis (13). A very small number of our patients had both bladder and upper urinary tract involved and a few had a second primary malignancy.

The principal clinical value of [18F] FDG PET-CT in our study extends beyond identifying additional metastatic lesions. Rather, its greatest contribution lies in improving patient selection for definitive treatment. Radical cystectomy remains the cornerstone of treatment for localized muscle-invasive bladder cancer but is associated with considerable morbidity and long-term effects on quality of life. This consideration may be even more relevant in resource-constrained healthcare settings such as Pakistan, where access to specialized postoperative rehabilitation, stoma care services, reconstructive support, and long-term survivorship programs remains limited. Consequently, avoiding unnecessary radical cystectomy through more accurate staging not only prevents surgical morbidity but may also reduce the substantial physical, psychological, and financial burden, imposed on patients and their families (14). Accurate preoperative staging with [18F] FDG PET-CT may therefore have greater clinical value in low- and middle-income countries than would be reflected by diagnostic accuracy alone.

Every effort should therefore be made to establish the true extent of disease before undertaking a cystectomy, though a life-altering procedure. In our cohort, [18F] FDG PET-CT upstaged 17% of patients and altered overall management in 11.3%, primarily by identifying previously unsuspected metastatic disease that redirected treatment from curative local therapy to systemic or palliative management. **Lijnen et al.** reported that the sensitivity of [18F] FDG PET-CT exceeded 80% in both bladder cancer and upper tract urothelial carcinoma. **Lijnen et al.** also demonstrated higher diagnostic accuracy of [18F] FDG PET-CT than conventional imaging in both bladder cancer (91% vs. 81%) and upper tract urothelial carcinoma (84% vs. 76%) (15). This is further supported by a meta-analysis by **Lu et all** which found the pooled sensitivity and specificity of [18F] FDG PET-CT for staging or restaging of bladder cancer as 82% and 89% respectively (16, 17), (19).

Presence of lymph node metastases is an important prognostic factor in upper tract urothelial carcinoma. Nodal metastases are common with about 60% in T3 and T 4 tumors and up to 30% in T2 tumors. We found a significant number of our patients had regional nodal (43%) or distant metastases (32%) at the time of baseline imaging highlighting the propensity of urothelial cancers for early dissemination. The most common site for metastatic disease was lymph nodes followed by lungs, bones and liver as shown in the Fig. 2. We also found muscle and ovarian metastases in one patient each. A study by **Voskuilen et al.** found [18F] FDG PET-CT to have sensitivity of 82% and specificity 84% in detection of lymph node metastases in UC patients (18). Similarly, **Goodfellow et al**. found in the 233 patients included in their study that PET/CT was able to detect metastatic disease outside the pelvis with a sensitivity of 54% compared to 41% for the staging CT in preoperative staging of bladder cancers (19, 20). **Aydh et al.** reported in a systematic review of 23 studies that, despite variability in sensitivity, [18F] FDG PET/CT demonstrated consistently high specificity for lymph node staging in urothelial carcinoma (21).

In our study we found that the PET-CT findings led to changes in treatment in a significant number of patients. We found it changed the management in 6 of our patients (11.3%), while five of the patients were shifted to palliative systemic therapy because of identification of advanced disease, one patient went on to have potentially curative surgical resection of a solitary FDG avid lymph node. This is in keeping with other recent studies revealing that PET-CT has the potential to influence management of patients with more accurate staging than the conventional imaging and helping to avoid unnecessary aggressive treatment. **Zattoni et al.** reported in a large multicenter retrospective study with 286 patients revealing a change in management in 114/286 patients (40%) in urothelial cancer patients with inclusion of [18F] FDG PET-CT especially in those with bladder cancer patients where this reached 74% (22). **Falińska et al.** concluded in a recent comprehensive review that despite limitations because of physiological urinary excretion, [18F] FDG PET-CT has significant clinical value in staging, prognostic assessment and response evaluation compared to conventional imaging (23).

A few other studies assessing the impact of [18F] FDG PET-CT on management change in urothelial malignancies also support our findings and report a significant role of PET in changing management of UC patients. **Apolo et al.** studied 57 patients in which 72% had a PET/CT during restaging and in 68%

patient's management was changed signifying role of FDG PET/CT in detection of recurrence and patient management (24).

Alongi et al. reported that **[18F]FDG PET/CT** changed patient management in 40% of the 41 patients included in their study (25).

Our study also highlights the prognostic significance of PET-CT in our patient cohort. Our study found 3 years PFS of 79% while 5 years OS was found to be 62.1%. Almost half of the patients with PET positive disease (46.6%) died during follow up period with all of them having metabolically active nodal or distant metastatic disease. In contrast, the patient group without FDG uptake had fewer deaths. These findings suggest that adverse outcomes are associated with metabolically active nodal and metastatic disease, which can be used as prognostic markers. **Pattou et al.** in their study found that all patients with persistent lymph node uptake on the [18F] FDG PET-CT 7 months after neoadjuvant chemotherapy experienced disease progression. They concluded that persistent metabolically active lymph nodes post chemotherapy in PET/CT is an independent adverse prognostic factor for disease free survival (26). **Drieskens et al**. in one of the earlier studies also revealed that patients with negative scans show a significantly longer median survival of 32 months with 13.5 months for PET positive patients emphasizing the prognostic value of PET-CT in staging muscle invasive and high-grade bladder carcinomas (27).

Limitations

The limitations of the study are that it was a single-center, retrospective study with a small patient sample, and the possibility of selection bias cannot be excluded.

Conclusion

F-18 FDG PET-CT provides incremental value over conventional imaging in the staging and restaging of urothelial carcinoma, by improving disease assessment, influencing treatment decisions, and facilitating more appropriate selection of patients for radical cystectomy. Identifying occult nodal and distant metastatic disease, may help avoid unnecessary radical surgery and its associated long-term morbidity while preserving quality of life. Furthermore, FDG-positive nodal or distant metastatic disease is associated with inferior survival outcomes, supporting the prognostic role of PET-CT in this patient population. Therefore, [18F] FDG PET-CT serves as an important imaging modality for both treatment planning and prognostic stratification in patients with urothelial carcinoma.

Declarations

No funding was received and there are no conflicts of interest

Consent to Participate

Because this was a retrospective analysis of existing data, the requirement for written informed consent was formally waived under our IRB exemption (Ref: **EX-21-05-26-01**).

Human Ethics and Consent to Participate Declarations:

This retrospective study received an exemption from the Institutional Review Board (IRB) of our hospital (Ref: **EX-21-05-26-01**).

2. Consent to Participate

Because this was a retrospective analysis of existing data, the requirement for written informed consent was formally waived under our IRB exemption (Ref: **EX-21-05-26-01**).

3. Citation(s) for Reference 17

We have reviewed the reference list and inserted the missing in-text citation for Reference 17 in the main text.

Data Availability

Declaration: The data set analyzed during the current study is not publicly available, but is available from the corresponding author on request.

References

1. Bray F, Laversanne M, Sung H, Ferlay J, Siegel RL, Soerjomataram I, Jemal A. Global cancer statistics 2022: GLOBOCAN estimates of incidence and mortality worldwide for 36 cancers in 185 countries. Cancer J Clin. 2024;74(3):229–63.
2. Akdemir E, Stuiver MM, van de Kamp MW, der Hulst JB-v, Mertens LS, Hendricksen K, van Harten WH, May AM, Sweegers MG. Long-term quality of life in patients with bladder cancer following radical cystectomy. BJU Int. 2025;135:675–83. https://doi.org/10.1111/bju.16610.
3. Lijnen RAG, Ringia JB, Claps F, Vogel WV, Boellaard TN, van Rhijn BWG, Braat AJAT, Mertens LS. Diagnostic Value of Fluorine-18-fluorodeoxyglucose Positron Emission Tomography/Computed Tomography in Staging Histological Subtypes of Invasive Bladder Cancer. Eur Urol Oncol. 2026;6:S2588. 9311(26)00046 – 5.
4. Szablewski L. Glucose transporters as markers of diagnosis and prognosis in cancer diseases. Oncol Rev. 2022;16(1):561.
5. Expert Panel on Urological Imaging, Barker SJ, Soylu E, Allen BC, Auron M, et al. ACR Appropriateness Criteria® Pretreatment Staging of Urothelial Cancer: 2024 Update. J Am Coll Radiol. 2024;21(11S):S464–89. 10.1016/j.jacr.2024.08.022.

6. Crozier J, Papa N, Perera M, Ngo B, Bolton D, Sengupta S, Lawrentschuk N. Comparative sensitivity and specificity of imaging modalities in staging bladder cancer prior to radical cystectomy: a systematic review and meta-analysis. World J Urol. 2019;37(4):667–90.
7. https:// (last accessed on 11-03-2026).
8. van der Heijden AG, Bruins HM, Carrion A, Cathomas R, Compérat E, Dimitropoulos K, et al. European Association of Urology Guidelines on Muscle-invasive and Metastatic Bladder Cancer: Summary of the 2025 Guidelines. Eur Urol. 2025;87(5):582–600.
9. Holzbeierlein J, Bixler BR, Buckley DI, Chang SS, Holmes RS, James AC et al. Treatment of Non-Metastatic Muscle-Invasive Bladder Cancer: AUA/ASCO/SUO Guideline (2017; Amended 2020, 2024). J Urol. 2024;212(1):3–10.
10. Witjes JA, Bruins HM, Cathomas R, Compérat EM, Cowan NC, Gakis G, et al. ESMO Clinical Practice Guideline for diagnosis, treatment and follow-up of bladder cancer. Ann Oncol. 2022;33(3):244–58.
11. Kohler J, Rodler S, Andersson J, Jüptner M, Lützen U, Both M, Nuhn P. Innovative imaging techniques for urothelial carcinoma. Urologie (Heidelberg, Germany). 2026Feb 4.
12. National cancer institute surveillance. epidemiology and end results program https://seer.cancer.gov/statfacts/html/urinb.html (last accessed on 06-07-2026).
13. https:// (last accessed on 06-07-2026).
14. Waqar U, Jaffar R, Rafique T, Madad S, Khan S, Ahmed L. Bladder Cancer in Pakistan Challenges in Early Diagnosis and Multidisciplinary Management. J Popul Ther Clin Pharmacol. 2024;31:1020–7. https://doi.org/10.53555/jptcp.v31i7.7186.
15. Leder R, Dunnick N. Transitional Cell Carcinoma of the Pelvicalices and Ureter. AJR Am J Roentgenol. 1990;155(4):713–22.
16. Sternberg CN. Perioperative chemotherapy in muscle-invasive bladder cancer to enhance survival and/or as a strategy for bladder preservation. Semin Oncol. 2007;34:122–8.
17. Lu YY, Chen JH, Liang JA, Wang HY, Lin CC, Lin WY, Kao CH. Clinical value of FDG PET or PET/CT in urinary bladder cancer: a systemic review and meta-analysis. Eur J Radiol. 2012;81(9):2411–6.
18. Vikram R, Sandler C, Ng C. Imaging and Staging of Transitional Cell Carcinoma: Part 1, Lower Urinary Tract. AJR Am J Roentgenol. 2009;192(6):1481–7.
19. Charlotte S, Voskuilen D, Schweitzer B, Jensen et al. Diagnostic Value of 18F-fluorodeoxyglucose Positron Emission Tomography with Computed Tomography for Lymph Node Staging in Patients with Upper Tract Urothelial Carcinoma,European Urology Oncology,Volume 3, Issue 1,2020,Pages 73–79,ISSN 2588–9311.
20. Goodfellow H, Viney Z, Hughes P, Rankin S, Rottenberg G, Hughes S, Evison F, Dasgupta P, O'Brien T, Khan MS. Role of fluorodeoxyglucose positron emission tomography (FDG PET)-computed tomography (CT) in the staging of bladder cancer. BJU Int. 2014;114(3):389–95.
21. Aydh A, Abufaraj M, Mori K, Quhal F, Pradere B, Motlagh RS, Mostafaei H, Karakiewicz PI, Shariat SF. Performance of fluoro-2-deoxy-D-glucose positron emission tomography-computed tomography

imaging for lymph node staging in bladder and upper tract urothelial carcinoma: a systematic review. Arab J Urol. 2020;19(1):59–66.

22. Zattoni F, Incerti E, Dal Moro F, Moschini M, Castellucci P, Panareo S, Picchio M, Fallanca F, Briganti A, Gallina A, Fanti S, Schiavina R, Brunocilla E, Rambaldi I, Lowe V, Karnes JR. Evangelista L. ^{18}F-FDG PET/CT and Urothelial Carcinoma: Impact on Management and Prognosis-A Multicenter Retrospective Study. Cancers (Basel). 2019;11(5):700.
23. Falińska H, Witkowska-Patena E, Krzyżanowska K, Dziuk M. Positron Emission Tomography/Computed Tomography in Bladder Cancer: The Role of [18F]FDG and Non-FDG Radiotracers. Medicina. 2026;62(4):703.
24. Apolo AB, Riches J, Schoder H, Akin O, Trout A, Milowsky MI, Bajorin DF. Clinical value of fluorine-18 2-fluoro-2-deoxy-D-glucose positron emission tomography/computed tomography in bladder cancer. J Clin Oncol. 2010;28:3973–8.
25. Alongi P, Caobelli F, Gentile R, Stefano A, Russo G, Albano D, Baldari S, Gilardi MC, Midiri M, Eur. J Nucl Med Mol Imaging. 2017;44:224–33.
26. Pattou M, Robert G, Gouhizoun O, Guéna F, Khaddad A, Mebroukine S, Margue G, Gross-Goupil M, Lefort F, Morgat C, Bernhard JC, Bladou F, Klein C. Persistent lymph node uptake on [18 F]-FDG PET-CT after neoadjuvant chemotherapy: a major predictive factor of disease-free survival in MIBC. World J Urol. 2026;44(1):77.
27. Drieskens O, Oyen R, Van Poppel H, et al. FDG-PET predicts survival in patients with muscle-invasive and high-grade bladder cancer. Eur J Nucl Med Mol Imaging. 2005;32(12):1412–7.

Figures

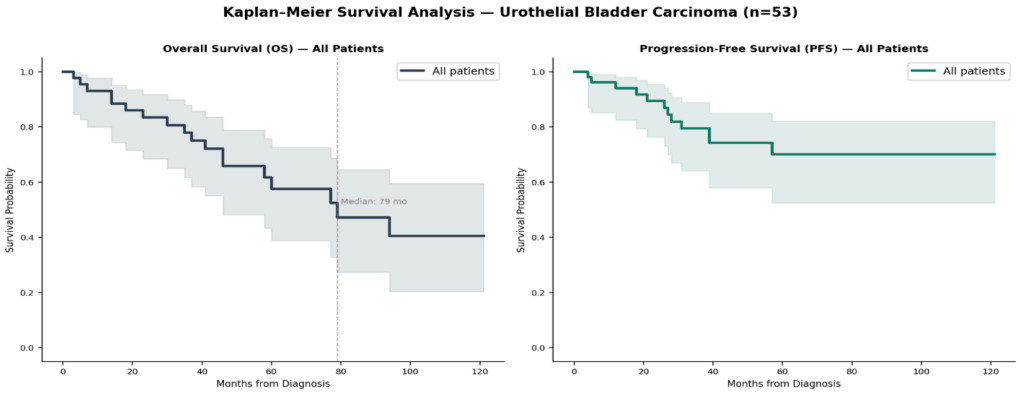

Figure 1:Displays Kaplan–Meier estimates of Overall Survival (OS, left panel) and Progression-Free Survival (PFS, right panel) for the entire cohort of 53 patients with urothelial carcinoma who underwent [18F] FDG PET-CT . median OS was 94.0 months (95% CI: 58.0 – not reached). A median PFS was not reached within the observation window, reflecting that the majority of patients (77.4%) remained free of documented disease progression at last follow-up.

Figure 1

See image above for figure legend

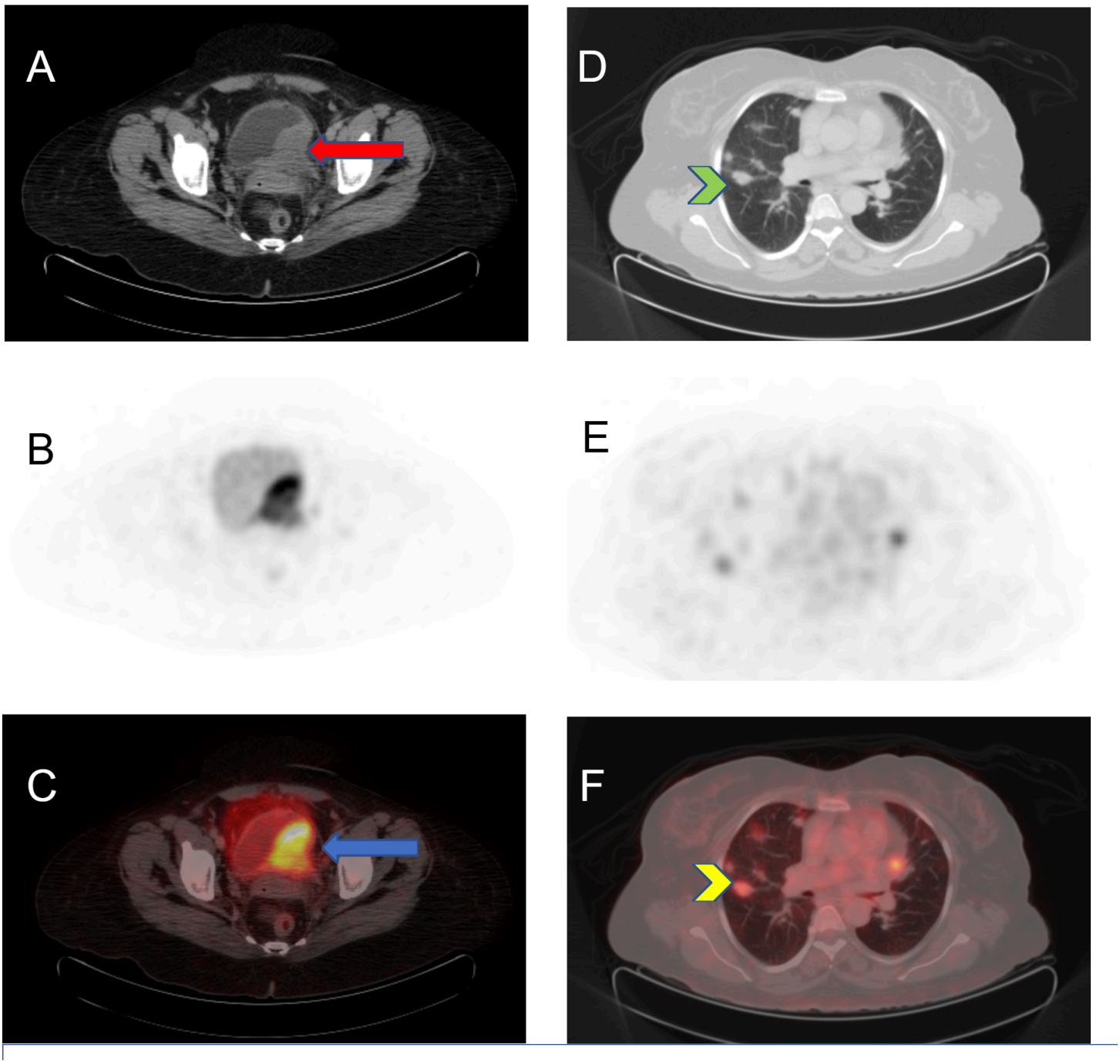

Figure 2

[52 years old female with invasive high-grade urothelial carcinoma. Baseline F18-FDG PET-CT shows hypermetabolic primary urinary bladder tumor involving the left lateral wall and distal left ureter as shown in figure A-C (A= CT image, B= PET only image, C = Fused image), along with avid pulmonary and mediastinal nodal metastases as shown in figure D-F, (D= CT image, E= PET only image, F = Fused image].