Research Square

Preprints are preliminary reports that have not undergone peer review.
They should not be considered conclusive, used to inform clinical practice,
or referenced by the media as validated information.

Feasibility and Mid-term Efficacy of Endovascular Repair of Acutely Ruptured Thoracic Aorta

Sandeep Sunder Amin
Klinikum Oldenburg AöR: Klinikum Oldenburg AoR
Osama Eldergash
Misurata University Faculty of Medicine
Martin Maurer
Klinikum Oldenburg AöR: Klinikum Oldenburg AoR
Matteo Haupt
Klinikum Oldenburg AöR: Klinikum Oldenburg AoR
Felix Fleissner
Klinikum Oldenburg AöR: Klinikum Oldenburg AoR
Andreas Martens
Klinikum Oldenburg AöR: Klinikum Oldenburg AoR
Rohit Philip Thomas
rohit0904@gmail.com

Klinikum Oldenburg AöR: Klinikum Oldenburg AoR https://orcid.org/0000-0002-1212-2764

Research Article

Keywords: endovascular management, acute aortic pathology, spinal ischaemia, aortic dissection

Posted Date: November 26th, 2026

DOI: https://doi.org/10.21203/rs.3.rs-11599276/v1

License: This work is licensed under a Creative Commons Attribution 4.0 International License.
Read Full License

Abstract

Purpose: To evaluate early and mid-term outcomes of emergency thoracic endovascular aortic repair (TEVAR) for thoracic acute aortic syndromes (AAS) complicated by rupture/impending rupture, with particular focus on neurological complications and associated risk factors.

Materials and Methods: Retrospective analysis of clinical data of 41 consecutive patients who underwent urgent TEVAR for thoracic AAS complicated by rupture/impending rupture between 2012 and 2022 was performed. Procedural characteristics, complications, neurological events, reinterventions, and survival outcomes were assessed.

Results: Technical success was achieved in all patients. Intra-/periprocedural or in-hospital mortality was 5/41 (12.2%). Neurological complications occurred in 4/41 (9.8%) of patients, including stroke in 3/41 (7.3%) and spinal cord ischaemia (SCI) in 2/41 (4.9%). Among 38 patients with assessable LSA status, neurological complications occurred in 3/15 patients with LSA coverage versus 1/23 without coverage (20.0% vs. 4.3%; p=0.280). SCI was observed exclusively type B dissection patients with retrograde type A involvement (2/4 vs. 0/37, p=0.003). Greater aortic coverage length was significantly associated with SCI (p=0.024). Renal function remained stable overall, although transient acute kidney injury occurred in 4/41 (9.8%) of patients. Mean intensive care unit stay was 6.6 days. One-year Kaplan–Meier overall survival was 65.2% (95% CI 48.4–77.7%), and reintervention was required in 2/41 patients (4.9%).

Conclusion: Emergency percutaneous TEVAR is an effective treatment option for thoracic AAS, with high technical success and acceptable early mortality. Neurological complications were infrequent overall but were numerically more frequent with LSA coverage, while SCI was associated with extensive aortic coverage and retrograde type A involvement.

Introduction

Acute aortic syndromes (AAS) require urgent diagnosis and treatment because early mortality is high [1], particularly in acute type A aortic dissection, where untreated mortality has historically been reported to increase by approximately 1–2% per hour [2–4]. Type A dissections are generally treated surgically, whereas uncomplicated type B dissections are managed medically [5–7]. Thoracic endovascular aortic repair (TEVAR) has become the preferred treatment for complicated type B dissections and other acute descending thoracic aortic pathologies, particularly in emergency settings [8–13].

Most available TEVAR outcome data are derived from elective or selected populations. Evidence regarding emergency TEVAR across heterogeneous acute thoracic aortic pathologies remains limited, particularly concerning neurological complications and their anatomical correlations. This study evaluated early and mid-term outcomes of emergency TEVAR for acute thoracic aortic syndromes complicated by rupture or impending rupture, with a particular focus on neurological complications and

associated procedural or anatomical factors, including left subclavian artery coverage, retrograde type A involvement, and the extent of aortic coverage.

Materials and Methods

This retrospective observational study included consecutive adult patients who underwent urgent TEVAR for acute aortic syndromes between 1 January 2012 and 31 December 2022 at a single tertiary care centre. Acute aortic syndromes included aortic dissection, intramural haematoma, and penetrating aortic ulcer complicated by rupture, impending rupture, fistula formation, or aortic arch involvement. Representative CTA findings are shown in Fig. 1. Patients undergoing elective TEVAR or open surgical repair were excluded. Institutional review board approval was obtained, and written informed consent was waived because of the retrospective design and emergency setting.

Procedural details

All procedures were performed under general anaesthesia in the angiography suite or a hybrid operating room with cardiac surgical backup. Vascular access was predominantly percutaneous via the common femoral artery using suture-mediated closure devices; surgical cutdown was used when vascular anatomy was unsuitable for percutaneous access. After angiographic confirmation of the pathology, a thoracic stent graft was deployed to exclude the rupture site or entry tear. A representative angiographic example is shown in Fig. 2.

Proximal extension with left subclavian artery (LSA) coverage was accepted when required for an adequate seal. When LSA coverage was anticipated, preservation of LSA perfusion was assessed by the interdisciplinary aortic team. In haemodynamically stable patients with contained rupture and suitable anatomy, staged carotid-subclavian or supra-aortic revascularization was performed. In active rupture, profound haemodynamic instability, or malperfusion, immediate endovascular exclusion was prioritized. In-situ fenestration, thoracic branched endografts, and physician-modified endografts were not used in this cohort because these techniques were not routinely available for emergency use during the early study period.

Postoperative management and follow-up

Serial neurological examinations were performed for early detection of neurological deficits. Contrast-enhanced CTA was obtained within 30 days and subsequently at 6 months, 12 months, and annually, or earlier if clinically indicated. Renal function was monitored using serum creatinine; acute kidney injury was defined according to KDIGO criteria as an increase in serum creatinine ≥ 0.3 mg/dL [14].

The primary endpoints were technical success, neurological complications including stroke and spinal cord ischaemia, and in-hospital/30-day mortality. Secondary endpoints included acute kidney injury, access-related complications, reintervention, and mid-term survival.

Statistical analysis

Statistical analysis was performed using SPSS version 23 (IBM Corp., Armonk, NY, USA). Continuous variables were summarized as mean ± standard deviation or median and range, as appropriate, and categorical variables as frequencies and percentages. Owing to the small cell counts, all neurological 2×2 subgroup comparisons were performed using two-sided Fisher's exact tests. Continuous variables were compared using the Mann–Whitney U test.

Overall survival was assessed using Kaplan–Meier analysis, with TEVAR as time zero and all-cause death as the event. Patients known to be alive at the end of the observation period were administratively censored on 31 December 2022; one patient lost to follow-up was censored at the last known date alive. All 41 patients were included in the survival analysis. LSA comparisons were restricted to the 38 patients with assessable LSA status; three patients who died perioperatively were excluded from these analyses. Given the small number of neurological events, subgroup analyses were considered exploratory. A two-sided p value < 0.05 was considered statistically significant.

Results

A total of 41 patients underwent emergency TEVAR for acute thoracic aortic pathologies. Mean age was 76.6 years (range 54–99 years); 27/41 (65.9%) were male and 14/41 (34.1%) female. The most frequent indications were ruptured thoracic aneurysm (16/41, 39.0%), type B dissection with contained rupture (7/41, 17.1%), type B dissection with frank rupture (4/41, 9.8%), type B dissection with retrograde type A involvement (4/41, 9.8%), and complicated intramural haematoma (4/41, 9.8%) (Table 1).

Technical success was achieved in 41/41 procedures (100%). Percutaneous femoral access was used in 34/41 patients (82.9%) and surgical cutdown in 7/41 (17.1%). LSA coverage was required in 15/41 patients (36.6%), including complete coverage in 11/41 (26.8%) and partial coverage in 4/41 (9.8%). Two patients with contained distal arch aneurysm underwent staged supra-aortic revascularization before complete LSA coverage. Neither developed stroke or spinal cord ischaemia; one subsequently developed asymptomatic subclavian bypass occlusion managed conservatively. Mean aortic coverage length was 243.5 ± 89.2 mm (median 200 mm; range 150–428 mm), and mean ICU stay was 6.6 days (range 1–27 days) (Table 2).

Neurological complications occurred in 4/41 patients (9.8%): stroke in 3/41 (7.3%) and spinal cord ischaemia (SCI) in 2/41 (4.9%), with one patient experiencing both. Of the four affected patients, two had partial LSA coverage, one complete coverage, and one no LSA coverage. Neurological deficits were apparent immediately after extubation or within 24 hours in all four patients and were confirmed by imaging; no delayed neurological deficits occurred during the remaining in-hospital/30-day period.

Among the 38 patients with assessable LSA status, neurological complications occurred in 3/15 patients with LSA coverage versus 1/23 without coverage (20.0% vs. 4.3%; two-sided Fisher's exact

p=0.280). These findings are illustrated in Figure 3. Stroke occurred in 2/15 versus 1/23 patients (13.3% vs. 4.3%; p=0.550), and SCI in 1/15 versus 1/23 patients (6.7% vs. 4.3%; p=1.000) (Table 3).

SCI occurred exclusively in patients with type B dissection and retrograde type A extension (2/4, 50.0% vs. 0/37, 0%; p=0.003). Given the small number of events, this association was considered exploratory. Coverage length was also significantly greater in patients with SCI (p=0.024; Table 3, Figure 4).

Mean serum creatinine remained stable (0.98 mg/dL preoperatively vs. 1.0 mg/dL postoperatively). Acute kidney injury occurred in 4/41 patients (9.8%) and was transient in all. Femoral access-related complications occurred in 9/41 patients (22.0%), including pseudoaneurysm in 7/41 (17.1%) and haemorrhage in 2/41 (4.9%).

In-hospital/30-day mortality was 5/41 (12.2%). Kaplan–Meier analysis included all 41 patients. Dedicated imaging follow-up was available in 28 patients, whereas survival status was available for the entire cohort except one patient lost to follow-up. Overall, 17 deaths occurred during the observation period, including 14 within the first year after TEVAR. Kaplan–Meier overall survival was 87.8% at 30 days, 75.3% at 3 months, 70.2% at 6 months, 65.2% at 1 year (95% CI 48.4–77.7%), and 59.3% at 2 years. Survival declined predominantly during the early post-procedural period and subsequently stabilised during mid-term follow-up (Figure 5, Table 4).

Discussion

Emergency TEVAR provided effective haemorrhage control with acceptable early mortality in this elderly, high-risk cohort. Neurological complications occurred in 4/41 patients (9.8%) and were numerically more frequent among patients requiring LSA coverage, although this association was not statistically significant. SCI occurred only in patients with type B dissection and retrograde type A involvement and was associated with greater aortic coverage length. Re-intervention was uncommon during follow-up.

The present cohort partially overlaps with an earlier single-centre series from our institution of 22 patients with non-traumatic descending thoracic aortic rupture treated between 2011 and 2017 [15]. The current study extends that experience through broader inclusion of acute thoracic aortic syndromes, longer recruitment and follow-up, and additional analyses of neurological complications, LSA management, aortic coverage length, retrograde type A involvement, and actuarial survival.

Compared with historical open surgical repair, which has been associated with higher perioperative mortality, including 33% versus 19% for endovascular repair in a meta-analysis of ruptured descending thoracic aneurysms [16], the 5/41 (12.2%) early mortality observed in our cohort supports TEVAR as an important emergency treatment option in selected patients.

Neurological injury remains a major concern after TEVAR. In our cohort, neurological complications occurred in 3/15 patients with LSA coverage compared with 1/23 without coverage (20.0% vs. 4.3%; p = 0.280). Given the small number of events, this difference does not establish a causal association.

Nevertheless, the observed event rate among patients requiring LSA coverage supports careful evaluation of LSA preservation whenever feasible. The LSA contributes to vertebrobasilar and spinal collateral perfusion, and its exclusion may reduce perfusion reserve, particularly in haemodynamically unstable patients [17–19].

In elective TEVAR, anticipated LSA coverage may be accompanied by carotid-subclavian bypass or subclavian transposition. In emergency settings, however, the benefit of preserving LSA flow must be balanced against the need for rapid haemorrhage control and the additional procedural burden of revascularization. Two haemodynamically stable patients in our cohort with contained distal arch rupture underwent staged supra-aortic revascularization before complete LSA coverage; neither developed stroke or SCI. These findings illustrate that revascularization can be feasible in selected emergency patients. More recently, thoracic branched endografts, in-situ fenestration, and physician-modified endografts have expanded options for preserving LSA perfusion, although their use in emergencies depends on anatomy, device availability, and operator expertise [20–22]. An illustrative post-study example is shown in Fig. 6.

SCI was observed in 2/4 patients with type B dissection and retrograde type A involvement compared with 0/37 patients with other pathologies ($p = 0.003$). Because of the fact that only two SCI events occurred, this finding should be considered exploratory and hypothesis-generating. Retrograde type A extension may represent a more extensive dissection phenotype with greater compromise of branch vessels and collateral pathways relevant to spinal cord perfusion. In addition, longer thoracic aortic coverage reduces intercostal inflow and increases dependence on residual collateral circulation. This is consistent with evidence that extensive descending thoracic aortic coverage is associated with increased SCI risk [9, 23–27]. The significant association between coverage length and SCI in our cohort ($p = 0.024$) therefore likely reflects the interaction between dissection extent, aortic coverage, and individual collateral anatomy rather than one isolated factor.

The high early mortality observed in this cohort likely reflects the severity of presentation rather than technical failure of TEVAR. Patients requiring emergency treatment for rupture or impending rupture frequently present with acute haemodynamic instability, haemorrhagic shock, or organ malperfusion have little opportunity for preoperative optimization. These factors are well-recognized predictors of poor outcome in acute thoracic aortic disease. Because of the retrospective design and limited sample size, the individual contribution of presentation severity, underlying pathology, and changes in management over the 2012–2022 study period cannot be reliably determined. Early mortality should therefore be interpreted in the context of the underlying disease severity and urgency of treatment.

During mid-term follow-up, mortality was predominantly related to non-aortic causes and comorbidities rather than failure of the aortic repair, consistent with previous long-term studies of acute aortic syndromes [28, 29]. Nevertheless, delayed aortic complications remain possible and support continued surveillance imaging [30].

Several limitations should be acknowledged. This was a retrospective, single-centre study with a small and heterogeneous population, and secondary interventions may have been underutilized. Long-term imaging follow-up was incomplete in some patients because of mortality, mobility limitations, and comorbidities. Systematic assessment of Circle of Willis integrity and vertebral artery dominance was not performed because emergency imaging was directed primarily at rapid aortic assessment and treatment planning; their potential contribution to neurological risk could therefore not be evaluated.

Conclusion

Emergency TEVAR achieved high technical success with acceptable early mortality in this high-risk cohort. Neurological complications were infrequent overall but more frequent in patients requiring LSA coverage, while SCI occurred only in patients with retrograde type A involvement and was associated with greater aortic coverage. These findings are exploratory and require confirmation in larger cohorts. Systematic evaluation of LSA preservation should be considered whenever clinically and anatomically feasible.

References

1. Bossone E, LaBounty TM, Eagle KA (2018) Acute aortic syndromes: diagnosis and management, an update. Eur Heart J 39(9):739–749. https://doi.org/10.1093/eurheartj/ehx319
2. Smedberg C, Hultgren R, Olsson C, Steuer J (2024) Incidence, presentation and outcome of acute aortic dissection: results from a population-based study. Open Heart 11(1):e002595. https://doi.org/10.1136/openhrt-2023-002595
3. Xu W, Haran C, Dean A, Lim E, Bernau O, Mani K et al (2023) Acute aortic syndrome: nationwide study of epidemiology, management, and outcomes. Br J Surg 110(9):1197–1205. https://doi.org/10.1093/bjs/znad162
4. Harris KM, Nienaber CA, Peterson MD, Woznicki EM, Braverman AC, Trimarchi S et al (2022) Early mortality in type A acute aortic dissection: insights from the International Registry of Acute Aortic Dissection. JAMA Cardiol 7(10):1009–1015. https://doi.org/10.1001/jamacardio.2022.2718
5. Harris C, Croce B, Cao C (2016) Type A aortic dissection. Ann Cardiothorac Surg 5(3):256. https://doi.org/10.21037/acs.2016.05.04
6. Wheat MW Jr, Palmer RF, Bartley TD, Seelman RC (1965) Treatment of dissecting aneurysms of the aorta without surgery. J Thorac Cardiovasc Surg 50:364–373. https://doi.org/10.1016/S0022-5223(19)33192-7
7. Umaña JP, Lai DT, Mitchell RS, Moore KA, Rodriguez F, Robbins RC et al (2002) Is medical therapy still the optimal treatment strategy for patients with acute type B aortic dissections? J Thorac Cardiovasc Surg 124(5):896–910. https://doi.org/10.1067/mtc.2002.123131
8. Iannacone E, Girardi L (2018) Thoracic endovascular aortic repair (TEVAR) versus open versus medical management of type B dissection. J Vis Surg 4:8. https://doi.org/10.21037/jovs.2017.12.19

9. Isselbacher EM, Preventza O, Black JH 3rd, Augoustides JG, Beck AW, Bolen MA et al (2022) 2022 ACC/AHA guideline for the diagnosis and management of aortic disease: a report of the American Heart Association/American College of Cardiology Joint Committee on Clinical Practice Guidelines. Circulation 146(24):e334–e482. https://doi.org/10.1161/CIR.0000000000001106
10. Lau C, Leonard JR, Iannacone E, Gaudino M, Girardi LN (2019) Surgery for acute presentation of thoracoabdominal aortic disease. Semin Thorac Cardiovasc Surg 31(1):11–16. https://doi.org/10.1053/j.semtcvs.2018.07.018
11. Mkalaluh S, Szczechowicz M, Dib B, Weymann A, Szabo G, Karck M (2018) Open surgical thoracoabdominal aortic aneurysm repair: the Heidelberg experience. J Thorac Cardiovasc Surg 156(6):2067–2073. https://doi.org/10.1016/j.jtcvs.2018.05.081
12. Sörelius K, Wanhainen A (2018) Challenging current conservative management of uncomplicated acute type B aortic dissections. EJVES Short Rep 39:37–39. https://doi.org/10.1016/j.ejvssr.2018.05.010
13. Khawar M, Ali U, Rasheed MA, Rasheed AB, Shah SA, Zain S et al (2025) Thoracic endovascular vs open surgical repair in descending thoracic aortic aneurysms: a systematic review and meta-analysis. World J Cardiol 17(10):110962. https://doi.org/10.4330/wjc.v17.i10.110962
14. Kellum JA (2015) Diagnostic criteria for acute kidney injury: present and future. Crit Care Clin 31(4):621–632. https://doi.org/10.1016/j.ccc.2015.06.001
15. Thomas RP, Amin SS, Eldergash O, Kowald T, Bremer S, Easo J et al (2018) Urgent endovascular treatment for non-traumatic descending thoracic aortic rupture. Cardiovasc Intervent Radiol 41(9):1318–1323. https://doi.org/10.1007/s00270-018-2006-0
16. Jonker FHW, Trimarchi S, Verhagen HJM, Moll FL, Sumpio BE, Muhs BE (2010) Meta-analysis of open versus endovascular repair for ruptured descending thoracic aortic aneurysm. J Vasc Surg 51(4):1026–1032e2. https://doi.org/10.1016/j.jvs.2009.10.103
17. Huang Q, Chen XM, Yang H, Lin QN, Qin X (2018) Effect of left subclavian artery revascularisation in thoracic endovascular aortic repair: a systematic review and meta-analysis. Eur J Vasc Endovasc Surg 56(5):644–651. https://doi.org/10.1016/j.ejvs.2018.07.018
18. Cooper DG, Walsh SR, Sadat U, Noorani A, Hayes PD, Boyle JR (2009) Neurological complications after left subclavian artery coverage during thoracic endovascular aortic repair: a systematic review and meta-analysis. J Vasc Surg 49(6):1594–1601. https://doi.org/10.1016/j.jvs.2008.12.075
19. Potter HA, Ding L, Han SM, Fleischman F, Weaver FA, Magee GA (2024) Spinal cord ischemia and reinterventions following thoracic endovascular repair for acute type B aortic dissections. J Vasc Surg 80(3):656–664. https://doi.org/10.1016/j.jvs.2024.03.458
20. Hajibandeh S, Hajibandeh S, Antoniou SA, Torella F, Antoniou GA (2016) Revascularisation of the left subclavian artery for thoracic endovascular aortic repair. Cochrane Database Syst Rev 4:CD011738. https://doi.org/10.1002/14651858.CD011738.pub2
21. Mei F, Sun J, Wang K, Guan W, Huang M, Fan J et al (2023) Physician-modified endovascular graft for left subclavian artery fenestration during thoracic endovascular aortic repair. Ann Vasc Surg

95:14–22. https://doi.org/10.1016/j.avsg.2023.04.014

22. Bontinis V, Bontinis A, Chorti A, Schoretsanitis N, Giannopoulos A, Ktenidis K (2023) Single branched endografts for the preservation of left subclavian artery in the treatment of zone II thoracic aortic lesions: a systematic review and meta-analysis. Ann Vasc Surg 94:396–406. https://doi.org/10.1016/j.avsg.2023.04.019
23. Alzghari T, An KR, Harik L, Rahouma M, Dimagli A, Perezgorvas-Olaria R et al (2023) Spinal cord injury after open and endovascular repair of descending thoracic aneurysm and thoracoabdominal aortic aneurysm: an updated systematic review and meta-analysis. Ann Cardiothorac Surg 12(5):409–417. https://doi.org/10.21037/acs-2023-scp-14
24. Li HL, Wu S, Chan YC, Cheng SW, Guo W, Xiong J (2020) Early and mid-term mortality and morbidity of contemporary international endovascular treatment for type B aortic dissection: a systematic review and meta-analysis. Int J Cardiol 301:56–61. https://doi.org/10.1016/j.ijcard.2019.09.071
25. Kamman AV, de Beaufort HWL, van Bogerijen GHW, Nauta FJH, Heijmen RH, Moll FL et al (2016) Contemporary management strategies for chronic type B aortic dissections: a systematic review. PLoS ONE 11(5):e0154930. https://doi.org/10.1371/journal.pone.0154930
26. Zeldich D, Bierowski M, Shabo L, Yaddanapudi S, Marhefka G (2025) Neurovascular complications of acute aortic syndrome. J Stroke 27(1):19–29. https://doi.org/10.5853/jos.2024.02915
27. Mylonas SN, Mammadov R, Dorweiler B (2024) Complementary thoracic endovascular aortic repair after frozen elephant trunk for residual type A aortic dissection: perioperative and mid-term outcomes. J Clin Med 13(10):3007. https://doi.org/10.3390/jcm13103007
28. Corsini A, Pacini D, Lovato L, Russo V, Lorenzini M, Foà A et al (2018) Long-term follow-up of patients with acute aortic syndromes: relevance of both aortic and non-aortic events. Eur J Vasc Endovasc Surg 56(2):200–208. https://doi.org/10.1016/j.ejvs.2018.03.030
29. Tan MES, Morshuis WJ, Dossche KME, Kelder JC, Waanders FGJ, Schepens MAAM (2005) Long-term results after 27 years of surgical treatment of acute type A aortic dissection. Ann Thorac Surg 80(2):523–529. https://doi.org/10.1016/j.athoracsur.2005.02.059
30. Vilacosta I, San Román JA, di Bartolomeo R, Eagle K, Estrera AL, Ferrera C et al (2021) Acute aortic syndrome revisited: JACC state-of-the-art review. J Am Coll Cardiol 78(21):2106–2125. https://doi.org/10.1016/j.jacc.2021.09.022

Tables

Tables 1 to 4 are available in the Supplementary Files section.

Figures

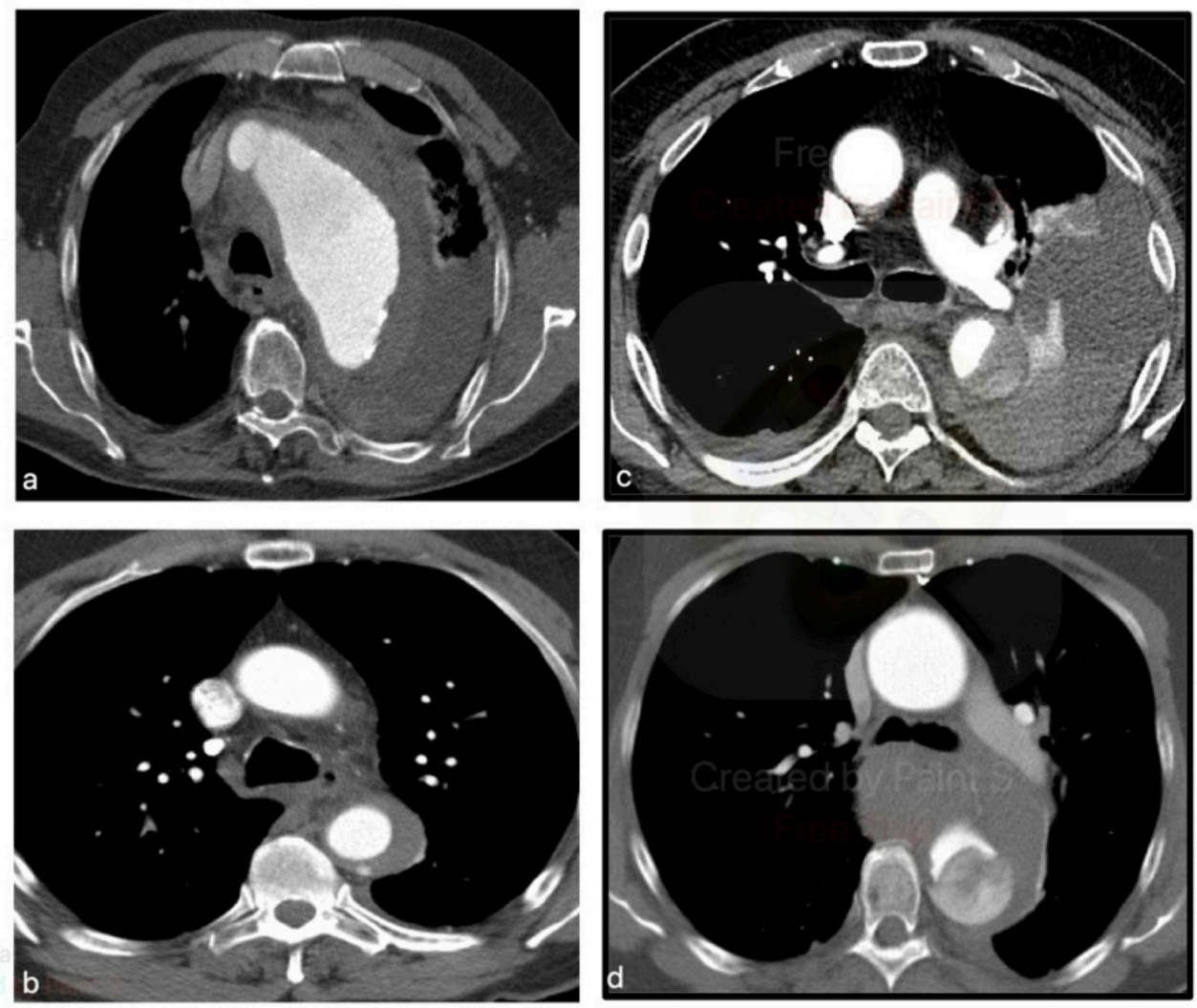

Figure 1

CTA examples of acute thoracic aortic pathology: (a) ruptured thoracic aneurysm; (b) symptomatic intramural haematoma; (c) ruptured type B aortic dissection with haemothorax; (d) ruptured aortic dissection with mediastinal haematoma and acute aortobronchial fistula.

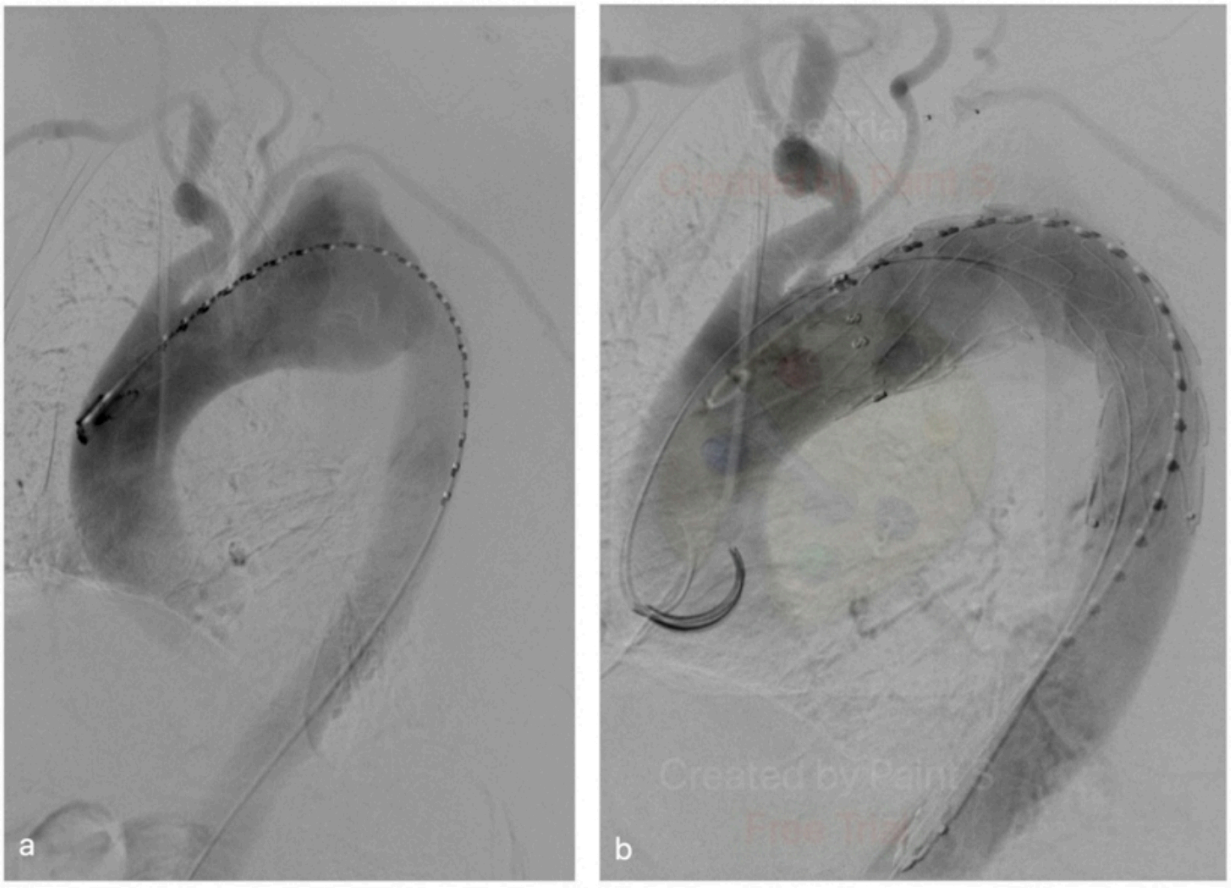

Figure 2

Digital subtraction angiography (DSA) of the same patient shown in Figure 1a. (a) Ruptured thoracic aneurysm adjacent to the origin of the left subclavian artery. (b) Final DSA after embolisation and complete coverage of the left subclavian artery origin to achieve an adequate proximal seal, with retrograde filling of the left vertebral artery.

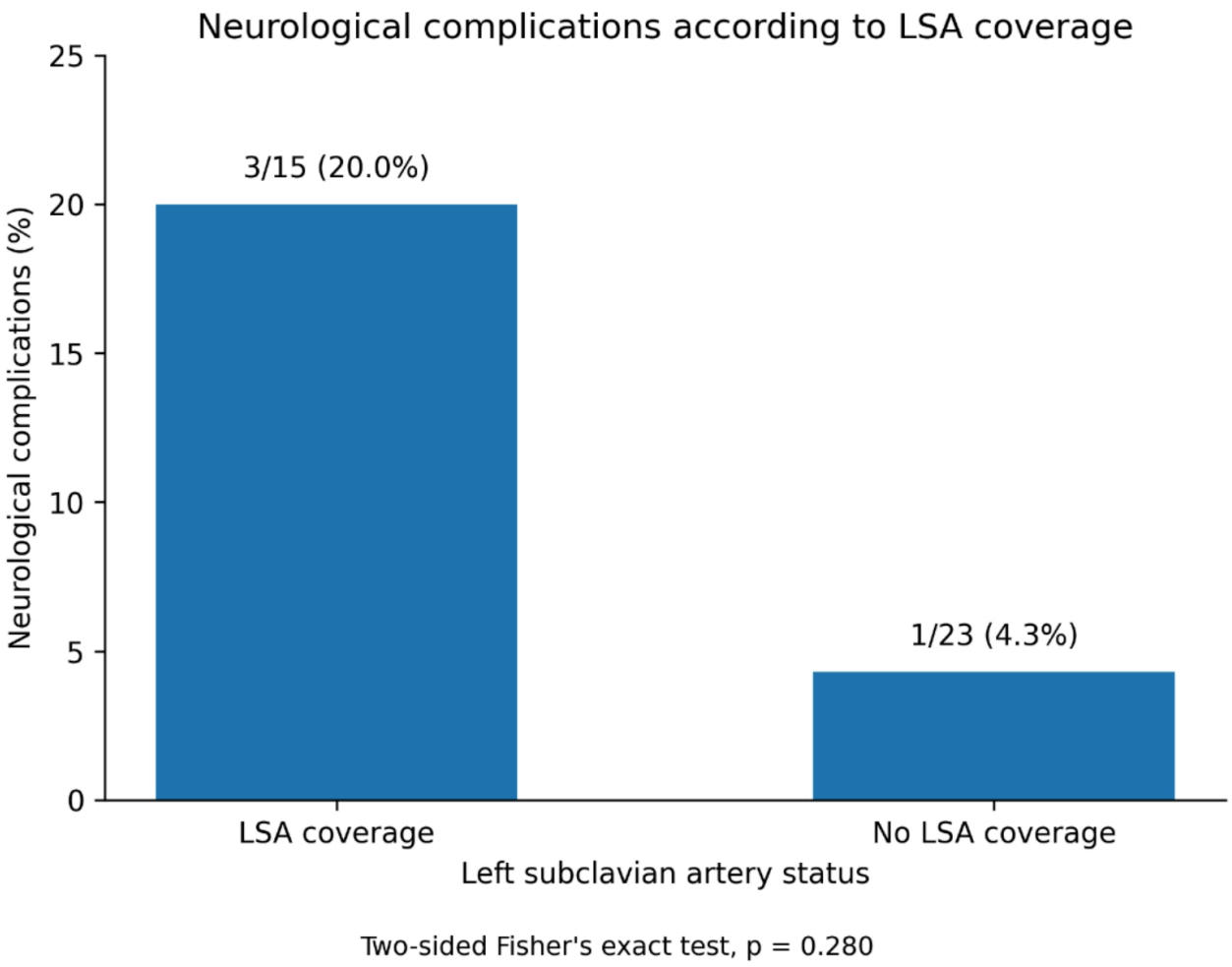

Figure 3

Neurological complications according to left subclavian artery coverage. Neurological complications occurred in 3/15 patients with partial or complete LSA coverage and in 1/23 patients without LSA coverage (20.0% vs 4.3%; two-sided Fisher’s exact p=0.280).

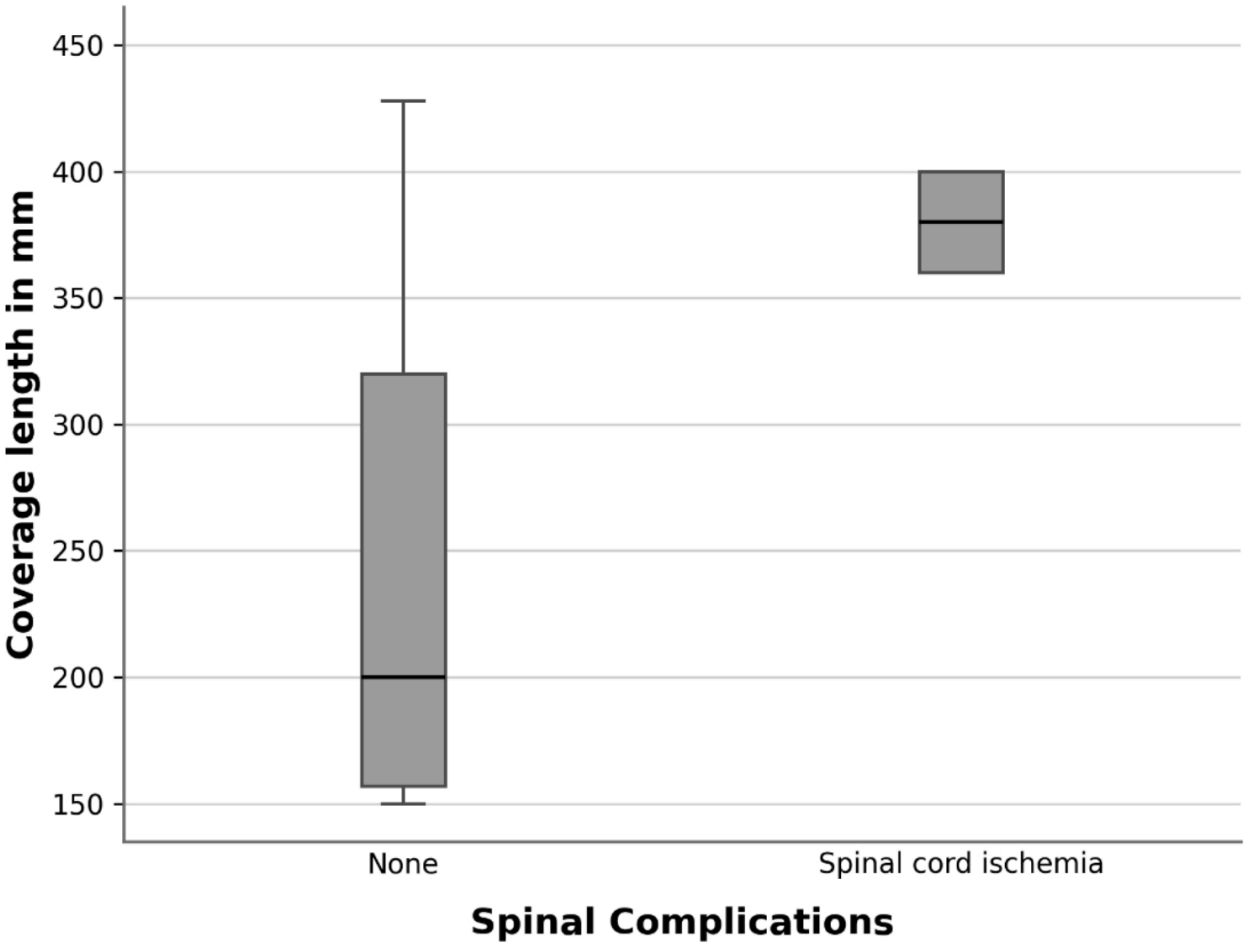

Figure 4

Aortic coverage length in patients with and without spinal cord ischaemia. The two patients with SCI had coverage lengths of 400 mm and 360 mm, compared with a median of 200 mm (range 150–428 mm) in patients without SCI; exact Mann–Whitney U p=0.024.

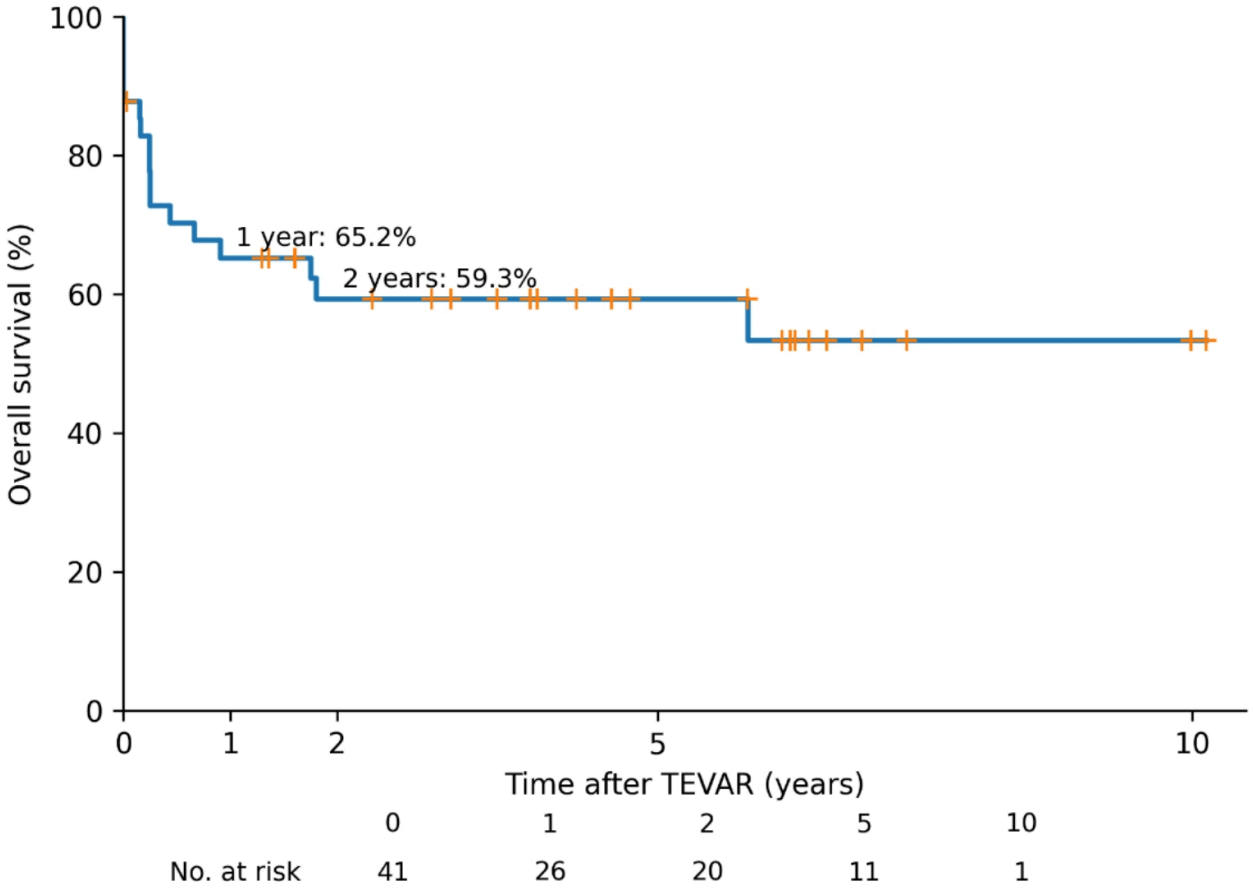

Figure 5

Kaplan–Meier overall survival after emergency TEVAR. Survival was 87.8% at 30 days, 75.3% at 3 months, 70.2% at 6 months, 65.2% at 1 year, and 59.3% at 2 years. The greatest decline occurred during the early post-procedural period, followed by relative stabilization during mid-term follow-up.

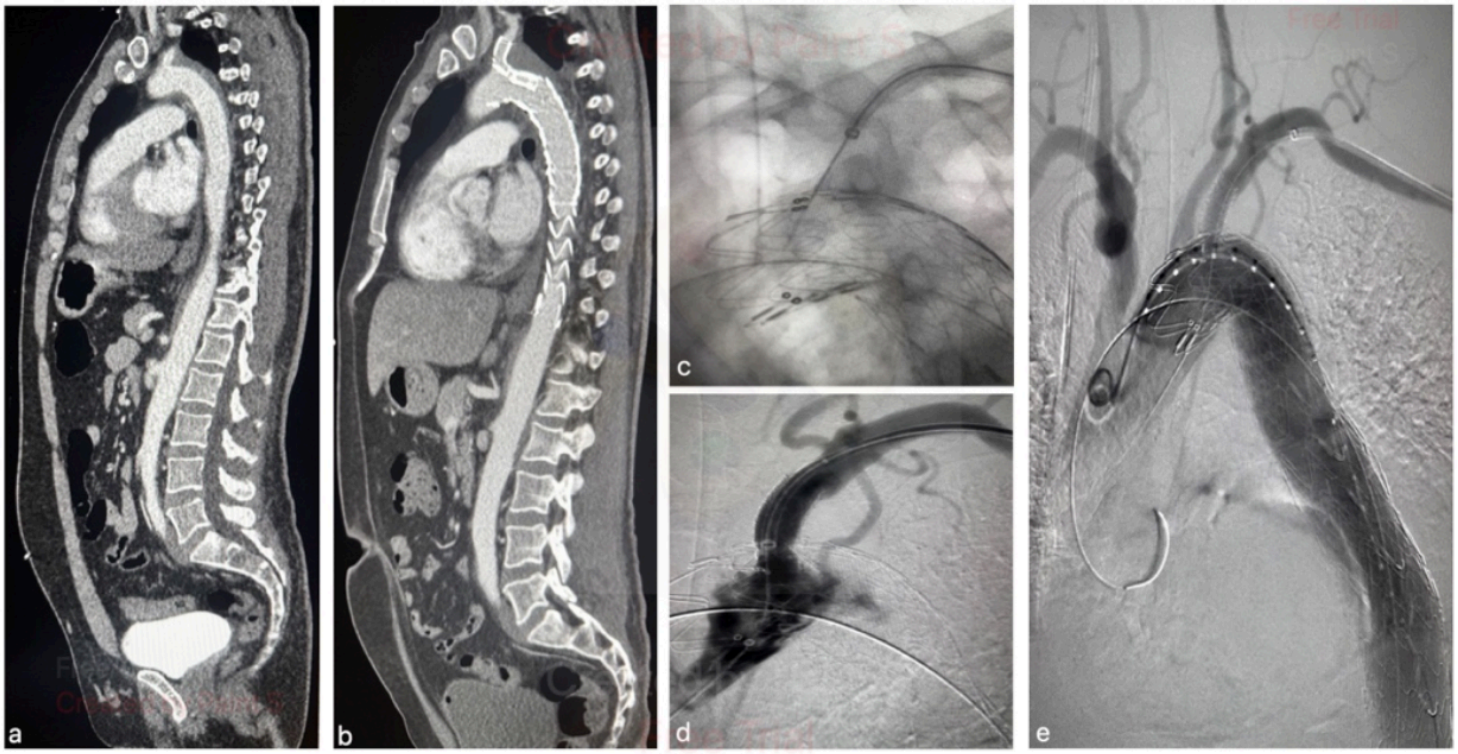

Figure 6

Illustrative post-study examples of left subclavian artery preservation during TEVAR; the patients shown were not included in the 41-patient study cohort. (a) Sagittal CTA showing acute intramural haematoma. (b) Post-TEVAR sagittal CTA after implantation of a thoracic branched endograft with preserved left subclavian artery perfusion. (c) Angiographic image demonstrating in-situ fenestration of the thoracic endograft via a needle system introduced through the left brachial artery. (d) DSA after in-situ fenestration and implantation of a bridging covered stent. (e) Final DSA demonstrating preserved left subclavian artery perfusion.

Supplementary Files

This is a list of supplementary files associated with this preprint. Click to download.

- TablesCleanCopy.docx