Research Square

Preprints are preliminary reports that have not undergone peer review.
They should not be considered conclusive, used to inform clinical practice,
or referenced by the media as validated information.

Morphometric and Intraoperative Correlates of Clinical Outcomes in Microvascular Decompression for Trigeminal Neuralgia: A Multicenter Cohort Analysis

Nicolás Rincón-Arias

nrincon@fucsalud.edu.co

Universidad FUCS. Hospital Infantil Universitario de San José.

Juan J. Orozco

Universidad FUCS

Santiago Useche

Universidad FUCS

Jairo Cruz

Universidad FUCS

David A. Fonseca

Universidad FUCS

Juan C. Covaleda

Universidad FUCS. Hospital Infantil Universitario de San José.

Jaime Sánchez

Universidad FUCS. Hospital Infantil Universitario de San José

Edgar G. Ordóñez-Rubiano

Universidad FUCS. Hospital de San José – Sociedad de Cirugía de Bogotá

Hernando A. Cifuentes-Lobelo

Universidad FUCS. Hospital Infantil Universitario de San José.

Oscar F. Zorro-Guio

Universidad FUCS. Hospital de San José – Sociedad de Cirugía de Bogotá

Research Article

Keywords: Microvascular Decompression, Neurovascular Compression, Nerve Morphometry, Trigeminal Neuralgia

Posted Date: November 24th, 2026

DOI: https://doi.org/10.21203/rs.3.rs-11587245/v1

License: This work is licensed under a Creative Commons Attribution 4.0 International License.
Read Full License

Additional Declarations: No competing interests reported.

Abstract

Background and Objective:

Trigeminal neuralgia (TN) is a debilitating neuropathic facial pain condition commonly associated with neurovascular compression. Microvascular decompression (MVD) is the most effective surgical non-destructive procedure and provides durable pain relief at long-term follow-up. This study aimed to evaluate clinical, radiological, and intraoperative variables associated with postoperative outcomes in patients with TN undergoing MVD.

Methods:

This is a multicenter retrospective cohort study in adult patients treated with MVD between 2020 and 2025 at Hospital Infantil Universitario de San José. Bogotá, Colombia and the Hospital de San José – Sociedad de Cirugía de Bogotá. Bogotá, Colombia. Clinical data, neuroimaging findings, and intraoperative variables and multimedia were collected. The pain was assessed using the Barrow Neurological Institute (BNI) classification preoperatively, in the immediate postoperative period, and in the follow-up.

Results:

A total of 25 patients were enrolled (mean age 59.6 ± 13.7 years; 80% female). The cohort primarily presented with classical Type 1 TN (88%), with a predilection for right-sided involvement (60%) and multi-dermatomal V2+V3 distribution (56%). Preoperative neuroradiological analysis identified neurovascular conflict (NVC) in 92% of cases. Quantitative morphometric assessment revealed significant nerve atrophy at the root entry zone (REZ) on the symptomatic side compared to the asymptomatic side (2.96 ± 0.69 mm vs. 3.45 ± 0.41 mm). Clinical outcomes were favorable, with a significant reduction in mean BNI scores from 3.74 ± 0.13 preoperatively to 1.42 ± 0.65 immediately post-operatively.

Conclusions:

MVD remains the definitive surgical treatment for classical), yielding significant immediate and long-term pain control. Quantitative MRI morphometry demonstrates marked trigeminal nerve atrophy at the root entry zone on the symptomatic side, establishing structural REZ changes as an objective biomarker of true mechanical conflict. Integrating preoperative nerve dimensions with intraoperative profiles—particularly identifying complex arterio-venous compressions—enhances diagnostic and thrapeutic precision to optimize clincial and surgical decision-making.

INTRODUCTION

Trigeminal neuralgia (TN) is a neuropathic disorder characterized by recurrent episodes of intense facial pain, described as electric shock-like or stabbing, following the distribution of one or more branches of the trigeminal nerve. The pain is unilateral, with an abrupt onset and termination, lasting from a few

seconds to more than five minutes, and is triggered by innocuous stimuli such as touch, speech, chewing, or a light breeze over specific areas of the face known as "trigger zones".[1–3]

From an etiopathogenic standpoint, TN is classified into three main types. Classical TN is caused by neurovascular compression of the trigeminal nerve, most commonly by the superior cerebellar artery. Secondary TN is attributable to neurological conditions such as multiple sclerosis or tumors affecting the nerve's course. Finally, idiopathic TN has no identifiable cause.[2–4] The common pathophysiological mechanism across all forms involves focal demyelination at the root entry zone (REZ) of the trigeminal nerve into the brainstem, which facilitates the generation of ectopic impulses and ephaptic transmission between adjacent fibers. In classical TN, this demyelination results from vascular compression leading to progressive nerve degeneration, whereas in secondary TN it arises primarily from structural or inflammatory lesions.[4,5]

From an epidemiological perspective, TN predominantly affects older adults, with incidence increasing significantly from the age of 50–60 years, reaching up to 20 cases per 100,000 inhabitants per year in individuals over 60.[6,7] The female sex is more frequently affected, with a female-to-male ratio ranging from 2:1 to 3:1 across different epidemiological series.[3,8] Prevalence is higher in women over 40 years of age.[9] Regarding topographic distribution, the maxillary (V2) and mandibular (V3) branches are most commonly involved, with a predominance of right-sided pain; bilateral TN is uncommon and, when present, suggests a probable secondary etiology.[1,4,8]

The diagnosis of TN is fundamentally clinical and rests on three key criteria: pain localized to the territory of one or more trigeminal branches (V1, V2, or V3), paroxysms of intense and brief pain, and triggering by innocuous stimuli.[2] Neurological examination is typically normal between attacks, although sensory deficits may be present in secondary TN. Despite the clinical nature of the diagnosis, brain MRI — both unenhanced and contrast-enhanced — is essential to rule out secondary causes and to evaluate the presence of neurovascular conflict, a finding that directly guides surgical decision-making.[2,3,5,10]

The management of TN is multidisciplinary and depends on its type and etiology. First-line pharmacological treatment relies on sodium channel blockers, primarily carbamazepine and oxcarbazepine, which achieve symptomatic control in approximately 75% of patients.[1,3,5,8] In refractory cases or when adverse effects are intolerable, additional pharmacological alternatives and referral for surgical evaluation are considered.[1,5]

Among surgical options, microvascular decompression (MVD) is the procedure with the strongest evidence base and is the treatment of choice in patients without significant comorbidities who have demonstrated neurovascular conflict on MRI, showing superiority over other invasive and non-invasive techniques in terms of pain relief.[1,3,5,10]

Given the significant impact of TN on patients quality of life, the assessment of preoperative and postoperative pain is a key element in outcome evaluation. Within this context, the present study aims to

identify surgical prognostic factors for pain control in patients who underwent microvascular decompression of the trigeminal nerve following pharmacological treatment and with radiological evidence of neurovascular conflict on MRI, with the purpose of establishing long-term favorable prognostic factors in this population.

METHODS

Patients and Inclusion Criteria

This is a ~~multicenter cross-sectional cohort research~~multicenter retrospective cohort study that included adult patients with a clinical diagnosis of TN who underwent neurosurgical treatment with MVD at Hospital de San José – Sociedad de Cirugía de Bogotá or Hospital Infantil Universitario de San José. Bogotá, Colombia.

The cases were selected from the centralized registry of neurosurgical procedures between 2020 and 2025 in both hospitals.

A review of patient medical records was conducted to establish the presentation of the condition, its duration, pharmacological management and duration of pharmacological management. In addition, the operative description for each patient was reviewed to determine variables such as intraoperative compression, compressing vessel, intraoperative arachnoiditis, and procedural complications.

Furthermore, each patient's imaging studies were reviewed to obtain the neuroradiological variables. The immediate postoperative period and post-operative pain were reviewed and classified using the Barrow Neurological Institute (BNI) classification.[11]

According to the scientific, technical, and administrative standards for health research outlined in Resolution 008430 of 1993 by the Ministry of Health of Colombia, this study is classified as minimal risk. The investigation relies on data obtained from medical records and neurosurgical multimedia records.

This study was approved by the Institutional Ethics Board and Institutional Medical Research Committee of the Fundación Universitaria de Ciencias de la Salud – Universidad FUCS. Although the study is based on a retrospective cohort design to analyze variables, written informed consent to participate was obtained from all included patients. This study complies with the ethical principles for medical research involving human subjects as outlined in the Declaration of Helsinki.

Neuroradiological Protocol for TN:

The neuroradiological severity of neurovascular conflict was assessed using a three-degree Sindou scale (I through III), which characterizes the interaction between the offending vessel and the V CN.[12]

- Degree I severity was assigned when the vessel was in direct contact with the nerve root but without visible indentation.

- Degree II severity indicated a more significant interaction, where the vessel caused displacement or distortion of the nerve root.
- Degree III severity represented the most severe form of compression, characterized by clear indentation in the nerve root. **Figure 4.**

To characterize the preoperative structural state of the V CN and the NVC a 1.5T MRI were retroactively reviewed for each patient. Qualitative signal alterations were evaluated by comparing the V CN intensity on constructive interference in steady state (CISS) sequences relative to the contralateral, unaffected side, classifying it as either hyperintense or isointense.

Furthermore, the morphometric quantitative features of the V CN included were:

- REZ diameter: Measured bilaterally on both the symptomatic (affected) and asymptomatic (unaffected) sides (mm).
- Nerve diameter at the compression site: Trigeminal nerve diameter at the site of vascular conflict was evaluated using a distance-matched bilateral control protocol. On the symptomatic side, the linear distance (mm) from the REZ to the point of maximal neurovascular compression was determined, and the cross-sectional diameter of the nerve was measured at this precise locus. For comparative analysis, the same geometric distance from the REZ was measured along the contralateral nerve, where the unaffected nerve diameter was recorded.
- Distance of compression from the REZ: Quantified as the absolute linear distance from the center of the vascular conflict to the REZ at the brainstem (mm).

Statistical analysis:

The absolute and relative frequencies of the categorical variables are described. Means with standard deviations, and interquartile ranges were calculated according to the distribution of the variables. The $\chi 2$ test, Mann-Whitney U test, and t-test were performed according to the distribution of variables. Statistical significance was set at $p<0.05$. significant. The statistical software package STATA v.15® (StataCorp LLC, College Station, TX, USA) was used for data analysis.

RESULTS

Patient Demographics and Baseline Preoperative Clinical Characteristics

During the study, 25 patients diagnosed with TN who underwent MVD were analyzed. The mean age of the cohort was 59.6 years (SD ±13.7) with a wide distribution (26–86 years). A female predominance (80%) was observed during the study, which is consistent with the classic epidemiology of TN. **Table 1.**

From a clinical perspective, the baseline characteristics of this cohort demonstrated a strong alignment with classical Type 1 TN criteria, as defined by the International Classification of Headache Disorders,

3rd edition (ICHD-3) and the International Association for the Study of Pain (IASP), accounting for 88% (n = 22) in our cohort.[13,14]

The TN presentation in out cohort was predominantly right-sided (60%, n = 15/25), with a high prevalence of multi-dermatomal involvement characterized primarily by overlapping maxillary and mandibular (V2 + V3) branch distribution (56%, n = 14/25). **Table 1 - Figure 1.** The cohort exhibited a long-standing history of disease, with a mean symptom duration of 7.82 ± 8.44 years and a mean duration of preoperative pharmacological management of 6.42 ± 7.07 years. 52% of the patients (n = 13/25) required pharmacological polytherapy (≥2 medications). Among the targeted medical regimens maintained at baseline, carbamazepine monotherapy was utilized in 28% of cases. **Table 1**

Qualitative and Quantitative Morphometric Neuroradiological Preoperative Analysis

The preoperative MRI revealed morphological evidence of NVC in 92% of the patient cohort (n = 23/25), with isolated arterial compression presenting as the primary radiological construct (68%, n = 17/25). Anatomical localization of the mechanical conflict demonstrated a distinct predilection for proximal segments, involving both the REZ and the cisternal segment synchronously in 48% of cases (n = 12/25), followed by isolated REZ localization in 32% (n = 8/25). Cisternal and juxtapetrosal conflicts were rare, representing 8% (n = 2/25) and 4% (n = 1/25) of the cohort, respectively. **Table 2.**

Qualitative signal evaluation via high-resolution CISS sequences demonstrated that the symptomatic nerve remained isointense relative to the contralateral side in 56% of cases (n = 14/25), while focal hyperintensity at the NVC was documented in the remaining 44% (n = 11/25). **Table 2.**

The mean cross-sectional diameter of the V CN at the REZ was reduced on the affected (symptomatic) side compared to the unaffected (asymptomatic) side (2.96 ± 0.69 mm vs. 3.45 ± 0.41 mm, respectively). Similarly, at the precise point of maximum vascular contact—located at a mean linear distance of 1.87 ± 0.64 mm from the REZ—the mean nerve diameter on the compressed side was smaller than the distance-matched contralateral control segment (2.16 ± 0.84 mm vs. 2.44 ± 0.61 mm. **Table 2 - Figure 5.**

Intraoperative Surgical Neurovascular Compression

Direct neurosurgical exploration confirmed the presence of NVC in 100% of the treated cases (n = 25/25). In terms of the compressive mechanics, an isolated arterial component was identified in 56% of patients (n = 14/25), while a mixed arterio-venous compression profile was documented in 36% (n = 9/25); isolated venous compression was the least frequent archetype, representing 8% of the cohort (n = 2/25). Granular analysis of the offending vessels revealed that the superior cerebellar artery (SCA), either isolated or in combination with other structures, was the dominant vascular structure of NVC. Concurrent compression by the SCA and the superior petrosal vein was documented in 28% of cases (n = 7/25), followed closely by isolated SCA compression in 24% (n = 6/25). The anterior inferior cerebellar artery (AICA) and the posterior inferior cerebellar artery (PICA) each accounted for 12% of the

compressive intraoperative findings (n = 3/25). Complex multi-vessel involvements—including SCA + AICA (4%), SCA + AICA + pontotrigeminal vein (4%), and SCA + vertebral artery (4%)—were occasionally encountered. Isolated involvement of the superior petrosal vein or a combination of the basilar and vertebral arteries were each restricted to 4% of the population (n = 1/25). **Table 3 - Figure 2.**

Mild arachnoiditis was identified in 52% of patients (n = 13/25), whereas moderate and severe variants were noted in 32% (n = 8/25) and 4% (n = 1/25), respectively; only 12% (n = 3/25) of the cohort presented without arachnoiditis. **Table 3.**

Longitudinal Pain Control and BNI Classification Shift

Preoperatively, 68% of the study cohort (n = 17) presented with BNI classification of IV. Postoperative clinical evolution evaluated via the Wilcoxon signed-rank test revealed a statistically significant difference between immediate and follow-up BNI scores (W = 4.00, p = 0.042). The mean immediate postoperative BNI score was 1.42 ± 0.65, shifting to 1.71 ± 0.86 at long-term follow-up. **Figure 3 - Table 4.** This minimal rise indicates a slight loss of definitive pain control over time.

DISCUSSION

The efficacy of MVD is high: pooled analyses and independent outcome assessments report that 62–89% of patients are pain-free at long-term follow-up (3–11 years), with 73–80% maintaining pain relief at 4–5 years.[5]

Neurovascular Conflict in the Root Entry Zone (REZ)

Neurovascular conflict (NVC) at the root entry zone (REZ) is the fundamental pathophysiologic mechanism in TN, where vascular compression causes morphological changes of the trigeminal nerve at the transition zone between peripheral and central myelin, leading to focal demyelination and subsequent hyperexcitability.[2,5]

Simple contact between the trigeminal nerve and a vascular structure is not sufficient to cause TN.[8,15,16] To attribute the disorder to a NVC, the anomalous vessel must induce anatomical alterations in the trigeminal REZ.[2]

There is a significant difference in the location of neurovascular conflict (NVC) based on the presence of symptoms. In cases of asymptomatic contact, the point of contact is generally found more distal from the brain stem, averaging 3.85 ± 2.69 mm from the REZ.[17] Conversely, in cases of symptomatic NVC, the contact point is typically located more proximal to the brain stem, averaging 0.94 ± 1.27 mm form the REZ.[17] This suggests that the NVC near to the brain stem is correlated with the development of TN.

In our results, the REZ was involved in 80% of the identified NVC, either as an isolated finding (32%) or in conjunction with the cisternal segment (48%). **Table 2.**

Our study highlights a high prevalence of complex neurovascular architecture, with mixed arterio-venous NVC identified in 36% of cases and involvement of the superior petrosal vein (SPV) in 36% of the cohort (either in isolation or in combination). In the literature, from the SPV itself or its tributaries (transverse pontine vein, pontotrigeminal vein, vein of the cerebellopontine fissure, vein of the middle cerebellar peduncle) — accounts for roughly 5.5–20% of cases, either alone or combined with arterial compression.[18,19]

From a microsurgical perspective, addressing a mixed arterio-venous NVC is technically demanding because both offending vessels must be addressed independently while avoiding injury to adjacent perforators and brainstem veins, and because the venous element is often entangled in thickened arachnoid that obscures the REZ and the arterial conflict beneath it.[20]

Trigeminal Nerve Size in TN

Trigeminal nerve atrophy is now recognized as a core diagnostic and pathophysiological feature of TN. Consistent with existing literature, our morphometric assessment revealed a quantifiable atrophy of the symptomatic nerve compared to the contralateral side. Specifically, we observed a mean REZ diameter of 2.96 ± 0.69 mm on the affected side versus 3.45 ± 0.41 mm on the asymptomatic side. These findings mirror pivotal studies demonstrating that ipsilateral nerve volume and cross-sectional area are significantly smaller in TN patients than in healthy controls, providing objective, non-invasive evidence of chronic neural degeneration.[21]

This volumetric discrepancy serves as a critical discriminator in clinical practice and surgical decision-making. Neurovascular contact alone has poor specificity, frequently appearing in up to 36% of asymptomatic nerves; however, the presence of nerve atrophy or dislocation, as documented in our cohort, raises diagnostic specificity to 97%.[2,22] These morphometric changes are therefore essential for distinguishing "classical TN," driven by significant mechanical root deformation, from incidental neurovascular contact that may not be the primary driver of clinical symptoms.

Our measurements, where the diameter of the nerve at the compression site was significantly lower than the healthy nerve (2.16 ± 0.84 mm vs 2.44 ± 0.61 mm), align with this paradigm, reinforcing the understanding that such atrophy reflects cumulative mechanical injury to the REZ. **Table 2.** In the literature, nerve atrophy and dislocation together have shown high specificity (97%), with good positive (81–86%) and negative (82–87%) predictive values for symptomatic-side identification.[5,23]

Correlation Between the Sindou Scale and Surgical Findings

The Sindou scale's predictive value varies with the NVC severity.[12] In a blinded study of 100 patients comparing preoperative MRI to surgical findings, MRI demonstrated 97% sensitivity and 50% specificity for detecting NVC, with an area under the ROC curve of 0.93.[24] However, the agreement between MRI-graded severity and intraoperative findings was moderate (Cohen's $\kappa = 0.38$), indicating substantial variability in predicting the exact degree of compression.[24]

The positive predictive value was differentiated by compression grade, with excellent prediction for high-grade conflicts but poor reliability for low-grade compressions. Some apparent low-grade compressions on MRI were revealed as false positives during surgical exploration.[24]

The clinical diagnosis in TN remains paramount, with MRI serving as a complementary tool that is most valuable when showing high-grade compression. The positive predictive value for conflict presence is high (92-95%), supporting surgical decision-making when severe compression is visualized, but the low negative predictive value (27-33%) means negative imaging does not reliably exclude surgically correctable pathology.[24,25]

The correlation between preoperative neuroimaging and intraoperative findings remains a critical determinant in the surgical management of TN. In our series, while high-resolution MRI suggested NVC in 68% of patients while intraoperative exploration confirmed NVC in 100% of the cohort.

While CISS provide excellent contrast between cerebrospinal fluid and neurovascular structures, they suffer from lack of signal differentiation between arteries and veins, between vessels and nerves, and for brain parenchyma.[26] This fundamental limitation means that subtle or dynamic vessel-nerve contacts can be mischaracterized or missed entirely.[26]

Even high-resolution MRI failed to identify 21% of arterial compressions, 42.5% of venous compressions, and 18.5% of combined compressions in a large surgical series.[27] The negative predictive value of preoperative MRI is 27-33%, meaning that absence of visible compression on imaging does not reliably exclude surgically correctable pathology.[27]

Surgical discoveries without imaging correlate: In approximately 11% of microvascular decompression cases, surgeons find neurovascular compression or contact that was not evident on preoperative imaging, yet still proceed with MVD.[27]

Stability of Pain Relief after MVD: Immediate vs. Long-Term Outcomes

Immediate postoperative pain relief after MVD is remarkably high, but it does not guarantee durable, long-term freedom from trigeminal neuralgia; a subset of initially pain-free patients will experience recurrence over years of follow-up, and the strongest data indicate that a lack of immediate pain relief predicts a substantially higher risk of subsequent recurrence. [28–30] Across broader literature, complete or near-complete pain relief in the immediate postoperative period is achieved in the large majority of patients—ranging from 85.7% to 96% in various cohorts, including 86.7% complete plus 10.3% partial relief in a 1025-patient series, 92.7% pain-free status in a 523-patient 23-year cohort, and 78.9% complete relief at 7 days in a Japanese multicenter prospective study.[28–32]

In alignment with these benchmarks, our results demonstrate a profound immediate clinical improvement: the cohort transitioned from a preoperative mean BNI score of 3.74 (SD 0.127) to an immediate postoperative mean of 1.42 (SD 0.654), with 88% of patients (n = 22/25) achieving BNI grade

I–II immediately following the procedure. However, evaluating the stability of this relief at a mean follow-up of 8.6 months revealed a mean BNI score drift to 1.71 (SD 0.859), with 84% (n = 21/25) maintaining BNI grade I–II. Although the vast majority of our patients sustained excellent outcomes, the Wilcoxon signed-rank test confirmed a statistically significant difference between immediate and long-term BNI scores (p = 0.042), indicating a subtle yet measurable temporal degradation in pain control over time. **Table 4.**

Several anatomical and pathological factors contribute to this longitudinal variability. Intraoperatively, we identified a highly complex vascular landscape, with 100% of cases confirming neurovascular conflict, of which 36% (n = 9) involved complex mixed arterial and venous compression.

Furthermore, our cohort demonstrated a significant burden of adhesive disease, with 88% of patients exhibiting some degree of arachnoiditis. This highlights a critical prognostic variable, as intraoperative arachnoiditis is recognized in the literature as a significant negative prognostic factor at index MVD. In a large cohort of 395 MVDs, for instance, intraoperative arachnoiditis was noted in 51 patients (13%)—graded mild in 39.2% and severe in 60.8%—where only 56.9% achieved a successful outcome (BNI I or II) compared to much higher success rates in cases without arachnoiditis, yielding a 15-year pain-free probability of 72% in the arachnoiditis subgroup.[33]

Notably, the adverse effect of arachnoiditis is most pronounced when combined with low-grade neurovascular conflict—meaning that when arachnoid scarring itself, rather than robust vascular compression, constitutes the dominant pathology, the surgical result tends to be poorer. This evidence suggests that arachnoiditis is not merely a surrogate for compression severity, but may independently impair the nerve's tolerance to residual or minor contact, or reflect chronic mechanical and inflammatory injury to the nerve root. In our surgical experience, these adhesive changes can facilitate the reformation of neurovascular contact or localized neural irritation over time, even following a successful initial MVD.

LIMITATIONS

Our study has several limitations that warrant careful consideration. First, the sample size of 25 patients over an eight-year multicenter period may be perceived as relatively small. However, this reflects our stringent inclusion criteria designed to prioritize "data purity" and intraoperative findings accuracy over volume. By exclusively including patients with complete medical records and high-resolution imaging—specifically those with CISS sequences—we ensured the highest level of granularity for our morphometric analyses and Sindou scale grading. This rigorous selection process allowed for a more precise correlation between radiological findings and surgical outcomes, albeit at the expense of a larger cohort.

Second, the retrospective nature of this research introduces inherent limitations regarding the standardization of intraoperative reporting. While we identified moderate-to-severe arachnoiditis in 84% of our patients, the qualitative descriptions found in surgical notes may vary in their detail regarding the

specific nuances of microvascular compression and the exact extent of arachnoid adhesions. This variability in documentation could potentially mask more subtle associations between intraoperative findings and long-term pain relief.

Finally, the statistical constraints of our study must be acknowledged. The violation of residual normality in our exploratory linear regression model ($p = 0.004$) and the low coefficient of determination ($R^2 = 0.118$) limit the interpretability of our predictive modeling. Consequently, these findings should be viewed as high-fidelity descriptive correlations rather than definitive prognostic predictors, underscoring the need for larger, prospective trials to validate these surgical trends.

CONCLUSIONS

MVD provides effective pain relief in patients with TN, with most patients achieving significant improvement in the immediate postoperative period and maintaining good pain control during follow-up, despite a slight decline over time. In this cohort, some of the conventional variables such as symptom duration were not significantly associated with postoperative pain outcomes, suggesting that the intrinsic characteristics of the NVC can have a more critical role. Consequently, quantitative MRI morphometry demonstrates significant trigeminal nerve atrophy at the REZ on the symptomatic side, establishing structural REZ changes and nerve displacement as objective radiological biomarkers of true mechanical conflict.

Abbreviations

Anterior Inferior Cerebellar Artery
AICA
Barrow Neurological Institute
BNI
Central nervous system
CNS
Constructive Interference Iin Steady State
CISS
International Classification of Headache Disorders, 3rd edition
ICHD-3
International Association for the Study of Pain
IASP
Microvascular Decompression
MVD
Neurovascular conflict
NVC

Posterior Inferior Cerebellar Artery
PICA
Root Entry Zone
REZ
Superior Cerebellar Artery
SCA
Trigeminal Neuralgia
TN
V CN
V Cranial Nerve

Declarations

Ethics Approval and Consent to Participate:

All procedures performed in this study involving human participants were conducted in strict accordance with the ethical standards of the institutional and national research committee (Institutional Ethics Board and Institutional Medical Research Committee of the Fundación Universitaria de Ciencias de la Salud – Universidad FUCS; classified as minimal risk under Resolution 008430 of 1993 by the Ministry of Health and Social Protection of Colombia).

Furthermore, the research was conducted in full compliance with the 1964 Declaration of Helsinki and its later amendments or comparable ethical standards. Written informed consent to participate was obtained from all individual participants included in the study.

Clinical Trial Registration:

Clinical trial number: not applicable.

Funding Sources:

This research did not receive specific financial support from public agencies, commercial entities, nonprofit organizations, or any other institutions. The authors confirm that there was no external funding.

Conflicts of Interest:

The authors declare no conflicts of interest.

References

1. Snel BJ, Cohen SP, Erdine S, Day MR, Van Zundert J, Vissers K et al (2025) 13. Trigeminal Neuralgia. Pain Pract Off J World Inst Pain 25(5):e70051. 10.1111/papr.70051 PubMed PMID: 40384548;

PubMed Central PMCID: PMC12086744

2. Cruccu G, Di Stefano G, Truini A, Trigeminal Neuralgia (2020) N Engl J Med 383(8):754–762. 101056/NEJMra1914484 PubMed PMID: 32813951
3. Amaechi O (2025) Trigeminal Neuralgia: Rapid Evidence Review. Am Fam Physician 111(5):427–432 PubMed PMID: 40378323
4. Maarbjerg S, Di Stefano G, Bendtsen L, Cruccu G (2017) Trigeminal neuralgia - diagnosis and treatment. Cephalalgia Int J Headache 37(7):648–657 doi:10.1177/0333102416687280 PubMed PMID: 28076964
5. Bendtsen L, Zakrzewska JM, Heinskou TB, Hodaie M, Leal PRL, Nurmikko T et al (2020) Advances in diagnosis, classification, pathophysiology, and management of trigeminal neuralgia. Lancet Neurol 19(9):784–796. 10.1016/S1474-4422(20)30233-7 PubMed PMID: 32822636
6. Manzoni GC, Torelli P (2005) Epidemiology of typical and atypical craniofacial neuralgias. Neurol Sci Off J Ital Neurol Soc Ital Soc Clin Neurophysiol 26(Suppl 2):s65–67. 10.1007/s10072-005-0410-0 PubMed PMID: 15926023
7. Hong JH, Lee JY, Kim SJ, Seo KH (2023) Retrospective Analysis of Clinical Feature in Trigeminal Neuralgia. Pain Physician 26(1):39–44 PubMed PMID: 36791292
8. Ashina S, Robertson CE, Srikiatkhachorn A, Di Stefano G, Donnet A, Hodaie M et al (2024) Trigeminal neuralgia. Nat Rev Dis Primer 10(1):39. 10.1038/s41572-024-00523-z PubMed PMID: 38816415
9. Bahgat D, Ray DK, Raslan AM, McCartney S, Burchiel KJ (2011) Trigeminal neuralgia in young adults. J Neurosurg 114(5):1306–1311 10781 PubMed PMID: 21128738
10. Liu Y, Tanaka E, Pathogenesis (2025) Diagnosis, and Management of Trigeminal Neuralgia: A Narrative Review. J Clin Med 14(2):528 doi:10.3390/jcm14020528 PubMed PMID: 39860534; PubMed Central PMCID: PMC11765769
11. Rogers CL, Shetter AG, Fiedler JA, Smith KA, Han PP, Speiser BL (2000) Gamma knife radiosurgery for trigeminal neuralgia: the initial experience of The Barrow Neurological Institute. Int J Radiat Oncol Biol Phys 47(4):1013–1019. 10.1016/s0360-3016(00)00513-7 PubMed PMID: 10863073
12. Sindou M, Leston J, Decullier E, Chapuis F (2007) Microvascular decompression for primary trigeminal neuralgia: long-term effectiveness and prognostic factors in a series of 362 consecutive patients with clear-cut neurovascular conflicts who underwent pure decompression. J Neurosurg 107(6):1144–1153. 10.3171/JNS-07/12/1144 PubMed PMID: 18077952
13. Terminology | International Association for the Study of Pain International Association for the Study of Pain (IASP) [Internet]. [cited 2026 Aug 8]. Available from: https://www.iasp-pain.org/resources/terminology/
14. ICHD-3 [Internet] (2026) Aug 8]. 13.1.1 Trigeminal neuralgia. Available from: https://ichd-3.org/13-painful-cranial-neuropathies-and-other-facial-pains/13-1-trigeminal-neuralgia/13-1-1-classical-trigeminal-neuralgia/
15. Love S, Coakham HB (2001) Trigeminal neuralgia: pathology and pathogenesis. Brain J Neurol 124(Pt 12):2347–2360. 10.1093/brain/12412.2347 PubMed PMID: 11701590

16. Maarbjerg S, Wolfram F, Gozalov A, Olesen J, Bendtsen L (2015) Significance of neurovascular contact in classical trigeminal neuralgia. Brain J Neurol 138(Pt 2):311–319. 10.1093/brain/awu349 PubMed PMID: 25541189
17. Suzuki M, Yoshino N, Shimada M, Tetsumura A, Matsumura T, Fukayama H et al (2015) Trigeminal neuralgia: differences in magnetic resonance imaging characteristics of neurovascular compression between symptomatic and asymptomatic nerves. Oral Surg Oral Med Oral Pathol Oral Radiol 119(1):113–118. 10.1016/j.oooo.2014.09.013 PubMed PMID: 25442253
18. Pătrășcan AM, Brehar FM, Gorgan RM (2026) Pivotal Factors for Minimizing the Risks of Therapeutic Failure in Trigeminal Neuralgia and Hemifacial Spasm. Curr Pain Headache Rep 30(1):27. 10.1007/s11916-025-01449-1
19. Huang Y, Huang Y, Xiao C, Huang Q, Chai X (2026) Preoperative imaging evaluation of primary trigeminal neuralgia using 3D TOF-MRA and 3D FIESTA-c: A retrospective study of 412 cases. J Neurol 273(7):418. 10.1007/s00415-026-13893-z
20. Xiao Y, Xu C, Li P, Liu Y, Geng L, Zou Y et al (2026) Optimizing microvascular decompression for venous compression in trigeminal neuralgia: clinical outcomes and technical considerations. Neurol Res. ;1–11. doi:10.1080/01616412.2026.2660938 PubMed PMID: 42035407.
21. Leal PRL, Barbier C, Hermier M, Souza MA, Cristino-Filho G, Sindou M (2014) Atrophic changes in the trigeminal nerves of patients with trigeminal neuralgia due to neurovascular compression and their association with the severity of compression and clinical outcomes. J Neurosurg 120(6):1484–1495. 10.3171/2014.2.JNS131288 PubMed PMID: 24745706
22. Cruccu G, Finnerup NB, Jensen TS, Scholz J, Sindou M, Svensson P et al (2016) Trigeminal neuralgia: New classification and diagnostic grading for practice and research. Neurology 87(2):220–228. 10.1212/WNL.0000000000002840 PubMed PMID: 27306631; PubMed Central PMCID: PMC4940067
23. Kenis C, Libeert A, Pyfferoen L, Salamon N, Vanden Bossche S, Casselman J (2026) Advances in cranial nerve imaging: emerging MRI techniques. Neuroradiology 68(7):2103–2118. 10.1007/s00234-026-04034-4
24. Brînzeu A, Drogba L, Sindou M (2018) Reliability of MRI for predicting characteristics of neurovascular conflicts in trigeminal neuralgia: implications for surgical decision making. J Neurosurg 130(2):611–621. 10.3171/2017.8.JNS171222 PubMed PMID: 29624148
25. Hitchon PW, Bathla G, Moritani T, Holland MT, Noeller J, Nourski KV (2019) Predictability of vascular conflict by MRI in trigeminal neuralgia. Clin Neurol Neurosurg 182:171–176. 10.1016/j.clineuro.2019.05.005 PubMed PMID: 31151046
26. Bendtsen L, Zakrzewska JM, Abbott J, Braschinsky M, Di Stefano G, Donnet A et al (2019) European Academy of Neurology guideline on trigeminal neuralgia. Eur J Neurol 26(6):831–849. 10.1111/ene.13950
27. Xu R, Nair SK, Raj D, Materi J, So RJ, Gujar SK et al (2022) The Role of Preoperative Magnetic Resonance Imaging in Assessing Neurovascular Compression Before Microvascular

Decompression in Trigeminal Neuralgia. World Neurosurg 168:e216–e222. 10.1016/j.wneu2022.09.092 PubMed PMID: 36167303

28. Kumar R, Stien KJ, Pollock BE (2026) Microvascular Decompression for Patients With Type 1 Trigeminal Neuralgia Using Vein Sacrifice and a Teflon Transposition Technique: A 23-Year Cohort. Neurosurgery 98(3):588–596. 10.1227/neu.0000000000003614 PubMed PMID: 40622146
29. Krzemińska A, Koźba-Gosztyła M, Bladowska J, Czapiga B (2025) Efficacy of microvascular decompression in the treatment of trigeminal neuralgia: a retrospective Single-Center study of 28 cases. Neurosurg Rev 48(1):614. 10.1007/s10143-025-03772-y PubMed PMID: 40839306
30. Ashraf M, Sajjad F, Hussain SS, Cheema HA, Ali S, Umar H et al (2024) Long-term outcome of microvascular decompression for typical trigeminal neuralgia with autologous muscle: an analysis of 1025 patients from a developing country. J Neurosurg 141(3):849–859. 10.3171/2023.9.JNS231473 PubMed PMID: 38608302
31. Wang DD, Raygor KP, Cage TA, Ward MM, Westcott S, Barbaro NM et al (2018) Prospective comparison of long-term pain relief rates after first-time microvascular decompression and stereotactic radiosurgery for trigeminal neuralgia. J Neurosurg 128(1):68–77. 10.3171/2016.9.JNS16149 PubMed PMID: 28298026
32. Mizobuchi Y, Nagahiro S, Kondo A, Arita K, Date I, Fujii Y et al (2021) Microvascular Decompression for Trigeminal Neuralgia: A Prospective, Multicenter Study. Neurosurgery 89(4):557–564. 10.1093/neuros/nyab229 PubMed PMID: 34325470
33. Mazzucchi E, Brinzeu A, Sindou M (2019) Arachnoiditis as an outcome factor for microvascular decompression in classical trigeminal neuralgia. Acta Neurochir (Wien) 161(8):1589–1598. 10.1007/s00701-019-03981-7 PubMed PMID: 31240582

Tables

Table 1. Patient Demographics and Baseline Preoperative Clinical Characteristics

Variable	N / mean (SD)	% / range
Demographic Data		
Age in years	59.6 (13.7)	26 – 86
Female sex	20/25	80%
Clinical Characteristics		
Duration of symptoms (years)	7.82 (8.44)	0.4 – 33
Duration of medical treatment (years)	6.42 (7.07)	0.4 – 30
Side of Pain		
Right side	15/25	60%
TN ICHD-3 and IASP Classification		
- Type 1 TN	22/25	88%
- Type 2 TN	3/25	12%
TN distribution:		
- V1	2/25	8
- V2	0/25	0%
- V3	4/25	16%
- V1 + V2	1/25	4%
- V1 + V3	0/25	0%
- V2 + V3	14/25	56%
- V1 + V2 + V3	4/25	16%
Pharmacological polytherapy (≥ 2 drugs)	13/25	52%
- Carbamazepine	7/25	28%
- Carbamazepine + Pregabaline	5/25	20%
- Pregabaline	3/25	12%
- Carbamazepine + Pregabaline + Oxcarbazepine	3/25	12%

International Classification of Headache Disorders, 3rd edition: ICHD-3; International Association for the Study of Pain: IASP; SD: standard deviation; TN: trigeminal neuralgia; V1: Ophthalmic branch of the trigeminal nerve; V2; Maxillary branch of the trigeminal nerve; V3: Mandibular branch of the trigeminal nerve

Table 2. Qualitative and Quantitative Morphometric Neuroradiological Preoperative Analysis of the Trigeminal Nerve

Neuroradiological Preoperative Factors	N	%
Preoperative neuroradiological neurovascular compression		
- Arterial compression	17/25	68%
- Vein compression	3/25	12%
- Arterial + vein cmpression	3/25	12%
- Without compression	2/25	8%
Preoperative neurovascular compression segment of the V CN		
- REZ + cisternal segment	12/25	48%
- REZ	8/25	32%
- Cisternal segment	2/25	8%
- Yuxtapetrosal segment	1/25	4%
- Without compression	2/25	8%
V CN intensity in CISS in relation with the contralateral V CN		
- Hiperintense	11/25	44%
- Isointense	14/25	56%
Trigeminal Nerve Preoperative Neuroradiological Features		
	Mean ± SD	
REZ diameter on affected side (mm)	2.96 ± 0.69	
REZ diameter on unaffected side (mm)	3.45 ± 0.41	
Diameter of nerve with compression — affected (mm)	2.16 ± 0.84	
Diameter of nerve with compression — unaffected (mm)	2.44 ± 0.61	
Distance of compression from the REZ (mm)	1.87 ± 0.64	

REZ: root entry zone; SD: standard deviation

Table 3. Intraoperative Neurovascular Anatomy, Compression Profiles, and Degree of Local Arachnoiditis.

Intraoperative Findings and Neurovascular Conflict Archetypes	N	%
Neurovascular Compression Confirmed Intraoperatively		
Yes (all cases)	25	100%
Intraoperative Surgical Neurovascular Compression		
- Arterial compression	14/25	56%
- Vein compression	2/25	8%
- Arterial + vein compression	9/25	36%
Vessel ff the Neurovascular Compression		
- SCA + superior petrosal vein	7/25	28%
- SCA	6/25	24%
- AICA	3/25	12%
- PICA	3/25	12%
- SCA + AICA	1/25	4%
- SCA + AICA + Pontotrigeminal vein	1/25	4%
- SCA + vertabral artery	1/25	4%
- AICA + superior petrosal vein	1/25	4%
- Superior petrosal vein	1/25	4%
- Basilar artery + vertebral artery	1/25	4%
Degree Of Intraoperative Arachnoiditis		
- Mild arachnoiditis	13/25	52%
- Moderate arachnoiditis	8/25	32%
- Severe arachnoiditis	1/25	4%
- Without arachnoiditis	3/25	12%

IOP: intraoperative. SCA: superior cerebellar artery. AICA: anterior inferior cerebellar artery. PICA: posterior inferior cerebellar artery. MVD: microvascular decompression. Percentages for offending vessels are not mutually exclusive, as both primary and additional compressing vessels were recorded.

Table 4. Longitudinal Pain Control and BNI Classification Shift

	N	%
Preoperative BNI Classification: Mean (SD)	3.74 (0.127)	
- Grade 1 – 2	0/25	0%
- Grade 3a	4/25	16%
- Grade 3b	4/25	16%
- Grade 4	17/25	68%
Immediate postoperative BNI Mean (SD)	1.42 (0.654)	
- Grade 1 – 2	22/25	
- Grade 3a	0/25	0%
- Grade 3b	0/25	0%
- Grade 4	0/25	0%
Follow-up BNI Classification Mean (SD)	1.71 (0.859)	
- Grade 1 – 2	21/25	84%
- Grade 3a	2/25	8%
- Grade 3b	1/25	4%
- Grade 4	1/25	4%
Change in the BNI Classification: Immediate vs. Follow-Up (Wilcoxon signed-rank test)		
Wilcoxon statistic (W)	4.00	p = 0.042*

BNI: Barrow Neurological Institute Pain Intensity Classification (1 = no pain; 5 = severe pain). The comparison between immediate postoperative and follow-up BNI scores was performed using the Wilcoxon signed-rank test for paired samples. Statistically significant ($p < 0.05$).

Table 5. Postoperative Clinical Outcomes, Longitudinal Pain Scores, and Resource Utilization

Postoperative Variable	N / Mean (SD)	% / Range
Postoperative Complications		
No complications	20	80%
Minor complication	4	16%
Major complication	1	4%
Postoperative Follow-Up (Months)		
Mean (SD)	8.6 ± 22.2	0.1–102.4
Hospital length of stay (days)		
Mean (SD)	3.4 (1.6)	0 – 7
ICU length of stay (days)		
Mean (SD)	1.6 (1.5)	0 – 6

Table 6. Exploratory Linear Regression for Immediate Postoperative Pain (BNI Score). Regarding the exploratory linear regression model evaluating immediate postoperative pain scores, the violation of the residual normality assumption (Shapiro-Wilk $p = 0.004$) and the low coefficient of determination ($R^2 = 0.118$) highlight the inherent limitations of parametric modeling when applied to discrete clinical ordinal scales like the BNI classification. In the pathophysiology of TN, clinical and anatomical recovery depends on a complex interplay of variables, rather than simple linear relationships. Consequently, our primary conclusions rely on robust non-parametric analyses (such as the Wilcoxon signed-rank test validating longitudinal pain control stability).

Predictor	Estimate	SE	t	p	95% CI Lower	95% CI Upper
Intercept	1.076	0.400	2.69	0.015*	—	—
Arachnoiditis IOP (grade 2 vs. 1)	0.531	0.438	1.21	0.240	−0.589	2.212
Arachnoiditis IOP (grade 3 vs. 1)	0.567	0.464	1.22	0.237	−0.618	2.353
Arachnoiditis IOP (grade 4 vs. 1)	−0.019	0.780	−0.024	0.981	−2.527	2.469
Duration of symptoms (years)	−0.014	0.017	−0.85	0.405	−0.648	0.273
Model R^2	0.118	—	—	—	—	—

Dependent variable: immediate postoperative BNI: Barrow Neurological Institute Pain Intensity Classification Predictors: grade of intraoperative arachnoiditis and preoperative symptom duration. SE: standard error. CI: confidence interval. $R^2 = 0.118$. Residual normality (Shapiro-Wilk): $p = 0.004$ (assumption not met).

Statistically significant ($p < 0.05$). Note: given that residual normality is violated, linear regression results should be interpreted with caution; non-parametric complementary analyses are recommended.

Figures

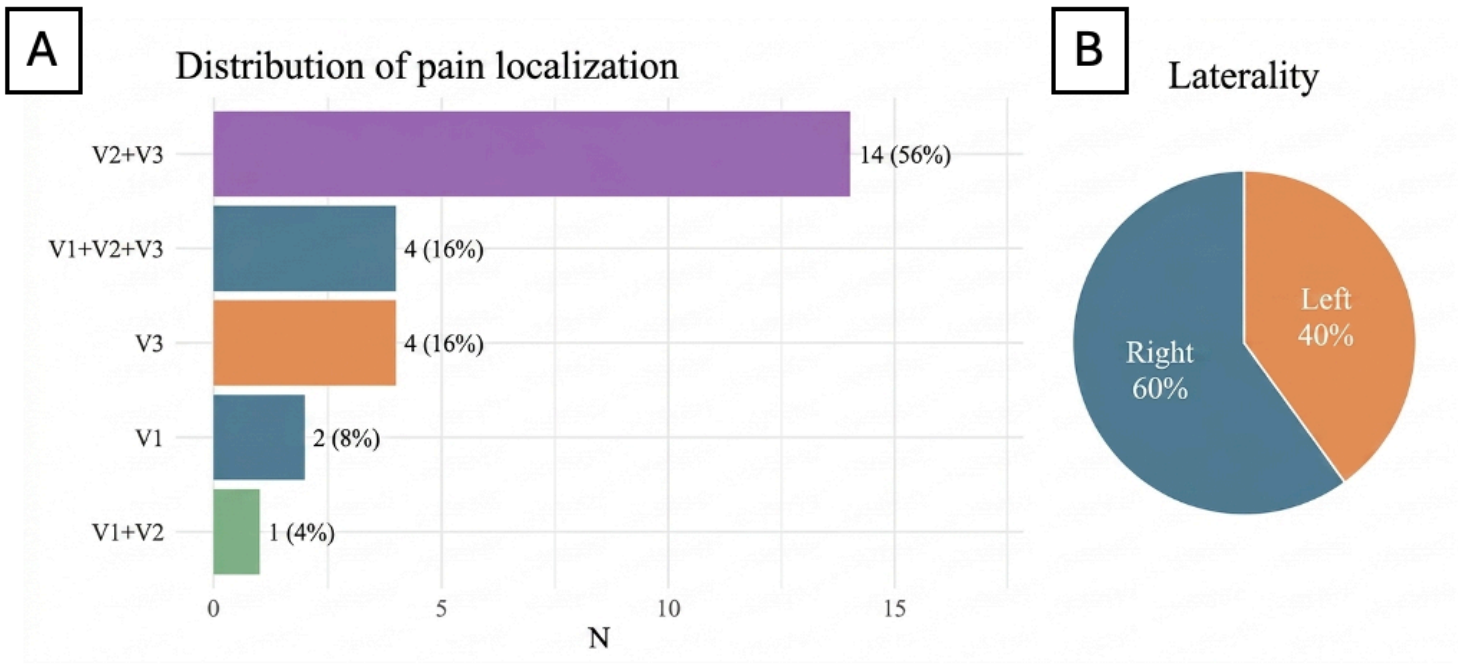

Figure 1

Distribution of Pain and Laterality of TN. Mapping of the affected trigeminal nerve divisions demonstrated a high prevalence of multi-dermatomal involvement within the study cohort (**Figure 1A**). Overlapping pain in both the maxillary and mandibular divisions (V2 + V3) was the predominant clinical phenotype, observed in more than half of the patient population (n = 14, 56%). Regarding the side of clinical presentation (**Figure 1B**), right-sided facial pain was more frequently observed, accounting for 60% of the cohort (n = 15).

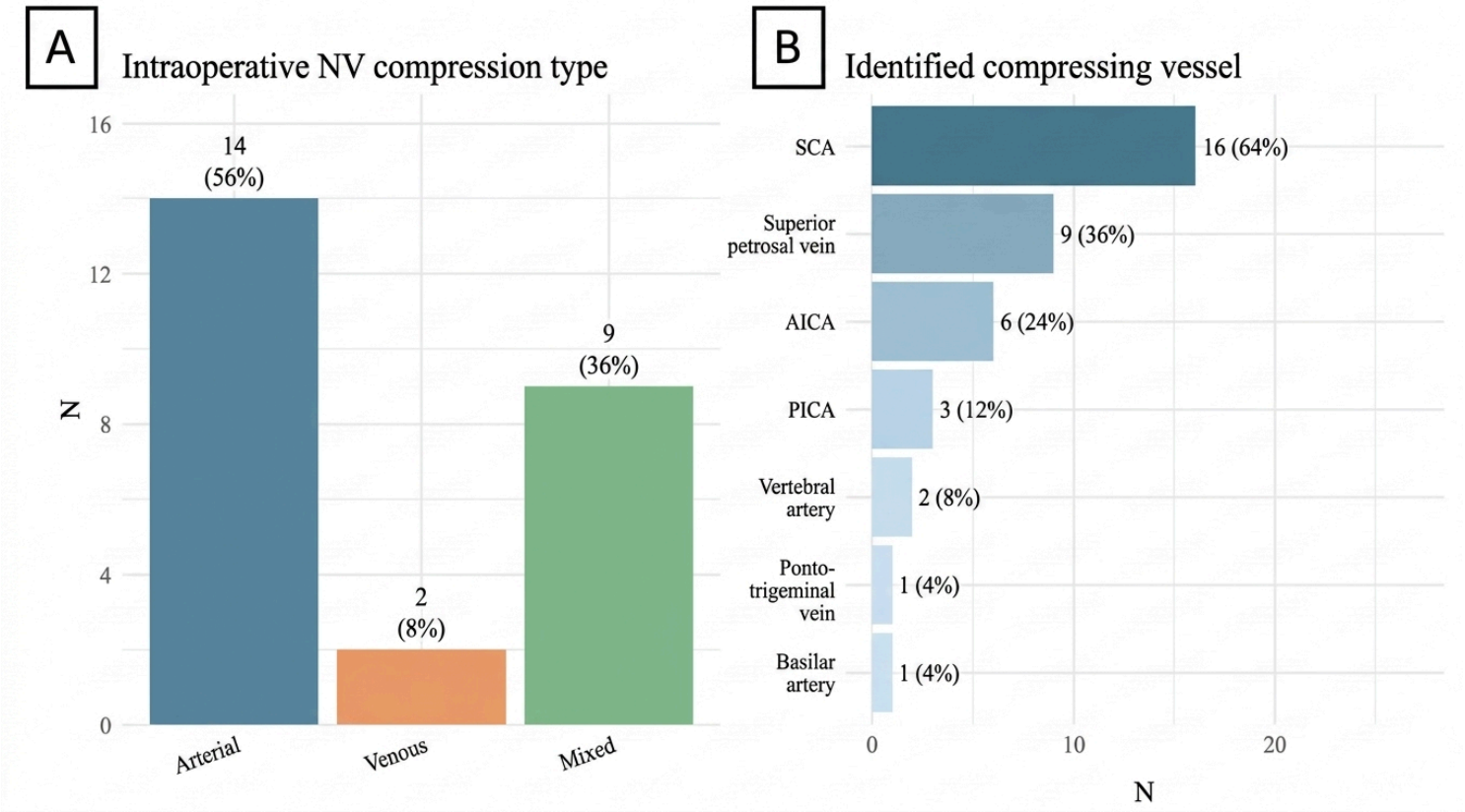

Figure 2

Characterization of Mechanical Compression. Broad categorization of the neurovascular conflict (**Figure 2A**) revealed that pure arterial compression was the most prevalent mechanism, identified in 14 cases (56%). Mixed neurovascular compression involving synchronous arterio-venous conflicts was documented in 9 patients (36%), whereas pure isolated venous compression was rare, accounting for only 2 cases (8%) within the cohort. An analysis of the specific vascular structures responsible for mechanical distortion (**Figure 2B**) identified the superior cerebellar artery (SCA) as the primary culprit vessel, contributing to the neurovascular conflict in 16 total cases (64%). The superior petrosal vein acted as a compressing element—either independently or in combination with arterial loops—in 9 cases (36%).

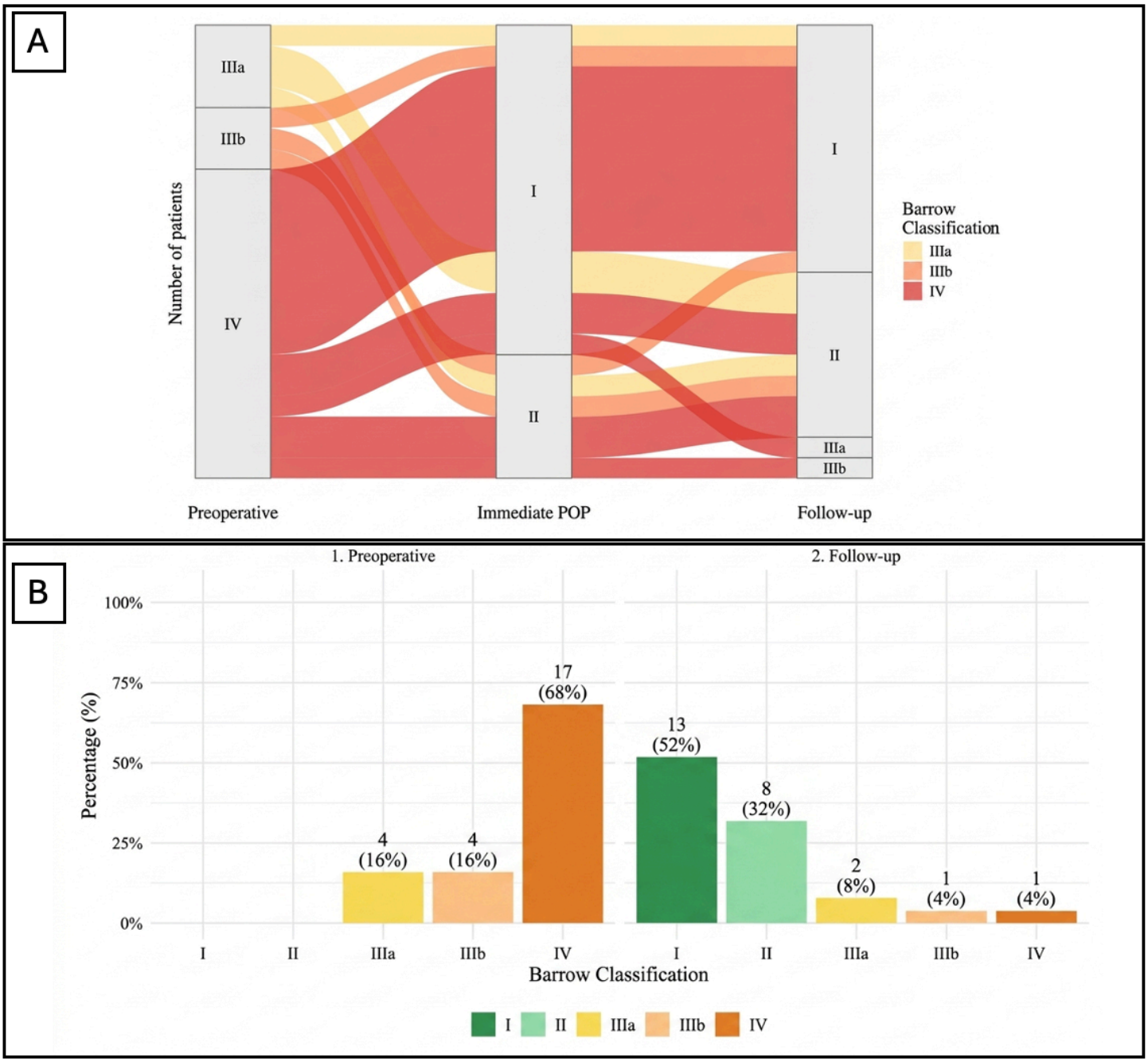

Figure 3

Longitudinal Pain Evolution and BNI Classification Transitions after MVD. (A) Sankey flow tracking showing individual clinical trajectories from baseline to long-term follow-up. **(B)** Percentage distribution of the study population across distinct BNI Classification.

SCA: superior cerebellar artery. AICA: anterior inferior cerebellar artery. PICA: posterior inferior cerebellar artery. Percentages for offending vessels are not mutually exclusive, as both primary and additional compressing vessels were recorded.

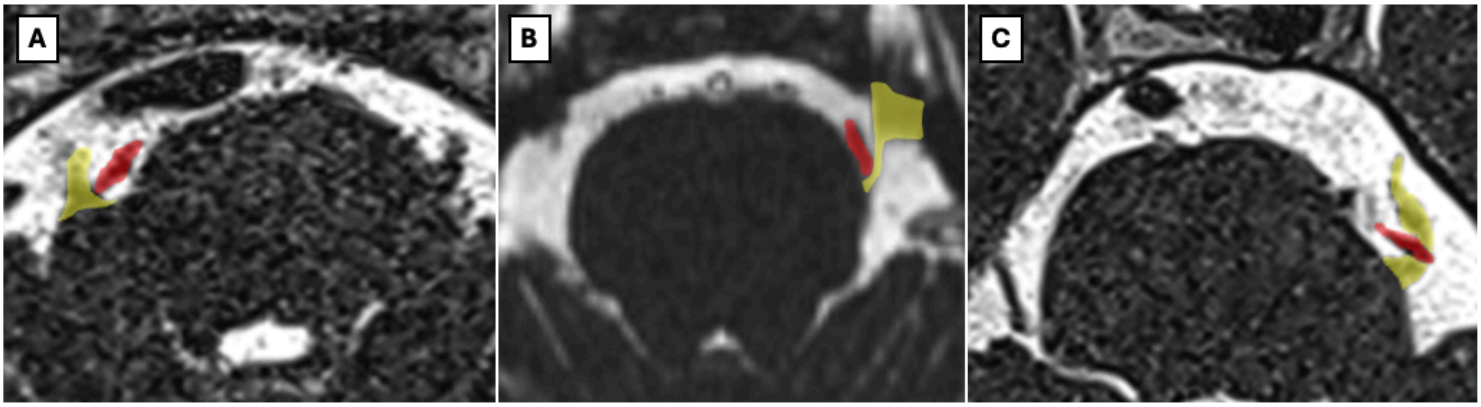

Figure 4

MRI classification of neurovascular conflict severity according to Sindou et al. Axial high-resolution MRI sequences with color-coded segmentation of the trigeminal nerve (yellow) and the offending vessel (red). The findings are graded as follows:

A. Grade I (Simple Contact): The offending vessel abuts the root entry zone (REZ) of the trigeminal nerve **without visible indentation**or deformation. **B. Grade II (Distortion):** The vascular contact results in visible **displacement and/or distortion** of the nerve root trajectory and shape. **C. Grade III (Indentation):** The vessel causes severe compression, characterized by a **marked indentation** (notching) of the nerve root at the site of conflict.

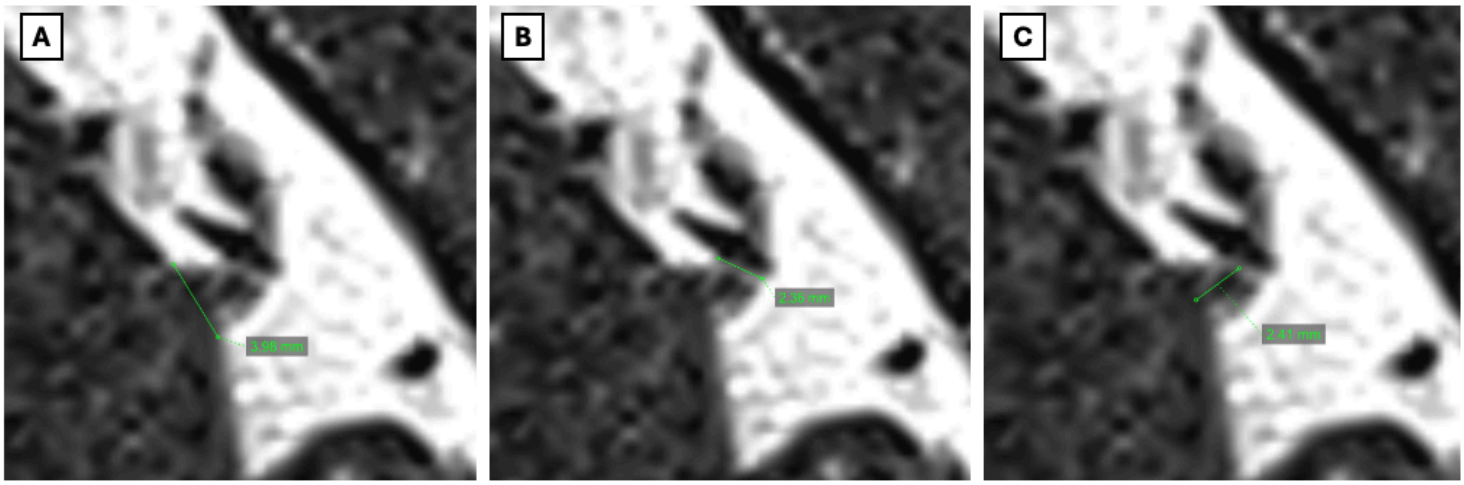

Figure 5

Neuroradiological Morphometric Analysis of the Trigeminal Nerve on the Symptomatic Side. (A) Measurement of the maximum diameter of the Root Entry Zone (REZ) in this case this diameter was 3.98 mm. (B) Maximum diameter of the nerve at the point of neurovascular contact in this case this diameter was 2.36 mm. (C) Measurement of the distance between the REZ and the site of neurovascular contact in this case this diameter was 2.41 mm.

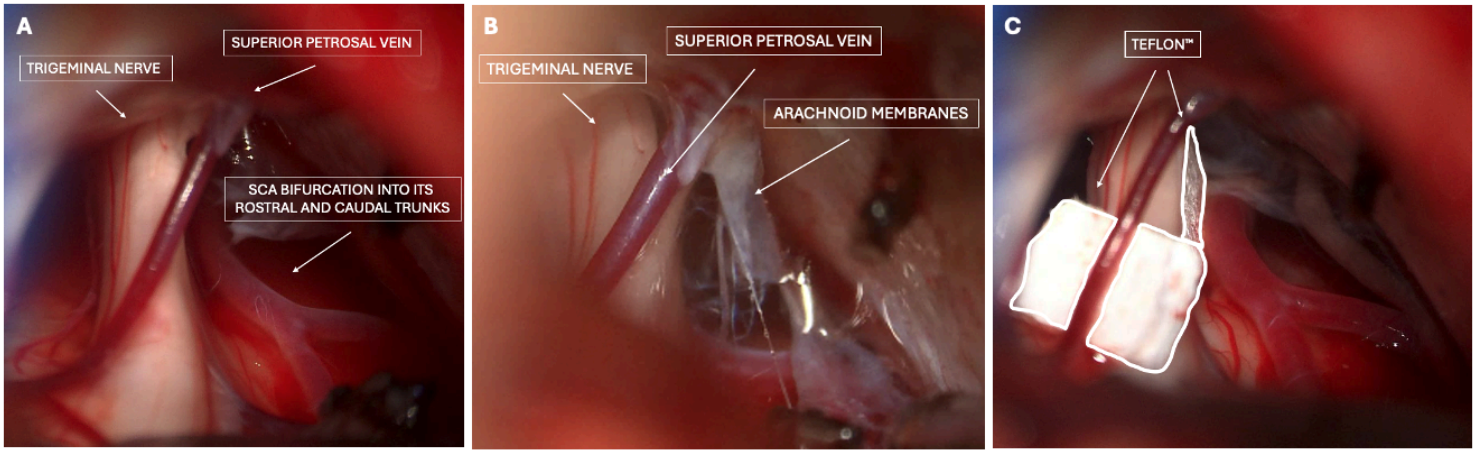

Figure 6

Intraoperative Findings and Decompression of the Trigeminal Nerve. A. Double Neurovascular Conflict: High-magnification view showing the trigeminal nerve in contact with the superior cerebellar artery (SCA) at its bifurcation into the rostral and caudal trunks. The superior petrosal vein (SPV) is also noted in contact. Contributing to the complex vascular architecture. **B. Arachnoid Compression:** Detailed view of dense arachnoid membranes and adhesions to the trigeminal nerve and the surrounding neurovascular structures. **C. Microvascular Decompression:**Final view following the transposition of the offending vessels. Two Teflon™ felt pledgets have been strategically placed to insulate the nerve from the double vascular conflict ensuring a tension-free decompression.

Supplementary Files

This is a list of supplementary files associated with this preprint. Click to download.

- 01.11.26.FIGURESANDTABLES.docx