Research Square

Preprints are preliminary reports that have not undergone peer review.
They should not be considered conclusive, used to inform clinical practice,
or referenced by the media as validated information.

ABBA - Arthroscopic Bicortical Biceps Anchorage: A Cadaveric Evaluation of Neurovascular Safety

Gert-Jan Opsomer

info@dokteropsomer.be

Ziekenhuis Oost-Limburg Genk, Orthopaedic Research Foundation

Jef Mulder

Ziekenhuis Oost-Limburg Genk, Orthopaedic Research Foundation

Ludwig Anne

Ziekenhuis Oost-Limburg Genk, Orthopaedic Research Foundation

Leen Popleu

Hasselt University

Olivier Verborgt

Antwerp University Hospital

Alexander Tongel

Ghent University Hospital

Research Article

Keywords: Arthroscopic technique, Biceps tendon, Cadaveric evaluation, Safety, Tenodesis

Posted Date: November 23rd, 2026

DOI: https://doi.org/10.21203/rs.3.rs-11576658/v1

License: This work is licensed under a Creative Commons Attribution 4.0 International License.
Read Full License

Additional Declarations: No competing interests reported.

ABBA - ARTHROSCOPIC BICORTICAL BICEPS ANCHORAGE:

A CADAVERIC EVALUATION OF NEUROVASCULAR SAFETY

Authors: Gert-Jan Opsomer[1], Jef De Mulder[1], Ludwig Anne[1], Leen Popleu[2], Olivier Verborgt[3], Alexander Van Tongel[4]

Affiliations

[1] Ziekenhuis Oost-Limburg Genk, Orthopaedic Research Foundation, Synapspark 1, 3600 Genk, Belgium

[2] Hasselt University, Faculty of Medicine and Life Sciences, Agoralaan, 3590 Diepenbeek, Belgium

[3] Antwerp University Hospital, Faculty Rehabilitation Sciences, Prinsstraat 13, 2000 Antwerpen, Belgium

[4] Ghent University Hospital, Faculty of Medicine and Health Sciences, Corneel Heymanslaan 10, 9000 Gent, Belgium

Corresponding author: Gert-Jan Opsomer, MD, Ziekenhuis Oost-Limburg Genk, Orthopaedic Research Foundation, Synapspark 1, 3600 Genk, Belgium. E-mail: info@dokteropsomer.be

1. Abstract

Purpose

The Arthroscopic Bicortical Biceps Anchorage (ABBA) technique provides subpectoral bicortical fixation of the long head of the biceps tendon (LHBT) with a cortical button. Because it requires drilling through the posterior humeral cortex, it carries a potential risk of neurovascular injury. This cadaveric study evaluated how the drilling trajectory affects the distance to the axillary nerve, radial nerve and humeral head cartilage during ABBA tenodesis.

Methods

Twenty fresh-frozen cadaveric forequarter specimens were randomly allocated to three groups based on drilling direction relative to the humeral shaft: 20° superior (n = 6), perpendicular (n = 8), and 20° inferior (n = 6). After ABBA tenodesis, the shortest distances from the cortical button to the axillary nerve, radial nerve, and humeral head cartilage margin were measured.

Results

Mean distances to the axillary nerve, radial nerve, and cartilage margin were 13.1 ± 1.6, 55.1 ± 6.6, and 22.9 ± 3.2 mm for superior angulation; 6.5 ± 1.8, 34.8 ± 7.3, and 26.3 ± 9.2 mm for perpendicular drilling; and 16.3 ± 2.8, 35.4 ± 3.7, and 43.2 ± 5.4 mm for inferior angulation. All parameters differed significantly between groups. Perpendicular drilling

placed the button significantly closer to the axillary nerve than either angulated trajectory, and inferior angulation yielded the largest distance to the cartilage margin.

Conclusion

Drilling orientation significantly influences the neurovascular safety of the ABBA technique. Inferior angulation of approximately 20° offers the most favorable balance between nerve safety and chondral avoidance.

Keywords

Arthroscopic technique

Biceps tendon

Cadaveric evaluation

Safety

Tenodesis

2. Introduction

Pathology of the long head of the biceps tendon (LHBT) is a common cause of anterior shoulder pain [5]. When conservative management fails, surgical treatment — most commonly tenotomy or tenodesis — is indicated [3, 8]. Tenotomy is technically straightforward but may result in cosmetic deformity and muscle cramping, whereas tenodesis better preserves the biceps contour and strength [16].

Multiple surgical approaches and fixation methods for LHBT tenodesis have been described, yet no single technique has demonstrated clear clinical superiority, and no universal gold standard has been established [4, 8, 10, 20]. Among the available options, subpectoral fixation within cancellous bone is conceptually regarded as an ideal location, combining strong fixation with elimination of intra-groove pathology [15, 18, 19].

The Arthroscopic Bicortical Biceps Anchorage (ABBA) technique is an arthroscopic method that achieves tenodesis of the LHBT in cancellous bone at the subpectoral level. The procedure involves the placement of a cortical button through both cortices of the humerus, allowing for secure bicortical fixation. However, the technique has a notable learning curve and carries a theoretical risk of neurovascular injury due to bicortical drilling through the posterior humeral cortex.

In the present cadaveric anatomical study, we conducted a safety analysis focusing on the posterior neurovascular structures at risk during humeral drilling. Different drilling trajectories were evaluated to identify the orientation that provides the greatest safety margin relative to the axillary, radial nerve and the articular cartilage during bicortical fixation of the long head of the biceps tendon.

3. Methods

3.1. Brief summary of the surgical technique for ABBA tenodesis

The ABBA-technique is an arthroscopic assisted approach for subpectoral biceps tenodesis using an accessory axillary portal. The patient is positioned in the beach-chair position. Four portals are used: a posterior viewing portal for diagnostic arthroscopy, an anterior working portal for tagging and tenotomy of the long head of the biceps, a lateral portal for subacromial work and final visualization, and an axillary working portal for tenodesis. Through the axillary portal, an anterior bursectomy is performed to expose the pectoralis major insertion. The bicipital sheath is incised, the tenotomized LHBT is retrieved, and the tendon is secured to a cortical button implant (Arthrex, Naples, FL, USA) using Krackow stitches. The tendon diameter is measured to determine drill size. A guide pin is then drilled from anterior to posterior through the humerus one cm inferior to the upper border of the pectoralis major tendon, followed by unicortical drilling of the anterior cortex with the appropriate drill size. The cortical button system is shuttled along the guide pin, the cortical button is flipped against the posterior cortex, and the tendon is pulled into the bone tunnel for secure fixation. This technique provides stable fixation, accurate anatomic restoration, and arthroscopic control while minimizing soft tissue dissection. For further details, see Online Resource 1.

3.2. Cadaveric study: evaluation of neurovascular risk

This cadaveric study was conducted on twenty fresh-frozen forequarter specimens obtained from the anatomy laboratory of Hasselt University (UHasselt, Belgium). Specimens without previous surgery, fracture or gross deformity of the shoulder region were included.

The specimens were randomly allocated to the three drilling groups using computer-generated randomization. Skin and subcutaneous tissue were removed down to the level of the fascia to allow enough exposure of the muscles from the shoulder region. A systematic dissection was first performed to identify relevant anatomical landmarks through a deltopectoral approach. The LHBT was then tenotomized through the rotator interval. Following this step, the insertion of the pectoralis major tendon was carefully exposed. The upper border of the pectoralis major tendon insertion was subsequently identified and used as the anatomical landmark for determining the entry point of the guide pin to create the humeral drill tunnel.

The guide pin trajectory was categorized into three groups: group one with 20° superior angulation relative to the humeral shaft, group two perpendicular to the humerus, and group three with 20° inferior angulation (Fig. 1). Once the guide pin was drilled through the humerus, the long head of the biceps tendon was attached to a cortical button implant (Arthrex, Naples, FL, USA) (Fig. 2). The tendon diameter was subsequently measured, and the corresponding drill size was used to unicortically overdrill the anterior cortex along the pre-positioned guide pin. The cortical button was subsequently shuttled through the prepared bone tunnel, and the tendon was pulled into the tunnel under controlled traction until proper tension was obtained (Fig. 3).

Following fixation, a careful posterior dissection of the humerus was performed to expose the axillary and radial nerve. The minimal distance from the cortical button to each nerve was measured with a digital caliper (Fig. 4). The humeral head was then exposed to visualize the articular cartilage, enabling measurement of the shortest distance from the button to the cartilage margin. These data were used to evaluate the spatial relationship

between button placement and nearby structures, thereby determining the safest drilling trajectory for subpectoral biceps tenodesis

3.3. STATISTICS

All statistical analyses were performed in collaboration with the Department of Statistics, Hasselt University (Belgium). A linear mixed-model analysis, with drilling direction as fixed effect and as random effect, was conducted to compare the distances between the cortical button and the surrounding anatomical structures (axillary nerve, radial nerve, and cartilage margin) across the three drilling direction groups (20° superior, perpendicular, and 20° inferior). Pairwise post-hoc comparisons were subsequently performed to identify specific intergroup differences. Statistical significance was defined at a two-tailed p-value < 0.05.

4. Results

Twenty cadaveric upper limbs were analyzed, distributed among three drilling direction groups: six with a 20° superior angulation to the humeral shaft, eight perpendicular and six with a 20° inferior angulation. All procedures allowed successful placement of the cortical button without cortical breach or implant malfunction. The minimal distances from the cortical button to the axillary nerve, radial nerve, and the humeral head cartilage margin were measured for each specimen.

For the superior angulation group, the mean distance to the axillary nerve was 13.1 ± 1.6 mm, to the radial nerve 55.1 ± 6.6 mm, and to the cartilage margin 22.9 ± 3.2 mm. In the perpendicular group, corresponding distances were 6.5 ± 1.8 mm, 34.8 ± 7.3 mm, and 26.3

142 ± 9.2 mm, respectively. In the inferior angulation group, the mean distances were 16.3 ±
143 2.8 mm to the axillary nerve, 35.4 ± 3.7 mm to the radial nerve, and 43.2 ± 5.4 mm to the
144 cartilage margin (Table 1) (Fig. 5).

145 A mixed-model analysis demonstrated a statistically significant difference between the
146 three groups for all measured parameters: distance to the axillary nerve ($p = 0.002$), radial
147 nerve ($p = 0.0003$), and cartilage margin ($p = 0.0002$). Pairwise post-hoc analysis of the
148 mixed model revealed significant differences between several drilling directions. For the
149 axillary nerve, the perpendicular group showed significantly smaller distances compared
150 with both the inferior ($p = 0.0001$) and superior ($p = 0.0045$) orientations, while the
151 difference between inferior and superior angulation was not statistically significant ($p =$
152 0.0625). Regarding the radial nerve, both the inferior ($p = 0.0001$) and perpendicular ($p =$
153 0.0004) groups were significantly closer than the superior group, whereas the perpendicular
154 and inferior orientations did not differ ($p = 0.8561$). For the cartilage margin, significant
155 differences were found between the inferior group and both the perpendicular ($p = 0.0009$)
156 and superior ($p = 0.0002$) groups, with no difference between the perpendicular and
157 superior directions ($p = 0.4673$).

158 ## 5. Discussion

159 Biceps tenodesis (BT) is a well-established and effective surgical technique for the
160 management of long head of the biceps tendon pathology [3]. Although clinical outcomes
161 are generally favorable, several tenodesis locations have been described, each associated
162 with specific risks and potential neurovascular injury [11, 13].

163 ### 5.1. Literature review

164 Bicortical BT techniques that involve perforation of the posterior humeral cortex have
165 raised concern regarding the proximity of the drill trajectory and fixation device to
166 surrounding neurovascular structures. Arora et al., who included bicortical suspensory
167 button groups in their biomechanical comparison, found the axillary nerve at a mean
168 distance of only 7.8 mm from the bicortical button, with several specimens within 3 mm
169 of the nerve, and concluded that bicortical fixation at this level puts the axillary nerve at
170 risk [2]. In contrast, Pinedo et al. observed a considerably greater mean distance between
171 the axillary nerve and the posterior exit point (38.8 ± 8.7 mm), suggesting that nerve
172 proximity varies depending on drilling technique and anatomical reference points [12].
173 This variability among studies likely reflects the heterogeneity of anatomical landmarks
174 used to guide BT, which may account for the broad range of reported distances to
175 neurovascular structures. To address these inconsistencies, we compiled a summary table
176 including comparable studies and the results of the present study for direct comparison [1,
177 2, 6, 7, 9, 12, 14, 17] (Table 2).

178 ### 5.2. Axillary nerve

When applying rigorous inclusion criteria restricted to studies with comparable entry points, drilling trajectories, and measurements of the axillary nerve distance, the work by Lancaster et al. appears most analogous to the present study. In our perpendicular drilling group, the mean distance to the axillary nerve was 6.5 ± 1.8 mm, closely corresponding with Lancaster et al. 10.7 ± 3.5 mm [9]. Similarly, Abraham et al. and Chernchujit et al. reported mean distances of 17.7 ± 2.4 mm and 10.6 ± 2.9 mm, respectively [1, 6]. These findings collectively confirm that the axillary nerve lies in close proximity to the posterior cortex during bicortical fixation, particularly with perpendicular drilling.

5.3. RADIAL NERVE

Multiple studies have evaluated the relationship between the drill trajectory and the radial nerve, with reported distances ranging from 10.4 mm to 48.0 mm [6, 7, 14, 17]. When limiting comparison to studies employing a similar entry point and drilling direction, the investigations by Saithna et al. 26.2 ± 7.0 mm and Sethi et al. 48.0 ± 10.7 mm are the most relevant [14, 17]. This closely corresponds with our result of 34.8 ± 7.3 mm. Although these values have a broad spectrum, the collective evidence suggests that the radial nerve remains at a safe distance during bicortical BT, irrespective of drilling orientation.

5.4. CLINICAL RELEVANCE AND SURGICAL IMPLICATIONS

The present findings have important clinical implications for optimizing the safety of bicortical subpectoral biceps tenodesis. Among the drilling orientations evaluated, both superior and inferior trajectories increased the distance to the axillary nerve compared with

perpendicular drilling. However, superior angulation resulted in the smallest distance to the humeral head cartilage, whereas only inferior angulation significantly increased this distance compared with both other trajectories. A superiorly directed tunnel may therefore increase the risk of chondral injury. Considering all measured parameters, inferior angulation provided the most favorable safety profile, maintaining adequate clearance from the axillary nerve while avoiding proximity to the cartilage margin. Although inferior angulation directs the drill trajectory slightly closer toward the radial nerve, this difference was not statistically significant compared with perpendicular drilling. These results suggest that an inferiorly oriented bicortical technique offers the best balance for neurovascular safety.

5.5. LIMITATIONS

This study has several limitations that should be acknowledged. First, as with all cadaveric investigations, soft-tissue dissection may alter the native spatial relationships between neurovascular structures and the bone surface, potentially leading to overestimation of the true distances. Second, both male and female specimens were used, and anatomical variation between sexes—particularly in humeral size and soft-tissue volume—may have influenced the measured distances. Third, measurements were obtained in a static cadaveric setting with a single arm position; in vivo variability related to arm rotation, abduction or muscle tension could not be assessed. Additionally, differences in humeral morphology and specimen age were not controlled for, which may further affect the generalizability of the findings. Finally, this study focused solely on anatomical safety and did not evaluate the biomechanical performance or clinical outcomes associated with the different drilling

orientations. Despite these limitations, the consistent methodology and statistically significant results provide valuable anatomical insight that may guide safer surgical practice and inform future biomechanical and clinical research.

6. Conclusion

In summary, this cadaveric analysis confirms that drilling orientation significantly influences the neurovascular safety of the ABBA technique. Inferior angulation of approximately 20° relative to the humeral shaft provides the most favorable drill trajectory in avoidance of neurovascular injury. These findings may serve as a practical reference for surgeons adopting arthroscopic bicortical biceps tenodesis and contribute to the standardization and safety of this promising technique.

7. Acknowledgments

The authors would like to express their gratitude to everyone who contributed to the development of this research. We particularly thank our colleagues and collaborators for their valuable insights and constructive feedback throughout the project.

We also acknowledge the support of the technical staff and the facilities provided by Hasselt University.

The authors sincerely thank those who donated their bodies to science so that anatomical research could be performed. Results from such research can potentially increase mankind's overall knowledge that can then improve patient care. Therefore, these donors and their families deserve our highest gratitude.

8. Statements and Declarations

Funding: This study was supported in part by the Orthopaedic Research Foundation Genk.

Competing interests: The authors have no relevant financial or non-financial interests to disclose.

Ethics approval: Not applicable. This study was performed exclusively on bodies donated to science. Under Belgian legislation, anatomical research on donated cadavers does not require approval by an ethics committee.

Consent to participate: All specimens were obtained through the body donation program of Hasselt University. The donors provided written informed consent during life for the use of their bodies for education and research.

Consent to publish: Not applicable; no identifying information of the donors is included in this article.

Data availability: The datasets generated and analysed during the current study are available from the corresponding author on reasonable request.

Author contributions:

G-J Opsomer: [Protocol/project development, Data collection or management, Data analysis, Manuscript writing/editing]; J De Mulder: [Data collection or management]; L Anne: [Data collection or management, Manuscript writing/editing]; L Popleu: [Data collection or management]; O Verborgt: [Protocol/project development, Manuscript

writing/editing]; A Van Tongel: [Protocol/project development, Manuscript writing/editing]

9. Online resource, figure and table captions

ONLINE RESOURCE

Online Resource 1 ABBA – Arthroscopic Bicortical Biceps Anchorage: video of the surgical technique

FIGURES

Fig. 1 Entry site of the guide pin in relation to the pectoralis major tendon insertion. The entry point was positioned one cm inferior to the superior border of the pectoralis major insertion. Three drilling orientations were evaluated in this study: 20° superior angulation, perpendicular to the humeral shaft, and 20° inferior angulation

Fig. 2 The cortical button system Type II RT ART1588RT-2J (Arthrex, Naples, FL, USA) secured to the long head of the biceps tendon (LHBT) using Krackow sutures

Fig. 3 Final position of the biceps tendon following tunneling through the humeral drill hole from anterior to posterior. The tendon is drawn intramedullary, one cm inferior to the superior border of the pectoralis major insertion. The native muscle–tendon length relationship is preserved, with the musculotendinous junction aligned approximately at its original level

Fig. 4 Posterior dissection following completion of the ABBA biceps tenodesis technique. The axillary and radial nerves were exposed and marked for measurement. The image

demonstrates the distance between the cortical button and the axillary nerve, measured with a digital caliper. The axillary nerve is positioned superior to the cortical button along the posterior aspect of the humerus if the drill trajectory is perpendicular

Fig. 5 Schematic representation of the distance from each drill path to the cartilage edge and the axillary nerve. PM pectoralis major, CE cartilage edge, AN axillary nerve

TABLES

Table 1 Mean distance to clinically relevant structures according to drill trajectory group

Table 2 Summary of comparable studies and the results of the present study

10. References

1. Abraham MJ, Amaravathi RS, Tamboowalla KB, Pilar A, Kany J, Krishnamurthy SL, Sekaran P, Luke DI (2023) The proximity of the axillary nerve during keyhole tenodesis of the long head of the biceps tendon: a cadaveric study. Indian J Orthop 57:284–289. https://doi.org/10.1007/s43465-022-00783-5

2. Arora AS, Singh A, Koonce RC (2013) Biomechanical evaluation of a unicortical button versus interference screw for subpectoral biceps tenodesis. Arthroscopy 29:638–644. https://doi.org/10.1016/j.arthro.2012.11.018

3. Belk JW, Kraeutler MJ, Houck DA, Chrisman AN, Scillia AJ, McCarty EC (2021) Biceps tenodesis versus tenotomy: a systematic review and meta-analysis of level I

randomized controlled trials. J Shoulder Elbow Surg 30:951–960. https://doi.org/10.1016/j.jse.2020.11.012

4. Belk JW, Thon SG, Hart J, McCarty EC, McCarty EC (2021) Subpectoral versus suprapectoral biceps tenodesis yields similar clinical outcomes: a systematic review. J ISAKOS 6:356–362. https://doi.org/10.1136/jisakos-2020-000543

5. Chen CH, Hsu KY, Chen WJ, Shih CH (2005) Incidence and severity of biceps long head tendon lesion in patients with complete rotator cuff tears. J Trauma 58:1189–1193. https://doi.org/10.1097/01.ta.0000170052.84544.34

6. Chernchujit B, Chiarnpattanodom A, Agrawal S (2023) Bi-cortical transhumeral drilling for biceps tenodesis – is it safe? Asia Pac J Sports Med Arthrosc Rehabil Technol 31:1–5. https://doi.org/10.1016/j.asmart.2022.12.001

7. Ding DY, Gupta A, Snir N, Wolfson T, Meislin RJ (2014) Nerve proximity during bicortical drilling for subpectoral biceps tenodesis: a cadaveric study. Arthroscopy 30:942–946. https://doi.org/10.1016/j.arthro.2014.03.026

8. Hsu AR, Ghodadra NS, Provencher MT, Lewis PB, Bach BR (2011) Biceps tenotomy versus tenodesis: a review of clinical outcomes and biomechanical results. J Shoulder Elbow Surg 20:326–332. https://doi.org/10.1016/j.jse.2010.08.019

9. Lancaster S, Smith G, Ogunleye O, Packham I (2016) Proximity of the axillary nerve during bicortical drilling for biceps tenodesis. Knee Surg Sports Traumatol Arthrosc 24:1925–1930. https://doi.org/10.1007/s00167-014-3214-z

10. Mazzocca AD, Bicos J, Santangelo S, Romeo AA, Arciero RA (2005) The biomechanical evaluation of four fixation techniques for proximal biceps tenodesis. Arthroscopy 21:1296–1306. https://doi.org/10.1016/j.arthro.2005.08.008

11. McCrum CL, Alluri RK, Batech M, Mirzayan R (2019) Complications of biceps tenodesis based on location, fixation, and indication: a review of 1526 shoulders. J Shoulder Elbow Surg 28:461–469. https://doi.org/10.1016/j.jse.2018.09.005

12. Pinedo M, Calvo C, Ekdahl M, Gutierrez V (2020) Suprapectoral biceps tenodesis with bicortical drilling procedures: anatomic analysis of chondral and axillary nerve risk with transhumeral pin guide. J Shoulder Elbow Surg 29:1435–1439. https://doi.org/10.1016/j.jse.2019.12.010

13. Rhee PC, Spinner RJ, Bishop AT, Shin AY (2013) Iatrogenic brachial plexus injuries associated with open subpectoral biceps tenodesis: a report of 4 cases. Am J Sports Med 41:2048–2053. https://doi.org/10.1177/0363546513495646

14. Saithna A, Longo A, Jordan RW, Leiter J, MacDonald P, Old J (2017) A cadaveric assessment of the risk of nerve injury during open subpectoral biceps tenodesis using a bicortical guidewire. Knee Surg Sports Traumatol Arthrosc 25:2858–2863. https://doi.org/10.1007/s00167-015-3972-2

15. Sanders B, Lavery KP, Pennington S, Warner JJP (2012) Clinical success of biceps tenodesis with and without release of the transverse humeral ligament. J Shoulder Elbow Surg 21:66–71. https://doi.org/10.1016/j.jse.2011.01.037

16. Selman F, Audigé L, Mueller AM, Wieser K, Grubhofer F (2025) The impact of biceps tenotomy/tenodesis on Popeye sign incidence and functional outcome. JSES Int 9:373–379. https://doi.org/10.1016/j.jseint.2024.10.015

17. Sethi PM, Vadasdi K, Greene RT, Vitale MA, Duong M, Miller SR (2015) Safety of open suprapectoral and subpectoral biceps tenodesis: an anatomic assessment of risk for neurologic injury. J Shoulder Elbow Surg 24:138–142. https://doi.org/10.1016/j.jse.2014.06.038

18. Tan H, Wang D, Lebaschi AH, Hutchinson ID, Ying L, Deng XH, Rodeo SA, Warren RF (2018) Comparison of bone tunnel and cortical surface tendon-to-bone healing in a rabbit model of biceps tenodesis. J Bone Joint Surg Am 100:479–486. https://doi.org/10.2106/JBJS.17.00797

19. van Deurzen DFP, Gurnani N, Alta TDW, Willems JH, Onstenk R, van den Bekerom MPJ (2020) Suprapectoral versus subpectoral tenodesis for long head biceps brachii tendinopathy: a systematic review and meta-analysis. Orthop Traumatol Surg Res 106:693–700. https://doi.org/10.1016/j.otsr.2020.01.004

20. Werner BC, Evans CL, Holzgrefe RE, Tuman JM, Hart JM, Carson EW, Diduch DR, Miller MD, Brockmeier SF (2014) Arthroscopic suprapectoral and open subpectoral biceps tenodesis: a comparison of minimum 2-year clinical outcomes. Am J Sports Med 42:2583–2590. https://doi.org/10.1177/0363546514547226



Fig. 1: Entry site of the guide pin in relation to the pectoralis major tendon insertion. The entry point was positioned one cm inferior to the superior border of the pectoralis major insertion. Three drilling orientations were evaluated in this study: 20° superior angulation, perpendicular to the humeral shaft, and 20° inferior angulation.

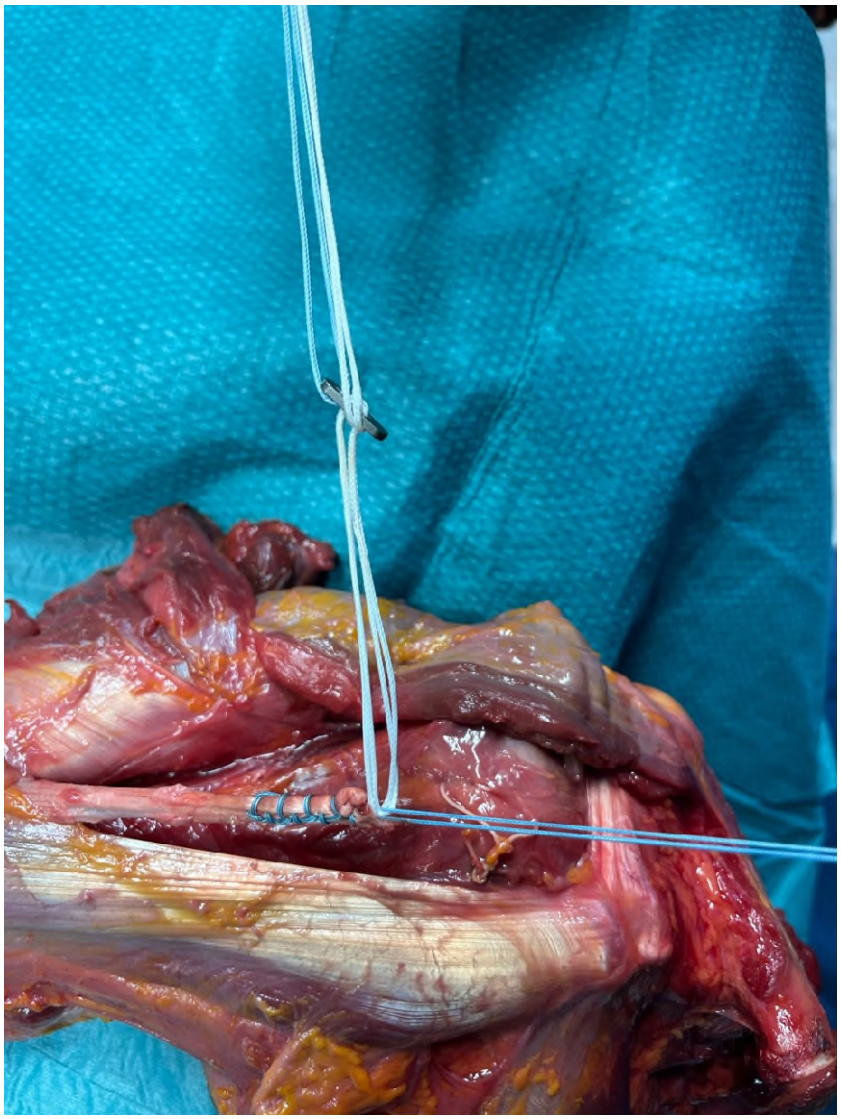

Fig. 2: The cortical button system Type II RT ART1588RT-2J (Arthrex, Naples, FL, USA) secured to the long head of the biceps tendon (LHBT) using Krackow sutures.

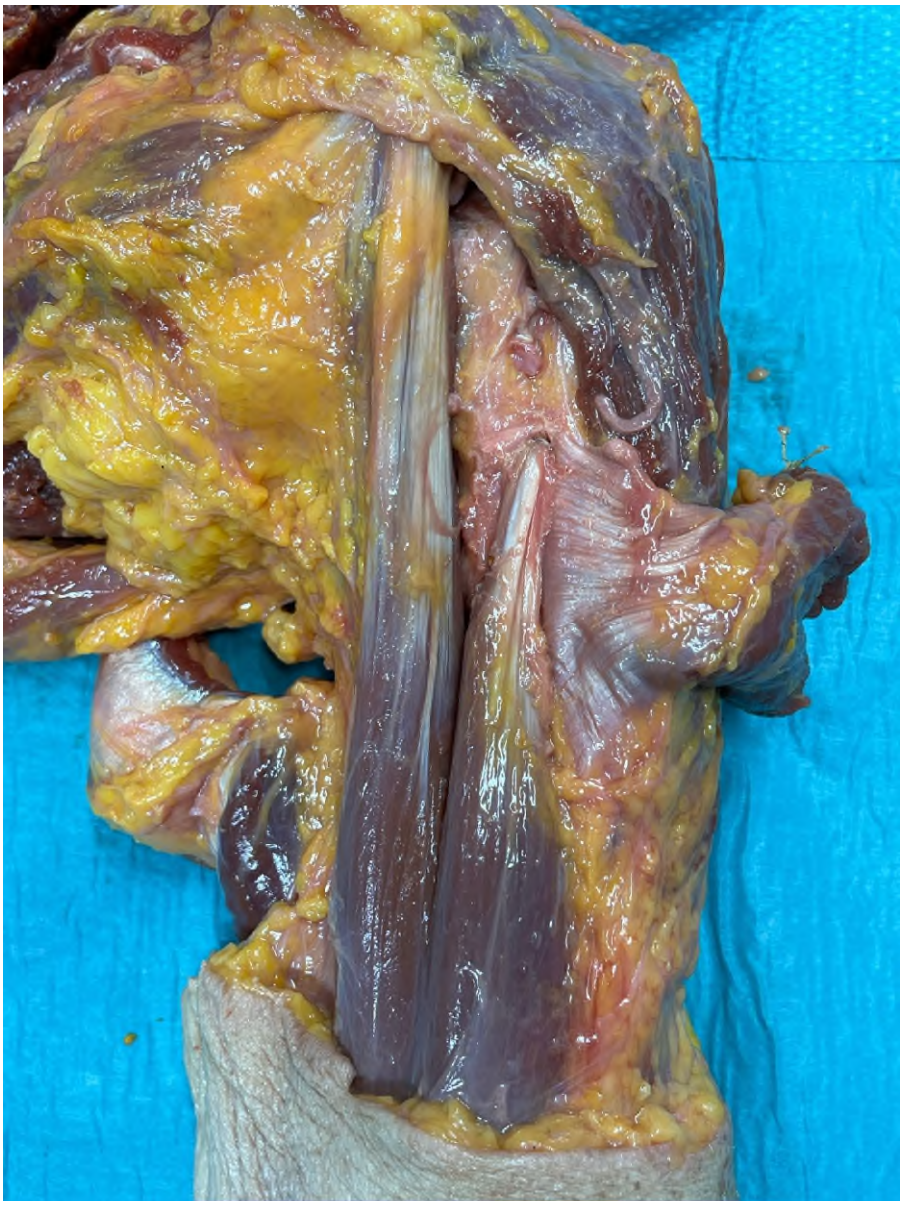

Fig. 3: Final position of the biceps tendon following tunneling through the humeral drill hole from anterior to posterior. The tendon is drawn intramedullary, one cm inferior to the superior border of the pectoralis major insertion. The native muscle–tendon length relationship is preserved, with the musculotendinous junction aligned approximately at his original level.

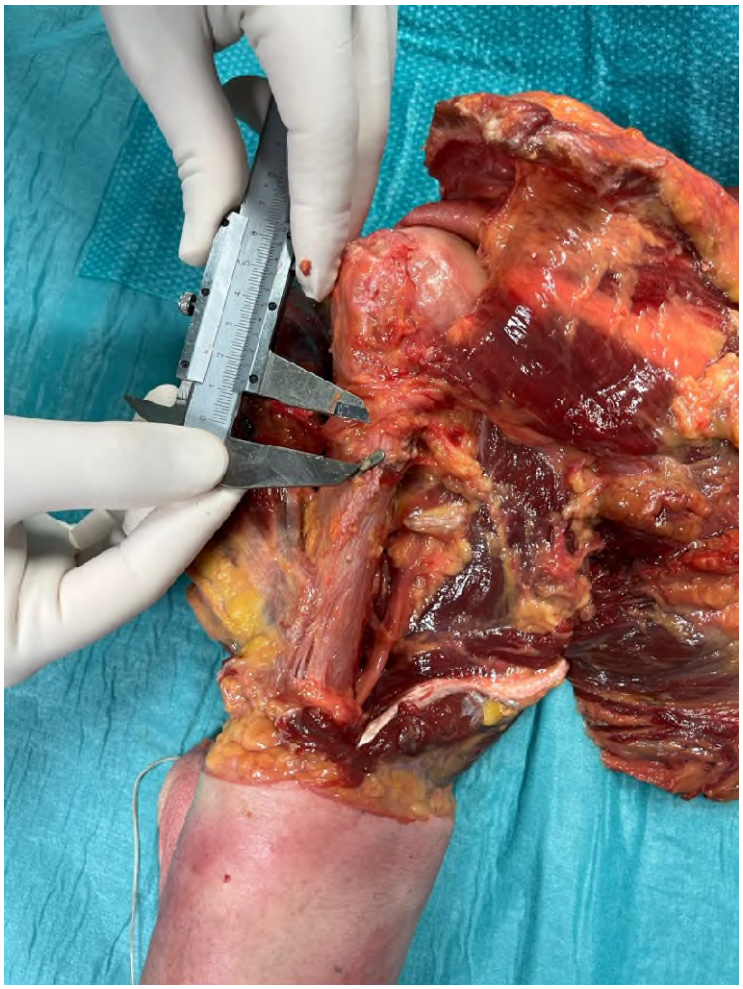

Fig. 4: Posterior dissection following completion of the ABBA biceps tenodesis technique. The axillary and radial nerves were exposed and marked for measurement. The image demonstrates the distance between the cortical button and the axillary nerve, measured with a digital caliper. The axillary nerve is positioned superior to the cortical button along the posterior aspect of the humerus if the drill trajectory is perpendicular.

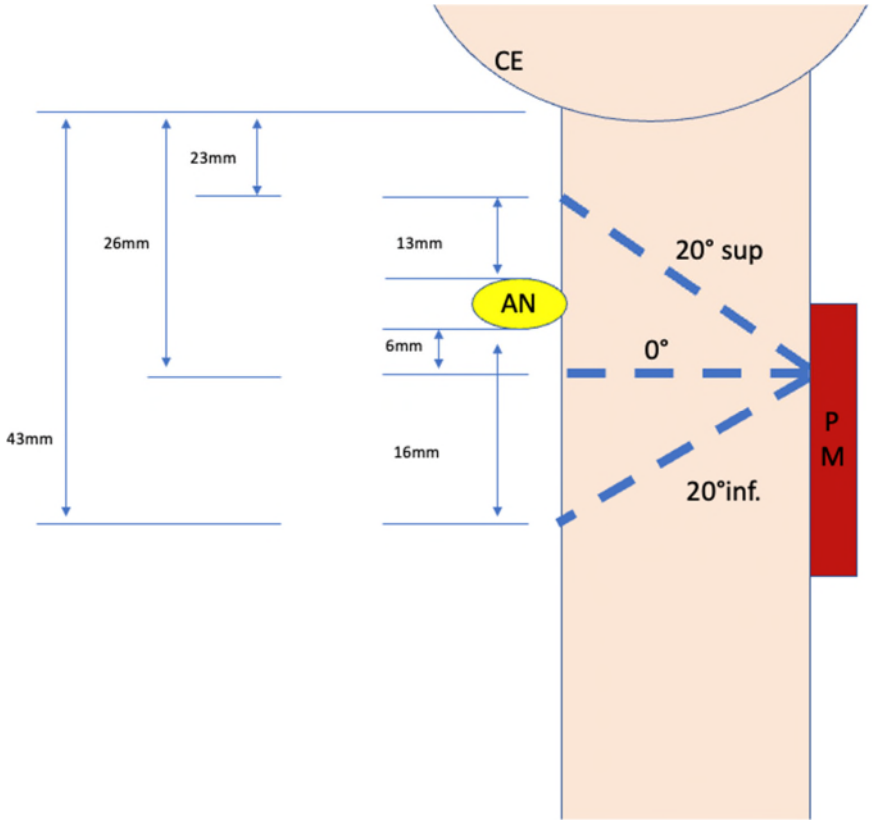

Fig. 5: The figure provides a schematic representation of how far each drill path is from the cartilage edge and the axillary nerve.
(PM : Pectoralis major ; CE : Cartilage Edge ; AN : axillary nerve)

	Distance (mean ± SD) (mm):		
Direction:	Axillary nerve:	Radial nerve:	Cartilage border:
20° cranial	13.2 ± 1.6	55.1 ± 6.6	22.9 ± 3.2
perpendicular	6.5 ± 1.8	34.8 ± 7.3	26.3 ± 9.2
20° caudal	16.3 ± 2.8	35.4 ± 3.7	43.2 ± 5.4
p=	0,0002	0,0003	0,0002

Table 1: Mean distance to clinical relevant structures in function of the drill trajectory group.

Authors:	Entry point:	Drill angle:	Distance to (mm): Axillary nerve:	Radial nerve:	Cartilage border:
Abraham et al. (n=10) [1] 2022	Upper border PM *(subpectoral)*	10° cranial	17.70 ± 2.40	NA	NA
Chernchujit et al. (n=10) [7] 2023	Upper border PM *(subpectoral)*	perpendicular	*75% superior to nerve:* 10.55 ± 2.87 *20% inferior to nerve:* 9.13 ± 6.15 *5% direct contact*	NA	NA
	Lower border PM *(subpectoral)*	perpendicular	NA	10.41 ± 2.18	NA
Pinedo et al. (n=10) [14] 2020	15 mm inferior to top BG *(suprapectoral)*	perpendicular	38.8 ± 8.7	NA	16.7 ± 3.9
		10° caudal	28.9 ± 7.8	NA	9.8 ± 3.7
		20° caudal	18.8 ± 10.7	NA	6.1 ± 4.8
Saithna et al. (n=10) [16] 2017	1cm superior to lower border PM *(subpectoral)*	perpendicular	15.7 ± 3.4	26.2 ± 7	NA
Lancaster et al. (n=12) [11] 2016	Upper border PM *(subpectoral)*	perpendicular	10.7 ± 3.5	NA	NA
Sethi et al. (n=10) [19] 2015	1cm superior to lower border PM (subpectoral)	perpendicular	36.7 ± 11.2	48.0 ± 10.7	NA
		30° cranial	24.1 ± 11.2	NA	NA
	1 cm superior to upper border PM (suprapectoral)	perpendicular	10.5 ± 5.5	41.3 ± 9.3	NA
Ding et al. (n=6) [9] 2014	Lower border PM *(subpectoral)*	perpendicular	25.10 ± 3.50	30.30 ± 3.10	NA
Arora et al. (n=6) [2] 2013	4 cm inferior lesser tubercle *(suprapectoral)*	perpendicular	2.14 ± 2.04	10.79 ± 2.45	NA
Current study (n=20) 2025	Upper border PM *(subpectoral)*	20° cranial	13.15 ± 1.60	55.13 ± 6.57	22.9 ± 3.17
		perpendicular	6.53 ± 1.76	34.8 ± 7.31	26.25 ± 9.15
		20° caudal	16.26 ± 2.76	35.39 ± 3.69	43.23 ± 5.40

Table 2: A table of summary including comparable studies and the results of the present study for direct comparison.

Supplementary Files

This is a list of supplementary files associated with this preprint. Click to download.

- ABBAvideoSD480p.mov