Research Square

Preprints are preliminary reports that have not undergone peer review.
They should not be considered conclusive, used to inform clinical practice,
or referenced by the media as validated information.

When 6-mL is too much: transient retinal striae after peribulbar block, a case report

Taufan Pramadika[1]

taufanpramadikamd@lecturer.undip.ac.id

Universitas Diponegoro

Mochamat Mochamat[1]

Universitas Diponegoro

Taufik Saputra[1]

Universitas Diponegoro

Vito Etenio[1]

Universitas Diponegoro

Jennefer Jennefer[1]

Universitas Diponegoro

Afrisal Hari Kurniawan[2]

JEC Semarang Eye Hospital

Case Report

Keywords: Case report, Peribulbar anesthesia, Chorioretinal folds, Intraocular pressure, Orbital compliance, Vitrectomy

Posted Date: November 26th, 2026

DOI: https://doi.org/10.21203/rs.3.rs-11575628/v1

License: This work is licensed under a Creative Commons Attribution 4.0 International License.
Read Full License

Additional Declarations: No competing interests reported.

Abstract

Background

Peribulbar anesthesia is widely used for vitreoretinal surgery, yet the orbital volume tolerance varies between patients. Retinal striae resulting from orbital overfilling after a peribulbar block have rarely been described, and guidance on repeat anesthesia on the same eye following such an event remains limited.

Case presentation:

A 65-year-old Indonesian woman of East Asian descent with hypertension, pseudophakia, and progressive cystoid macular edema in the right eye was scheduled for vitrectomy under peribulbar anesthesia with sedation. Central retinal thickness had increased from 205 to 322 μm and visual acuity had fallen from 0.40 to 0.10 over four months. She had narrow palpebral fissures with upper eyelid hooding. On the first attempt, a 6-mL block (4 mL of 0.5% bupivacaine and 2 mL of 2% lidocaine) resulted in orbital tension, conjunctival chemosis, and a rise in intraocular pressure from 16.3 to 24 mmHg. After vitrectomy began, the surgeon observed retinal striae, prompting discontinuation of the procedure. Four days later the striae had resolved, and surgery was repeated with a reduced volume of 4-mL (3 mL of 0.5% bupivacaine and 1 mL of 2% lidocaine) injected slowly in small increments. Orbital tension was palpated, and the adequacy of anesthesia and motor block was assessed between increments. The revised block provided adequate akinesia and analgesia without chemosis, and a 25-gauge vitrectomy was completed without complications. At the 65-day follow-up, intraocular pressure was 14 mmHg, and uncorrected visual acuity had improved to 0.33.

Conclusions

In this patient, 6-mL volume exceeded orbital tolerance and caused transient retinal striae, whereas a smaller incremental block titrated to the clinical response was sufficient. A single case cannot define safe volumes, but it supports an approach in which peribulbar injection is guided by the orbital response rather than by a fixed volume.

Background

Peribulbar anesthesia remains a mainstay of vitreoretinal surgery because it provides akinesia and analgesia while allowing elderly patients with systemic disease to avoid general anesthesia [1]. Serious complications are rare. In a network that performed local anesthetic blocks in more than 280,000 patients over eight years, retrobulbar hemorrhage occurred in 0.037% of cases, while globe perforation occurred in 0.004% [2]. Minor events are far more common. In one comparative series, chemosis occurred following 57.0% of conventional peribulbar blocks, and intraocular pressure increased after the

block in 5.6% of cases [3]. Between these extremes lies a less well-described problem: an orbit that is simply overfilled.

The orbit is a closed compartment; thus, additional injected volume may increase orbital tension. Volumes of 4 to 7 mL are standard for vitreoretinal surgery [4, 5], and some centers adjust the volume to axial length [5]. A recent randomized trial comparing 4-mL and 7-mL blocks found no significant difference in mean intraocular pressure after the block. However, intraocular pressure values showed considerable variability, with a standard deviation of almost 9 mmHg in the larger volume group [6]. Mean values therefore obscure individual patients whose orbits cannot absorb the injected volume. When this occurs, the consequences can be serious; orbital compartment syndrome with intermittent central retinal artery nonperfusion has been reported after injection of as little as 3.5 mL by the sub-Tenon route [7].

Chorioretinal folds are a recognized sign of mechanical stress on the posterior globe and are described in correlation with orbital masses, thyroid eye disease, and scleral buckling [8]. However, they are rarely reported as a consequence of a local anesthetic block. We report transient retinal striae after a 6-mL peribulbar block in a patient with narrow palpebral fissures and the uneventful completion of surgery four days later with a 4-mL block injected incrementally under continuous assessment. The case is reported in accordance with the CARE guidelines.

Case presentation

A 65-year-old Indonesian woman of East Asian descent with hypertension presented to our vitreoretinal clinic with decreased vision in the right eye. The right eye was pseudophakic, and both eyes had a posterior vitreous detachment. Best-corrected visual acuity was 0.50 in the right eye (sphere 0.00, cylinder −0.75 at 90°, and no improvement with pinhole) and 1.00 in the left eye. Intraocular pressure measured by non-contact tonometry was 19 mmHg in the right eye and 18 mmHg in the left eye, and central corneal thickness in the right eye was 533 µm. External examination showed narrow palpebral fissures in both eyes, with upper eyelid skin hooding that further reduced the vertical aperture (Figure 2).

Spectral-domain optical coherence tomography (Topcon 3D OCT, 7×7 mm macular cube) at presentation showed small hyporeflective intraretinal cysts at the fovea of the right eye, with a center thickness of 205 µm and a central subfield thickness of 235 µm, compared with 155 µm and 213 µm in the left eye. At the five-week follow-up, the edema had progressed: large cystoid spaces distorted the foveal contour on the vertical scan, smaller parafoveal cysts were visible on the horizontal scan, and the center thickness had increased to 322 µm, with a central subfield thickness of 320 µm, above the 99th percentile of the device's normative database. The left eye was unchanged, with a center thickness of 162 µm. On both scans, the retinal pigment epithelium was smooth, with no undulation to suggest chorioretinal folds (Figure 1).

Over the follow-up period, uncorrected visual acuity in the right eye declined from 0.40 to 0.33, 0.30, and 0.10, while intraocular pressure remained between 12 and 14 mmHg. With a diagnosis of cystoid

macular edema and progressive visual loss, pars plana vitrectomy with internal limiting membrane (ILM) peeling of the right eye was planned under peribulbar anesthesia with intravenous sedation as a day-case procedure.

Preoperative blood tests showed a hemoglobin of 13.2 g/dL, a leukocyte count of 7.3 × 10^3/μL, a platelet count of 333 × 10^3/μL, a random glucose of 107 mg/dL, a urea of 29 mg/dL, and a creatinine of 1.04 mg/dL. Sodium, potassium, chloride, and ionized calcium were within normal limits, bleeding and clotting times were normal, and hepatitis B surface antigen and anti-hepatitis C antibody were nonreactive. The electrocardiogram showed sinus rhythm at 72 beats per minute, a PR interval of 155 ms, a QRS duration of 90 ms, and a corrected QT of 431 ms, with low voltage in the chest leads; it was reported as borderline normal.

First procedure. Intraocular pressure in the right eye on the afternoon of surgery was 16.3 mmHg, measured by non-contact tonometry. The block consisted of 4-mL of 0.5% bupivacaine (20 mg) and 2-mL of 2% lidocaine (40 mg), a total of 6-mL with final concentrations of approximately 0.33% bupivacaine and 0.67% lidocaine, injected with our standard peribulbar technique. Shortly afterwards, the orbit became clinically tense and full, conjunctival chemosis occurred, and intraocular pressure increased to 24 mmHg. Vitrectomy was initiated, but on viewing the fundus through the operating microscope the vitreoretinal surgeon identified retinal striae across the posterior pole, which were recorded in the operative notes and had not been present on any previous examination. The procedure was discontinued because of the elevated intraocular pressure and the striae, and surgery was rescheduled.

Second procedure. Four days later, the striae had resolved, and intraocular pressure on the morning of surgery was 13.3 mmHg by non-contact tonometry. The block volume was reduced to 4-mL, consisting of 3-mL of 0.5% bupivacaine (15 mg) and 1-mL of 2% lidocaine (20 mg), with final concentrations of approximately 0.375% bupivacaine and 0.5% lidocaine. Compared with the initial block, the total volume was reduced by one third, the bupivacaine dose by 25%, and the lidocaine dose by 50%, while bupivacaine accounted for three quarters of the mixture rather than two thirds. The solution was injected slowly in small increments. Between increments, orbital fullness was assessed visually, periocular tension was palpated with the non-injecting hand, and the adequacy of anesthesia and motor block was evaluated before any further volume was injected (Table 1). The revised block provided satisfactory globe akinesia and adequate analgesia without chemosis.

A 25-gauge transconjunctival pars plana vitrectomy was then performed without conjunctival peritomy. The planned ILM peeling was converted intraoperatively to an inverted ILM flap, followed by fluid-air exchange with room air tamponade. The sclerotomies were self-sealing, and no anesthetic or surgical complication was documented.

Postoperative course. The patient received topical prednisolone acetate and moxifloxacin every 3 hours and atropine 1% twice daily. On postoperative day 2, intraocular pressure in the right eye was 10 mmHg and visual acuity was 1/300, with residual intraocular air. Uncorrected visual acuity improved to 0.20 on

day 16 and remained 0.20 on day 30. At the last follow-up visit, 65 days after surgery, visual acuity had improved to 0.33, above the preoperative level of 0.10, and intraocular pressure was 14 mmHg. Intraocular pressure remained between 10 and 16 mmHg at every postoperative visit, and the left eye remained stable (Table 2).

Table 1. Comparison of the two peribulbar blocks

	Initial block	Revised block
0.5% bupivacaine	4-mL (20 mg)	3-mL (15 mg)
2% lidocaine	2-mL (40 mg)	1-mL (20 mg)
Total volume	6-mL	4-mL
Final concentration in the mixture	Bupivacaine 0.33%, lidocaine 0.67%	Bupivacaine 0.375%, lidocaine 0.5%
Bupivacaine share of the volume	67%	75%
Injection technique	Our standard technique	Slow, incremental, with palpation of periocular tension and evaluation of anesthesia and motor block between increments
Intraocular pressure before the block	16.3 mmHg	13.3 mmHg
Intraocular pressure after the block	24 mmHg	Not raised clinically
Orbit and conjunctiva	Tense orbit, chemosis	No chemosis
Retinal striae	Present	Absent
Akinesia and analgesia	Not assessed (surgery stopped)	Adequate throughout surgery
Outcome	Procedure discontinued; striae resolved within 4 days	Vitrectomy completed; no anesthetic complication

Intraocular pressure before each block was measured by non-contact tonometry at the preoperative clinic visit on the day of surgery.

Table 2. Visual acuity and intraocular pressure of the right eye

Time point	Visual acuity (decimal)	IOP (mmHg)
Presentation	0.50 (best corrected)	19
Preoperative assessment 1	0.40	13
Preoperative assessment 2	0.33	12
Preoperative assessment 3	0.30	12
Latest preoperative assessment	0.10	14
First surgical attempt, before block	Not recorded	16.3
First surgical attempt, after block	Not recorded	24
Right before revised block	Not recorded	13.3
Postoperative day 2	1/300 (intraocular air)	10
Postoperative day 16	0.20	16
Postoperative day 30	0.20	13
Postoperative day 65	0.33	14

Visual acuity is uncorrected unless stated. IOP, intraocular pressure, measured by non-contact tonometry except for the post-block value of 24 mmHg, which was measured in the operating room.

Patient perspective. At follow-up, the patient reported being satisfied with her care and with the surgical outcome.

Discussion and conclusions

This case carries two messages, both limited to this patient. A 6-mL peribulbar block, usually regarded as a moderate volume, exceeded her orbital tolerance and compressed the globe enough to fold the retina. A 4-mL block, smaller than many anesthesiologists would choose for vitrectomy, was sufficient when it was injected incrementally and titrated to the clinical response. Neither observation establishes a safe or unsafe volume for other patients, but together they show why the orbital response, rather than a routine volume, should guide the block.

Mechanism of retinal striae

The striae were absent on all preoperative examinations, and two baseline tomography scans showed a smooth retinal pigment epithelium without folds. They appeared in association with a tense orbit, chemosis, and an increase in intraocular pressure from 16.3 mmHg before the block to 24 mmHg afterward, and they had resolved four days later, once the anesthetic had been absorbed. This sequence points to orbital overfilling. Since the bony walls cannot yield and the septum and lids have limited

capacity to stretch, excess injected volume may increase orbital pressure and exert pressure on the globe. The sclera was indented, and the choroid and retina followed this deformation, producing folds of the kind seen with orbital masses and other forms of external compression [8]. Folds can also appear with hypotony, where the scleral shell is intact, while its contents shrink [9], which suggests that the underlying problem may arise from a mismatch between the globe wall and its contents. In our patient, this mismatch may have resulted from external compression and resolved once the orbital volume normalized. Retrobulbar hemorrhage was unlikely, since it usually causes progressive proptosis and markedly elevated intraocular pressure, reaching 46 mmHg in a recent case [7]. Hypersensitivity to hyaluronidase was also excluded by the immediate onset and confined distribution of the swelling [10].

Why this orbit tolerated less than most is less certain. Mean intraocular pressure after 4-mL and 7-mL blocks did not differ significantly in a recent randomized trial, but individual values varied widely [6]. Thus, a volume that is well tolerated on average may still be excessive for one patient. Female orbits are approximately 14% smaller than male orbits [11], and the volume required for a block varies with axial length [5]. In addition, orbital fat in East Asian adults protrudes from early adulthood as a structural trait [12]. East Asian upper eyelids also differ in contour and fissure obliquity [13], and palpebral fissure height in East Asian women with single eyelids and epicanthal folds averages approximately 9 mm [14]. In our patient, the narrow palpebral fissures and hooded upper lids were the most practical warning at the bedside. The small palpebral aperture with tight lids may limit anterior orbital expansion, and hooding may make early proptosis and lid tension more difficult to detect until the orbit becomes visibly tense. We do not suggest that fissure width is a measure of orbital volume; rather, these features may prompt a more cautious approach to peribulbar injection.

Clinical signs and decision to postpone surgery

A tense orbit, chemosis, and a rise in intraocular pressure after the block are signs that the orbit has reached its limit. Continuing surgery would have added the infusion pressure associated with vitrectomy to an eye already under external compression. Sustained elevation of intraocular pressure may contribute to retinal artery occlusion after ophthalmic regional anesthesia, particularly in patients with compromised retinal circulation [15]. Our patient also had hypertension, which has been associated with higher intraocular pressure in population studies [16]. Because central retinal artery occlusion carries a poor visual prognosis with no established treatment [17], postponing surgery for four days was a reasonable precaution.

Modification of the block regimen

The second block was planned around the patient's response rather than a fixed volume. The total was reduced from 6-mL to 4-mL, with 15 mg of bupivacaine and 20 mg of lidocaine, compared with 20 mg and 40 mg, respectively, in the initial block. Lidocaine was halved, while most of the bupivacaine dose was retained, because lidocaine provides a faster onset, whereas bupivacaine provides the duration of

action needed for a vitrectomy of uncertain duration. The final concentrations differed modestly, so the revised block succeeded through a smaller, incrementally injected volume, not through a stronger solution.

The technique mattered as much as the dose. The solution was injected slowly in small increments, allowing the orbital tissues to accommodate each portion and supporting the rationale for limiting both volume and rate of injection during ophthalmic blocks [7]. Between increments, orbital tension was palpated with the non-injecting hand, and the anesthesia and motor block were evaluated. The endpoint was adequate akinesia and analgesia rather than a predetermined volume. Measuring intraocular pressure after the block may provide an additional objective check before surgery begins [1]. This approach has a trade-off. In the randomized trial, surgeons reported greater satisfaction with 7-mL than with 4-mL [6], suggesting that smaller-volume blocks may sometimes require supplementation. In our patient, 4-mL provided adequate anesthesia for the entire procedure. Postoperative intraocular pressure remained between 10 and 16 mmHg, and uncorrected visual acuity improved from 0.10 preoperatively to 0.33 at 65 days. The recovery is reassuring, although it cannot exclude lasting functional damage from the episode of compression, as the visual outcome also reflects the macular surgery.

When volume tolerance is a concern, alternative approaches may help reduce the volume required. A 5-mL medial canthal block was associated with substantially less chemosis than a conventional peribulbar block [3]. Sub-Tenon anesthesia avoids orbital needle insertion, but may provide incomplete akinesia [5, 18], while hyaluronidase may improve the spread of a smaller volume [19]. Dexmedetomidine as an adjuvant shortens the onset of akinesia and reduces intraocular pressure [20], potentially allowing an effective block with lower volume.

Limitations

This report has several limitations. The retinal striae were documented through the surgeon's intraoperative observation and recorded in the operative notes, but no fundus images were obtained. The intraocular pressure of 24 mmHg after the initial block was measured in the operating room, whereas the values before each block were obtained by non-contact tonometry in the clinic; therefore, these measurements are not strictly comparable. Orbital dimensions and axial length were not measured, and the role of orbital anatomy is therefore inferred. Finally, a single case cannot establish a safe injection volume, and these findings should not be generalized to all patients with narrow palpebral fissures.

Conclusions

In this patient, a 6-mL peribulbar block was associated with transient retinal striae and an increase in intraocular pressure, suggesting that the injected volume exceeded orbital tolerance. Repeat surgery four days later was completed without complication using a 4-mL block given in small increments, with palpation of orbital tension and the adequacy of anesthesia and motor block evaluated between

increments. When the eyelid or orbital features suggest limited space, titrating the block to achieve adequate akinesia and analgesia rather than using a fixed volume is a reasonable precaution.

Abbreviations

CARE: CAse REport guidelines; ILM: Internal limiting membrane; IOP: Intraocular pressure

Declarations

Ethics approval and consent to participate

Not applicable.

Consent for publication

Written informed consent was obtained from the patient for publication of this case report and any accompanying images. A copy of the written consent is available for review by the Editor-in-Chief of this journal.

Availability of data and materials

All data generated or analyzed during this study are included in this published article.

Competing interests

The authors declare that they have no competing interests.

Funding

Not applicable.

Authors' contributions

TP performed the anesthetic management of both procedures and conceived the report. AHK performed the vitreoretinal surgery and provided the ophthalmic findings. MM and VE collected the clinical data, reviewed the literature, and drafted the manuscript. TS contributed to the perioperative care and critically revised the manuscript. JJ revised the manuscript. All authors read and approved the final manuscript.

Acknowledgements

Not applicable.

References

1. Kumar CM, Seet E, Chua AWY. Updates in ophthalmic anaesthesia in adults. BJA Educ. 2023;23(4):153–9. https://doi.org/10.1016/j.bjae.2023.01.003.
2. Kauser D, Das AV, Warjri GB, George KP, Rao RN, Pediredla S. Clinical profile, complications and trends of ocular anaesthesia in a multi-tier ophthalmology network in India: an eight-year experience. Cureus. 2024;16(4):e57564. https://doi.org/10.7759/cureus.57564.
3. Datta D, Khan P. Medial canthal peribulbar block: a safe, efficacious alternative to conventional peribulbar block. Ophthalmol J. 2023;8:131–7. https://doi.org/10.5603/oj.94021.
4. Stasiowski MJ, Lyssek-Boroń A, Krysik K, Majer D, Zmarzły N, Grabarek BO. Evaluating the efficacy of pre-emptive peribulbar blocks with different local anesthetics or paracetamol using the adequacy of anesthesia guidance for vitreoretinal surgeries: a preliminary report. Biomedicines. 2024;12(10):2303. https://doi.org/10.3390/biomedicines12102303.
5. Kılıç Y, Gürsoy HH, Bilgeç MD, Bilir A, Güleç MS. Peribulbar vs. incisionless sub-Tenon's blocks: a retrospective cohort study. Eur J Med Res. 2024;29:635. https://doi.org/10.1186/s40001-024-02251-2.
6. Alam BER, Young SK, Kiyota Y, Mullaly CM, Oh K, Agarwal K, et al. The effect of peribulbar block volume on intraocular pressure change: a randomized prospective study. Am J Ophthalmol. 2026;289. https://doi.org/10.1016/j.ajo.2026.05.010.
7. Costa AM, Sidhu S, Hardy TG. Retrobulbar haemorrhage post sub-Tenons block: a case report. J Med Case Rep. 2026;20:22. https://doi.org/10.1186/s13256-025-05742-w.
8. Cheng JY, Hsu D, Feo A, Liu V, Mafi M, Sarraf D. Chorioretinal folds: a review and update of new and old etiologies. Surv Ophthalmol. 2026;71(2):405–22. https://doi.org/10.1016/j.survophthal.2025.07.004.
9. Narnaware SH, Bawankule PK, Nagdeve R. Folds of 'doom': choroidal folds due to hypotony. Eye (Lond). 2025. https://doi.org/10.1038/s41433-025-04148-8.
10. Cheng C, Han Y, Liu X, Yu W, Yang N. Hypersensitivity reaction to hyaluronidase after peribulbar anesthesia for cataract surgery: two case reports. Drug Healthc Patient Saf. 2026;18:1–8. https://doi.org/10.2147/DHPS.S543301.
11. Kontio R, Wilkman T, Mesimäki K, Chepurnyi Y, Asikainen A, Haapanen A, et al. Automated 3-D computer-aided measurement of the bony orbit: evaluation of correlations among volume, depth, and surface area. J Pers Med. 2024;14(5):508. https://doi.org/10.3390/jpm14050508.
12. Kato K, Okuda I. Characteristics and age-related changes in orbital fat protrusion in East Asians: a retrospective 3-dimensional computed tomography-based study. Aesthet Surg J Open Forum. 2025;7:ojaf122. https://doi.org/10.1093/asjof/ojaf122.

13. Shin DY, Cho WK, Paik JS, Yang SW. Upper eyelid contour measurement in an Asian population using Bézier curve analysis. PLoS One. 2025;20(6):e0316714. https://doi.org/10.1371/journal.pone.0316714.
14. Long L, Xie L, Zeng H, Lai Q, Liu J, Liao W. Modified inverted 'L' epicanthoplasty combined with incisional blepharoplasty for epicanthal folds and single eyelids: a clinical outcomes study. Am J Transl Res. 2025;17(3):2014–22. https://doi.org/10.62347/QAPY8097.
15. Chua AWY, Chua MJ, Harrisberg BP, Kumar CM. Retinal artery occlusion after ophthalmic surgery under regional anaesthesia: a narrative review. Anaesth Intensive Care. 2024;52(2):82–90. https://doi.org/10.1177/0310057X231215826.
16. Mogi M, Ikegawa Y. Close relationship between systemic blood pressure and intraocular pressure. Hypertens Res. 2025;48(3):882–3. https://doi.org/10.1038/s41440-025-02104-3.
17. Chen C, Singh G, Madike R, Cugati S. Central retinal artery occlusion: a stroke of the eye. Eye (Lond). 2024;38(12):2319–26. https://doi.org/10.1038/s41433-024-03029-w.
18. Nene AS, Divate S, Khare S, Pirdankar OH, Badole P, Shenoy P, et al. Sub-Tenon versus peribulbar anesthesia in vitreoretinal surgery: a retrospective analysis in a tertiary eye care center. J Clin Ophthalmol Res. 2024;12(3):227–32. https://doi.org/10.4103/jcor.jcor_22_24.
19. Mohankumar A, Rajan M. Role of hyaluronidase as an adjuvant in local anesthesia for cataract surgery. Indian J Ophthalmol. 2023;71(7):2649–55. https://doi.org/10.4103/IJO.IJO_2515_22.
20. Kavitha V, Seetharamiah S, Heralgi MM. Efficacy and safety of dexmedetomidine as an adjuvant in peribulbar anesthesia: a systematic review. Delhi J Ophthalmol. 2026;36:87–96.

Figures

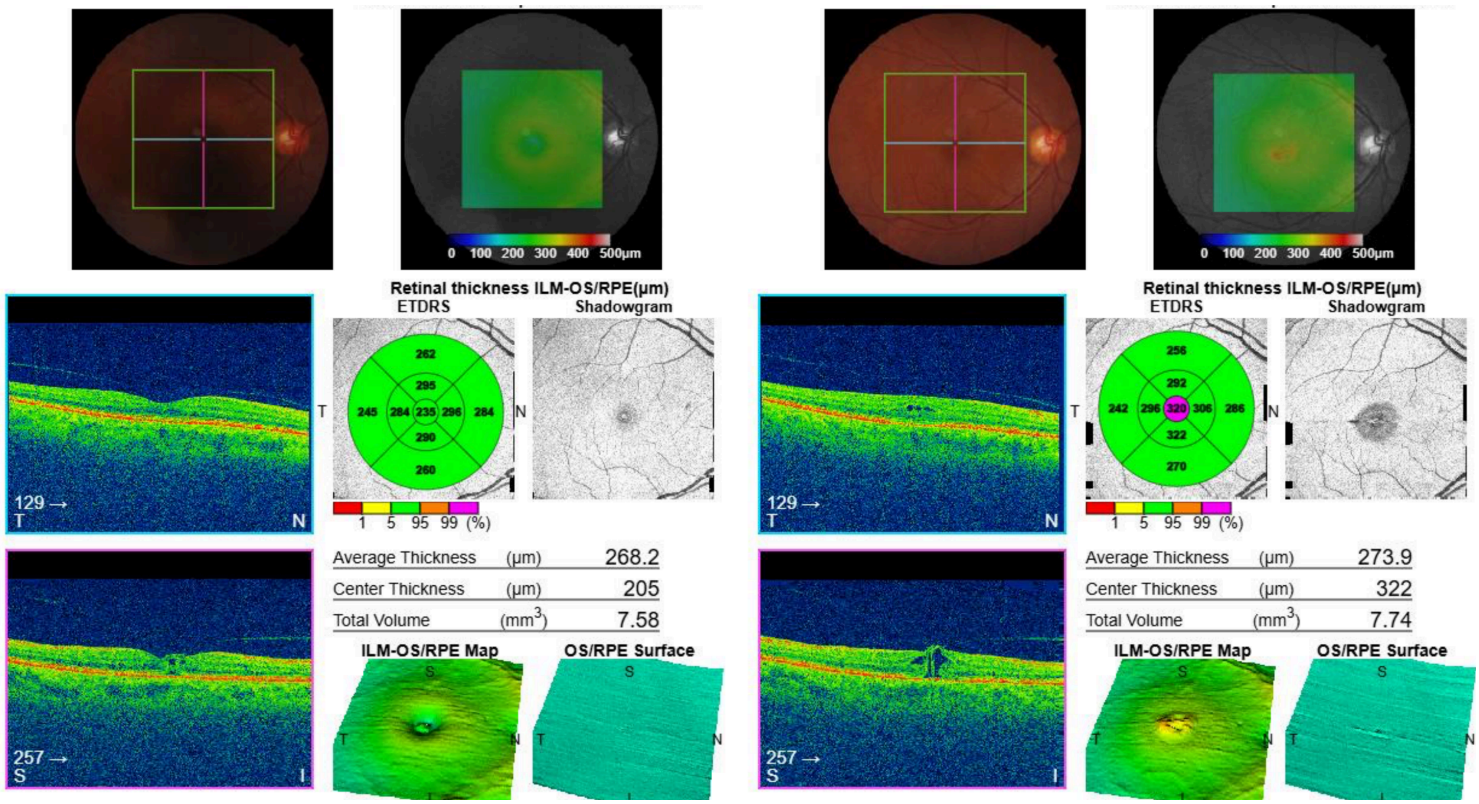

Figure 1

Progression of cystoid macular edema in the right eye before surgery

Spectral-domain optical coherence tomography (Topcon 3D OCT, 7×7 mm macular cube). A At presentation, small intraretinal cysts are present at the fovea, with a center thickness of 205 µm and a central subfield thickness of 235 µm. B Five weeks later, large central cystoid spaces distort the foveal contour on the vertical scan, and the center thickness has increased to 322 µm, with a central subfield thickness of 320 µm. The retinal pigment epithelium is smooth on both scans, without chorioretinal folds.

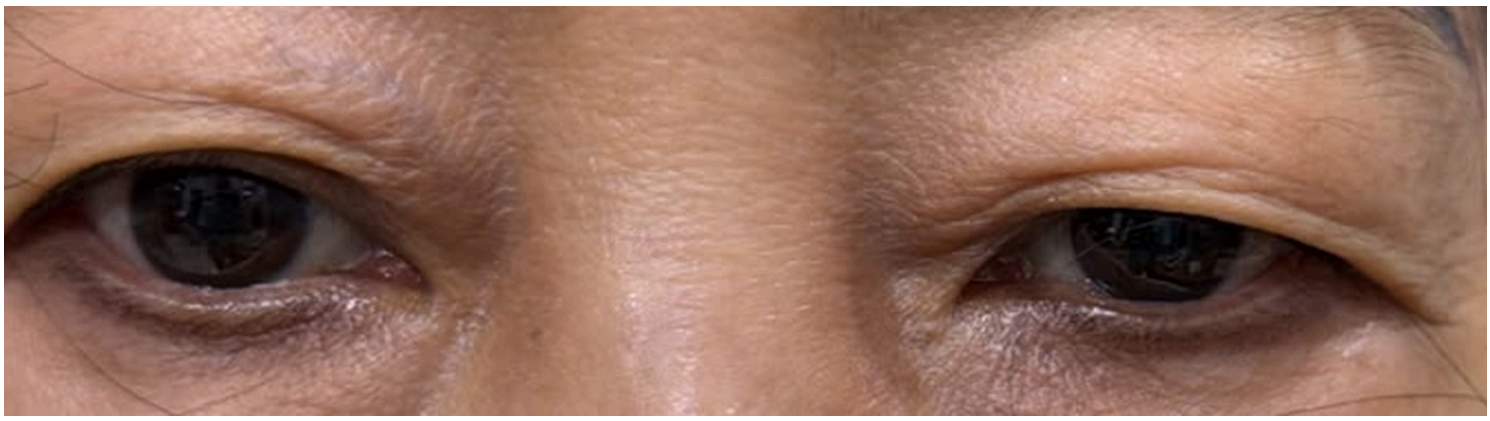

Figure 2

Narrow palpebral fissures before surgery

Preoperative photograph cropped to the periocular region, showing narrow palpebral fissures in both eyes with upper eyelid skin hooding that reduces the vertical aperture.