Research Square

Preprints are preliminary reports that have not undergone peer review.
They should not be considered conclusive, used to inform clinical practice,
or referenced by the media as validated information.

Unilateral Biportal Endoscopic Decompression for Lumbar Spinal Epidural Lipomatosis: A Single-Center Retrospective Study of 27 Cases

Wenli Zhou
Hubei University of Chinese Medicine
Xin Zhang
Hubei Provincial Hospital of Traditional Chinese Medicine
Feng Li
Hubei Provincial Hospital of Traditional Chinese Medicine
Lin Li
Hubei Provincial Hospital of Traditional Chinese Medicine
Hua Chen
ch1222@126.com

Hubei Provincial Hospital of Traditional Chinese Medicine

Research Article

Keywords: Spinal epidural lipomatosis, unilateral biportal endoscopy, minimally invasive surgery, lumbar spinal stenosis, clinical safety

Posted Date: November 24th, 2026

DOI: https://doi.org/10.21203/rs.3.rs-11573764/v1

License: This work is licensed under a Creative Commons Attribution 4.0 International License.
Read Full License

Additional Declarations: No competing interests reported.

Abstract

Background

Spinal epidural lipomatosis (SEL) is a rare disorder caused by pathological overgrowth of epidural fat. The expanding fat reduces the effective volume of the spinal canal and may compress the thecal sac or nerve roots, resulting in a spectrum of neurological deficits. Open decompression has traditionally been the standard surgical treatment for SEL, but minimally invasive alternatives are receiving increasing attention. Unilateral biportal endoscopic (UBE) decompression is a promising technique for degenerative spinal disorders; however, evidence supporting its use in SEL remains limited. This single-center retrospective study aimed to evaluate the short-term clinical efficacy and safety of UBE decompression in patients with symptomatic lumbar SEL.

Methods

Twenty-seven patients with symptomatic lumbar SEL who underwent UBE decompression between January 2021 and September 2024 were enrolled. All patients were followed for at least 12 months. The Visual Analog Scale (VAS) for back and leg pain, the Oswestry Disability Index (ODI), the Japanese Orthopaedic Association (JOA) score, and the modified MacNab criteria were recorded before surgery and at the final follow-up. Radiographic assessments included the spinal canal area (SCA), dural sac area (DSA), and facet joint preservation rate. Complications and reoperations were documented, and a subgroup analysis was performed according to body mass index (BMI ≥ 28 kg/m²).

Results

The cohort comprised 18 men and 9 women, with a mean age of 56.7 ± 13.5 years. The etiology was idiopathic in 20 patients (74.1%), obesity-related in 5 (18.5%), and steroid-related in 2 (7.4%). The mean follow-up duration was 14.6 ± 5.3 months. At the final follow-up, the ODI, VAS scores for back and leg pain, and JOA score had all improved significantly compared with preoperative values. The rate of excellent or good outcomes according to the modified MacNab criteria was 85.2%. At the final follow-up, the SCA showed no significant change compared with preoperative values, while the DSA increased significantly, and no segmental instability was observed. Three patients (11.1%) developed postoperative complications, all of which were mild; no permanent neurological injury or reoperation was required. Obese patients achieved comparable clinical outcomes, although operative time was longer and intraoperative blood loss was greater.

Conclusion

UBE decompression provided satisfactory short-term clinical and radiographic outcomes with a favorable safety profile in carefully selected patients with symptomatic lumbar SEL. Obesity did not compromise clinical outcomes but may increase operative difficulty. UBE may serve as a minimally invasive alternative to open decompression; however, its long-term efficacy requires further investigation.

Background

Spinal epidural lipomatosis (SEL) is a rare condition characterized by pathological, non-neoplastic overgrowth of adipose tissue within the epidural space, which can lead to progressive spinal canal stenosis, neural compression, and functional impairment[1–3]. The estimated prevalence of SEL on magnetic resonance imaging (MRI) ranges from 2.2% to 6.3% in the general population, with only a minority of cases being symptomatic[4, 5]. Established risk factors include prolonged exogenous glucocorticoid use, endogenous hypercortisolism, obesity, and idiopathic etiology[6–8].

The clinical manifestations of symptomatic SEL are nonspecific and frequently mimic degenerative lumbar spinal stenosis or disc herniation, presenting as low back pain, radiculopathy, and neurogenic claudication; in severe cases, cauda equina syndrome or myelopathy may occur[9, 10]. Diagnosis relies heavily on imaging, with MRI regarded as the gold standard because of its superior soft-tissue contrast and its ability to distinguish epidural fat from cerebrospinal fluid and neural structures[11].

Treatment strategies for SEL are stratified according to symptom severity and etiology. Conservative management—including weight reduction, discontinuation of offending glucocorticoids, and physical therapy—remains the first-line option for mild-to-moderate cases[7, 12]. Surgery is indicated in patients with progressive neurological deficits, intractable pain, or persistent symptoms despite at least 3 months of conservative treatment[10]. Conventional open surgery, such as laminectomy combined with epidural fat resection, provides reliable decompression but is associated with extensive paraspinal muscle dissection, prolonged recovery, and a risk of iatrogenic instability, particularly in multilevel procedures[9, 13].

As a minimally invasive alternative, unilateral biportal endoscopic (UBE) decompression has been widely applied in various degenerative lumbar disorders, including spinal stenosis, disc herniation, and degenerative spondylolisthesis[14, 15]. Since Kang et al.[16] first reported the use of UBE for SEL in 2019, accumulating case series have suggested its feasibility in this rare disease[11, 13, 17, 18]. However, existing evidence remains limited to small case reports. This study aimed to evaluate the short-term clinical efficacy and safety of UBE decompression in patients with symptomatic lumbar SEL.

Methods and analysis

Study design and patient selection

This single-center retrospective study protocol was approved by the Institutional Review Board (IRB) and the Medical Ethics Committee. All patients provided written informed consent for surgery and for the anonymized use of their data for research purposes. The study was conducted in accordance with the Declaration of Helsinki.

Between January 2021 and September 2024, 31 patients diagnosed with symptomatic lumbar SEL underwent UBE decompression at our institution. Four patients were excluded (2 lost to follow-up, 1 with a history of prior surgery at the same segment, and 1 with incomplete records), and the remaining 27 patients were included in the final analysis. All procedures were performed by two senior attending spine surgeons.

The inclusion criteria were: (1) age ≥ 18 years; (2) MRI-confirmed lumbar SEL, with characteristic T1 hyperintense epidural fat accumulation causing compression of the thecal sac; (3) symptoms attributable to SEL, including radiculopathy, neurogenic claudication, or objective neurological deficits; (4) failure of conservative treatment (medication, physical therapy, epidural injection, or activity modification) for at least 3 months; and (5) a minimum postoperative follow-up of 12 months with complete clinical and radiographic data. The exclusion criteria were: (1) spinal infection, tumor, or trauma; (2) previous surgery at the same segment; (3) segmental instability on dynamic flexion-extension radiographs; (4) comorbid pathologies requiring fusion (e.g., spondylolisthesis greater than grade I or severe scoliosis); (5) coagulation disorders or bleeding tendency; (6) inability to tolerate general anesthesia; and (7) incomplete medical records or loss to follow-up.

Surgical procedure

All procedures were performed by two senior attending spine surgeons with extensive experience in UBE. A standardized UBE technique, modified for the specific features of SEL, was used.

After satisfactory general anesthesia, each patient was placed in the standard prone position, and routine sterile preparation and draping were performed. The responsible segment was precisely localized under C-arm fluoroscopy. Two portal incisions were made 1.5 cm lateral to the midline at the level of the intervertebral disc, and the working and viewing channels were established sequentially. The paraspinal muscles were split with dilators, and soft tissue was dissected through the intermuscular plane. The disc level was reconfirmed under fluoroscopy. First, the inferior edge of the superior lamina, the superior edge of the inferior lamina, and a portion of the facet joint were removed stepwise using a high-speed burr, rongeurs, and osteotomes, followed by resection of the hypertrophied ligamentum flavum. A nerve dissector was used to carefully separate the adipose tissue from the nerve roots and dura, avoiding excessive traction that could cause neurological injury or dural tear. Under clear endoscopic visualization, the hyperplastic epidural fat was meticulously removed with pituitary forceps. After decompression, restoration of satisfactory nerve root pulsation and relief of thecal sac compression were confirmed. The surgical field was thoroughly irrigated and hemostasis was achieved, a drain was placed, and the incision was closed (Fig. 1).

Postoperative management

All patients were encouraged to ambulate early with brace protection within the limits of pain tolerance; the brace was worn for 3–4 weeks. Rehabilitation was initiated within 24 hours postoperatively, and all patients followed a standardized rehabilitation protocol encompassing bedside activity instruction, spinal positioning management, and standardized strengthening exercises of the back and lower limb musculature, supplemented by evidence-based nutritional guidance and standardized pharmacological management.

Outcome measures

Outcome measures
Demographic and clinical data extracted from medical records included age, sex, body mass index (BMI), medical comorbidities, history of glucocorticoid use, American Society of Anesthesiologists (ASA) physical status classification, symptom duration, and previous conservative treatment.

Clinical outcomes were assessed before surgery, at 3 months postoperatively, and at the final follow-up by an independent spine surgeon not involved in the surgery, through outpatient visits or structured telephone interviews(Supplementary material 1). The assessments included the Oswestry Disability Index (ODI), the Visual Analog Scale (VAS) for back and leg pain, the Japanese Orthopaedic Association (JOA) score, and the modified MacNab criteria.

Perioperative parameters included operative time, estimated intraoperative blood loss, postoperative drainage volume, time to first ambulation, length of postoperative hospital stay, and number of intraoperative fluoroscopic exposures.

Radiographic outcomes were evaluated using preoperative and postoperative (within 1 week) CT and MRI, as well as MRI and dynamic radiographs at the final follow-up. All imaging measurements were performed by two independent spine surgeons blinded to clinical outcomes using the institutional Picture Archiving and Communication System (PACS); the mean of the two measurements was used for analysis, and disagreements exceeding 10% were resolved by consensus. The measured parameters included the spinal canal area (SCA), dural sac area (DSA), canal expansion rate, dural sac expansion rate, facet joint preservation rate, Manjila grade, and segmental stability on dynamic flexion-extension radiographs[10, 19, 20].

Safety outcomes included intraoperative and postoperative complications (dural tear, nerve root injury, epidural hematoma, surgical site infection, deep vein thrombosis, and pulmonary complications). The reoperation rate and any symptomatic recurrence during follow-up were also recorded.

Statistical analysis

All statistical analyses were performed using IBM SPSS version 27.0 (IBM Corp., Armonk, NY, USA). Continuous data are expressed as mean ± standard deviation. The paired-samples t-test was used for within-group preoperative-to-postoperative comparisons, and the independent-samples t-test was used for subgroup analyses. Categorical data are expressed as percentages (%), and the chi-square test was used for between-group comparisons. All tests were two-tailed, and $P < 0.05$ was considered statistically significant.

Results

Demographic and baseline characteristics

During the study period, 31 patients underwent UBE decompression for lumbar SEL. Of these, 2 were lost to follow-up (< 6 months), 1 had a history of laminectomy at the same segment, and 1 had incomplete clinical records; 27 patients were finally included in the analysis. The cohort comprised 18 men (66.7%) and 9 women (33.3%), with a mean age of 56.7 ± 13.5 years. The mean BMI was 28.4 ± 4.2 kg/m², and 15 patients (55.6%) were obese (BMI ≥ 28 kg/m²). Single-level involvement was present in 23 patients (85.2%), most commonly at L4/5 (14 patients, 51.9%), followed by L5/S1 (9 patients, 33.3%); two-level involvement was present in 4 patients (14.8%). No patient had three or more consecutive affected levels. The most common comorbidity was hypertension (12 patients, 44.4%), followed by type 2 diabetes mellitus (6 patients, 22.2%). The mean symptom duration was 14.9 ± 9.7 months, and all patients had failed at least 3 months of conservative treatment. The etiology of SEL was idiopathic in 20 patients (74.1%), obesity-related in 5 (18.5%), and steroid-related in 2 (7.4%). Notably, no patient had Cushing syndrome or other endocrine disorders. Baseline demographic and clinical characteristics are summarized in Table 1.

Table 1 Demographic and clinical characteristics (n=27)

Characteristic	value (%)
Age (year)	56.7±13.5
Gender (%)	
Male	18 (66.7)
Female	9 (33.3)
Body mass index (kg/m2)	28.4±4.2
Obesity (BMI≥28 kg/m2)	15 (55.6)
Involved segments (%)	
Single-level	23 (85.2)
L4/5	14 (51.9)
L5/S1	9 (33.3)
Two-level	4 (14.8)
≥3 consecutive segments	0 (0)
ASA classification (%)	
Grade I	3 (11.1)
Grade II	16 (59.3)
Grade III	8 (29.6)
Comorbidities (%)	
Hypertension	12 (44.4)
Type 2 diabetes mellitus	6 (22.2)
Coronary artery disease	2 (7.4)
Chronic obstructive pulmonary disease	1 (3.7)
Duration of symptoms (month)	14.9±9.7
Failure of conservative treatment ≥3 months	27 (100)
Etiology of SEL (%)	
Idiopathic	20 (74.1)
Obesity-related	5 (18.5)
Steroid-related	2 (7.4)

Abbreviations: BMI: body mass index; ASA: American Society of Anesthesiologists; SEL: spinal epidural lipomatosis.

Perioperative data and complications

All 27 procedures were completed successfully without conversion to open surgery. The mean incision length was 2.4 ± 0.4 cm, the mean operative time was 87.6 ± 22.4 minutes, and the mean estimated intraoperative blood loss was 87.9 ± 28.6 mL; no patient required intraoperative or postoperative transfusion. The mean postoperative drainage volume was 89.6 ± 35.4 mL, and all drains were removed within 48 hours. The mean time to first ambulation was 18.7 ± 6.2 hours, and the mean length of postoperative hospital stay was 4.7 ± 1.9 days. Unilateral decompression was performed in 19 patients (70.4%) and bilateral decompression in 8 (29.6%), according to preoperative symptoms and imaging findings. Histopathological examination of the resected tissue confirmed mature adipose tissue in all cases, with no evidence of tumor or inflammation. Intraoperative or postoperative complications occurred in 3 patients (11.1%). Two patients (7.4%) developed a dural tear, which was recognized intraoperatively and repaired primarily under endoscopic visualization in both cases; neither patient developed persistent cerebrospinal fluid leakage, pseudomeningocele, or any other complication requiring re-intervention. One patient (3.7%) experienced transient sensory dysesthesia (burning sensation in the affected dermatome), which resolved spontaneously within 3 weeks without specific treatment (Table 2).

Table 2
Surgical indicators (n = 27)

Characteristic	Value (%)
Completion of surgery (%)	
Completed successfully	27 (100)
Conversion to open surgery	0 (0)
Incision length (cm)	2.4 ± 0.4
Surgical duration (min)	87.6 ± 22.4
Estimated intraoperative blood loss (mL)	87.9 ± 28.6
Intraoperative or postoperative transfusion	0 (0)
Postoperative drainage volume (mL)	89.6 ± 35.4
Drain removal within 48 h	27 (100)
Time to first ambulation (h)	18.7 ± 6.2
Postoperative hospital stay (day)	4.7 ± 1.9
Decompression approach (%)	
Unilateral decompression	19 (70.4)
Bilateral decompression	8 (29.6)
Complications occurrence (%)	
Dural tear (repaired endoscopically)	2 (7.4)
Cerebrospinal fluid leakage	0 (0)
Pseudomeningocele	0 (0)
Transient sensory radiculopathy	1 (3.7)
No complications	24 (88.9)

Clinical outcomes

At the final follow-up, all patient-reported outcome measures had improved significantly compared with preoperative values ($P < 0.001$). The mean VAS score for back pain improved from 5.19 ± 1.27 to 1.37 ± 0.79, and the VAS score for leg pain from 5.78 ± 1.12 to 1.19 ± 0.92. The mean ODI decreased from 63.89 ± 10.02 preoperatively to 16.93 ± 4.79, and the mean JOA score increased from 11.52 ± 2.42 to 21.33 ± 2.94. According to the modified MacNab criteria at the final follow-up, outcomes were excellent in 16 patients (59.3%), good in 7 (25.9%), fair in 3 (11.1%), and poor in 1 (3.7%), yielding an overall satisfaction rate of 85.2% (Table 3).

Table 3
Clinical outcomes

ODI score (Mean ± STD)	Value	Difference ± Difference STD	P value
Preoperative	63.89 ± 10.02	——	
3 months postoperative	29.63 ± 9.11*	34.26 ± 7.39	< 0.001
Final follow-up	16.93 ± 4.79*	46.96 ± 9.44	< 0.001
VAS for back pain (Mean ± STD)			
Preoperative	5.19 ± 1.27	——	
3 months postoperative	2.07 ± 0.96*	3.11 ± 1.12	< 0.001
Final follow-up	1.37 ± 0.79*	3.81 ± 1.14	< 0.001
VAS for leg pain (Mean ± STD)			
Preoperative	5.78 ± 1.12	——	
3 months postoperative	2.15 ± 0.91*	3.63 ± 1.08	< 0.001
Final follow-up	1.19 ± 0.92*	4.59 ± 1.45	< 0.001
JOA score (Mean ± STD)			
Preoperative	11.52 ± 2.42	——	
3 months postoperative	19.63 ± 3.88*	8.11 ± 3.92	< 0.001
Final follow-up	21.33 ± 2.94*	9.81 ± 3.81	< 0.001
Modified MacNab score at final follow-up (%)			
Excellent	16 (59.26%)		
Good	7 (25.93%)		
Fair	3 (11.11%)		
Poor	1 (3.70%)		
Abbreviations: ODI: Oswestry disability index; VAS: visual analog scale; JOA: Japanese Orthopaedic Association; * Compared with preoperative clinical outcomes, $p < 0.05$.			

Radiographic outcomes

Postoperative MRI demonstrated substantial removal of the epidural fat. The SCA increased only slightly after surgery (2.46 ± 0.22 cm² vs. 2.50 ± 0.22 cm²), indicating no meaningful expansion of the osseous canal. In contrast, the mean DSA increased significantly from 0.66 ± 0.14 cm² to 1.35 ± 0.12 cm² (P < 0.001), with a mean dural sac expansion rate of 114.0 ± 47.3% (Fig. 2). The mean facet joint preservation rate was 78.5 ± 5.9% on the surgical side and 92.5 ± 3.3% on the contralateral side. No segmental instability was observed on postoperative or final follow-up dynamic flexion-extension radiographs.

Subgroup analysis

Obese patients (n = 15) and non-obese patients (n = 12) achieved comparable improvements in the ODI (Δ44.67 ± 9.90 vs. Δ49.83 ± 8.34, P = 0.154), VAS back pain (Δ3.53 ± 1.13 vs. Δ4.17 ± 1.11, P = 0.157), VAS leg pain (Δ4.47 ± 1.64 vs. Δ4.75 ± 1.22, P = 0.611), and JOA score (Δ9.40 ± 4.47 vs. Δ10.33 ± 2.90, P = 0.519). However, obese patients had a significantly longer mean operative time (98.9 ± 16.0 vs. 73.6 ± 21.7 minutes, P < 0.05) and greater intraoperative blood loss (107.6 ± 20.6 vs. 63.3 ± 14.0 mL, P < 0.001) (Table 4).

Table 4
Subgroup analysis of obese and non-obese patients (n = 27)

Variable	Obese (n = 15)	Non-obese (n = 12)	P value
Clinical improvement (final follow-up − preoperative)			
ODI score improvement	Δ44.67 ± 9.90	Δ49.83 ± 8.34	0.154
VAS back pain improvement	Δ3.53 ± 1.13	Δ4.17 ± 1.11	0.157
VAS leg pain improvement	Δ4.47 ± 1.64	Δ4.75 ± 1.22	0.611
JOA score improvement	Δ9.40 ± 4.47	Δ10.33 ± 2.90	0.519
Perioperative parameters			
Surgical duration (min)	98.9 ± 16.0	73.6 ± 21.7	< 0.05
Estimated intraoperative blood loss (mL)	107.6 ± 20.6	63.3 ± 14.0	< 0.001

Data are presented as mean ± standard deviation; improvement = final follow-up score − preoperative score; P values from independent-samples t tests; obesity defined as BMI ≥ 28 kg/m².

Discussion

SEL is a rare disease with limited surgical evidence. Open laminectomy combined with epidural fat resection has long been the mainstay of surgical treatment, with reported satisfaction rates of 70%–90% [3, 8, 21]. However, open surgery requires extensive muscle stripping and carries a risk of iatrogenic

instability (particularly when the facet joints are violated) and prolonged recovery[20]. Al-Khawaja et al. [1] reported a relatively high reoperation rate after open decompression in patients with SEL, partially attributable to postoperative instability and epidural fibrosis.

In recent years, we have continued to explore minimally invasive techniques for SEL. Kang et al.[16] first reported three cases of percutaneous biportal endoscopic treatment of SEL, achieving satisfactory decompression without complications. Subsequently, some scholars proposed the “piecemeal fat resection technique” to prevent nerve traction injury[22]. For hyperplastic adipose tissue in the epidural space, the technique adopts “sharp dissection combined with piecemeal resection”. After gentle release of adhesions using a nerve dissector, the adipose tissue is removed in fragments with microscissors. Li Y et al.[11] further verified that UBE technology can safely manage intraspinal adipose tissue via “piecemeal resection plus intraoperative neuromonitoring”, providing clinical evidence for UBE in the treatment of SEL. Several studies have compared UBE with other minimally invasive surgeries in multiple dimensions, including operative duration, intraoperative blood loss, surgical complications and postoperative neurological recovery, and concluded that UBE yields prominent advantages[15, 18].

Compared with conventional degenerative lumbar spinal stenosis, SEL poses distinct surgical challenges. The epidural fat in SEL is typically soft, highly mobile, and circumferentially distributed, and it often densely adheres to and encases the thecal sac and nerve roots[11, 13]. This differs fundamentally from the discrete osseous or ligamentous compression encountered in typical spinal stenosis. Our technical approach emphasizes the following key principles. First, meticulous adhesiolysis with a nerve dissector under continuous saline irrigation is essential. The fluid medium facilitates blunt dissection and reduces traction on neural structures. Rough grasping or aggressive suctioning of the fatty tissue must be avoided to prevent dural tears or nerve root avulsion. Second, piecemeal fat resection with pituitary forceps under direct visualization allows controlled removal without circumferential dissection. The surgical goal is adequate neural decompression rather than complete fat excision; when it does not compromise decompression, we intentionally preserve a thin layer of fat covering the thecal sac, which may theoretically reduce postoperative epidural fibrosis and dural adhesions. Third, 29.6% of patients with bilateral symptoms underwent unilateral laminotomy for bilateral decompression (ULBD). The UBE technique provides an adequate visual field and instrument maneuvering space to decompress the contralateral side across the midline while preserving the contralateral facet joint and paraspinal muscles[23]. This is particularly advantageous in SEL, where circumferential fat compression is common. Fourth, the hyperplastic fat is richly vascularized, and hemostasis requires judicious use of low-power bipolar coagulation. Continuous saline irrigation naturally provides a bloodless surgical field and dissipates heat, reducing the risk of thermal neural injury[11, 18].

Obesity is a well-established risk factor for SEL, with epidemiological studies showing a positive correlation between BMI and epidural fat accumulation[24]. In our cohort, 55.6% of patients were obese (BMI ≥ 28 kg/m²), consistent with reported prevalence in SEL populations. Interestingly, the subgroup analysis showed comparable degrees of clinical improvement between obese and non-obese patients, suggesting that obesity does not compromise the efficacy of UBE decompression. However, obese

patients required longer operative time and had greater blood loss, possibly attributable to increased epidural fat volume, thicker soft-tissue layers, and more challenging portal establishment. Surgeons should anticipate increased technical difficulty in obese patients, but obesity should not be regarded as a contraindication to UBE.

A primary concern in decompression surgery for SEL is the risk of iatrogenic instability, particularly when multilevel decompression is required. Open laminectomy with aggressive facetectomy has been associated with postoperative spondylolisthesis and progressive deformity[19, 25]. In our series, the mean facet joint preservation rate was 78.5% on the surgical side and 92.5% on the contralateral side, exceeding the 50% threshold below which biomechanical studies suggest instability may occur[25]. Moreover, no patient developed segmental instability on dynamic radiographs during follow-up. These findings support the concept that UBE maintains spinal stability by preserving the posterior tension-band structures while minimizing facet joint violation, even in the presence of pre-existing degenerative changes.

Our overall complication rate was 11.1%, comparable to the previously reported 10%–25% for open decompression surgery of spinal stenosis[20]. Both dural tears (7.4%) were recognized and repaired intraoperatively without sequelae; this rate is consistent with the 5%–10% reported in the literature on UBE for degenerative stenosis[18, 26], although it may be slightly higher in SEL because the fat disrupts normal anatomical planes. Notably, no nerve root injury, infection, or epidural hematoma occurred, and the reoperation rate was 0 during follow-up.

This study has several limitations inherent to its retrospective single-center design and the rarity of SEL. First, the absence of a control group precludes direct comparison with open surgery or other minimally invasive techniques. Second, our findings may reflect the concentration of expertise at a single high-volume center, and learning-curve effects may yield different outcomes in less experienced hands. Finally, the mean follow-up of 14.6 ± 5.3 months is insufficient to assess long-term outcomes such as delayed instability, adjacent-segment disease, or late epidural fat reaccumulation; longer follow-up is needed to draw more robust conclusions.

Conclusion

UBE decompression is a feasible and safe minimally invasive surgical option for carefully selected patients with symptomatic lumbar SEL. In this consecutive series of 27 patients, pain, disability, and neurological function improved significantly, radiographic decompression was substantial, and the complication rate was low. Obesity increased operative complexity but did not compromise clinical outcomes. UBE may be a viable alternative to open decompression in selected patients, particularly those without segmental instability; however, long-term prospective comparative studies are needed to confirm the durability of its efficacy and to define its comparative benefits.

Data Availability

The datasets used and/or analysed during the current study are available from the corresponding author on reasonable request

Abbreviations

ASA
American Society of Anesthesiologists
BMI
Body mass index
COPD
Chronic obstructive pulmonary disease
CT
Computed tomography
DSA
Dural sac area
IRB
Institutional Review Board
JOA
Japanese Orthopaedic Association
MRI
Magnetic resonance imaging
ODI
Oswestry Disability Index
PACS
Picture Archiving and Communication System
SCA
Spinal canal area
SD
Standard deviation
SEL
Spinal epidural lipomatosis
UBE
Unilateral biportal endoscopy
ULBD
Unilateral laminotomy for bilateral decompression
VAS
Visual analogue scale

Declarations

Ethics Statement

This study was conducted in strict accordance with the Declaration of Helsinki and approved by the Ethics Committee of Hubei Provincial Hospital of Traditional Chinese Medicine on December 3, 2024 (approval No. HBZY2024-D81-01). Written informed consent was obtained from each participant prior to study initiation.

Consent for publication

All patients participating in this study provided written informed consent. All authors listed meet the authorship criteria according to the latest guidelines of the International Committee of Medical Journal Editors, and all authors are in agreement with the manuscript.

Funding

No financial support was provided for this work.

Author Contribution

ZWL: Manuscript drafting, revision and editing, data curation, methodology.ZX: Manuscript drafting, revision and editing.LF: Data curation, manuscript revision and editing.LL: Data curation, methodology, manuscript revision and editing.CH: Data curation, manuscript revision and editing, surgical protocol design.

Data Availability

The datasets used and/or analysed during the current study are available from the corresponding author on reasonable request.

References

1. Al-Khawaja D, Seex K, Eslick GD. Spinal epidural lipomatosis–a brief review. J Clin Neurosci. 2008;15:1323–6. https://doi.org/10.1016/j.jocn.2008.03.001.
2. Mallard F, Buni M, Nolet PS, Emary P, Taylor JA, Moammer G. Lumbar spinal epidural lipomatosis: A case report and review of the literature. Int J Surg Case Rep. 2021;78:71–5. https://doi.org/10.1016/j.ijscr.2020.11.128.
3. Walker PB, Sark C, Brennan G, Smith T, Sherman WF, Kaye AD. Spinal Epidural Lipomatosis: A Comprehensive Review. Orthop Rev (Pavia). 2021;13:25571. https://doi.org/10.52965/001c.25571.

4. Lisai P, Doria C, Crissantu L, Meloni GB, Conti M, Achene A. Cauda equina syndrome secondary to idiopathic spinal epidural lipomatosis. Spine (Phila Pa 1976). 2001;26:307–9. https://doi.org/10.1097/00007632-200102010-00017.
5. Theyskens NC, Paulino Pereira NR, Janssen SJ, Bono CM, Schwab JH, Cha TD. The prevalence of spinal epidural lipomatosis on magnetic resonance imaging. Spine J. 2017;17:969–76. https://doi.org/10.1016/j.spinee.2017.02.010.
6. Kuhn MJ, Youssef HT, Swan TL, Swenson LC. Lumbar epidural lipomatosis: the Y sign of thecal sac compression. Comput Med Imaging Graph. 1994;18:367–72. https://doi.org/10.1016/0895-6111(94)90007-8.
7. D'Agostino V, Petrera MR, Tedesco G, Pipola V, Ponti F, Spinnato P. Could Spinal Epidural Lipomatosis Be the Hallmark of Metabolic Syndrome on the Spine? A Literature Review with Emphasis on Etiology. Diagnostics (Basel). 2023;13:322. https://doi.org/10.3390/diagnostics13020322.
8. Alomari S, Lubelski D, Khalifeh JM, Sacino AN, Theodore N, Witham T, et al. Etiologies and Outcomes of Spinal Epidural Lipomatosis: Systematic Review of the Literature and Meta-Analysis of Reported Cases. Clin Spine Surg. 2022;35:383–7. https://doi.org/10.1097/BSD.0000000000001344.
9. Deng Z, Wang Y, Shaik MS, Li D, Di R, Wu Z, et al. Case Report: Spinal epidural lipomatosis with incomplete cauda equina syndrome treated with unilateral biportal endoscopic technique. Front Surg. 2026;13:1762865. https://doi.org/10.3389/fsurg.2026.1762865.
10. Manjila S, Fana M, Medani K, Kay MD, Manjila R, Bazil TG, et al. Spinal Epidural Lipomatosis Causing Lumbar Canal Stenosis: A Pictorial Essay on Radiological Grading and the Role of Bariatric Surgery Versus Laminectomy. Cureus. 2022;14:e26492. https://doi.org/10.7759/cureus.26492.
11. Li Y, Guo H, Li Z, Wang Y, Tang Z, Li H, et al. Unilateral biportal endoscopy for the treatment of symptomatic spinal epidural lipomatosis: a case report and literature review. Front Surg. 2025;12:1580499. https://doi.org/10.3389/fsurg.2025.1580499.
12. Salman AA, Ahmed AB, Sharabati H, Bakri IA, Al-Darawish AM. A challenging diagnosis of spinal epidural lipomatosis: A case report and review of the literature. Int J Surg Case Rep. 2024;121:109948. https://doi.org/10.1016/j.ijscr.2024.109948.
13. Tan B, Zheng Y-H, Lei C, Ouyang J-Y, Wen Y-B, Shi Z-H, et al. Unilateral biportal endoscopy vs. open decompression for lumbar epidural lipomatosis-cohort study using a prospective registry. Front Neurol. 2024;15:1366357. https://doi.org/10.3389/fneur.2024.1366357.
14. Sun H, Zhang Q, Xu K, Zhou Z, Jiang D, He S, et al. A retrospective study on safety and clinical outcomes of unilateral biportal endoscopic technique for spinal degenerative diseases. PeerJ. 2025;13:e19076. https://doi.org/10.7717/peerj.19076.
15. Chen Y, Lin W, Lei S, You Y, Zhang X, Ma Y, et al. Comparing the Efficacy and Safety of Unilateral Biportal Endoscopic Decompression with Percutaneous Endoscopic Lumbar Decompression for Lumbar Degenerative Diseases: A Meta-Analysis. World Neurosurg. 2024;187:e383–98. https://doi.org/10.1016/j.wneu.2024.04.093.

16. Kang S-S, Lee S-C, Kim S-K. A Novel Percutaneous Biportal Endoscopic Technique for Symptomatic Spinal Epidural Lipomatosis: Technical Note and Case Presentations. World Neurosurg. 2019;129:49–54. https://doi.org/10.1016/j.wneu.2019.05.214.
17. Guo W, Li T, Feng C, Yu Y, Hu Y, Fan X. Clinical comparison of unilateral biportal endoscopic transforaminal lumbar interbody fusion verse 3D microscope-assisted transforaminal lumbar interbody fusion in the treatment of single-segment lumbar spondylolisthesis with lumbar spinal stenosis: a retrospective study with 24-month follow-up. J Orthop Surg Res. 2023;18:943. https://doi.org/10.1186/s13018-023-04401-4.
18. Jiang H-W, Chen C-D, Zhan B-S, Wang Y-L, Tang P, Jiang X-S. Unilateral biportal endoscopic discectomy versus percutaneous endoscopic lumbar discectomy in the treatment of lumbar disc herniation: a retrospective study. J Orthop Surg Res. 2022;17:30. https://doi.org/10.1186/s13018-022-02929-5.
19. Gao Z, Cai Z, Wu Y, Xu Y, Wang J. Short-term clinical efficacy of unilateral biportal endoscopic unilateral laminectomy for bilateral decompression for lumbar epidural lipomatosis: an observational study. BMC Musculoskelet Disord. 2025;26:973. https://doi.org/10.1186/s12891-025-09231-5.
20. Li X, Liu J, Liu Z. Comparison of the results of open PLIF versus UBE PLIF in lumbar spinal stenosis: postoperative adjacent segment instability is lesser in UBE. J Orthop Surg Res. 2023;18:543. https://doi.org/10.1186/s13018-023-04038-3.
21. Schmutzer-Sondergeld M, Zimmermann H, Trabold R, Liebig T, Schichor C, Siller S. Outcome of posterior decompression for spinal epidural lipomatosis. Acta Neurochir (Wien). 2023;165:3479–91. https://doi.org/10.1007/s00701-023-05814-0.
22. Liu Z, Cai H, Zhao H, Tang L, Jia S, Zhou Z, et al. Case Report: Technical description and clinical evaluation of three cases of unilateral biportal endoscopic decompression for symptomatic spinal epidural lipomatosis. Front Surg. 2024;11:1309202. https://doi.org/10.3389/fsurg.2024.1309202.
23. Choi D-J, Kim J-E, Jung J-T, Kim Y-S, Jang H-J, Yoo B, et al. Biportal Endoscopic Spine Surgery for Various Foraminal Lesions at the Lumbosacral Lesion. Asian Spine J. 2018;12:569–73. https://doi.org/10.4184/asj.2018.12.3.569.
24. Zhang B, Yuan H, Hu L, Saad M. Obesity is a risk factor for epidural lipomatosis: a meta-analysis. J Orthop Surg (Hong Kong). 2021;29:23094990211027391. https://doi.org/10.1177/23094990211027391.
25. Liu R, He T, Wu X, Tan W, Yan Z, Deng Y. Biomechanical response of decompression alone in lower grade lumbar degenerative spondylolisthesis–A finite element analysis. J Orthop Surg Res. 2024;19:209. https://doi.org/10.1186/s13018-024-04681-4.
26. Chen Z, Zhou H, Wang X, Liu Z, Liu W, Luo J. Complications of Unilateral Biportal Endoscopic Spinal Surgery for Lumbar Spinal Stenosis: A Meta-Analysis and Systematic Review. World Neurosurg. 2023;170:e371–9. https://doi.org/10.1016/j.wneu.2022.11.019.

Figures

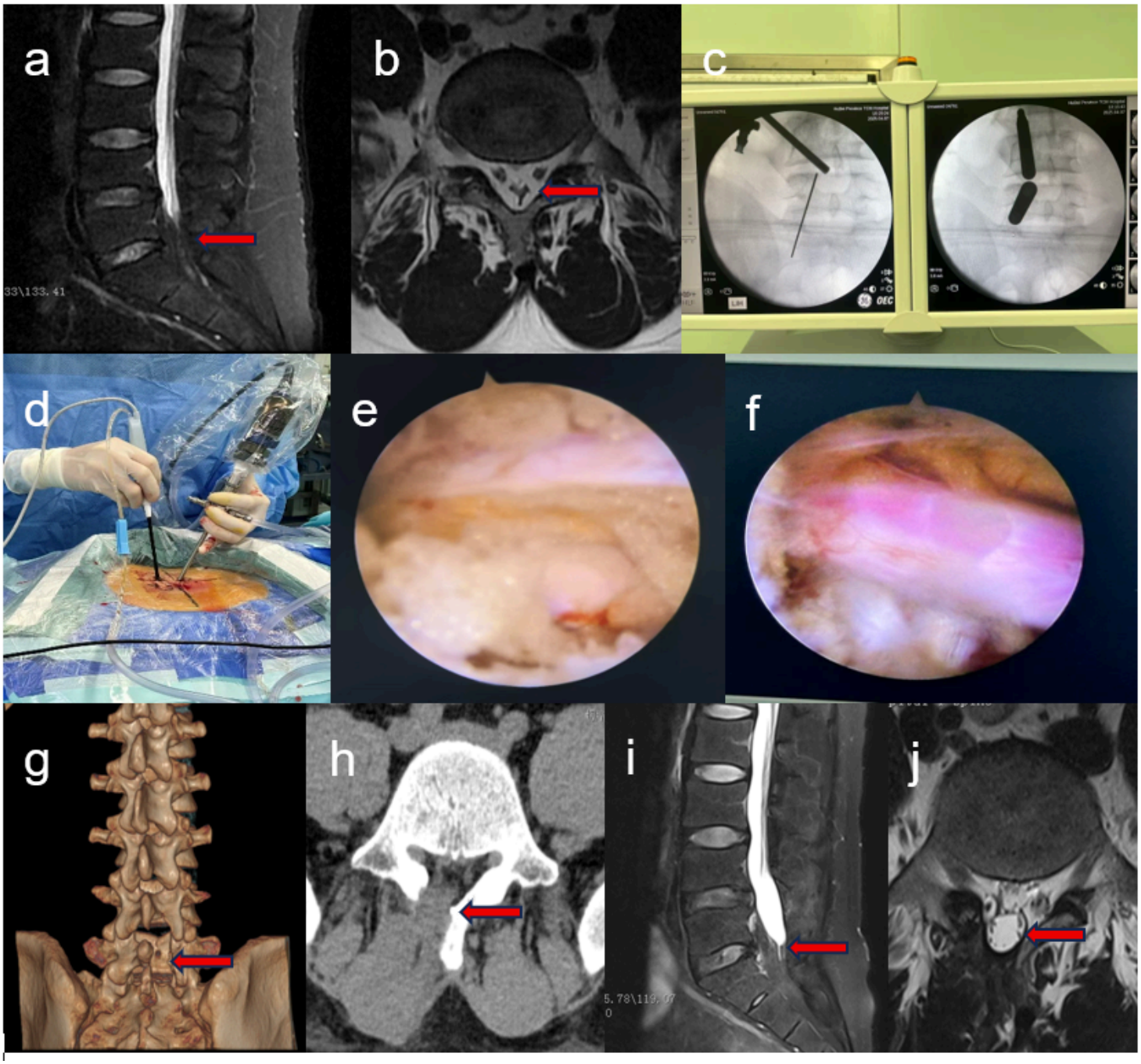

Figure 1

A patient was hospitalized due to low back pain accompanied by numbness in the right lower leg for 10 months, with aggravation over the previous 1 month. The patient was diagnosed with lumbar spinal epidural lipomatosis in our hospital and underwent UBE surgery. a, b: Preoperative lumbar MRI showing compression of the dural sac at the L5/S1 level with the classic "Y sign"; c: Intraoperative fluoroscopy for localization of the responsible segment; d: Intraoperative establishment of the dual channels. The left channel is the viewing portal, and the right is the working portal; e, f: Comparison before and after

adipose tissue debridement. The nerve root was adequately decompressed with restored blood supply after fat removal; g, h: Postoperative CT and three-dimensional reconstruction demonstrating partial laminectomy and substantial resection of intraspinal adipose tissue; i, j: Follow-up MRI obtained at 5 months postoperatively showing satisfactory expansion of the dural sac and adequate relaxation of nerve roots.

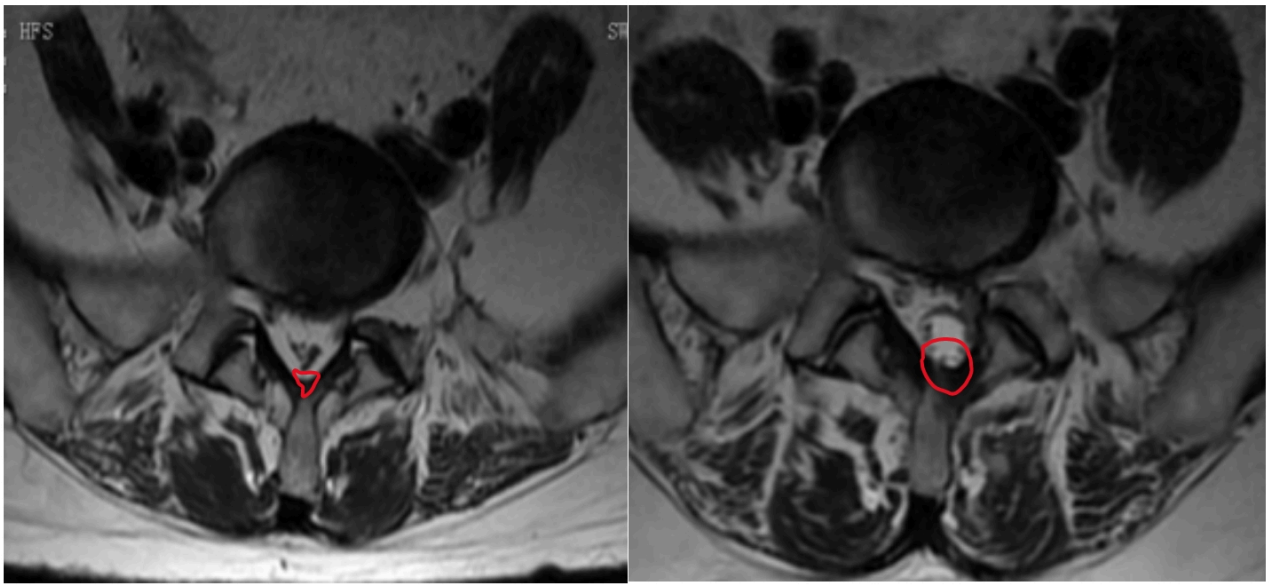

Figure 2

The calculation formula for the dural sac expansion rate was defined as: (Postoperative DSA − Preoperative DSA) / Preoperative DSA × 100%. In this case, (1.34 − 0.45) / 0.45 × 100% = 197.8%.

Supplementary Files

This is a list of supplementary files associated with this preprint. Click to download.

- Supplementarymaterial1.docx