Research Square

Preprints are preliminary reports that have not undergone peer review.
They should not be considered conclusive, used to inform clinical practice,
or referenced by the media as validated information.

Orbital apex syndrome caused by polymicrobial sinusitis due to Pseudomonas aeruginosa and methicillin-resistant Staphylococcus aureus in a patient undergoing hemodialysis: A case report

Eriko Masuda
erikotsukazaki25@gmail.com
Tokyo Metropolitan Okubo Hospital
Tomoko Kawanishi
Tokyo Metropolitan Okubo Hospital
Kazuki Ito
Tokyo Metropolitan Okubo Hospital
Kenshiro Soeda
Tokyo Metropolitan Okubo Hospital
Yuki Kohara
Tokyo Metropolitan Okubo Hospital
Toshie Ogawa
Tokyo Metropolitan Okubo Hospital
Yasutomo Abe
Tokyo Metropolitan Okubo Hospital
Mariko Takahara
Tokyo Metropolitan Okubo Hospital

Case Report

Keywords: orbital apex syndrome, bacterial sinusitis, type 2 diabetes, hemodialysis, Pseudomonas aeruginosa, methicillin-resistant Staphylococcus aureus

Posted Date: November 26th, 2026

DOI: https://doi.org/10.21203/rs.3.rs-11573345/v1

License: This work is licensed under a Creative Commons Attribution 4.0 International License. Read Full License

Additional Declarations: No competing interests reported.

Abstract

Background

Orbital apex syndrome is a vision-threatening condition characterized by dysfunction of the optic nerve and cranial nerves that pass through the optic canal and superior orbital fissure. We report a case of orbital apex syndrome secondary to bacterial sinusitis in a patient undergoing maintenance hemodialysis.

Case presentation

: A 63-year-old man with poorly controlled diabetes mellitus and kidney failure was admitted for lower-extremity cellulitis. Hemodialysis was initiated on hospital day 2. The cellulitis improved after 2 weeks of treatment with ampicillin/sulbactam. On hospital day 78, he reported a 3-day history of progressive visual impairment. Imaging revealed extensive right pansinusitis with bony destruction involving the orbital apex and skull base. Emergency endoscopic sinus surgery revealed necrotic tissue, and intraoperative cultures grew *Pseudomonas aeruginosa* and methicillin-resistant *Staphylococcus aureus*. Antimicrobial therapy was tailored to the culture results and continued for 42 days. Despite extensive locally invasive disease, the patient remained afebrile and showed only a modest systemic inflammatory response. Ophthalmoplegia and optic disc edema gradually improved, but vision did not recover.

Conclusion

This case highlights that severe bacterial sinusitis may rapidly progress to orbital apex syndrome despite relatively mild systemic manifestations in patients undergoing maintenance hemodialysis. Early diagnosis, prompt imaging, multidisciplinary management, and timely surgical intervention are essential to reduce the risk of irreversible vision loss.

Background

Orbital apex syndrome (OAS) is characterized by vision loss and ophthalmoplegia resulting from dysfunction of the optic canal and cranial nerves III, IV, V1, and VI, which transverse the optic canal or superior orbital fissure [1, 2]. Differential diagnoses include neoplastic, inflammatory, vascular, traumatic, and infectious disorders. Among the infectious causes, invasive fungal sinusitis is the most commonly identified, particularly in immunocompromised patients. In contrast, OAS associated with bacterial sinusitis is uncommon and has been documented in only a limited number of case reports [3–13]. Patients receiving maintenance hemodialysis have an increased risk of severe infections because of chronic kidney disease-associated immune dysfunction, repeated healthcare exposure, and multiple comorbidities [14–16]. Furthermore, localized infections may progress despite a mild systemic inflammatory response, making early diagnosis challenging.

We report a rare case of OAS caused by polymicrobial sinusitis due to *Pseudomonas aeruginosa* and methicillin-resistant *Staphylococcus aureus* (MRSA) in a patient undergoing maintenance hemodialysis.

Case Presentation

The patient was a 63-year-old man with a history of type 2 diabetes mellitus with poor glycemic control (HbA1c at admission, 8.5%), chronic kidney disease, severe aortic stenosis treated with percutaneous coronary intervention of the left circumflex artery, acute subdural hematoma treated with left craniotomy, and a remote cerebral infarction. The patient was admitted with cellulitis of the left lower leg. His serum creatinine and blood urea nitrogen concentrations were 6.22 mg/dL and 96.2 mg/dL, respectively. Hemodialysis was initiated for diabetic kidney disease via a temporary dialysis catheter on hospital day 2. The cellulitis was treated with ampicillin/sulbactam for 2 weeks and improved clinically and biochemically. A wound culture of cellulitis at admission yielded methicillin-susceptible *Staphylococcus aureus*(MSSA), and blood cultures obtained were negative. An arteriovenous fistula was created on hospital day 13, and hemodialysis via the fistula was initiated on hospital day 28. He remained hospitalized for rehabilitation because of impaired activities of daily living. Intensive insulin therapy generally maintained his random blood glucose concentration at < 180 mg/dL. On hospital day 78, he reported a 3-day history of progressive visual impairment.

On examination, visual acuity in the right eye was reduced to hand-motion perception, accompanied by complete ophthalmoplegia. The pupillary light reflexes were preserved, and funduscopic examination revealed right optic disc edema. The patient was afebrile and hemodynamically stable. Computed tomography (CT) and magnetic resonance imaging (MRI) demonstrated right-predominant pansinus opacification with bony destruction involving the orbital apex and skull base and soft tissue extension along the right optic nerve into the optic canal (Figs. 1, 2). CT performed at admission showed no evidence of sinusitis, indicating that the destructive sinonasal infection developed rapidly during hospitalization. Laboratory tests revealed a mild inflammatory response (white blood cell count, 11,000/μL; C-reactive protein, 3.27 mg/dL). These clinical findings are summarized in Table 1.

Table 1
Laboratory findings

White blood cell	**11.0**	**(3.3–8.6)**	**$\times 10^3/\mu L$**
Neutrophil	70.2	(41.8–73.8)	%
Lymphocytes	7.7	(18.3–47.5)	%
Monocytes	5.0	(2.5–7.3)	%
Eosinophil	16.2	(0.0–5.6)	%
Basophil	0.9	(0.1–1.3)	%
Red blood cell	4.81	(4.35–5.55)	$\times 10^6/\mu L$
Hemoglobin	14.3	(13.7–16.8)	g/dL
Hematocrit	43.5	(40.7–50.1)	%
Platelet	32.5	(15.8–34.8)	$\times 10^4/\mu L$
C-reactive protein	3.27	(< 0.14)	mg/dL
Total protein	7.1	(6.6–8.1)	g/dL
Serum albumin	3.2	(4.1–5.1)	g/dL
Blood urea nitrogen	27.4	(8–20)	mg/dL
Serum creatinine	4.46	(0.65–1.07)	mg/dL
Total bilirubin	0.32	(0.4–1.5)	mg/dL
Aspartate aminotransferase	13	(13–30)	U/L
Alanine aminotransferase	9	(10–42)	U/L
Lactate dehydrogenase	408	(124–222)	IU/L
β-D-glucan	24	(< 20)	pg/mL
HbA1c (on Admission)	8.5	(4.9–6.0)	%

Empiric treatment with ampicillin/sulbactam was initiated for suspected OAS associated with bacterial sinusitis. Blood cultures were negative, and nasal swab cultures were negative for MRSA. On day 5 after symptom onset, the antimicrobial regimen was broadened to piperacillin/tazobactam with adjunctive voriconazole and systemic corticosteroids because of concern for aggressive sinusitis with possible fungal involvement. On day 8 after symptom onset, urgent endoscopic sinus surgery (type III) was performed to achieve decompression. White necrotic tissue was identified at the orbital apex and anterior skull base. Intraoperative frozen section analysis revealed granulation tissue formation. Dehiscence of the medial orbital wall with protrusion of soft tissue into the orbit was observed, and decompression was successfully achieved. Intraoperative cultures grew *P. aeruginosa* and MRSA.

Based on the culture results, antimicrobial therapy was changed to cefepime plus vancomycin on day 10, and corticosteroids were discontinued. The serum β-D-glucan concentration was mildly elevated (24 pg/mL), but the serum *Aspergillus* antigen test and fungal cultures were negative. Histopathological examination revealed no evidence of fungal invasion. These findings supported a diagnosis of bacterial sinusitis rather than invasive fungal sinusitis, and voriconazole treatment was discontinued on day 22. After the patient developed cefepime-associated encephalopathy, cefepime was replaced with levofloxacin on day 22. Given the extensive destruction of the skull base, concomitant skull base osteomyelitis was considered, and targeted antimicrobial therapy was continued for 6 weeks. Although vision did not recover, ophthalmoplegia and optic disc edema gradually improved. The patient was subsequently transferred to a rehabilitation facility for ongoing care.

Discussion and Conclusions

This report describes a case of OAS caused by rapidly progressive polymicrobial sinusitis in a patient undergoing maintenance hemodialysis. Despite surgical decompression and prolonged pathogen-directed antimicrobial therapy, vision did not recover, although ophthalmoplegia and optic disc edema gradually improved. This clinical course highlights the aggressive nature of bacterial OAS in immunocompromised patients and the importance of early recognition and multidisciplinary management.

OAS is a severe neuro-ophthalmic emergency with diverse etiologies, including neoplastic, vascular, inflammatory, traumatic, and infectious disorders [1, 2]. Among infectious causes, invasive fungal sinusitis is the most frequently reported cause because of its aggressive course and predilection for immunocompromised hosts. In contrast, OAS associated with bacterial sinusitis is uncommon, and only a limited number of cases have been reported.

We searched PubMed for previously reported cases of OAS associated with bacterial sinusitis. The findings from 12 cases, including the present case, are summarized in Table 2 [3–13]. Diabetes mellitus was the most common comorbidity, occurring in eight cases. Among the previously reported cases, only one patient was receiving maintenance hemodialysis [4]. The causative organisms included *Pseudomonas aeruginosa* [3, 4, 8, 9, 11], *Staphylococcus aureus* [3, 7, 8, 10], and other organisms. Polymicrobial infections were identified in two cases [3, 8]. Among the cases with available laboratory data, C-reactive protein (CRP) levels ranged from 2.4 to 26.6 mg/dL. Some patients exhibited only mildly elevated CRP levels, suggesting that the severity of orbital apex involvement does not necessarily correlate with the systemic inflammatory response. Antibiotic therapy was administered in all cases, and surgical treatment was performed in 72.7% (8/11) of cases. Visual outcomes varied: visual impairment persisted in six patients, four recovered normal visual function, and one patient died of multiorgan failure before the visual outcome could be assessed. Despite appropriate antimicrobial therapy and surgical drainage, the variability in visual outcomes underscores the importance of recognizing OAS before irreversible optic nerve damage occurs. Similar to several previously reported cases, our patient had diabetes mellitus and a mild systemic inflammatory response. However, the combination of maintenance hemodialysis and polymicrobial infection was uncommon among the reported cases. Despite surgical intervention and appropriate antimicrobial therapy, his vision did not recover.

Table 2
Summary of previous case reports of OAS secondary to bacterial sinusitis

References	Age/Sex	Background	Causative organism	C-reactive protein (mg/dL)	Treatment	Outcome
Colson & Daily (1999) [3]	49/M	DM, chronic sinusitis	*Staphylococcus aureus, Pseudomonas aeruginosa*	NR	Antibiotics	No visual recovery
Kusunoki et al. (2011) [4]	60/F	DM, Kidney failure on hemodialysis	*Pseudomonas aeruginosa*	2.8	ESS, Antibiotics	No visual recovery
Allan et al. (2013) [5]	29/F	NR	NR	NR	ESS, Antibiotics	Complete visual recovery
Bodily et al. (2017) [6]	68/F	Acute myelogenous leukemia	*Streptococcus viridans*	NR	ESS, Antibiotics	No visual recovery (Light perception)
Pfeiffer et al. (2018) [7]	63/F	DM, metastatic breast cancer	MSSA	NR	ESS, Antibiotics	No visual recovery (No light perception)
Xiong & Moy (2018) [8]	58/M	T2DM	MRSA, *Pseudomonas aeruginosa*	Unremarkable	ESS, Antibiotics	Died from multiorgan failure
Leung et al. (2018) [9]	79/F	T2DM, previous FESS	*Pseudomonas aeruginosa*	NR	ESS, Antibiotics	Complete visual recovery
He et al. (2024) [10]	58/M	T2DM	MRSA	4.66	ESS, Antibiotics, Tooth extraction	No visual recovery (Light perception)
Koh et al. (2024) [11]	9/M	Hyper-IgM syndrome	*Pseudomonas aeruginosa*	26.6	ESS, Antibiotics	No visual recovery
Rajad et al. (2025) [12]	53/M	T2DM	NR	9.9	Antibiotics	Complete visual recovery
Kagzi et al. (2025) [13]	73/F	T2DM	*Serratia marcescens*	2.4	Antibiotics	Complete visual recovery
Our case	63/M	T2DM, Kidney	MRSA, *Pseudomonas*	3.27	ESS, Antibiotics	No visual recovery

Abbreviations: DM, diabetes mellitus; ESS, endoscopic sinus surgery; FESS, functional endoscopic sinus surgery; MRSA, methicillin-resistant Staphylococcus aureus; MSSA, methicillin-susceptible *Staphylococcus aureus*; NR, not reported; OAS, orbital apex syndrome; T2DM, type 2 diabetes mellitus. Cases described as posterior orbital cellulitis were included because they involved infection of the orbital apex or optic nerve secondary to sphenoethmoiditis.

References	Age/Sex	Background	Causative organism	C-reactive protein (mg/dL)	Treatment	Outcome
		failure on hemodialysis	*aeruginosa*			(Light perception)

Abbreviations: DM, diabetes mellitus; ESS, endoscopic sinus surgery; FESS, functional endoscopic sinus surgery; MRSA, methicillin-resistant Staphylococcus aureus; MSSA, methicillin-susceptible *Staphylococcus aureus*; NR, not reported; OAS, orbital apex syndrome; T2DM, type 2 diabetes mellitus. Cases described as posterior orbital cellulitis were included because they involved infection of the orbital apex or optic nerve secondary to sphenoethmoiditis.

Reports of polymicrobial OAS are limited, particularly among patients undergoing maintenance hemodialysis. In the present case, *Pseudomonas aeruginosa* and MRSA were isolated from intraoperative specimens, supporting their pathogenic roles rather than indicating simple nasal colonization. Histopathological examination revealed histiocyte-rich granulation tissue, prompting consideration of both reactive and neoplastic histiocytic disorders. However, immunohistochemical staining for BRAF V600E was negative, and the clinicopathological and microbiological findings supported bacterial sinusitis as the primary cause of OAS.

Extensive bony destruction extending to the skull base raised concern for central skull base osteomyelitis. Skull base osteomyelitis is an uncommon but potentially life-threatening complication of invasive infection and may develop secondary to advanced bacterial sinusitis. Although early diagnosis is often challenging because the clinical manifestations may be nonspecific, delayed treatment can result in multiple cranial neuropathies and poor neurological outcomes [17, 18]. In the present case, pathogen-directed antimicrobial therapy was continued for 6 weeks because of extensive destruction of the skull base and suspected osteomyelitis.

The patient had previously undergone treatment for cellulitis. Cellulitis is a common infection in patients with diabetes mellitus. There was an interval of approximately two months between the resolution of the cellulitis and the onset of visual symptoms. Blood cultures obtained during the episode of cellulitis were negative, and the organisms isolated from the preceding cellulitis and bacterial sinusitis differed. These findings suggest that a direct causal relationship between the preceding cellulitis and bacterial sinusitis was unlikely.

Patients undergoing hemodialysis have a substantially increased risk of severe infections and infection-related mortality. Sepsis-related mortality among patients with end-stage renal disease has been reported to be more than 100 times that in the general population [14]. Chronic kidney disease-associated immune dysregulation likely contributes to this increased susceptibility to infection [15, 16]. Uremia is associated with complex abnormalities in innate and adaptive immune responses, including impaired neutrophil function, altered antigen presentation, lymphocyte dysfunction, and persistent systemic inflammation. In the present patient, poorly controlled diabetes mellitus, kidney failure, recent initiation of hemodialysis, prolonged hospitalization, and repeated healthcare exposure may have collectively increased his susceptibility to rapidly progressive infection.

Another clinically important feature was the discrepancy between the severity of the local infection and the relatively mild systemic inflammatory response. At the onset of visual symptoms, the patient remained

afebrile and had only modest elevations in the white blood cell count and CRP level, despite extensive destruction of the orbital apex and skull base. Furthermore, CT performed at admission showed no evidence of sinus disease, suggesting that destructive sinusitis developed rapidly during hospitalization. These findings indicate that severe localized bacterial infections may progress despite limited systemic manifestations, particularly in patients with impaired host defenses. Therefore, acute visual disturbances or ophthalmoplegia in patients undergoing hemodialysis should prompt immediate imaging, even in the absence of fever or markedly elevated inflammatory markers.

In our patient, several days elapsed between symptom onset and definitive intervention, which may have adversely affected the visual outcome. The patient had preexisting higher cortical dysfunction resulting from prior cerebrovascular disease, which may have delayed the recognition and reporting of visual symptoms. The optic nerve is highly susceptible to compressive and inflammatory injury, and even brief periods of ischemia can result in irreversible damage. In patients with traumatic OAS refractory to corticosteroid therapy, endoscopic decompression of the optic canal and orbital apex has been reported to improve visual outcomes for cases refractory to corticosteroid therapy [19]. Surgical decompression has similarly been reported to preserve vision in patients with infectious OAS [20]. The infection was ultimately controlled; however, visual acuity did not recover, whereas ophthalmoplegia and optic disc edema gradually improved. This dissociation suggests that irreversible optic nerve injury had already occurred before definitive decompression.

Patients undergoing maintenance hemodialysis may develop rapidly progressive bacterial OAS despite relatively mild systemic inflammation. Early recognition, prompt neuroimaging, and close multidisciplinary collaboration among otolaryngologists, ophthalmologists, nephrologists, and infectious disease specialists are essential for timely intervention and the prevention of irreversible optic nerve injury.

Abbreviations

CT
Computed tomography
MRI
Magnetic resonance imaging
MRSA
Methicillin-resistant Staphylococcus aureus
OAS
Orbital apex syndrome

Declarations

Ethical approval and consent to participate

Not applicable.

Consent for publication

Informed consent was obtained from the patient.

Competing interests

The authors have declared that they have no competing interests.

Authors' information

Department of Nephrology, Tokyo Metropolitan Okubo Hospital, Tokyo, Japan

Eriko Masuda, Tomoko Kawanishi, Kazuki Ito, Yuki Kohara, Toshie Ogawa, Yasutomo Abe

Department of Ophthalmology, Tokyo Metropolitan Okubo Hospital, Tokyo, Japan

Mariko Takahara

Funding

No funding was received for this study.

Author Contribution

EM collected and analyzed the clinical data, reviewed the literature, and drafted the manuscript. TK contributed to patient management and critical revision of the manuscript. The other authors were primarily involved in the patients' clinical management during hospitalization and contributed to the patients' clinical care. All authors have read and approved the final version of the manuscript.

Acknowledgement

We thank the patient and his family for providing consent for publication of this case report. We would like to thank Editage (www.editage.jp) for English language editing.

Availability of data and materials

Not applicable.

References

1. Yeh S, Foroozan R. Orbital apex syndrome. Curr Opin Ophthalmol. 2004;15:490–8. https://doi.org/10.1097/01.icu.0000144387.12739.9c
2. Badakere A, Patil-Chhablani P. Orbital apex syndrome: a review. Eye Brain. 2019;11:63–72. https://doi.org/10.2147/EB.S180190

3. Colson AE, Daily JP. Orbital apex syndrome and cavernous sinus thrombosis due to infection with Staphylococcus aureus and Pseudomonas aeruginosa. Clin Infect Dis. 1999;29:701–2. https://doi.org/10.1086/598670
4. Kusunoki T, Kase K, Ikeda K. A case of orbital apex syndrome due to Pseudomonas aeruginosa infection. Clin Pract. 2011;1:e127. https://doi.org/10.4081/cp.2011.e127
5. Allan K, Atkinson H, Agada F. Posterior orbital cellulitis: case report and literature review. J Laryngol Otol. 2013;127:1148–51. https://doi.org/10.1017/S0022215113002181
6. Bodily L, Yu J, Sorrentino D, Branstetter BF. Invasive Streptococcus viridans sphenoethmoiditis leading to an orbital apex syndrome. Am J Ophthalmol Case Rep. 2017;8:4–6. https://doi.org/10.1016/j.ajoc.2017.07.006
7. Pfeiffer ML, Merritt HA, Bailey LA, Richani K, Phillips ME. Orbital apex syndrome from bacterial sinusitis without orbital cellulitis. Am J Ophthalmol Case Rep. 2018;10: 84–6. https://doi.org/10.1016/j.ajoc.2018.01.041
8. Xiong M, Moy WL. Orbital apex syndrome resulting from mixed bacterial sphenoid sinusitis. Eur J Case Rep Intern Med. 2018;5:000905. https://doi.org/10.12890/2018_000905
9. Leung V, Dunn H, Newey A, O'Donnell B. Orbital apex syndrome in Pseudomonas sinusitis after functional endoscopic sinus surgery. Ophthalmic Plast Reconstr Surg. 2018;34:e166–8. https://doi.org/10.1097/IOP.0000000000001196
10. He Z, Han H, Shang W, Song K. Orbital apex syndrome secondary to residual tooth root infection: a case report. Braz J Otorhinolaryngol. 2024;90:101455. https://doi.org/10.1016/j.bjorl.2024.101455
11. Koh SY, Hsu MH, Ko SF, Chen CH. Orbital apex syndrome secondary to Pseudomonas aeruginosa sinusitis in a child with hyperimmunoglobulin M syndrome. Pediatr Neonatol. 2024;65:412–3. https://doi.org/10.1016/j.pedneo.2024.03.006
12. Rajad H, Bigi S, Adnor S, et al. Orbital apex syndrome associated with cranial nerve V neuritis complicating bacterial maxillary sinusitis. Radiol Case Rep. 2025;20:3859–64. https://doi.org/10.1016/j.radcr.2025.04.111
13. Kagzi Y, Khambati M, Thiruvadi V, Chatterjee T. Serratia marcescens sinusitis presenting as left orbital apex syndrome. Eur J Case Rep Intern Med. 2025;12:005814. https://doi.org/10.12890/2025_005814
14. Sarnak MJ, Jaber BL. Mortality caused by sepsis in patients with end-stage renal disease compared with the general population. Kidney Int. 2000;58:1758–64. https://doi.org/10.1111/j.1523-1755.2000.00337.x
15. Betjes MGH. Immune cell dysfunction and inflammation in end-stage renal disease. Nat Rev Nephrol. 2013;9:255–65. https://doi.org/10.1038/nrneph.2013.44
16. Cohen G. Immune dysfunction in uremia 2020. Toxins (Basel). 2020;12:439. https://doi.org/10.3390/toxins12070439
17. Chapman PR, Choudhary G, Singhal A. Skull base osteomyelitis: a comprehensive imaging review. AJNR Am J Neuroradiol. 2021;42:404–13. https://doi.org/10.3174/ajnr.A7015
18. Clark MPA, Pretorius PM, Byren I, Milford CA. Central or atypical skull base osteomyelitis: diagnosis and treatment. Skull Base. 2009;19:247–54. https://doi.org/10.1055/s-0028-1115325

19. Zhou G, Yu B, Tu Y, Shi J, Wu W. Endoscopic transethmosphenoid optic canal and orbital apex decompression for patients with traumatic orbital apex syndrome. J Craniofac Surg. 2020;31:214–8. https://doi.org/10.1097/SCS.0000000000005904
20. Yoshida K, Shirata A, Sato T, Kishida Y, Saito K, Yamane K. A case of orbital apex syndrome due to aspergillus infection that avoided loss of visual acuity by optic canal decompression. Rinsho Shinkeigaku. 2016;56:1–6. https://doi.org/10.5692/clinicalneurol.cn-000741

Figures

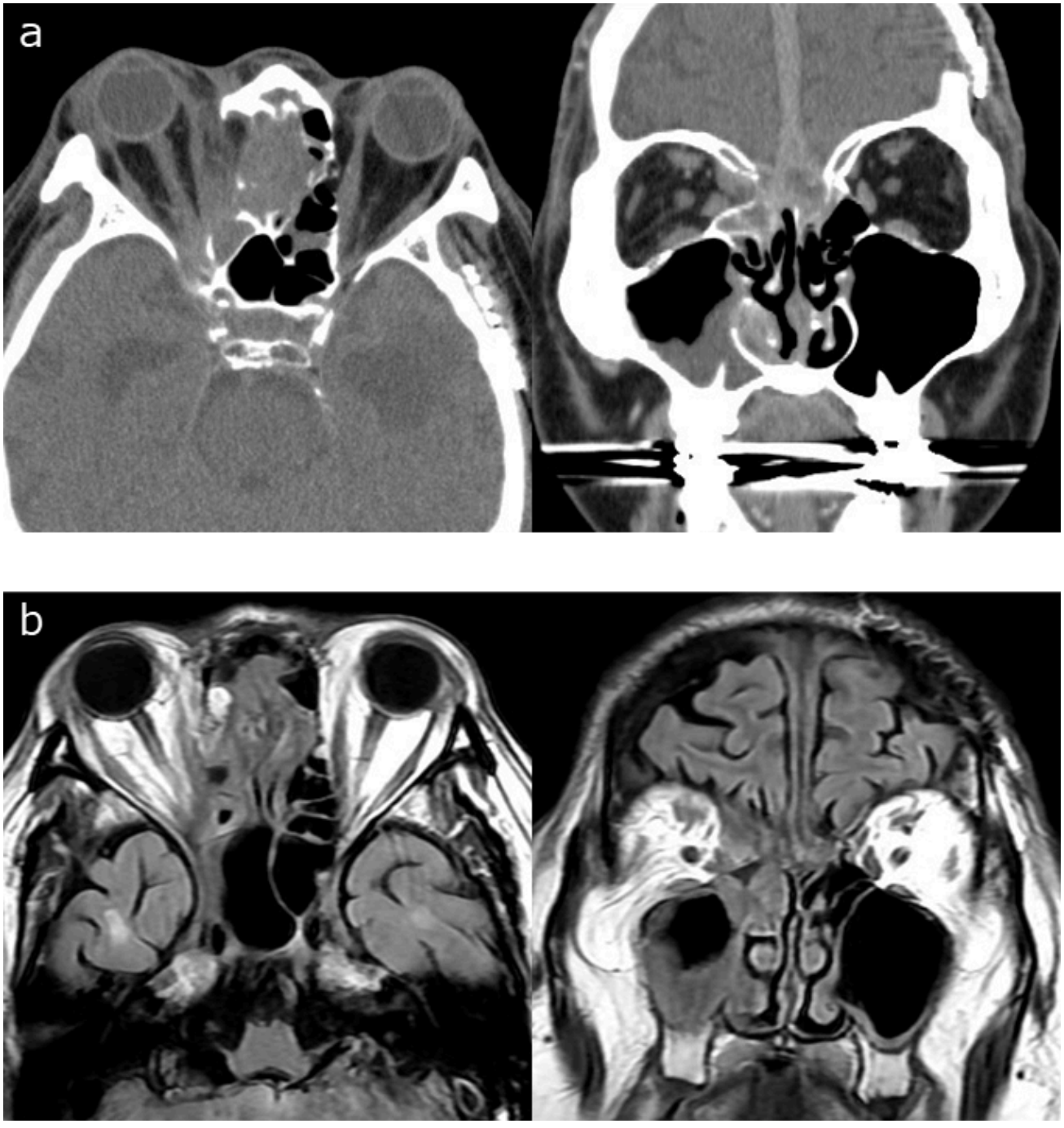

Figure 1

Imaging findings of the paranasal sinuses. (a) Computed tomography images show right-predominant opacification of the frontal, ethmoid, and maxillary sinuses, with bony destruction involving the orbital apex and skull base. (b) Magnetic resonance images show abnormal soft tissue extending from the right paranasal sinuses to the orbital apex and optic canal and involving the right optic nerve.

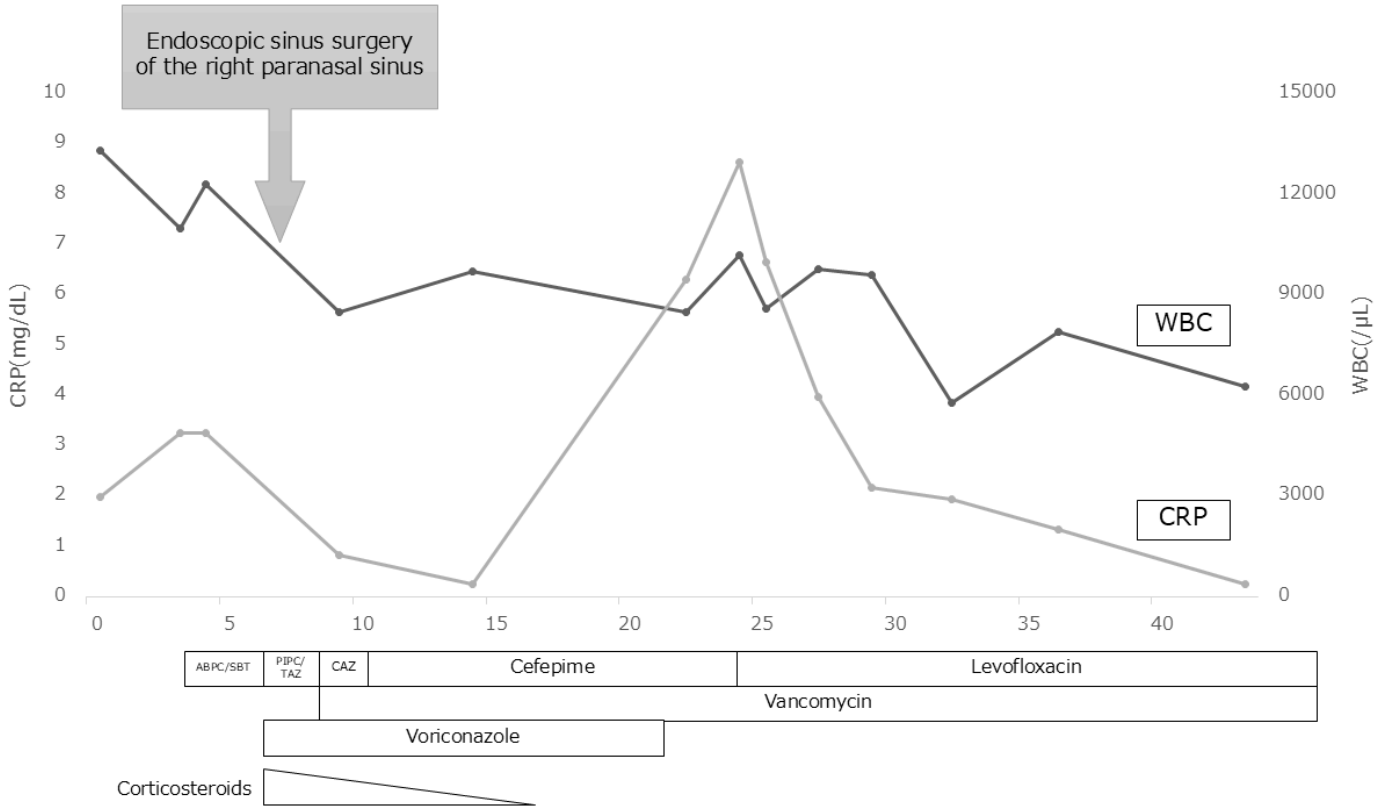

Figure 2

Clinical course showing changes in C-reactive protein (CRP) levels and white blood cell counts. ABPC/SBT, Ampicillin Sodium/Sulbactam Sodium; CAZ, Ceftazidime; PIPC/TAZ, Tazobactam/piperacillin