Research Square

Preprints are preliminary reports that have not undergone peer review.
They should not be considered conclusive, used to inform clinical practice,
or referenced by the media as validated information.

High-risk Pulmonary Embolism Associated with Drospirenone/Ethinylestradiol Tablets and In-hospital Cardiac Arrest: A Case Report of ECPR Combined with Mechanical Thrombectomy and Catheter-directed Thrombolysis

Mengyu Li
Zhejiang Chinese Medical University Hangzhou City
Ying Lin
Zhoushan Hospital of Zhejiang Province
Zhoubo Wang
Zhoushan Hospital of Zhejiang Province
Yuechuan Shen
137580315250163.com

Zhoushan Hospital of Zhejiang Province

Case Report

Keywords: Pulmonary embolism, Extracorporeal cardiopulmonary resuscitation, Extracorporeal membrane oxygenation, Mechanical thrombectomy, Catheter-directed thrombolysis

Posted Date: November 25th, 2026

DOI: https://doi.org/10.21203/rs.3.rs-11567412/v1

License: This work is licensed under a Creative Commons Attribution 4.0 International License.
Read Full License

Additional Declarations: No competing interests reported.

Abstract

Background: Estrogen-containing combined oral contraceptives (COCs) are established risk factors for venous thromboembolism (VTE). High-risk pulmonary embolism (PE) can rapidly progress to cardiac arrest; extracorporeal cardiopulmonary resuscitation (ECPR) provides circulatory support but requires adjunctive reperfusion.

Case Report: A 26-year-old woman developed chest tightness and dyspnea on day 8 of her second course of drospirenone/ethinylestradiol, and rapidly deteriorated into hypotension, altered consciousness, and in-hospital cardiac arrest. VA-ECMO was initiated for hemodynamic support, followed by mechanical aspiration thrombectomy and catheter-directed urokinase thrombolysis for residual distal thrombi. Thrombophilia work-up was negative. She was weaned from VA-ECMO on day 5, extubated on day 7, and discharged with a modified Rankin Scale score of 0.

Conclusions: PE should be suspected early in young women on estrogen-containing COCs with unexplained dyspnea or tachycardia, and bedside echocardiography is valuable for risk stratification. For PE-related cardiac arrest, ECPR offers a critical window but must be rapidly followed by reperfusion; anticoagulation during VA-ECMO demands careful balancing between circuit thrombosis and bleeding. After COC discontinuation, early recurrence risk is low, but lifelong avoidance of estrogen preparations is necessary.

1. Introduction

High-risk pulmonary embolism (PE), defined by cardiac arrest, obstructive shock, or persistent hypotension, arises from an acute increase in pulmonary vascular resistance leading to right ventricular failure and systemic hypoperfusion [1]. Some patients progress from a seemingly stable state to circulatory collapse within hours [2].

Estrogen-containing combined oral contraceptives (COCs) are well-documented risk factors for venous thromboembolism (VTE) [3], and the risk of drospirenone/ethinylestradiol is further influenced by estrogen dose, progestin type, and individual susceptibility [4]. COCs containing drospirenone and ethinylestradiol showed the highest proportional reporting ratio for VTE events in a recent pharmacovigilance analysis [5].

We present a case of high-risk PE with in-hospital cardiac arrest in a woman taking drospirenone/ethinylestradiol, who achieved a good outcome after ECPR, VA-ECMO, mechanical thrombectomy, and catheter-directed thrombolysis; we discuss the disease progression, reperfusion strategy, and anticoagulation management.

2. Case Presentation

A 26-year-old woman (body mass index 22 kg/m², never smoker, no recent travel, surgery, or trauma) presented to the emergency department on February 2, 2026, with a 4-hour history of sudden chest tightness, dyspnea, and anterior chest pain. Her menstrual cycles were irregular, and she had started drospirenone/ethinylestradiol tablets (drospirenone 3 mg/ethinylestradiol 0.03 mg) on November 24, 2025, completing one 28-day course. She discontinued the medication but resumed it on January 26, 2026, for persistent menstrual irregularity; symptoms began on day 8 of the second course. She had no personal or family history of thromboembolism.

On examination, temperature was 36.8°C, heart rate 128 bpm, respiratory rate 28/min, blood pressure 105/65 mmHg, and oxygen saturation 88% on oxygen via nasal cannula at 5 L/min. She was alert but anxious. Lung fields were clear, heart sounds were regular without murmurs, and there was no peripheral edema or clinical signs of deep vein thrombosis.

Electrocardiogram revealed sinus tachycardia, T-wave inversion in leads V1–V4, and an S1Q3T3 pattern (Fig. 1A). Arterial blood gas on 5 L/min oxygen showed pH 7.42, PaO_2 62 mmHg, $PaCO_2$ 35 mmHg, and lactate 2.8 mmol/L. D-dimer was markedly elevated at 4.46 mg/L FEU (normal < 0.5), high-sensitivity cardiac troponin I 0.08 ng/mL (normal < 0.04), and NT-proBNP 1850 pg/mL.

Bedside transthoracic echocardiography demonstrated a dilated right ventricle (RV/LV end-diastolic diameter ratio 1.2), reduced RV free wall motion, severe tricuspid regurgitation, and an estimated pulmonary artery systolic pressure of 55 mmHg, with preserved left ventricular ejection fraction. Given the echocardiographic findings, hypoxemia, and elevated biomarkers, acute high-risk PE was strongly suspected. While preparing for computed tomography pulmonary angiography (CTPA), the patient suddenly lost consciousness and was found in ventricular fibrillation. Immediate cardiopulmonary resuscitation (CPR) was initiated, and a single 200 J defibrillation restored sinus rhythm. However, systolic blood pressure could not be maintained above 60 mmHg, consistent with obstructive shock progressing to cardiac arrest.

Given the presence of a reversible cause (massive PE) and the failure of conventional CPR, the multidisciplinary team rapidly activated the ECPR protocol. Approximately 15 minutes after the onset of cardiac arrest, veno-arterial ECMO was established via the femoral route with an initial blood flow of 3.5 L/min. A subsequent electrocardiogram showed sinus tachycardia (Fig. 1B). After hemodynamic stabilization on VA-ECMO, CTPA was performed and confirmed extensive filling defects in the bilateral main pulmonary arteries and their branches, more severe on the right (Fig. 2).

3. Treatment

Following confirmation of massive PE, the Pulmonary Embolism Response Team (PERT) decided to proceed with percutaneous mechanical thrombectomy to reduce the proximal thrombus burden. A large-bore aspiration catheter (FlowTriever, Inari Medical) was used to aspirate thrombi from the bilateral main and lobar pulmonary arteries, yielding a large amount of dark red thrombus material. Post-procedure angiography showed patent main vessels but substantial residual thrombi at the segmental and

subsegmental levels (Fig. 3). To address these distal thrombi and further reduce pulmonary artery pressure, catheter-directed thrombolysis with urokinase (total 500,000 units administered in divided doses over 12 hours) was delivered into both pulmonary arteries. Follow-up echocardiography showed improved RV loading, with the RV/LV ratio reduced to 0.9.

The patient was transferred to the emergency intensive care unit on VA-ECMO. The ECMO parameters are summarized in Table 1. During cannulation, unfractionated heparin was administered as a bolus (5,000 IU). However, on day 1, active bleeding occurred at multiple sites (oral/nasal mucosa, gastric tube drainage, and cannulation sites) accompanied by hemodynamic instability, prompting temporary discontinuation of the heparin infusion. Despite this, the activated partial thromboplastin time (APTT) on day 1 remained elevated at 78 seconds, reflecting the residual heparin effect and possible consumption coagulopathy. Red blood cells (4 units), fresh frozen plasma (400 mL), and platelet concentrate (1 therapeutic dose) were transfused. On day 2, once bleeding had slowed, continuous heparin was restarted with a target APTT of 50–60 seconds (Table 1).

Table 1
VA-ECMO operational parameters and anticoagulation monitoring

VA-ECMO	**Day1**	**Day 2**	**Day 3**	**Day 4**	**Day 5**
Centrifugal pump speed (rpm)	3640	3235	3235	3305	3230
Blood flow rate (L/min)	2.98	2.89	2.96	3.02	2.75
Gas flow rate (L/min)	3	3	3	3	3
Oxygen concentration (%)	100	90	60	50	40
Water tank temperature (°C)	36	36	36	36	36
APTT (seconds)	78	68	61	63	65

*Heparin infusion was withheld on day 1 due to active bleeding; the APTT of 78 s reflects the residual effect of the cannulation bolus. Continuous heparin was restarted on day 2 with a target APTT of 50–60 s.

Serial laboratory data are presented in Table 2. Hemoglobin dropped from a baseline of 83 g/L to a nadir of 68 g/L, and platelet count fell to 48×10⁹/L. Liver enzymes (AST 495 U/L, ALT 202 U/L on day 1) were markedly elevated but decreased rapidly with hemodynamic improvement. Renal function remained normal throughout. D-dimer decreased from the admission value of 12.5 mg/L to 4.46 mg/L on day 1 (ECMO initiation), then rose to 19.52 mg/L on day 3 coinciding with thrombolytic therapy, and subsequently declined. C-reactive protein was mildly elevated, but blood cultures remained negative and chest imaging showed no new infiltrates, suggesting an inflammatory response to thrombus resolution rather than infection.

Table 2
Serial laboratory data from ECMO day 1 to day 5

Parameter	Day 1	Day 2	Day 3	Day 4	Day 5
Red blood cells (10^12/L)	2.75	2.28	2.28	2.45	2.33
White blood cells (10^9/L)	10.5	5.5	8.3	9.7	6.4
High-sensitivity C-reactive protein (mg/L)	61.3	31.1	129.9	172.2	167.4
Platelets (10^9/L)	67	48	63	48	49
Hemoglobin (g/L)	83	71	68	73	71
AST (U/L)	495	535	267	99	50
ALT (U/L)	202	170	129	95	69
Albumin (g/L)	30.1	30	36.6	37.5	33.1
Creatinine (μmol/L)	58	56	45	45	53
Troponin (ng/mL)	0.102	0.175	–	–	–
D-dimer (mg/L)	4.46	18.92	19.52	3.63	5.14
NSE (ng/mL)	–	27.1	12.9	–	4.7
Procalcitonin (ng/mL)	–	0.58	0.31	0.15	–

–, not measured; AST, aspartate aminotransferase; ALT, alanine aminotransferase; NSE, neuron-specific enolase; CRP, C-reactive protein.

After 5 days of VA-ECMO support, vasopressors were discontinued and the ECMO flow was gradually weaned to 1.0 L/min with FiO_2 40%. A pre-weaning pulmonary angiogram showed markedly reduced thrombus burden (Fig. 4). Echocardiography revealed a left ventricular ejection fraction of approximately 51% and substantial improvement in RV size and function. The patient was successfully decannulated on day 5. She was extubated on day 7, awake and oriented, with an electrocardiogram showing normal sinus rhythm at 78 bpm and resolution of T-wave changes (Fig. 1C). Neuron-specific enolase (NSE) decreased from a peak of 27.1 ng/mL to 4.7 ng/mL.

Thrombophilia screening (protein C, protein S, antithrombin III activity, antiphospholipid antibodies) was negative, though it was performed during the early anticoagulation period. Lower extremity venous ultrasound showed no deep venous thrombosis. The patient was discharged on hospital day 14 with a modified Rankin Scale score of 0. Discharge instructions included strict avoidance of estrogen-containing contraceptives; a progestin-only intrauterine device or barrier methods were recommended. Direct oral anticoagulant (rivaroxaban 15 mg twice daily for 21 days, then 20 mg daily) was prescribed for at least 6 months, with outpatient follow-up to reassess right ventricular function and pulmonary artery pressure before considering cessation.

4. Discussion and Conclusions

The onset of symptoms on day 8 of the second course of drospirenone/ethinylestradiol establishes a strong temporal link to COC exposure. Drospirenone-containing formulations carry the highest proportional reporting ratio for VTE in pharmacovigilance analyses [5]; given the negative thrombophilia screen—acknowledging that screening during early anticoagulation does not fully exclude an underlying predisposition—and the absence of other provoking factors, we classify this episode as COC-associated.

Early risk stratification in acute PE remains challenging. Our patient presented with normal blood pressure but tachycardia, hypoxemia, elevated biomarkers, and echocardiographic RV dysfunction, and progressed to cardiac arrest within hours, demonstrating that blood pressure alone is insufficient for early identification of high-risk PE. Guidelines advocate a multimodal approach combining clinical parameters, biomarkers, and imaging [6]. Bedside echocardiography is invaluable when patients cannot be safely transported for CTPA [7], and meta-analyses show that RV dysfunction on echocardiography predicts increased 30-day mortality even in hemodynamically stable patients [8]. In our patient, bedside echocardiography revealed marked right heart strain despite acceptable blood pressure, directly triggering intervention before overt decompensation.

For this patient with in-hospital cardiac arrest, the ECPR protocol was activated immediately, achieving a low-flow time of approximately 15 minutes—a factor instrumental in preserving neurological function. VA-ECMO provided right ventricular unloading and restored systemic perfusion, creating a critical window for definitive reperfusion; however, VA-ECMO alone does not remove the obstructing thrombi, and prompt reperfusion—mechanical thrombectomy, catheter-directed thrombolysis, or surgical embolectomy—is essential [9–11]. Registry data indicate that thrombectomy plus VA-ECMO (OR 0.50; 95% CI 0.41–0.61) or thrombolysis plus VA-ECMO (OR 0.60; 95% CI 0.43–0.85) is associated with lower in-hospital mortality than thrombolysis alone [9]. In our patient, rapid aspiration thrombectomy followed by localized thrombolysis reduced the clot burden and enabled ECMO weaning.

The combination of mechanical thrombectomy and catheter-directed thrombolysis was chosen because of the extensive thrombus distribution and the high bleeding risk during ECMO. Mechanical thrombectomy has become the predominant interventional modality [12], and the FLARE study confirmed that it reduces the RV/LV ratio by 25.1% with a 3.8% major adverse event rate [13]. In our patient, aspiration cleared the proximal thrombi, but considerable segmental and subsegmental clots remained, necessitating adjunctive catheter-directed urokinase; this minimized systemic fibrinolytic exposure while achieving comprehensive thrombus clearance. Urokinase was chosen over alteplase based on local availability and institutional protocol.

Anticoagulation during ECMO requires balancing prevention of circuit thrombosis against bleeding exacerbation. ECMO induces a multifactorial coagulopathy [14], with thrombocytopenia affecting up to 21% of adult patients and bleeding event rates of 16.6%–50.7% [15]. In our patient, heparin had to be interrupted for multisite oozing with transfusion support. A retrospective comparison showed that low-intensity heparin regimens are associated with fewer severe bleeding complications (11.5% vs. 32%, p =

0.012) and improved weaning success [16]; once bleeding was controlled on day 2, we restarted heparin at a conservative target APTT of 50–60 seconds, consistent with a low-intensity approach. Withholding heparin temporarily during active hemorrhage is feasible if ECMO flow is maintained, but requires close monitoring for thrombotic complications.

Two laboratory patterns merit brief interpretation. The marked elevation in liver enzymes (AST 495 U/L, ALT 202 U/L on day 1) with rapid decline is consistent with hypoxic hepatitis from low cardiac output and hepatic venous congestion, and generally resolves upon restoration of hemodynamics. The fall in D-dimer from 12.5 mg/L to 4.46 mg/L on day 1 likely reflects hemodilution from circuit priming and fluid resuscitation, whereas the rise on days 2–3 coincided with thrombolytic therapy and endogenous fibrinolysis—an expected phenomenon.

Neurological outcome was favorable (mRS 0 at discharge). NSE declined from 27.1 to 4.7 ng/mL, although NSE alone is insufficient for prognostication owing to variability from hemolysis and renal clearance [17]. This favorable result is attributable to the short low-flow time, high-quality CPR, and comprehensive post-resuscitation care. As survivors of high-risk PE may have mildly reduced exercise tolerance [17], structured cardiopulmonary follow-up is warranted.

For secondary prevention, the patient was counseled to avoid all estrogen-containing preparations lifelong. Given the clearly reversible provoking factor and the low reported risk of early recurrence after estrogen discontinuation [18], rivaroxaban was prescribed for at least 6 months, with follow-up echocardiography to assess right ventricular function and pulmonary pressures before considering cessation, in line with guideline-recommended 3–6 months of therapy for provoked VTE. With a negative thrombophilia screen and elimination of the trigger, extended anticoagulation is not anticipated, though the final decision will remain individualized.

In conclusion, this case of high-risk PE associated with drospirenone/ethinylestradiol demonstrates a successful multidisciplinary approach combining ECPR, mechanical thrombectomy, and catheter-directed thrombolysis. Key lessons are: (1) maintain high suspicion for PE in young women on estrogen-containing COCs with unexplained symptoms; (2) bedside echocardiography is crucial for early risk stratification; (3) ECPR provides a lifesaving window but must be rapidly followed by reperfusion; (4) anticoagulation during ECMO demands individualized, often low-intensity management; and (5) after COC discontinuation, early recurrence risk is low, but lifelong avoidance of estrogen preparations is mandatory.

Declarations

Conflict of Interest: The authors declare that they have no conflicts of interest related to this manuscript.

Ethical Statements: This study was approved by the Institutional Review Board of Zhejiang Zhoushan Hospital (No.2026-070-001). All procedures were in accordance with the ethical standards of the Helsinki Declaration. Written informed consent was obtained from the patient after a full explanation of

the study's nature, purpose, potential risks, and benefits. All personal identifiers have been removed to protect patient privacy.

Informed Consent: Informed consent was obtained from the individual participant included in the study.

Funding: Zhoushan Science and Technology Bureau Project (NO.2026C31088).

Author contributions: Mengyu Li and Yuechuan Shen conceived and designed the study and drafted the manuscript. Ying Lin collected and summarized the case data and performed the overall data analysis. Zhoubo Wang and Mengyu Li contributed to the statistical analysis for Tables 1 and 2. Yuechuan Shen and Ying Lin prepared Figures 1-4. All authors critically reviewed the manuscript and approved the final version.

References

1. Nasser MF, Jabri A, Limaye S, et al. Echocardiographic evaluation of pulmonary embolism: a review. J Am Soc Echocardiogr. 2023;36(9):906–12.
2. Becattini C, Vedovati MC, Pruszczyk P, et al. Oxygen saturation or respiratory rate to improve risk stratification in hemodynamically stable patients with acute pulmonary embolism. J Thromb Haemost. 2018;16(12):2397–402.
3. Practice Committee of the American Society for Reproductive Medicine. Combined hormonal contraception and the risk of venous thromboembolism: a guideline. Fertil Steril. 2017;107(1):43–51.
4. Khialani D, Rosendaal F, Vlieg AVH. Hormonal contraceptives and the risk of venous thrombosis [J]. Semin Thromb Hemost. 2020;46(8):865–71.
5. Raskin L, Didembourg M, Dogne JM, et al. Venous thromboembolism with combined oral contraceptives based on estrogen and progestin content: a disproportionality analysis of the United States Food and Drug Administration Adverse Event Reporting System database. Am J Obstet Gynecol. 2026;235(1):78–85.
6. Giannitsis E, Katus HA. Biomarkers for clinical decision-making in the management of pulmonary embolism. Clin Chem. 2017;63(1):91–100.
7. Thomas AL, Rupp JD, Suszanski J et al. Accuracy of point-of-care ultrasound versus consultative echocardiography to identify right ventricular dysfunction in emergency department patients with pulmonary embolism. Ann Emerg Med Published online June 18, 2026.
8. Barco S, Mahmoudpour SH, Planquette B, Sanchez O, Konstantinides SV, Meyer G. Prognostic value of right ventricular dysfunction or elevated cardiac biomarkers in patients with low-risk pulmonary embolism: a systematic review and meta-analysis. Eur Heart J. 2019;40(11):902–10.
9. Hobohm L, Sagoschen I, Habertheuer A, et al. Clinical use and outcome of extracorporeal membrane oxygenation in patients with pulmonary embolism. Resuscitation. 2022;170:285–92.

10. Farmakis IT, Sagoschen I, Barco S, et al. Extracorporeal membrane oxygenation and reperfusion strategies in high-risk pulmonary embolism hospitalizations. Crit Care Med. 2024;52(10):e512–21.
11. Meneveau N, Guillon B, Planquette B, et al. Outcomes after extracorporeal membrane oxygenation for the treatment of high-risk pulmonary embolism: a multicentre series of 52 cases. Eur Heart J. 2018;39(47):4196–204.
12. Kim JM, Horbal SR, Mewaldt C, et al. Mechanical thrombectomy and catheter-directed thrombolysis in acute pulmonary embolism: trends and practice patterns in the PERT Consortium Registry (2016–2024). J Am Coll Cardiol. 2026;87(13):1574–90.
13. Tu T, Toma C, Tapson VF, et al. A prospective, single-arm, multicenter trial of catheter-directed mechanical thrombectomy for intermediate-risk acute pulmonary embolism: the FLARE Study. JACC Cardiovasc Interv. 2019;12(9):859–69.
14. Thomas J, Kostousov V, Teruya J. Bleeding and thrombotic complications in the use of extracorporeal membrane oxygenation. Semin Thromb Hemost. 2018;44(1):20–9.
15. Jiritano F, Serraino GF, Ten Cate H, et al. Platelets and extra-corporeal membrane oxygenation in adult patients: a systematic review and meta-analysis. Intensive Care Med. 2020;46(6):1154–69.
16. Raman J, Alimohamed M, Dobrilovic N, Lateef O, Aziz S. A comparison of low and standard anti-coagulation regimens in extracorporeal membrane oxygenation. J Heart Lung Transpl. 2019;38(4):433–9.
17. Stadlbauer A, Philipp A, Blecha S, et al. Long-term follow-up and quality of life in patients receiving extracorporeal membrane oxygenation for pulmonary embolism and cardiogenic shock. Ann Intensive Care. 2021;11(1):181.
18. Verstraete A, Vanassche T, Blanco-Molina A et al. Venous thromboembolism in women on estrogen therapy: presentation, management, and outcomes in the RIETE registry. Blood Adv Published online June 30, 2026.

Figures

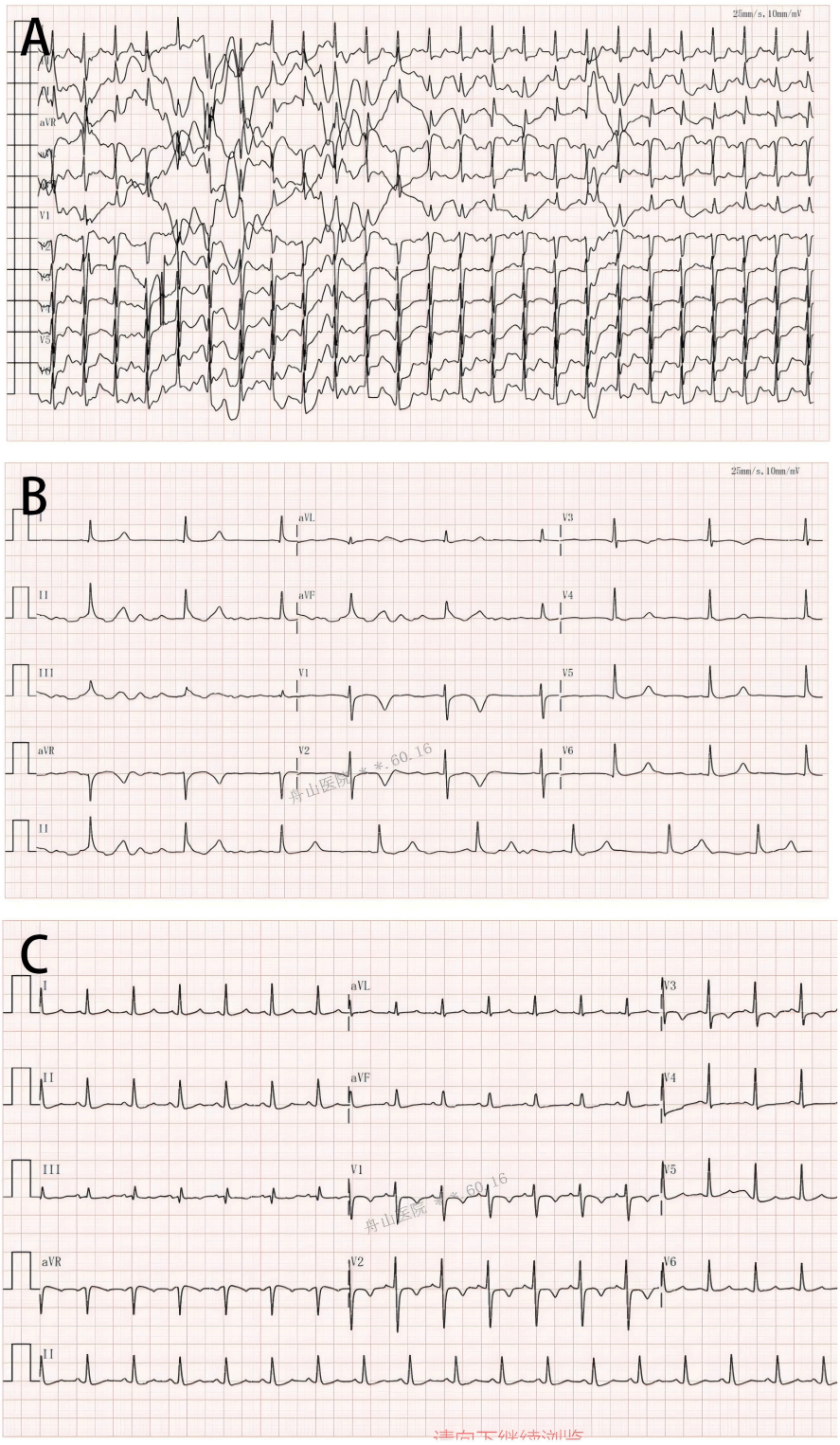

Figure 1

Serial 12-lead electrocardiograms. (A) On admission showing sinus tachycardia and S1Q3T3 pattern. (B) After VA-ECMO initiation, persistent sinus tachycardia. (C) After ECMO weaning, normal sinus rhythm with resolution of T-wave abnormalities.

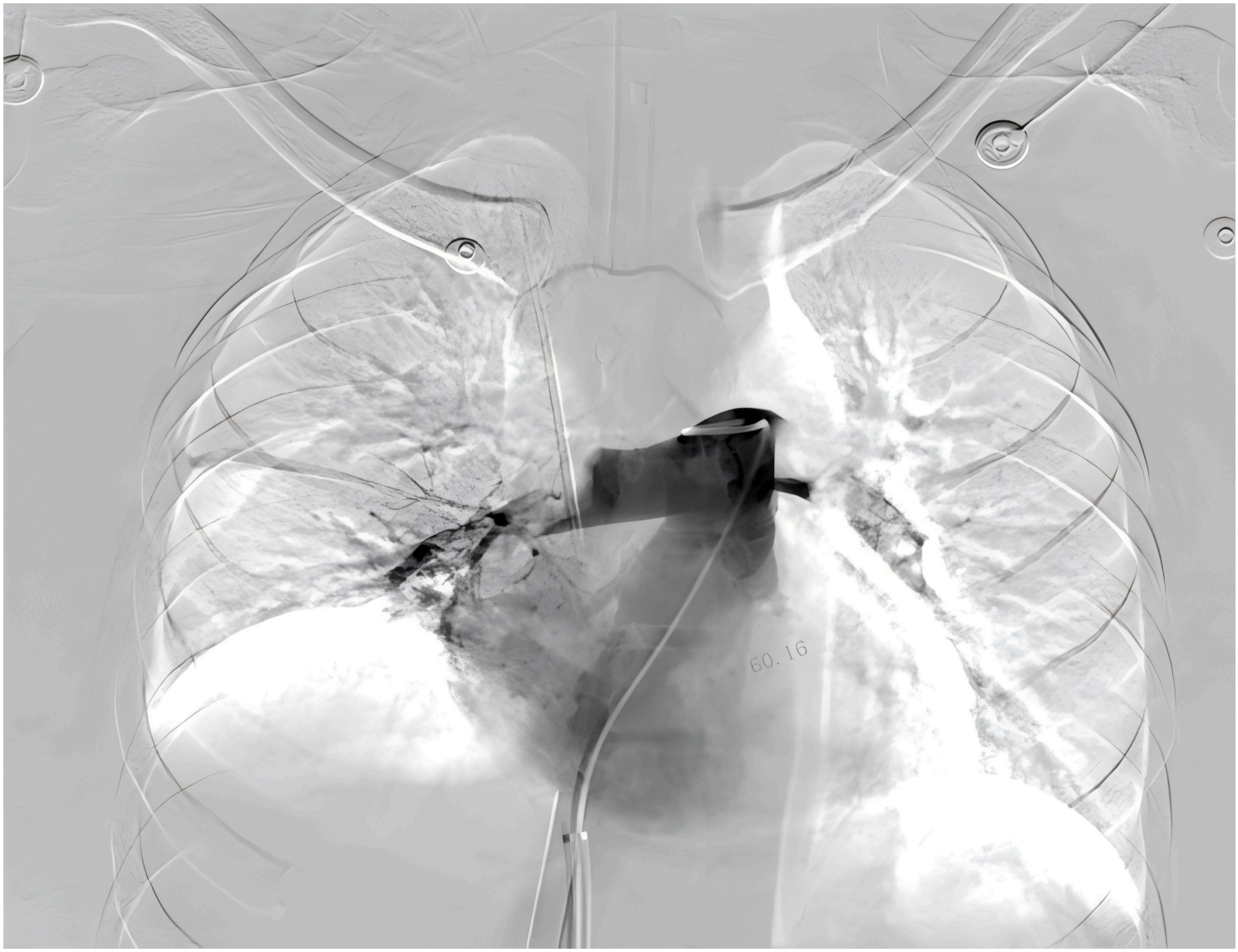

Figure 2

CT pulmonary angiography on admission demonstrating extensive filling defects in the bilateral main pulmonary arteries (arrows), consistent with massive pulmonary embolism.



Figure 3

Pulmonary angiography immediately after mechanical aspiration thrombectomy showing patent main arteries but residual thrombi at segmental and subsegmental levels.



Figure 4

Repeat pulmonary angiography before ECMO weaning (day 5) revealing marked reduction of thrombus burden.