Research Square

Preprints are preliminary reports that have not undergone peer review.
They should not be considered conclusive, used to inform clinical practice,
or referenced by the media as validated information.

Autologous Serum Eye Drops as Adjuvant Therapy for Severe Acute Ocular Stevens-Johnson Syndrome: A 10-Year Prospective Interventional Case Series

Shu-I Yeh

shuiyeh@gmail.com

Mackay Memorial Hospital

Hsin-Ming Liu

Ting-Wen Chu

Huey-Chuan Cheng

Yeou-Ping Tsao

Article

Keywords:

Posted Date: November 23rd, 2026

DOI: https://doi.org/10.21203/rs.3.rs-11555101/v1

License: This work is licensed under a Creative Commons Attribution 4.0 International License.
Read Full License

Additional Declarations: There is no conflict of interest

Abstract

Purpose

To evaluate the efficacy and long-term outcomes of early autologous serum (AS) eye drop intervention during the acute phase of severe ocular Stevens-Johnson syndrome and toxic epidermal necrolysis (SJS/TEN).

Methods

This is a prospective, uncontrolled, interventional case series that enrolled 12 consecutive patients (24 eyes) diagnosed with moderate to extremely severe acute ocular SJS/TEN at presentation, based on clinical examination, at a tertiary referral center from January 2015 to December 2025. All eyes underwent AS treatment during the acute phase of the ocular disease (within 7 days of onset) for at least one month with a follow-up for at least 3 months. Demographic data, baseline clinical features, and treatment outcomes were analyzed. Outcome measures included Schirmer I test, Ocular Surface Disease Index (OSDI), non-invasive keratograph break-up time (NIKBUT), and meibomian gland (MG) dropout using the Oculus Keratograph 5M.

Results

24 eyes from 12 patients were included (75.0% female; median follow-up, 13.5 months). 83.3% of eyes presented with severe to extremely severe acute-phase involvement. None eyes developed severe chronic complications. The median COCS at the final follow-up was 2.0 (IQR, 1.0–2.0). Regarding long-term ocular surface status, 68.2% of eyes had severe aqueous tear deficiency (Schirmer I test < 5 mm/5 min), and 36.4% of patients reported moderate-to-severe symptoms on the OSDI.

Conclusions

Early AS intervention during the acute phase of severe ocular SJS/TEN was associated with recovery of the severely damaged ocular surface, favorable long-term outcomes, and a low burden of chronic cicatricial complications.

Introduction

Stevens-Johnson syndrome (SJS) and its more severe variant, toxic epidermal necrolysis (TEN), are rare but potentially life-threatening immune-mediated mucocutaneous diseases, typically triggered by medications or infections and characterized by extensive epidermal necrolysis and mucosal bullae [1, 2]. Although the pathophysiology of the SJS/TEN spectrum remains incompletely understood, acute ocular involvement is highly prevalent, affecting 40% to 84% of patients. Acute ocular SJS/TEN is characterized

by severe surface inflammation, including conjunctival hyperemia, membranous conjunctivitis, and widespread epithelial defects involving the cornea, conjunctiva, and lid margins. Uncontrolled inflammation can rapidly lead to ocular surface keratinization and cicatrization [3]. Chronic ocular sequelae occur in 43% to 89% of patients and include severe dry eye disease, meibomian gland dysfunction and atrophy, ocular surface keratinization, symblepharon, and limbal stem cell deficiency, which may result in irreversible visual loss.

Primary ophthalmic management during the acute phase focuses on intensive supportive care, including close ocular monitoring, mechanical debridement, aggressive preservative-free lubrication, topical corticosteroids, and prophylactic antibiotics. In severe cases with corneal or conjunctival epithelial defects, eyelid margin involvement, or membrane formation, early amniotic membrane transplantation (AMT) within 4 to 7 days of onset has been shown to reduce long-term cicatricial sequelae. However, standardized global protocols remain lacking, and limited AMT availability and persistent inflammation highlight the need for accessible adjunctive therapies to stabilize the acute ocular surface [4–6]. Autologous serum (AS) is a blood-derived biologic product that closely resembles the biochemical composition of natural tears. Rich in neurotrophic and epitheliotropic factors, including epidermal growth factor, transforming growth factor-beta (TGF-β), fibronectin, and vitamin A, AS provides a regenerative microenvironment without the preservative-related toxicity of commercial lubricants [5]. Since its introduction in 1975 for aqueous deficiency [7], AS has become an established treatment for refractory ocular surface disorders, including severe dry eye disease, persistent epithelial defects, and neurotrophic keratopathy [8].

Furthermore, AS effectively controls severe ocular surface inflammation in autoimmune conditions such as Sjögren's syndrome, ocular graft-versus-host disease, and mucous membrane pemphigoid [5]. Although active systemic immunologic disease requires diligent monitoring, AS demonstrates an excellent safety profile with minimal adverse events [9]. However, while its efficacy in chronic SJS is documented, initiating AS during the hyperacute phase of SJS/TEN remains reserved. Therefore, this study evaluates long-term outcomes of early topical AS—as an adjunct or accessible alternative to AMT—in moderate-to-extremely severe acute ocular SJS/TEN to provide evidence for preserving ocular surface integrity and mitigating cicatricial complications.

Methods

Between January 2015 and January 2025, we conducted a prospective interventional case series of consecutive patients diagnosed with moderate to extremely severe acute ocular SJS/TEN at a tertiary referral center in Taiwan (Mackay Memorial Hospital, Taipei). The study protocol was approved by the Institutional Review Board of Mackay Memorial Hospital (IRB identifier: 25MMHIS011e) and adhered to the tenets of the Declaration of Helsinki. Written informed consent was obtained from all participants. Eligibility criteria were: (1) a definitive diagnosis of SJS, SJS/TEN overlap, or TEN confirmed by a board-certified dermatologist; (2) a definitive diagnosis of acute ocular SJS/TEN after comprehensive evaluation by a board-certified ophthalmologist; (3) moderate, severe, or extremely severe acute ocular

involvement based on the severity of corneal and/or conjunctival epithelial sloughing; and (4) initiation of topical AS as an adjunct to conventional medical therapy within 7 days of ocular symptom onset. Exclusion criteria were active corneal infection, delayed AS initiation (> 7 days after symptom onset), and a follow-up duration of less than 3 months. To prevent selection bias, all eligible consecutive cases were enrolled. Recorded clinical parameters encompassed demographics, intensive care or burn unit admission history, culprit medications, systemic and ocular manifestations, treatment protocols, and chronic sequelae evaluated over the follow-up period.

Acute Phase Evaluation and Grading

All patients with SJS/TEN admitted to the burn intensive care unit (ICU), irrespective of dermatological severity, routinely received an ophthalmologic consultation within 7 days of admission. A corneal specialist performed comprehensive bedside examinations using a portable slit lamp. Topical anesthesia was administered before gently placing an eyelid speculum to facilitate visualization. Fluorescein dye was used to detect epithelial defects, and the extent and location of staining were documented through clinical photographs and written descriptions. Upper and lower palpebral fornices were meticulously inspected under cobalt-blue illumination via lid eversion or gentle retraction. Positive lid margin fluorescein staining or pseudomembrane formation was defined as clinical evidence of localized epithelial sloughing.

The severity of acute ocular manifestations was graded and categorized using a modified Acute Ocular Score (mAOS) on a 5-point scale (grades 0–4), defined as follows: Grade 0 (none), no ocular involvement; Grade 1 (mild), conjunctival hyperemia only; Grade 2 (moderate), corneal punctate epitheliopathy or conjunctival epithelial sloughing (palpebral, bulbar, or eyelid margins) < 1 cm in maximum diameter; Grade 3 (severe), corneal epithelial erosion or conjunctival epithelial sloughing > 1 cm in maximum diameter; and Grade 4 (extremely severe), coexistence of corneal and conjunctival defects meeting Grade 3 criteria, or multiple conjunctival epithelial defects > 1 cm in maximum diameter [10].

Medical Interventions

All patients with acute ocular SJS/TEN received standardized medical therapy in both eyes and early high-dose pulse therapy to suppress the acute inflammatory surge. Daily ophthalmologic evaluations were conducted until complete re-epithelialization of the ocular surface was confirmed by negative fluorescein staining. Conventional medical interventions included topical antibiotics (levofloxacin 0.5% eye drops 4 times daily), topical steroids (prednisolone acetate 1% eye drops every 2 hours daily for 1 week, tapered to 4 times daily for 1 month, and dexamethasone 0.1% ophthalmic ointment twice daily), and topical lubricants (preservative-free artificial tears at least 4 times daily and ophthalmic ointment once or twice daily for 6 months). In severe and extremely severe cases, sweeping of the palpebral fornices and debridement were performed twice daily during the first 2 weeks post-onset, and subsequently once daily until acute inflammation subsided. Patients with extremely severe acute ocular

SJS/TEN developed rapidly progressing inflammatory adhesions that necessitated fornix sweeping more than twice daily; symblepharon rings were subsequently inserted. Additionally, therapeutic bandage soft contact lenses (Acuvue Oasys®, Johnson & Johnson, 14.5-mm diameter, plano, Senofilcon A) were applied to all corneas with epithelial erosions beyond punctate epitheliopathy and exchanged weekly until the epithelial defects resolved. Ocular surface epithelial defects served as the primary indication for initiating AS therapy. Accordingly, all moderate, severe, and extremely severe cases received 20% AS eye drops according to a structured regimen: hourly during the first week, every 2 hours during the second week, and four times daily for the remaining 2 weeks.

Preparation of 20% Autologous Serum

AS was prepared under rigorous aseptic protocols. Approximately 10 mL of peripheral venous blood was drawn into plain non-anticoagulated tubes. The blood samples were incubated at room temperature for 60 minutes to allow complete clot formation and fibrin retraction, followed by centrifugation at 3000 $\times$ g for 5 minutes to isolate the serum. Under a sterile laminar flow hood, 3 mL of the supernatant serum was collected and diluted with 12 mL of Balanced Salt Solution (BSS) to yield a 20% concentration. The final AS solution was dispensed into sterile amber dropper bottles. Patients were instructed to store the bottle currently in use in a refrigerator at 4°C to prevent bacterial contamination.

Long-term Outcome Measures and Grading

All patients were followed for a minimum of 3 months. Long-term outcomes were assessed via slit-lamp biomicroscopy and the Chronic Ocular Surface Complications Score (COCS; score range, 0–15), which encompasses six clinical parameters: conjunctival hyperemia (1 point); aqueous deficiency (Schirmer I test $\leq$ 5mm/5 min) (1 point); eyelid abnormalities, including trichiasis, distichiasis, or severe meibomian gland dysfunction (1 point each); corneal lesions, such as superficial punctate keratitis, thinning, or opacity (1 point each); limbal stem cell deficiency (1–3 points, ranging from partial neovascularization to total conjunctivalization); and symblepharon (1–4 points, graded by quadrant involvement). Severe chronic complications were defined as a COCS $\geq$ 8 [11].

For surviving patients, secondary assessments were conducted at the final follow-up (minimum 3 months post-presentation). Tear production was evaluated using the Schirmer I test with anesthesia and categorized as extremely dry (< 5 mm/5 min), moderately dry (5–9 mm/5 min), mildly dry (10–15 mm/5 min), or normal (> 15 mm/5 min) [12]. Subjective symptoms were quantified using the Ocular Surface Disease Index (OSDI) questionnaire, with scores classified as normal (0–12), mild (13–22), moderate (23–32), or severe (33–100). [13] Objective tear film stability and meibomian gland (MG) morphology were evaluated using the Oculus Keratograph 5M (Oculus GmbH, Wetzlar, Germany). Non-invasive keratograph break-up time (NIKBUT) average was recorded, with values $\geq$ 10 seconds considered within the normal range. MG dropout was staged via non-contact infrared meibography using a standard 4-point scale: Grade 0 (no loss), Grade 1 (< 33% loss), Grade 2 (33–67% loss), and Grade 3 (> 67% loss).

Statistical Analysis

Continuous variables were evaluated for distribution. Given the small sample size (*N = 12*) non-parametric statistical methods were employed. Continuous parameters are reported as median (interquartile range, IQR). Categorical and ordinal clinical variables are presented as absolute counts and percentages [*n* (%)]. Clinical outcomes were analyzed on an individual eye or patient basis, as appropriate. All statistical analyses were performed using R software version 4.4.2 (R Foundation for Statistical Computing, Vienna, Austria).

Results

Patient Recruitment and Demographics

Between January 2015 and December 2025, 132 patients were diagnosed with SJS, SJS/TEN overlap, or TEN at our institution. The primary etiologies included nonsteroidal anti-inflammatory drugs (27.3%, n = 36), antibiotics (36.4%, n = 48), and antiepileptics (36.4%, n = 48). Fifty patients (37.9%) received ophthalmology consultation, and 13 (9.8%) were diagnosed with moderate to extremely severe ocular involvement and received topical AS treatment during the acute phase. One patient was excluded due to mortality within the first month of follow-up. Consequently, 12 patients (24 eyes) met the inclusion criteria, and the demographic data were summarized in Table 1. The median age at presentation was 41 years (IQR, 21.5–52.5), with a female predominance (75.0%, n = 9). The cohort comprised 7 patients with SJS (58.3%), 1 with SJS/TEN overlap (8.3%), and 4 with TEN (33.3%). Regarding systemic and ocular management, 6 patients (50.0%) required admission to the burn ICU, and 6 patients (50.0%) underwent symblepharon ring insertion during the acute stage.

Acute Ocular Severity and Follow-Up

At presentation, acute ocular involvement was graded as moderate (mAOS = 2) in 4 eyes (16.7%), severe (mAOS = 3) in 5 eyes (20.8%), and extremely severe (mAOS = 4) in 15 eyes (62.5%). Representative clinical manifestations of moderate to extremely severe acute involvement and their long-term ocular outcomes are illustrated in Figs. 1–3. The median follow-up duration was 13.5 months (IQR, 5.5–54.0). Overall, 9 patients (75.0%) were followed for at least 6 months, and 7 patients (58.3%) maintained follow-up for 12 months or longer. Two patients (Cases 2 and 8) succumbed to systemic complications during the follow-up period.

Chronic Ocular Surface Complications Score (COCS)

The long-term ocular outcomes are detailed in Table 2. Notably, despite the high prevalence of extremely severe acute involvement, none of the patients progressed to severe chronic ocular surface complications. At the final follow-up, the median COCS was 2.0 (IQR, 1.0–2.0). Recorded chronic complications included dry eye disease in 10 patients (83.3%), superficial punctate keratitis in 4 patients

(33.3%; Fig. 1), palpebral conjunctival cicatrization in 4 patients (33.3%; Fig. 2), and MG atrophy in 7 patients (58.3%; Fig. 3). Only 1 patient (8.3%) exhibited residual mild symblepharon.

Tear Film, Meibomian Gland, and Symptomatic Assessment

Objective metrics indicated varying degrees of tear film dysfunction at the final follow-up. The Schirmer I test (N = 22 eyes) revealed aqueous deficiency in most eyes, with 15 eyes (68.2%) classified as extremely dry (< 5 mm/5 min), 3 (13.6%) as moderately dry, and 4 (18.2%) as mildly dry. Notably, despite pervasive low tear volume, NIKBUT (N = 16 eyes) remained within the normal range ($\geq$ 10 seconds) in 13 eyes (81.3%), with only 3 eyes (18.8%) demonstrating an abnormal break-up time (<10 seconds). Meibography (N = 16 eyes) demonstrated MG dropout of < 33% (Grade 1) in 5 eyes (31.3%), 33%–67% (Grade 2) in 8 eyes (50.0%), and > 67% (Grade 3) in 3 eyes (18.8%). The OSDI questionnaire (N = 11 patients) reflected a spectrum of patient-reported symptoms: 4 patients (36.4%) were categorized as normal, 3 (27.3%) as mild, 3 (27.3%) as moderate, and 1 (9.1%) as severe.

Discussion

Acute ocular involvement in SJS/TEN can cause severe and potentially irreversible visual impairment. Because mucosal disease may be disproportionate to cutaneous involvement, all patients with SJS/TEN require prompt ophthalmologic evaluation and severity grading to guide treatment [10, 14]. Mild-to-moderate disease may be managed with close observation and medical therapy, whereas severe and extremely severe disease requires urgent intervention to limit cicatricial complications. In our study, we followed standard medical management of acute ocular SJS/TEN, including withdrawal of the offending drug, topical and systemic corticosteroids, prophylactic antibiotics, and lubrication with artificial tears [10, 15]. However, patients with severe ocular surface damage require additional adjunct treatment to promote epithelial healing and reduce long-term sequelae.

Early AMT has been shown to act as a biological bandage in acute ocular SJS/TEN and is generally recommended within the first week to limit irreversible cicatricial changes [4, 6, 16, 17]. AMT suppresses inflammation, reduces fibrosis, and promotes epithelialization, thereby potentially reducing symblepharon, corneal scarring, and severe dry eye [17–20]. Although AMT is an established adjunctive treatment, its use may be limited by tissue availability, processing requirements, cost, and the need for procedural expertise. AS eye drops may provide a more accessible and economical alternative when AMT is unavailable or impractical. Both therapies promote epithelialization, modulate ocular surface inflammation, and may reduce cicatricial complications [12, 21, 22]. In a prospective randomized controlled trial, Sharma et al. demonstrated benefits of adjunctive AMT compared with medical therapy alone in patients with acute ocular SJS/TEN. However, their cohort had relatively mild ocular involvement: 88% had lid edema, conjunctival injection, or chemosis, whereas epithelial defects and eyelid membranes were reported in only 4% and 32% of AMT-treated eyes, respectively [18]. In contrast, all eyes in our cohort had epithelial defects, and 83.3% had severe (20.8%) or extremely severe (62.5%)

epithelial sloughing. Our cohort therefore represents a substantially more severe population, and our findings evidenced that 20% AS was an effective adjunct management for advanced acute ocular SJS/TEN.

Traditional sutured AMT may require an operating-room procedure and, in some cases, general anesthesia, whereas newer delivery methods have their own advantages and limitations. Glued AMT using fibrin or cyanoacrylate adhesives allows rapid application but remains supported by limited clinical evidence in SJS/TEN. Self-retaining devices such as Prokera® facilitate immediate, painless placement but may not provide complete coverage of the ocular surface. Hybrid techniques combining customized symblepharon rings with glued fixation of the eyelid margins have been proposed to achieve more extensive ocular surface coverage under topical anesthesia [20, 23, 24]. In our series, 20% AS provided a readily accessible approach for severely compromised ocular surfaces, particularly when AMT was unavailable or complex delivery was impractical. In severely affected eyes, a symblepharon ring mechanically separated injured mucosal surfaces and maintained fornical depth, potentially facilitating AS distribution and reducing cicatricial adhesions during the acute phase.

The pathophysiology of SJS/TEN is driven by an overwhelming surge of pro-inflammatory mediators, triggering a localized and systemic cytokine storm. This hyperactivates immune cell populations—specifically cytotoxic T-lymphocytes ($CD8^+$ T cells) and Natural Killer (NK) cells—which aggressively infiltrate the skin and mucous membranes. This immune activation floods tissues with key cytokines (including TNF-α, IFN-γ, IL-6, IL-8, and IL-18) and cytolytic proteins like granulysin, perforin, and granzyme B. Together, this hyperinflammatory environment induces rapid, widespread keratinocyte death via apoptosis and necroptosis, culminating in severe mucocutaneous blistering and ocular surface destruction [25, 26]. Although SJS/TEN is classified as a delayed T-cell-mediated hypersensitivity reaction, harvest or use of autologous serum (AS) during the acute phase poses major safety risks due to persistent systemic inflammation. Multi-cytokine profiling of acute-phase tears and serum confirms marked elevations of both pro- and anti-inflammatory cytokines, particularly IL-6, IL-8, and MCP-1 [27]. In our case series, all patients received early high-dose corticosteroid pulse therapy to suppress the acute inflammatory surge during the initial phase of Stevens-Johnson syndrome/toxic epidermal necrolysis (SJS/TEN). Corticosteroids function as broad-spectrum immunosuppressants that inhibit Th1- and monocyte-derived cytokines. While pulse and standard corticosteroids share similar cytokine-targeting profiles, high-dose pulse administration more efficiently suppresses monocyte-derived cytokines [28]. Consequently, the AS harvested under this anti-inflammatory regimen likely contained lower baseline levels of pro-inflammatory cytokines. Furthermore, combining AS with intensive topical corticosteroids effectively suppressed the ocular surface cytokine storm, reversing tissue damage and accelerating epithelial recovery.

In this prospective study, early topical AS therapy initiated within 7 days of disease onset was associated with favorable long-term ocular outcomes despite severe to extremely severe acute ocular involvement, with 83.3% of eyes having mAOS grades 3–4. At a median follow-up of 13.5 months, the median COCS was 2.0 (IQR, 1.0–2.0), and no patients developed severe chronic sequelae (COCS ≥ 8). Patient-reported

outcomes were also generally favorable, with 36.4% of patients (4/11) having normal OSDI scores. These findings support the potential role of early epithelium-targeted and anti-inflammatory intervention in limiting chronic ocular surface complications following acute SJS/TEN [3, 5, 8].

A notable finding was the apparent “tear film paradox.” Although 68.2% of eyes had severe aqueous tear deficiency (Schirmer I < 5 mm/5 min), 81.3% had normal NIKBUT (≥ 10 seconds), suggesting preserved tear film stability despite reduced aqueous production. Consistently, 63.6% of patients reported normal-to-mild dry-eye symptoms on the OSDI. Chronic ocular surface disease in SJS/TEN is multifactorial and may involve lacrimal drainage obstruction, MG dysfunction or loss and conjunctival goblet cell depletion [1]. We hypothesize that early AS therapy may help limit irreversible cicatricial damage to the conjunctival epithelium and submucosal structures, potentially preserving residual goblet cell populations and mucin-layer integrity. Preservation of the mucin layer may enhance corneal epithelial wettability, allowing even a relatively small aqueous volume to contribute to tear film stability. [29] Similarly, although 68.8% of eyes exhibited moderate-to-severe MG dropout (> 33%), residual MG function may have provided sufficient lipid coverage to limit excessive tear evaporation, particularly when the lid margins remained relatively free of severe cicatricial distortion.

To our knowledge, this is one of the few prospective studies to combine standardized clinical scores with multimodal objective assessment of long-term ocular outcomes after early AS therapy in SJS/TEN. Nevertheless, several limitations warrant consideration. First, the sample size was relatively small (N = 12) and lacked a parallel control group, reflecting the rarity of SJS/TEN and the ethical challenges of withholding adjunctive regenerative therapies in this sight-threatening acute condition. Consequently, direct causal evidence supporting the standalone therapeutic efficacy of AS remains limited, and our findings should be interpreted as a preliminary case series demonstrating safety and favorable clinical associations rather than definitive proof of treatment superiority. Second, while acute SJS/TEN involves a profound systemic inflammatory state and cytokine storm, our study did not evaluate systemic or local tear cytokine levels, limiting our ability to directly elucidate the biochemical interactions between circulating inflammatory mediators and topical AS administration. Third, the duration of follow-up varied among patients (3–96 months), reflecting the observational nature of long-term follow-up in this cohort. Larger multicenter prospective studies incorporating biomarker analyses and standardized treatment protocols are warranted to validate these findings, clarify the exact biochemical mechanisms of AS in the presence of acute systemic inflammation, and evaluate AS in combination with sutureless amniotic membrane transplantation or ocular surface conformers.

Conclusion

Early AS administration led to rapid re-epithelialization of severe corneal and conjunctival epithelial defects during the acute inflammatory phase of ocular SJS/TEN. Despite substantial acute ocular involvement, no patients developed severe chronic ocular surface complications, although aqueous tear deficiency and MG dropout remained common. These findings suggest that early AS therapy may be a viable and accessible treatment option for acute ocular SJS/TEN, particularly when AMT is unavailable

or impractical. Larger prospective multicenter studies are warranted to further evaluate its efficacy and define its role alongside other ocular surface–preserving interventions.

Declarations

Financial Support

None.

Conflict of Interest:

No conflicting relationship exists for any author.

Data availability

The data that support the findings of this study are not openly available due to reasons of sensitivity and are available from the corresponding author upon reasonable request and located in controlled access data storage.

References

1. Pisitpayat P, Nijvipakul S, Jongkhajornpong P: Ocular involvement in Steven-Johnson syndrome/toxic epidermal necrolysis: recent insights into pathophysiology, biomarkers, and therapeutic strategies. Curr Opin Ophthalmol 2024, 35(6):499–506.
2. Ueta M, Inoue C, Nakata M, Sotozono C, Kim MK, Wakamatsu T, Jongkhajornpong P, Saeed H, Rauz S, Ma DH et al: Severe ocular complications of SJS/TEN and associations among pre-onset, acute, and chronic factors: a report from the international ophthalmology collaborative group. Front Med (Lausanne) 2023, 10:1189140.
3. Saito Y, Abe R: New insights into the diagnosis and management of Stevens-Johnson syndrome and toxic epidermal necrolysis. Curr Opin Allergy Clin Immunol 2023, 23(4):271–278.
4. Gregory DG: Treatment of acute Stevens-Johnson syndrome and toxic epidermal necrolysis using amniotic membrane: a review of 10 consecutive cases. Ophthalmology 2011, 118(5):908–914.
5. Ripa M, Jabbehdari S, Yazdanpanah G, Lukacs E, Karcher B, Iqbal O, Bouchard C: The Role of Multisystem Disease in Composition of Autologous Serum tears and ocular surface symptom improvement. Ocul Surf 2020, 18(3):499–504.
6. Shanbhag SS, Hall L, Chodosh J, Saeed HN: Long-term outcomes of amniotic membrane treatment in acute Stevens-Johnson syndrome/toxic epidermal necrolysis. Ocul Surf 2020, 18(3):517–522.
7. Ralph RA, Doane MG, Dohlman CH: Clinical experience with a mobile ocular perfusion pump. Arch Ophthalmol 1975, 93(10):1039–1043.

8. Vazirani J, Sridhar U, Gokhale N, Doddigarla VR, Sharma S, Basu S: Autologous serum eye drops in dry eye disease: Preferred practice pattern guidelines. Indian J Ophthalmol 2023, 71(4):1357–1363.
9. Tsubota K, Goto E, Fujita H, Ono M, Inoue H, Saito I, Shimmura S: Treatment of dry eye by autologous serum application in Sjogren's syndrome. Br J Ophthalmol 1999, 83(4):390–395.
10. Gregory DG: New Grading System and Treatment Guidelines for the Acute Ocular Manifestations of Stevens-Johnson Syndrome. Ophthalmology 2016, 123(8):1653–1658.
11. Metcalfe D, Iqbal O, Chodosh J, Bouchard CS, Saeed HN: Acute and Chronic Management of Ocular Disease in Stevens Johnson Syndrome/Toxic Epidermal Necrolysis in the USA. Front Med (Lausanne) 2021, 8:662897.
12. Turkoglu E, Celik E, Alagoz G: A comparison of the efficacy of autologous serum eye drops with amniotic membrane transplantation in neurotrophic keratitis. Semin Ophthalmol 2014, 29(3):119–126.
13. Brott NR, Zeppieri M, Ronquillo Y: Schirmer Test. In: StatPearls. Treasure Island (FL); 2026.
14. Shah H, Parisi R, Mukherjee E, Phillips EJ, Dodiuk-Gad RP: Update on Stevens-Johnson Syndrome and Toxic Epidermal Necrolysis: Diagnosis and Management. Am J Clin Dermatol 2024, 25(6):891–908.
15. Gregory DG: The ophthalmologic management of acute Stevens-Johnson syndrome. Ocul Surf 2008, 6(2):87–95.
16. John T, Foulks GN, John ME, Cheng K, Hu D: Amniotic membrane in the surgical management of acute toxic epidermal necrolysis. Ophthalmology 2002, 109(2):351–360.
17. Shammas MC, Lai EC, Sarkar JS, Yang J, Starr CE, Sippel KC: Management of acute Stevens-Johnson syndrome and toxic epidermal necrolysis utilizing amniotic membrane and topical corticosteroids. Am J Ophthalmol 2010, 149(2):203–213.e202.
18. Sharma N, Thenarasun SA, Kaur M, Pushker N, Khanna N, Agarwal T, Vajpayee RB: Adjuvant Role of Amniotic Membrane Transplantation in Acute Ocular Stevens-Johnson Syndrome: A Randomized Control Trial. Ophthalmology 2016, 123(3):484–491.
19. Singh P, Palit A, Gupta A, Niyogi SG, Loganathan S, Chattopadhyay M, Meshram S, Verma A, Tripathy PK: Amniotic membrane grafting for acute ocular involvement in Stevens-Johnson syndrome: Review of perioperative considerations, surgical techniques, and outcomes. Indian J Ophthalmol 2025, 73(4):553–562.
20. Paris J, Macri C, Almater AI, Slattery J, Selva D: Amniotic membrane transplantation techniques in acute ocular Stevens-Johnson syndrome and toxic epidermal necrolysis: A systematic review. Ocul Surf 2025, 38:337–358.
21. Shay E, Kheirkhah A, Liang L, Sheha H, Gregory DG, Tseng SC: Amniotic membrane transplantation as a new therapy for the acute ocular manifestations of Stevens-Johnson syndrome and toxic epidermal necrolysis. Surv Ophthalmol 2009, 54(6):686–696.
22. Higuchi A: Autologous Serum and Serum Components. Invest Ophthalmol Vis Sci 2018, 59(14):DES121-DES129.

23. Shanbhag SS, Chodosh J, Saeed HN: Sutureless amniotic membrane transplantation with cyanoacrylate glue for acute Stevens-Johnson syndrome/toxic epidermal necrolysis. Ocul Surf 2019, 17(3):560–564.
24. Fu YK, Lin HY, Tsai TY, Quan WY, Liao YL, Tsai YJ, Ma DH: Outcome of sutureless amniotic membrane dressing ring for acute Stevens-Johnson syndrome with severe ocular involvement: A case report of 5 patients. Medicine (Baltimore) 2026, 105(2):e47003.
25. Yagi T, Sotozono C, Tanaka M, Fuwa M, Sekiyama E, Ueta M, Tashiro K, Kinoshita S: Cytokine storm arising on the ocular surface in a patient with Stevens-Johnson syndrome. Br J Ophthalmol 2011, 95(7):1030–1031.
26. Liu Y, Feng J, Ren Y, Shi W, Kang H, Peng Y, Tan Y, Wu R, Zhang G, He Y: Ocular surface involvement and histopathologic changes in the acute stage of Stevens-Johnson syndrome and toxic epidermal necrolysis: a cross-sectional study. BMC Ophthalmol 2023, 23(1):297.
27. Panpruk R, Puangsricharern V, Klaewsongkram J, Rerknimitr P, Kittipibul T, Chongpison Y, Buranapraditkun S: Clinical parameters and biological markers associated with acute severe ocular complications in Stevens-Johnson syndrome and toxic epidermal necrolysis. Sci Rep 2021, 11(1):20275.
28. Mizukawa Y, Shiohara T: Cytokine profile-guided management of Stevens-Johnson syndrome and toxic epidermal necrolysis (SJS/TEN): A management algorithm useful for guiding the selection of treatment options. Allergol Int 2026, 75(2):207–217.
29. Gipson IK: Distribution of mucins at the ocular surface. Exp Eye Res 2004, 78(3):379–388.

Figures

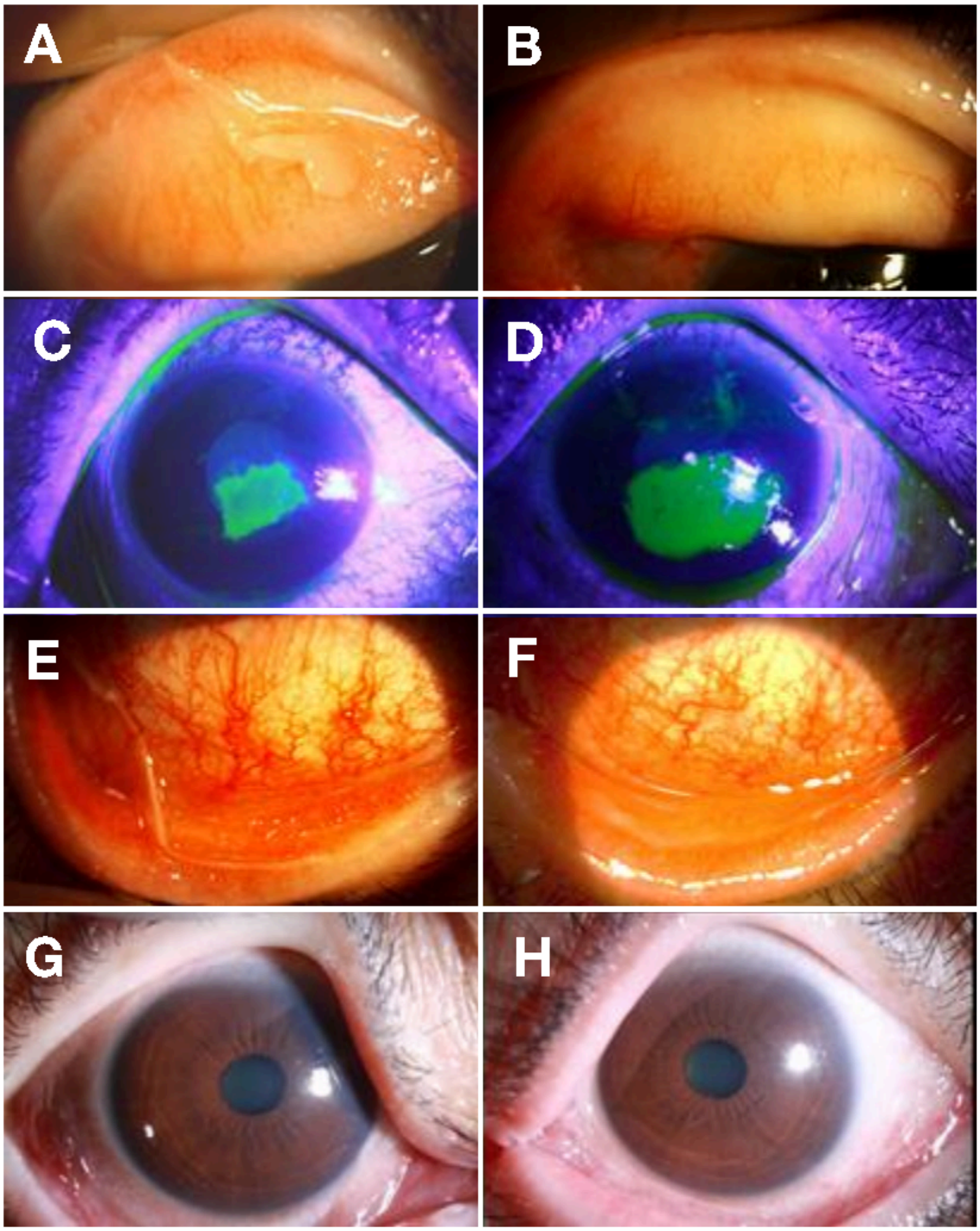

Figure 1

Slit-lamp photographs of a 44-year-old woman (Case 2 in Table 2) with bilateral, extremely severe acute ocular Stevens-Johnson syndrome before (A–F) and after (G, H) treatment. Baseline photos demonstrate extensive pseudomembranes in both the upper (A, B) and lower (E, F) palpebral conjunctiva, along with corneal epithelial erosions (C, D) highlighted by fluorescein staining. The patient was treated with intensive (every 2 hours) autologous serum eye drops for the first 2 weeks after symptom onset,

followed by maintenance therapy (4 times daily) for 1 month. At the 3-month follow-up (G, H), the ocular surface epithelia showed significant recovery with no signs of keratinization or scarring. (Left column: right eye; right column: left eye).

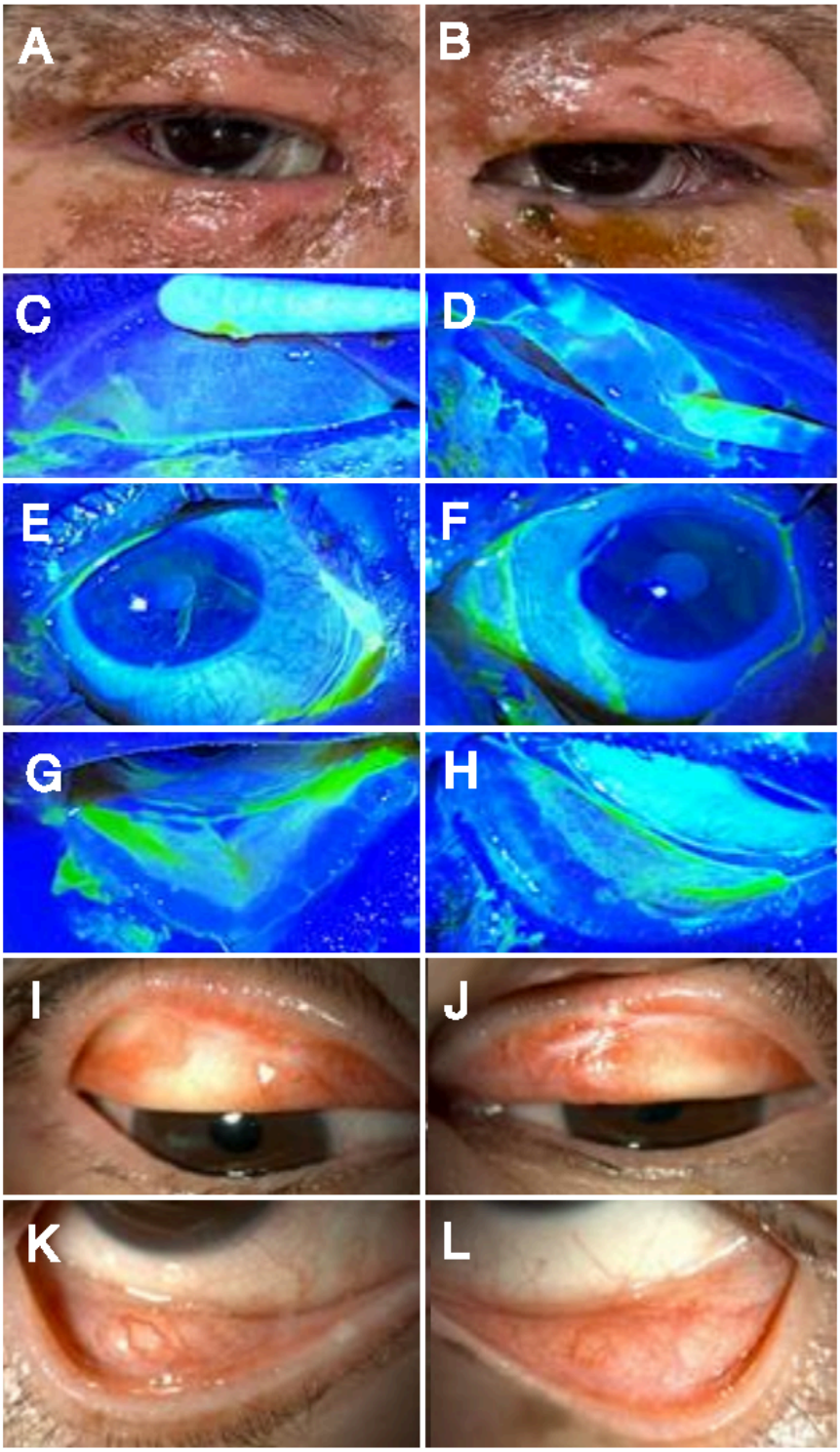

Figure 2

Bilateral, extremely severe acute ocular toxic epidermal necrolysis in a 60-year-old woman (Case 5 in Table 2) treated with autologous serum eye drops and symblepharon ring insertion within 7 days of symptom onset. Initial presentation (A–H): Slit-lamp examination demonstrates diffuse periocular skin ulceration (A, B), extensive epithelial defects in both the upper (C, D) and lower (G, H) palpebral conjunctiva, and diffuse punctate epitheliopathy (E, F), as highlighted by fluorescein staining. Six-month follow-up (I–L): Marked restoration of ocular surface smoothness is observed, with no evidence of keratinization or limbal stem cell deficiency. Mild cicatrization of the upper palpebral conjunctiva is present in both eyes (I, J), while the conjunctival fornices remain well-preserved without shortening (K, L). (Left column: right eye; right column: left eye).

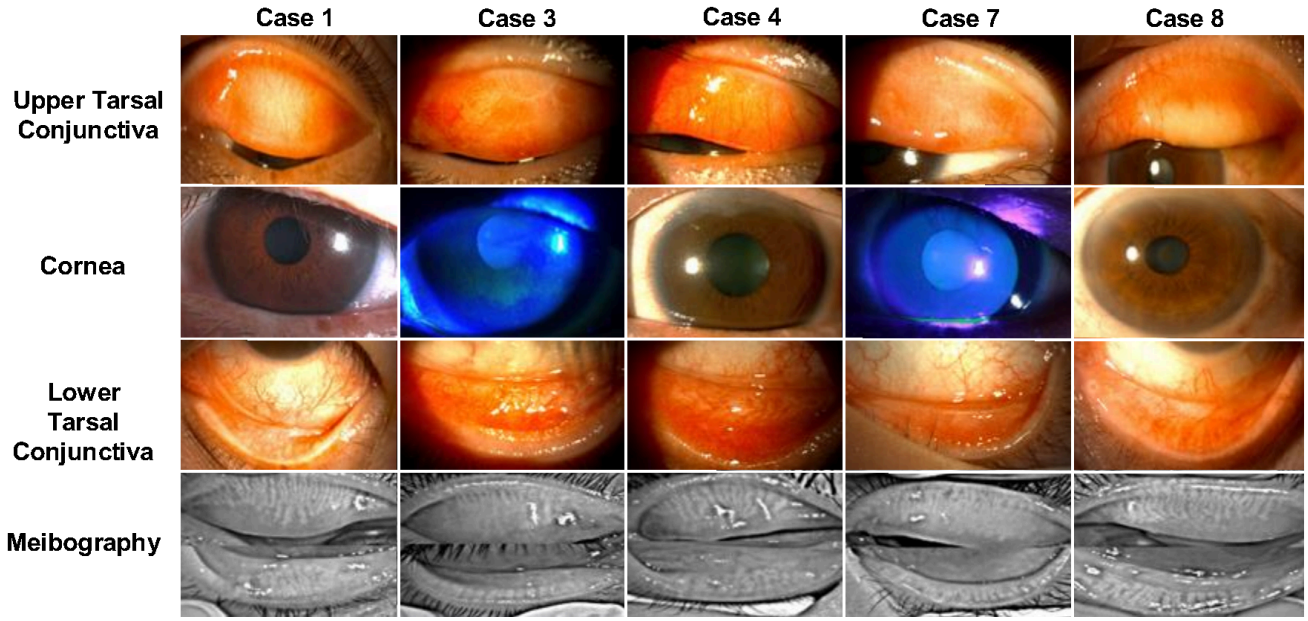

Figure 3

Representative white-light slit-lamp photographs of patients with acute ocular SJS/TEN treated with AS eye drops. Images demonstrate outcomes at 3 to 6 months post-treatment in moderate cases (Cases 3 and 8) and extremely severe cases (Cases 1, 4, and 7), where intensive AS therapy was initiated within 2 weeks of symptom onset. Significant restoration of ocular surface smoothness with minimal conjunctival scarring is observed (Cases 3 and 7), while superior corneal pannus is present in Case 4. Although all patients remained asymptomatic, most eyes exhibited features of dry eye disease, with meibography showing meibomian gland atrophy. Patients were gradually transitioned to preservative-free artificial tears while maintaining ocular surface integrity. (SJS = Stevens-Johnson syndrome; TEN = toxic epidermal necrolysis; AS = autologous serum).