Research Square

Preprints are preliminary reports that have not undergone peer review.
They should not be considered conclusive, used to inform clinical practice,
or referenced by the media as validated information.

Laparoscopic Versus Open Resection for Bismuth Type-III Hilar Cholangiocarcinoma: A Comparative Analysis of Perioperative Safety and Short-Term Clinical Outcomes

Shuo Qi
Hunan Provincial People's Hospital
Weinan Liu
Hunan Provincial People's Hospital
Chen Zou
Hunan Provincial People's Hospital
Weishun Huang
Hunan Provincial People's Hospital
Lian Shen
Hunan Provincial People's Hospital
Bingzhang Tian
Hunan Provincial People's Hospital
Kang Chen
Hunan Provincial People's Hospital
Changjun Liu
szhyxwkx@163.com

Hunan Provincial People's Hospital
Wei Cheng
Hunan Provincial People's Hospital
Guo Li
First People's Hospital of Xiangtan City

Research Article

Keywords: Hilar cholangiocarcinoma, Bismuth type-III, laparoscopic versus open, perioperative safety, comparative analysis

Posted Date: November 22nd, 2026

DOI: https://doi.org/10.21203/rs.3.rs-11552783/v1

License: This work is licensed under a Creative Commons Attribution 4.0 International License.
Read Full License

Additional Declarations: No competing interests reported.

Abstract

Purpose

This study aimed to evaluate whether laparoscopic radical resection achieves perioperative safety and short-term oncologic outcomes comparable to those of open surgery in patients with Bismuth type-III hilar cholangiocarcinoma (HCCA).

Methods

We retrospectively reviewed the medical records of 146 patients who underwent curative-intent resection for Bismuth type-III HCCA and stratified them according to surgical approach—laparoscopic versus open. Within each surgical group, patients were further categorized by anatomical subtype (IIIa or IIIb), yielding four distinct cohorts: MIS-IIIa, MIS-IIIb, OS-IIIa, and OS-IIIb. Perioperative safety parameters and short-term oncologic endpoints were compared both between surgical approaches and across anatomical subtypes within each approach.

Results

Compared with open surgery, the laparoscopic approach was associated with significantly lower estimated intraoperative blood loss and a shorter postoperative length of hospital stay (both $P < 0.05$). No statistically significant differences were observed between the two approaches regarding perioperative transfusion requirements, postoperative liver function indices, or overall complication rate ($P > 0.05$). Among laparoscopic cases, patients with Bismuth type-IIIb disease exhibited marginally higher postoperative serum ALB and Hb levels than those with type-IIIa disease ($P < 0.05$). However, across the entire cohort, no significant differences emerged between type-IIIa and type-IIIb disease in any perioperative metric—regardless of whether surgery was performed laparoscopically or openly ($P > 0.05$).

Conclusion

Laparoscopic radical resection is a safe and feasible alternative to open surgery for Bismuth type-III HCCA, offering accelerated recovery without compromising short-term oncologic outcomes. The technical advantages of laparoscopy—including enhanced visualization of deep anatomical structures and more precise dissection—are particularly pronounced in type-IIIb HCCA. With rigorous patient selection and an established minimally invasive surgical platform, this approach can be broadly implemented in clinical practice.

Introduction

Tumors originating from the mucosa of the left and right hepatic ducts—or from their confluence—are classified as hilar cholangiocarcinoma (HCCA)[1, 2]. The disease exhibits aggressive behavior: it preferentially spreads longitudinally along the bile duct wall, thereby reaching the portal vein and hepatic artery at an early stage—often before the onset of any clinical symptoms[3, 4]. Hilar cholangiocarcinoma is uncommon among gastrointestinal tumors, accounting for about 3% of them, yet it represents roughly one tenth of hepatobiliary malignancies and the majority (40%–60%) of all cholangiocarcinomas[5, 6]. Because the tumor is located at the hepatic hilum and lies in immediate proximity to major vascular structures, vascular involvement is frequently present at initial presentation. This anatomically challenging location—characterized by a confined surgical field densely populated with critical neurovascular and biliary structures—renders curative resection exceptionally difficult: achieving negative resection margins demands precise dissection under significant spatial constraints. For this reason, radical resection of HCCA has long been regarded as one of the most technically demanding procedures in hepatobiliary surgery.

Within the Bismuth–Corlette system, type-III disease sits at the more advanced end and is split according to which side is involved: in type-IIIa the tumor reaches the secondary right hepatic duct after involving the confluence, whereas in type-IIIb it extends into the secondary left hepatic duct[7]. Either way, the tumor has grown deeply into one side of the liver, so removing the bile duct alone will not clear it. The accepted operation is therefore an extended resection, combining hemihepatectomy on the diseased side with removal of the whole caudate lobe[8, 9]. To prepare the liver for such a large resection, selective biliary drainage is usually carried out beforehand so that functional reserve is preserved and the chance of post-hepatectomy liver failure is lowered[10, 11]. Type-III patients face a harder operation and more postoperative complications than those with type-I or type-II disease[12, 13].

The open approach has long served as the standard surgical strategy for type-III HCCA. Achieving favorable outcomes hinges upon meticulous preoperative planning, strict adherence to a standardized operative technique, and diligent postoperative management[14]. What the open approach offers is a clear, wide operative field and direct tactile assessment of tissues. Its drawbacks are equally well recognized: greater surgical trauma, increased postoperative pain, higher incidence of wound-related complications, and prolonged hospitalization. Over the past decade, advances in minimally invasive techniques and instrumentation have rendered laparoscopy increasingly feasible for the management of type-III HCCA[15, 16]. Even so, laparoscopy in this context requires careful patient selection rather than indiscriminate application, and its long-term safety and clinical benefits remain to be confirmed by larger, rigorously conducted studies.

Several high-volume centers have already taken up laparoscopy for type-III HCCA, yet the evidence base is still thin: randomized trials are absent, and large comparative series are few. It therefore remains unclear whether laparoscopy can equal, let alone outperform, open surgery in controlling blood loss and limiting perioperative complications. We addressed this question by reviewing consecutive type-IIIa and type-IIIb cases treated by either route in our own hepatobiliary unit over the same period. Operative time,

estimated blood loss, transfusion use, hospital stay, and major complications were compared between the two routes, together with short-term oncologic measures including R0 rate, lymph node yield, and 30- and 90-day mortality. The aim was to gauge, on real-world data, how far laparoscopy can be applied in this difficult setting and to provide a preliminary basis for clinical decisions.

Patients and Methods

Participant Enrollment

We reviewed, in a retrospective manner, the records of 146 individuals diagnosed with type-III HCCA. The diagnosis combined histological confirmation with preoperative radiological assessment, and every patient had undergone curative-intent resection in our hospital (Hunan Provincial People's Hospital, the First Affiliated Hospital of Hunan Normal University) between January 2020 and January 2025. No patient had missing clinical data. The investigation complied with the ethical standards of the Declaration of Helsinki, and the institutional Ethics Committee of Hunan Provincial People's Hospital granted approval before data collection began.

Every operation was carried out by departmental hepatobiliary surgeons already experienced in this field; each of them had independently completed more than 100 radical resections for hilar cholangiocarcinoma, whether performed laparoscopically or via the open route. The inclusion and exclusion criteria listed below were met by all enrolled patients. Patients were eligible if they: (1) had type-III HCCA confirmed both histopathologically and radiologically and had received R0 resection, with complete clinical records and ductal margins free of tumor; (2) had not received any tumor-directed treatment such as chemotherapy, radiotherapy, targeted agents, or immunotherapy before surgery; (3) had liver function of Child–Pugh class A or B; (4) had no history of, or concurrent, other malignancy; and (5) were free of severe cardiac, pulmonary, cerebral, or renal comorbidities. Patients were excluded if they: (1) underwent non-curative resection (R1 or R2) or had distant metastasis (M1); (2) had secondary rather than primary HCCA; or (3) had incomplete clinical data, in particular missing serum laboratory reports or inadequate diagnostic imaging. Because the prognostic significance of R1/R2 resection is still debated in oncological research, such cases were deliberately excluded from our analysis.

Preoperative management

Before surgery, each patient went through a full evaluation, covering routine blood tests, biochemical measurements, and screening before transfusion. To establish the Bismuth–Corlette type of the tumor, its exact anatomical position, and whether distant metastases were present, we obtained contrast-enhanced abdominal CT together with upper-abdominal MRI performed both without and with contrast, the latter including MRCP. When clinically justified, PET-CT was added on a case-by-case basis. The same work-up also addressed nutritional state, hepatic reserve as reflected by the Child–Pugh class, the estimated volume of the future liver remnant, and the function of vital organs; taken together, these

findings guided the assessment of surgical risk and of how well each patient could tolerate the operation. For those with hypertension, diabetes mellitus, or coronary artery disease, medical therapy was optimized so that blood pressure and glucose were tightly controlled, and specialists were brought in as needed. Routine preparation consisted of inserting nasogastric tubes and urinary catheters, securing the availability of blood products, and giving prophylactic intravenous antibiotics. Whenever a patient presented with poor nutrition, a serum bilirubin above 200 μmol/L, coagulopathy, or acute cholangitis, PTCD was performed before surgery to relieve biliary obstruction and bring the jaundice down.

Intraoperative Management

Whether the operation was laparoscopic or open, the same stepwise protocol was followed. We began with a thorough exploration of the abdominal cavity in order to rule out disseminated disease. The hepatic hilum and the extrahepatic biliary tree were then displayed, after which we judged resectability by examining how far the tumor had invaded, how extensively it involved surrounding structures, and how it lay in relation to nearby vessels. We cleared the lymphovascular and connective tissue located around the common hepatic artery (station 8), within the hepatoduodenal ligament (station 12), and behind the pancreas (station 13), and then skeletonized the common and proper hepatic arteries, the main portal vein, and the bile duct. The common bile duct was divided above the upper border of the pancreatic head, and the distal cut end was sent for frozen-section examination; the margin proved negative. Once the liver had been fully mobilized, a left or right hemihepatectomy together with total caudate lobectomy was carried out with the Pringle maneuver applied intermittently (15 minutes of inflow occlusion alternating with 5 minutes of reperfusion). If vascular invasion was encountered, the involved vessels were resected and reconstructed. The proximal bile duct was then divided, and its cut margin was likewise examined by frozen section, again with a negative result; the specimen was removed at this point. After the hilar duct orifices had been reconstructed and the biliary confluence reshaped—the distal duct being refashioned, as far as possible, into one or two left hepatic ducts or into the right anterior and posterior ducts for bilioenteric anastomosis—a Roux-en-Y hepaticojejunostomy was completed. Finally, a trough-shaped drain was positioned next to the liver transection surface and behind the bilioenteric anastomosis.

Indicator Analysis

Age, sex, and BMI were recorded for every patient, as were serum levels of CEA and of the carbohydrate antigens CA19-9 and CA125. We also documented comorbidities, among them hypertension, diabetes mellitus, and coronary artery disease. Laboratory values obtained around the time of surgery included Hb and PLT counts and four indices of hepatic function—TBIL, ALB, ALT, and AST. MTD was measured before surgery on contrast-enhanced CT or MRI. For the intraoperative period, we recorded how long the operation lasted, the estimated blood loss, and the amount and type of any blood transfused. Postoperative endpoints comprised the length of hospital stay, whether reoperation was required, and

all-cause mortality within 90 days. Complications arising after surgery were graded using the Clavien–Dindo system[17, 18]. Overall survival and recurrence were both timed from the date of surgery to the date of death or recurrence, or to the last follow-up visit; patients still alive when last seen were treated as censored observations.

Statistical Analysis

Each continuous variable was first checked for the shape of its distribution. Variables that were approximately normally distributed were compared with the independent-samples *t*-test and summarized as mean ± SD, whereas those showing a skewed distribution were analyzed with the Mann–Whitney *U* test and expressed as median with IQR. Categorical data were summarized as counts and percentages, and comparisons relied on the chi-square test or, when expected cell counts were small, Fisher's exact test. Survival and recurrence over time were visualized with Kaplan-Meier curves. SPSS version 25.0 (IBM Corp., Armonk, NY, USA) served as the analytic platform for every computation. Results were judged statistically significant when the two-sided *P* value was below 0.05.

Results

Study Design

Figure 1 shows how the study was organized. Screening left 113 patients who completed curative resection for HCCA, 53 by laparoscopy and 60 by laparotomy. The first division was by operative route, giving a laparoscopy group and a laparotomy group. Each was then split again according to the preoperative Bismuth–Corlette subtype, so that the laparoscopic side contained an MIS-IIIa and an MIS-IIIb subgroup, and the open side an OS-IIIa and an OS-IIIb subgroup. This two-level grouping mirrors the fact that the two anatomical variants call for different operative strategies.

Patient Characteristics

Baseline characteristics of the laparoscopy and laparotomy groups are presented in **Table 1**. No statistically significant differences were observed between the two groups with respect to age, sex, BMI, tumor markers (CEA, CA19-9, and CA125), MTD, preoperative comorbidities (hypertension, diabetes mellitus, and coronary heart disease), preoperative biliary drainage, or Bismuth–Corlette classification (subtypes IIIa and IIIb) (all $P > 0.05$).

Comparative analysis of perioperative outcomes between the laparoscopy and laparotomy groups

Perioperative results for the two operative routes appear in **Figure 2 and Table 2**. Serum ALB on postoperative days 1, 3, and 5, Hb on days 3 and 5, and PLT on day 3 were higher in the laparoscopy group (all $P < 0.05$). Blood loss was also lower with laparoscopy ($P = 0.018$) and the postoperative stay shorter ($P = 0.044$), although the operation itself took slightly longer ($P = 0.024$). The routes were comparable in transfusion requirement, the number of portal vein reconstructions, the number of lymph

nodes retrieved, reoperation, 90-day mortality, and postoperative ALT, AST, and TBIL (all $P > 0.05$). Clavien–Dindo grade I–II and grade III–IV complication rates were likewise similar ($P > 0.05$). As **Figure 3** shows, survival and recurrence at 36 months did not differ between the groups (all $P > 0.05$).

Comparison and analysis of perioperative outcomes between the IIIa-HCCA and IIIb-HCCA groups

Whether the two anatomical variants behave differently after curative resection was examined in **Figure 4 and Table 3**. Only one laboratory difference emerged: ALB on postoperative day 5 was higher in the IIIb-HCCA group than in the IIIa-HCCA group ($P < 0.05$). The remaining postoperative indices—ALT, AST, TBIL, Hb, and PLT measured on days 1, 3, and 5—were similar between the groups ($P > 0.05$). Operative duration, blood loss, transfusion, portal vein reconstruction, lymph node yield, hospital stay, reoperation, and 90-day mortality showed no differences either, and the same held for Clavien–Dindo grade I–II and III–IV complications ($P > 0.05$).

Comparison and analysis of perioperative outcomes between the MIS-IIIa and MIS-IIIb subgroups

We next looked within the laparoscopic route alone (**Figure 5 and Table 4**), where the MIS-IIIb subgroup showed a more favorable laboratory profile than MIS-IIIa: higher ALB on postoperative days 3 and 5, higher Hb on days 1 and 3, and slightly lower PLT on day 1 (all $P < 0.05$). ALT, AST, and TBIL did not separate the two subgroups ($P > 0.05$). Nor did operative duration, blood loss, transfusion, portal vein reconstruction, lymph node yield, hospital stay, reoperation, or 90-day mortality, and complication rates of Clavien–Dindo grade I–II and III–IV were alike in the two subgroups (all $P > 0.05$).

Comparison and analysis of perioperative outcomes between the OS-IIIa and OS-IIIb subgroups

The corresponding comparison within the open route is shown in **Figure 6 and Table 5**, and here no differences of any kind were detected: postoperative ALT, AST, TBIL, Hb, ALB, and PLT on days 1, 3, and 5 were all comparable ($P > 0.05$). The same was true of operative duration, blood loss, transfusion, portal vein reconstruction, lymph node yield, hospital stay, reoperation, 90-day mortality, and Clavien–Dindo grade I–II and III–IV complications (all $P > 0.05$).

Discussion

Among hepatobiliary operations, laparoscopic radical resection for type-III HCCA is one of the hardest to perform. Given its hallmark feature—tumor involvement of a single hepatic duct—the primary surgical objective in the laparoscopic setting is to achieve oncologically curative resection under minimally invasive visualization. This begins with thorough exposure and clearance of the hepatoduodenal ligament, including dissection of stations 8, 12, and 13[19]. Subsequently, based on the IIIa or IIIb subclassification, an anatomically appropriate hemihepatectomy—tailored to the side of biliary involvement—is performed in conjunction with total caudate lobectomy, ensuring negative intraoperative frozen-section margins at all bile duct resection sites. The procedure concludes with biliary reconstruction via Roux-en-Y hepaticojejunostomy[20, 21]. Several factors make this reconstruction

awkward under laparoscopy—tumor-related fibrosis, dense adhesions, and variant hilar vessels that are displaced from their usual position all narrow the working space when several duct orifices must be joined. Anastomoses made under such constraint are prone to tension and to poor perianastomotic perfusion, so bile leakage and hepatic dysfunction are harder to prevent than in open surgery[22, 23]. Acquiring the skill takes considerable experience in both advanced laparoscopic hepatobiliary surgery and open HCCA resection[24].

Several operative outcomes favored laparoscopy in our cohort. Since cases involving conversion from laparoscopic to open surgery may introduce methodological ambiguity, they were excluded from the analysis. Although operative time was marginally longer in the laparoscopy group (572.0 ± 146.4 min versus 509.8 ± 141.9 min in the open group), it demonstrated significantly reduced intraoperative blood loss (245.3 ± 133.4 mL versus 345.3 ± 288.5 mL). Consistent with this finding, the requirement for perioperative blood transfusion was markedly lower in the laparoscopy group—only 4 patients required transfusion, compared with 13 in the laparotomy group. No statistically significant differences were observed between the two groups regarding the quality of portal vein reconstruction, the extent of lymph node dissection or the overall survival and recurrence at 36 months after surgery, underscoring that laparoscopic surgery can achieve anatomically radical resection equivalent to that of open surgery. Better visualization, combined with refinements in technique, likely explains the smaller blood loss and hence the reduced transfusion need. This matters because transfusion—especially of whole blood or fresh frozen plasma—has repeatedly been linked to poorer survival in cholangiocarcinoma, including shorter overall and disease-free survival[25, 26].

In this study, the laparoscopy group exhibited significant advantages over the laparotomy group with respect to perioperative recovery. Specifically, patients undergoing laparoscopic surgery demonstrated significantly higher Hb and ALB levels on postoperative days 1, 3, and 5 compared with those in the laparotomy group; moreover, their median hospital stay was markedly shorter (14.4 ± 6.4 days versus 17.3 ± 8.6 days). However, no statistically significant differences were observed between the two groups in terms of postoperative complication rates, reoperation rates, or 90-day mortality. The most plausible explanation lies in the differing extent of surgical trauma: laparoscopy causes less tissue injury and a milder systemic inflammatory response, which preserves nutritional status, supports protein synthesis, and allows early postoperative nutritional indices to return toward baseline sooner[27, 28]. Taken together, these data indicate that laparoscopy speeds recovery after HCCA resection without adding risk, chiefly by reducing operative trauma and blood loss.

There exist fundamental differences in the characteristics of surgical trauma between type-IIIa and type-IIIb HCCA: patients with type-IIIa exhibit a smaller residual liver volume postoperatively and require a longer period for hepatic functional recovery. In contrast, although type-IIIb tumors necessitate less hepatic parenchymal resection, the local inflammatory stress is not attenuated relative to type-IIIa—largely attributable to the frequent requirement for concomitant vascular reconstruction[29, 30]. Initial analysis of this study revealed no statistically significant intergroup differences in perioperative

outcomes—including operative duration, intraoperative blood loss, postoperative length of hospital stay, and overall complication rates—between patients with type-IIIa and type-IIIb HCCA, irrespective of whether laparoscopic or open surgical approach was employed.

To probe whether the subtype effect depends on the operative route, we turned to a subgroup analysis. The results demonstrated that, within the laparoscopic cohort, patients with type-IIIb HCCA exhibited significantly higher serum ALB and Hb levels on postoperative days 1, 3, and 5 compared with those with type-IIIa. However, no statistically significant differences were observed between the two subgroups in core surgical metrics—including operative time, intraoperative blood loss, and rate of conversion to open surgery—or in other perioperative recovery parameters. In contrast, among patients undergoing open surgery, no significant differences emerged between the type-IIIb and type-IIIa subgroups across any assessed perioperative indicators. Collectively, these findings suggest that laparoscopic surgery confers distinct clinical advantages specifically in the management of type-IIIb HCCA. Mechanistically, the high-magnification visual field afforded by laparoscopy enables precise delineation of narrow anatomical spaces deep within the porta hepatis and surrounding the caudate lobe—thereby substantially reducing intraoperative blind spots during caudate lobe resection[31, 32]. Magnification also improves alignment during vascular reconstruction and biliary-enteric anastomosis, which may explain the earlier recovery of nutritional status and general condition[33, 34].

Our findings offer preliminary support for laparoscopy as a safe and standardized route to curative resection of type-III HCCA, with faster postoperative recovery than open surgery. Building upon these findings, we conducted prespecified subgroup analyses stratified by surgical approach—specifically for type-IIIa and type-IIIb HCCA. The results indicate that laparoscopic surgery may confer distinct clinical advantages in the management of type-IIIb HCCA. The study nonetheless has clear limitations. It is retrospective and confined to one center, with no external multicenter validation and no large representative cohort; in particular, the laparoscopic type-IIIa subgroup contained only 18 patients, so conclusions about that subgroup are statistically fragile. The subgroup comparisons were exploratory and were not corrected for multiple testing, and should therefore be read as hypothesis-generating rather than definitive. To strengthen the evidence, we intend to conduct a multicenter, prospective randomized controlled trial (RCT) that enrolls patients across a range of regions and hospital settings, including centers with differing surgical expertise and resources, in order to compare laparoscopic and open curative resection for type-III HCCA more definitively. This trial will systematically enroll patients across diverse geographic regions and healthcare settings—including institutions with varying levels of surgical expertise and infrastructure—to comprehensively compare the safety and efficacy of laparoscopic versus open curative resection for type-III HCCA. The primary objective is to generate high-quality evidence to inform standardized, evidence-based clinical implementation of laparoscopic techniques in the surgical management of HCCA.

Conclusion

In this cohort, laparoscopy achieved curative resection for type-III HCCA with a safety profile and oncologic outcomes comparable to open surgery, while shortening postoperative recovery. Subgroup analysis suggests the advantage is most pronounced in type-IIIb disease, where the magnified view aids dissection of deep structures. Laparoscopy thus appears to be a safe and effective minimally invasive option for HCCA resection, with reasonable potential for wider use—provided that candidates are selected carefully and the center has a mature minimally invasive platform.

Abbreviations

HCCA, hilar cholangiocarcinoma; BMI, body mass index; MTD, maximum tumor diameter; CEA, Carcinoembryonic Antigen; CA19-9, Carbohydrate Antigen 19-9; CA125, Carbohydrate Antigen 125; MIS, minimal invasive surgery; OS, open surgery; POD, postoperative day.

Declarations

Data Availability Statement

All data supporting the findings are presented within the article. Requests for further details should be directed to the corresponding authors.

Ethics Statement

The Ethics Committee of Hunan Provincial People's Hospital reviewed and approved this study involving human participants. Written informed consent was obtained from every patient before enrollment.

Author Contributions

Shuo Qi, Guo Li, Wei Cheng, and Changjun Liu played pivotal roles in conceptualizing the study. Weinan Liu, Chen Zou, Weishun Huang, and Lian Shen made substantial contributions to data collection and audit procedures. Shuo Qi, Guo Li and Weinan Liu conducted the data analyses and drafted the manuscript. Bingzhang Tian, Kang Chen, Changjun Liu, Wei Cheng, and Guo Li provided critical feedback and substantive revisions to the manuscript. All authors were actively involved in the development of this article and have approved the final submitted version.

Funding

This research was supported by the National Natural Science Foundation of China (No.82404102), the Natural Science Foundation of Hunan Province (Nos. 2025JJ50495, 2025JJ50653, 2026JJ81729, 2024JJ9479), 2026 Furong Plan Young Talent Program (Health and Wellness Category), the Hunan Provincial Health High-Level Talent Scientific Research Project (No.R2023096), the Hunan Provincial Class B Medical Discipline Construction Project (20260106-1004), the National Clinical Key

Specialty Construction Project (20191127-1001),Hunan Provincial Health Commission's Major Scientific Research Project for High-Level Talent in Healthcare (20240913-1016), the Health Research Project of the Hunan Provincial Health Commission (W20242019).

Conflict of Interest

The authors declare that they have no competing interests to disclose.

References

1. Halder R, Amaraneni A, Shroff RT. Cholangiocarcinoma: a review of the literature and future directions in therapy[J]. Hepatobiliary Surg Nutr. 2022;11(4):555–66.
2. Dar FS, Abbas Z, Ahmed I, et al. National guidelines for the diagnosis and treatment of hilar cholangiocarcinoma[J]. World J Gastroenterol. 2024;30(9):1018–42.
3. Mizuno T, Ebata T, Yokoyama Y, et al. Combined Vascular Resection for Locally Advanced Perihilar Cholangiocarcinoma[J]. Ann Surg. 2022;275(2):382–90.
4. De Bellis M, Contro A, Bianco A, et al. Portal vein stenting in recurrent or locally advanced peri-hilar cholangiocarcinoma[J]. Eur J Surg oncology: J Eur Soc Surg Oncol Br Association Surg Oncol. 2024;50(3):107984.
5. Inchingolo R, Acquafredda F, Ferraro V, et al. Non-surgical treatment of hilar cholangiocarcinoma[J]. World J Gastrointest Oncol. 2021;13(11):1696–708.
6. Forsmark CE, Diniz AL, Zhu AX. Consensus conference on hilar cholangiocarcinoma[J]. HPB: the official journal of the International Hepato Pancreato Biliary Association. 2015, 17(8): 666–668.
7. Quan X, Huang X, Liu J, et al. Preoperative assessment of longitudinal extent in hilar cholangiocarcinoma using noninvasive enhanced MR radiomics: a multicenter study[J]. Front Oncol. 2025;15:1632630.
8. Zhang J, Xu B, Chen W, et al. Left Hepatectomy Combined with Right Hepatic Artery Resection and Reconstruction for Hilar Cholangiocarcinoma[J]. Ann Surg Oncol. 2024;31(5):3086.
9. Zhang C, Liu J, Hong D, et al. Pure laparoscopic radical resection for type IIIa hilar cholangiocarcinoma[J]. Surg Endosc. 2018;32(3):1581–2.
10. Kazumori H, Ohno Y, Kawashima K. Cholangioscopy-assisted partial stent-in-stent method useful for bilateral biliary drainage of hilar cholangiocarcinoma[J]. Endoscopy. 2023;55(S 01):E1264–5.
11. Ribero D, Zimmitti G, Aloia TA, et al. Preoperative Cholangitis and Future Liver Remnant Volume Determine the Risk of Liver Failure in Patients Undergoing Resection for Hilar Cholangiocarcinoma[J]. J Am Coll Surg. 2016;223(1):87–97.
12. Campisi A, Kawaguchi Y, Ito K, et al. Right hepatectomy compared with left hepatectomy for resectable Klatskin tumor: A systematic review across tumor types[J]. Surgery. 2024;176(4):1018–28.

13. Jingdong L, Yongfu X, Yang G, et al. Minimally invasive surgery for hilar cholangiocarcinoma: a multicenter retrospective analysis of 158 patients[J]. Surg Endosc. 2021;35(12):6612–22.
14. Yin Y, Tao J, Xian Y, et al. Survival analysis of laparoscopic surgery and open surgery for hilar cholangiocarcinoma: a retrospective cohort study[J]. World J Surg Oncol. 2024;22(1):58.
15. Ma D, Wang W, Wang J, et al. Laparoscopic versus open surgery for hilar cholangiocarcinoma: a retrospective cohort study on short-term and long-term outcomes[J]. Surg Endosc. 2022;36(6):3721–31.
16. Dorovinis P, Machairas N, Terra A, et al. Minimally Invasive Surgery for Perihilar Cholangiocarcinoma-A Review of the Current Literature[J]. J Clin Med. 2025;14(11):3748.
17. Noji T, Uemura S, Wiggers JK, et al. Validation study of postoperative liver failure and mortality risk scores after liver resection for perihilar cholangiocarcinoma[J]. Hepatobiliary Surg Nutr. 2022;11(3):375–85.
18. Rebelo A, Friedrichs J, Grilli M, et al. Systematic review and meta-analysis of surgery for hilar cholangiocarcinoma with arterial resection[J]. HPB: official J Int Hepato Pancreato Biliary Association. 2022;24(10):1600–14.
19. Ding G, Ma J, Yun J, et al. Distribution and density of tertiary lymphoid structures predict clinical outcome in intrahepatic cholangiocarcinoma[J]. J Hepatol. 2022;76(3):608–18.
20. Conci S, Calderone G, Ruzzenente AASO, Authors Reflections. Could Robotics, 3D Imaging, and Liver Venous Deprivation Potentially Redefine Surgical Standards for Perihilar Cholangiocarcinoma? [J]. Ann Surg Oncol. 2026;33(1):642–3.
21. Zhang X, Bagante F, Chen Q, et al. Perioperative and long-term outcome of intrahepatic cholangiocarcinoma involving the hepatic hilus after curative-intent resection: comparison with peripheral intrahepatic cholangiocarcinoma and hilar cholangiocarcinoma[J]. Surgery. 2018;163(5):1114–20.
22. Spetzler VN, Schepers M, Pinnschmidt HO, et al. The incidence and severity of post-hepatectomy bile leaks is affected by surgical indications, preoperative chemotherapy, and surgical procedures[J]. Hepatobiliary Surg Nutr. 2019;8(2):101–10.
23. Ellis RJ, Soares KC, Jarnagin WR. Preoperative Management of Perihilar Cholangiocarcinoma[J]. Cancers. 2022;14(9):2119.
24. Pfister M, Ratti F, Gores GJ et al. Recommendations on Perihilar Cholangiocarcinoma. The Milan Jury-Based Consensus[J]. Ann Surg. 2025: 10–1097.
25. Bednarsch J, Czigany Z, Heij LR, et al. The prognostic role of in-hospital transfusion of fresh frozen plasma in patients with cholangiocarcinoma undergoing curative-intent liver surgery[J]. Eur J Surg oncology: J Eur Soc Surg Oncol Br Association Surg Oncol. 2022;48(3):604–14.
26. Liu Z, Cheng Z, Dai H, et al. Impact of perioperative blood transfusion on long-term survival in patients with different stages of perihilar cholangiocarcinoma treated with curative resection: A multicentre propensity score matching study[J]. Front Oncol. 2022;12:1059581.

27. Manolis AA, Manolis TA, Melita H, et al. Low serum albumin: A neglected predictor in patients with cardiovascular disease[J]. Eur J Intern Med. 2022;102:24–39.
28. Waghray A, Sobotka A, Marrero CR, et al. Serum albumin predicts survival in patients with hilar cholangiocarcinoma[J]. Gastroenterol Rep. 2017;5(1):62–6.
29. Sugiura R, Kuwatani M, Kato S, et al. Risk factors for dysfunction of preoperative endoscopic biliary drainage for malignant hilar biliary obstruction[J]. J Hepato-Biliary-Pancreat Sci. 2020;27(11):851–9.
30. Lauterio A, De Carlis R, Centonze L, et al. Current Surgical Management of Peri-Hilar and Intra-Hepatic Cholangiocarcinoma[J]. Cancers. 2021;13(15):3657.
31. Sucher R, Scheuermann U, Seehofer D. Total Laparoscopic Resection of Hilar Cholangiocarcinoma Type 3b: Applying a Parachute Technique for Hepaticojejunostomy[J]. Ann Surg Oncol. 2021;28(4):2030–4.
32. Zhang Y, Dou C, Wu W, et al. Total laparoscopic versus open radical resection for hilar cholangiocarcinoma[J]. Surg Endosc. 2020;34(10):4382–7.
33. Liu W, Xiong F, Wu G, et al. Biliary-enteric reconstruction in laparoscopic radical resection of hilar cholangiocarcinoma: a single-center retrospective cohort study[J]. BMC Cancer. 2023;23(1):456.
34. Morimoto K, Matsumoto K, Obata T, et al. Optimal liver drainage rate for survival in patients with unresectable malignant hilar biliary obstruction using 3D-image volume analyzer[J]. Therapeutic Adv Gastroenterol. 2023;16:1108389956.

Tables

Tables 1 to 5 are available in the Supplementary Files section.

Figures

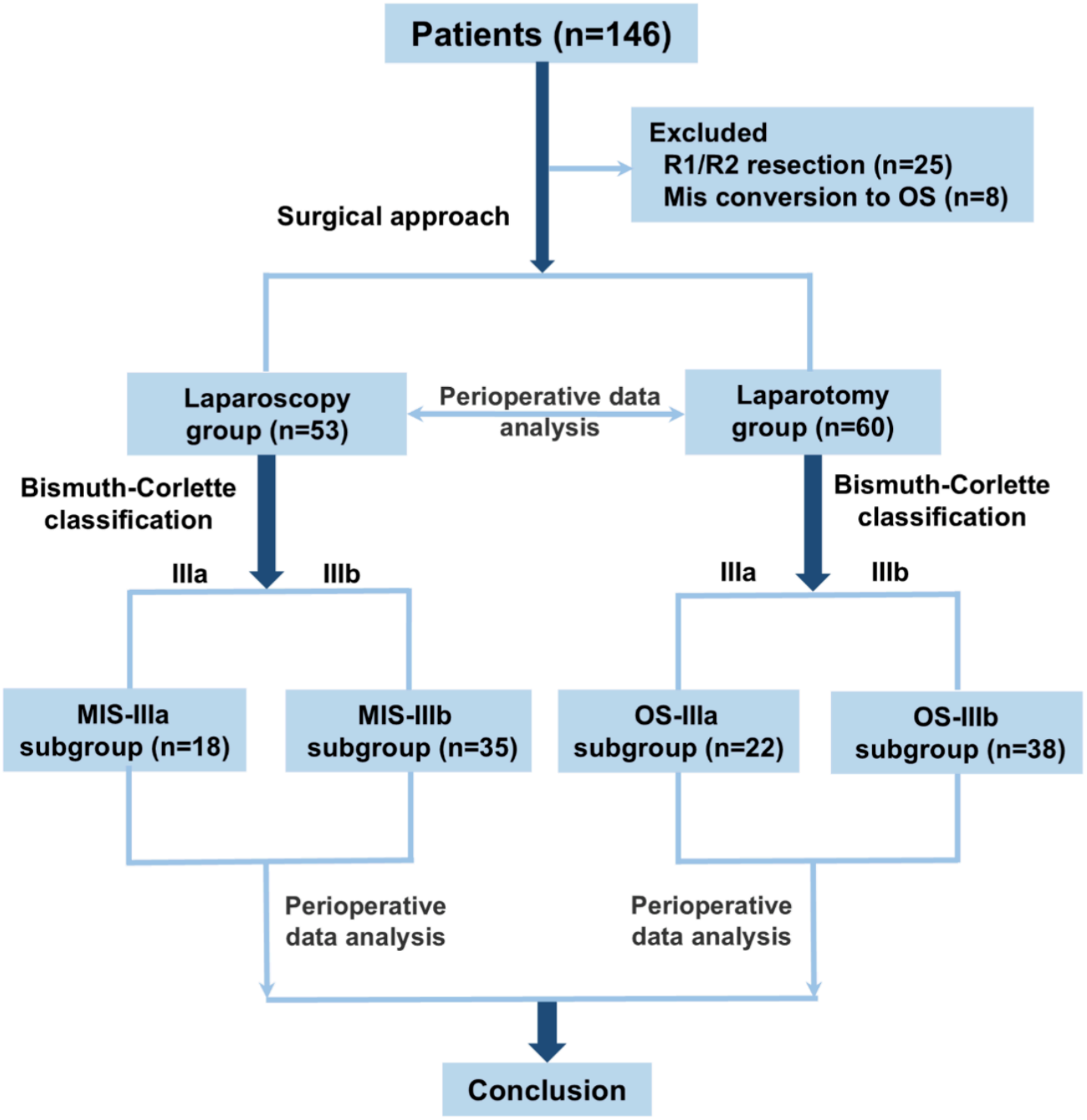

Figure 1

Schematic diagram of the study design.

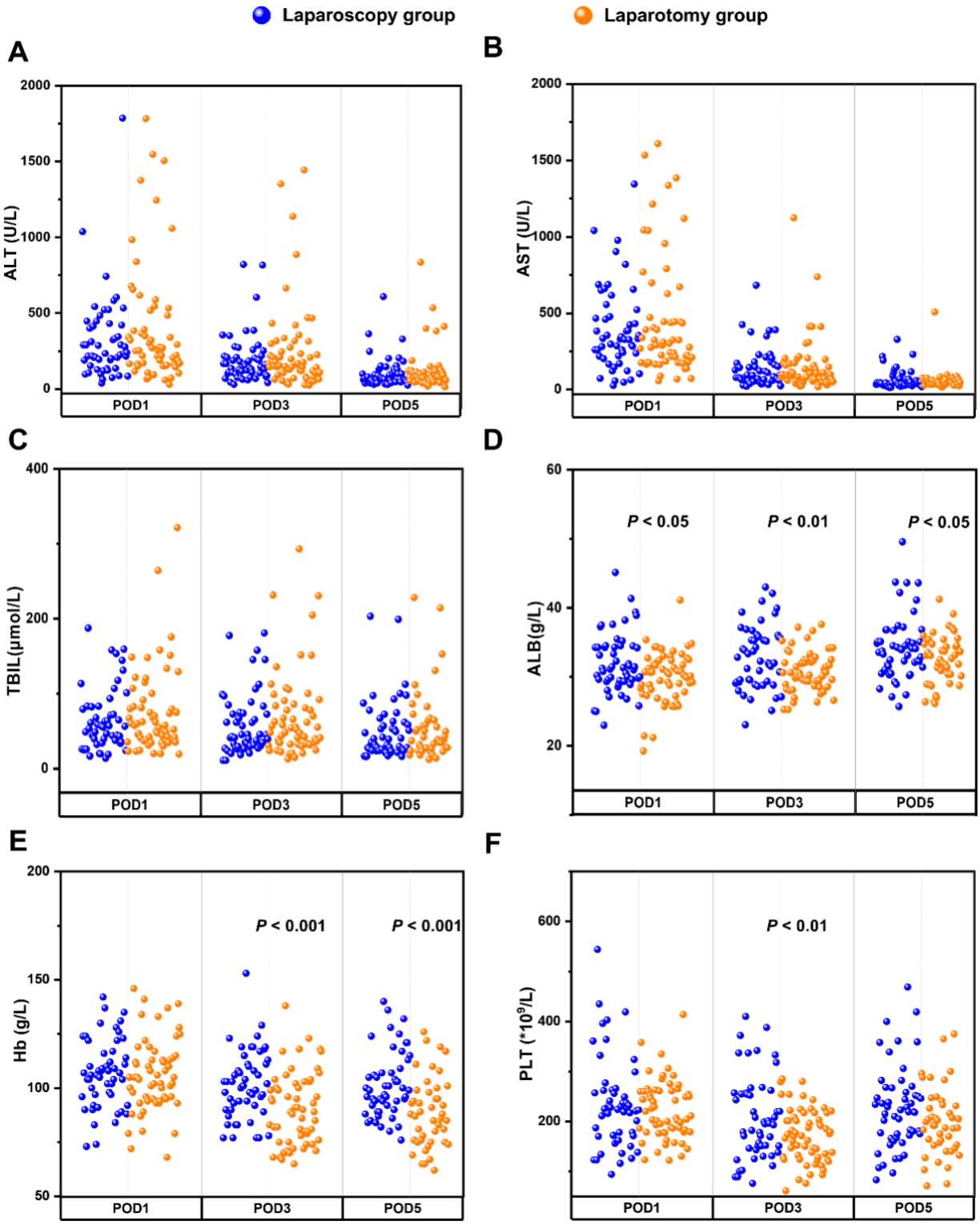

Figure 2

Postoperative ALT (A), AST (B), TBIL (C), ALB (D), Hb (E), and PLT (F) on POD1, POD3, and POD5 in the laparoscopy and laparotomy groups.

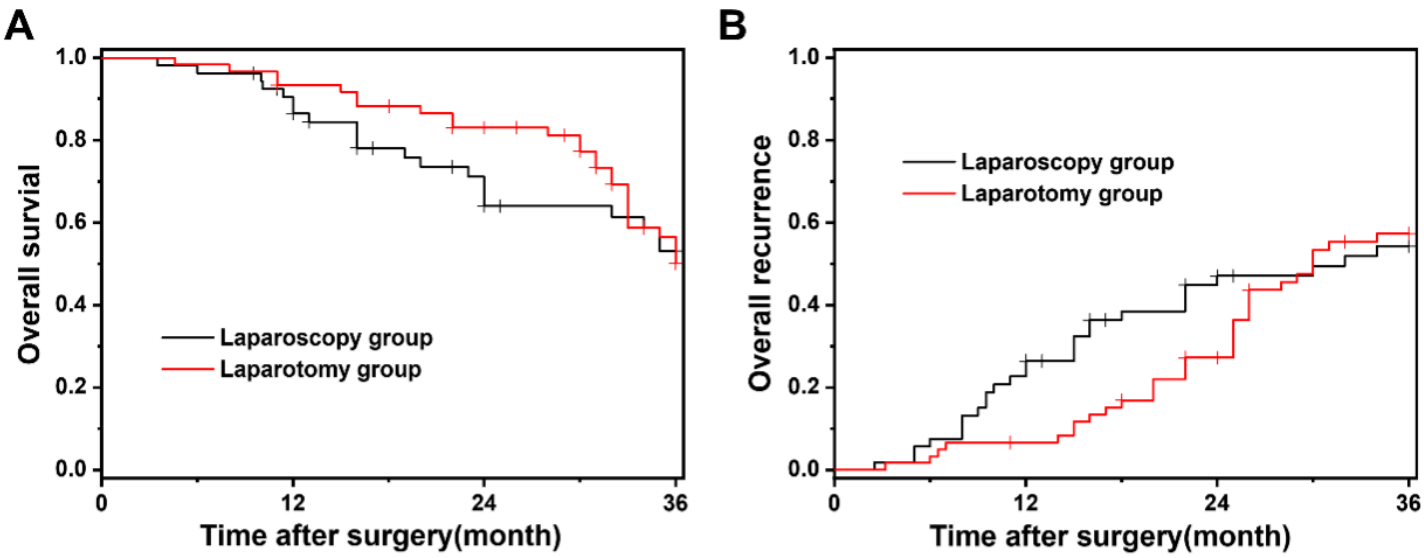

Figure 3

The overall survival (A) and recurrence (B) comparison between the Laparoscopy and Laparotomy groupsat 36 months after surgery.

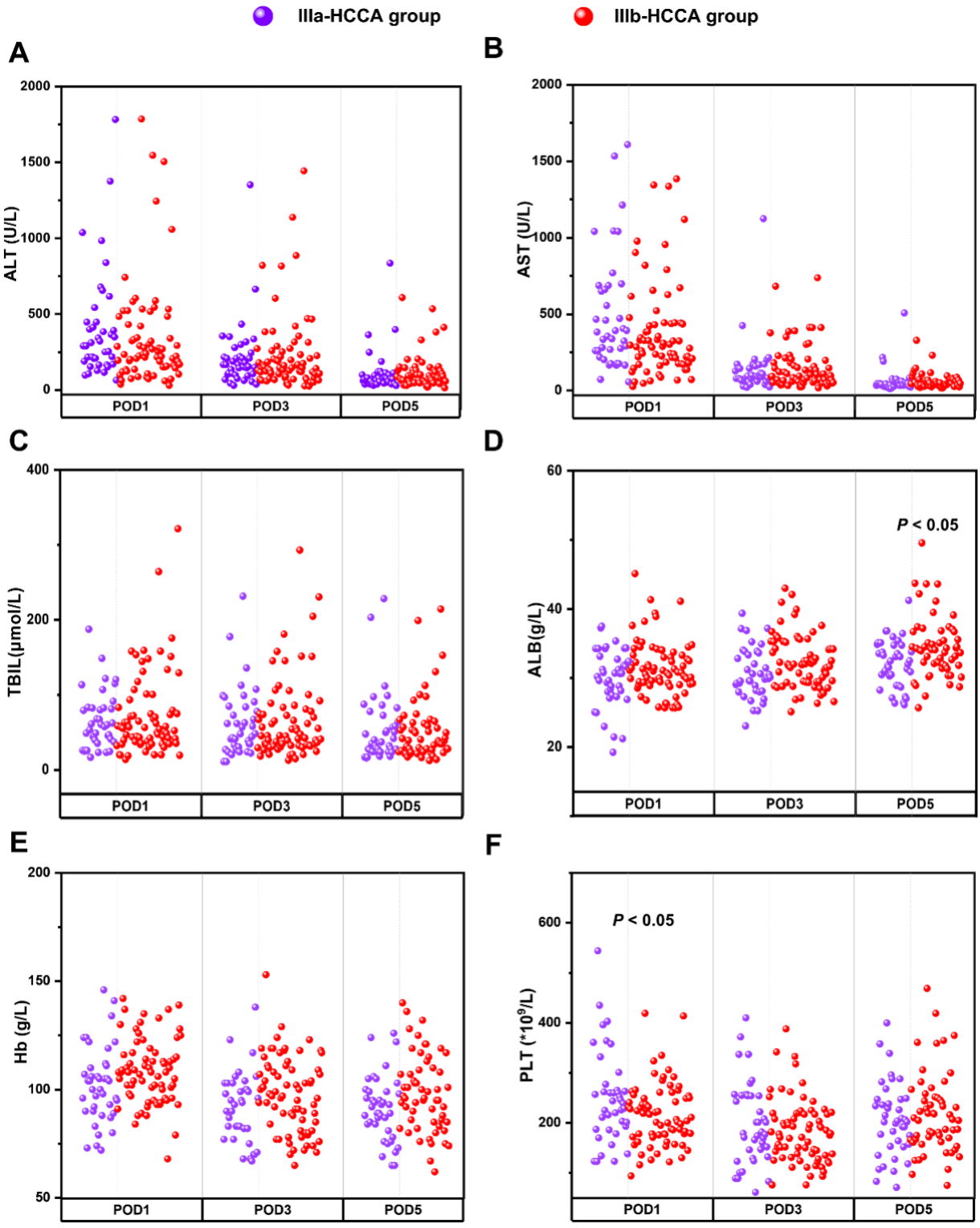

Figure 4

Postoperative ALT (A), AST (B), TBIL (C), ALB (D), Hb (E), and PLT (F) on POD1, POD3, and POD5 in the IIIa-HCCA and IIIb-HCCA groups.

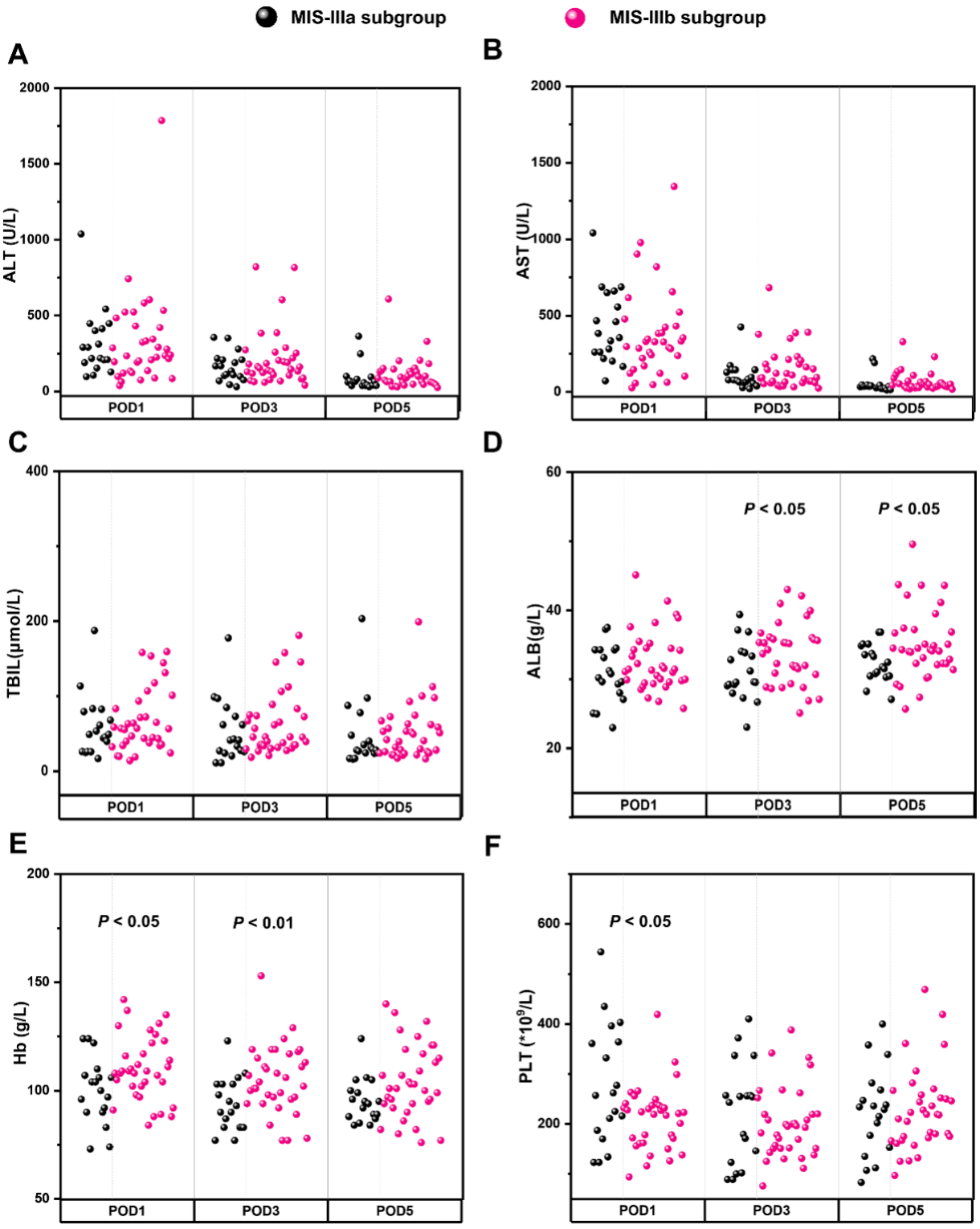

Figure 5

Postoperative ALT (A), AST (B), TBIL (C), ALB (D), Hb (E), and PLT (F) on POD1, POD3, and POD5 in the MIS-IIIa and MIS-IIIb subgroups.

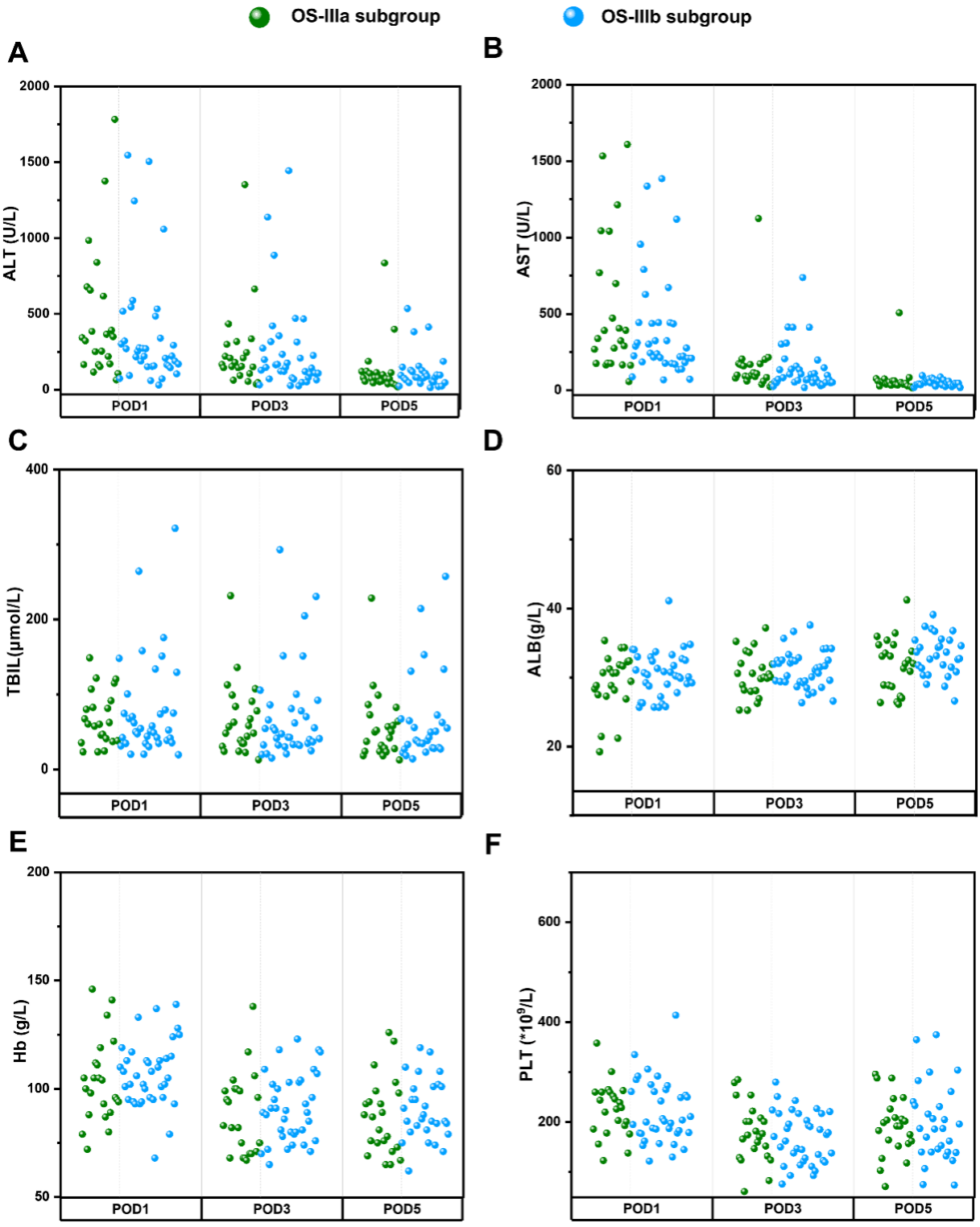

Figure 6

Postoperative ALT (A), AST (B), TBIL (C), ALB (D), Hb (E), and PLT (F) on POD1, POD3, and POD5 in the OS-IIIa and OS-IIIb subgroups.

Supplementary Files

This is a list of supplementary files associated with this preprint. Click to download.

- TablesV1.docx