Research Square

Preprints are preliminary reports that have not undergone peer review.
They should not be considered conclusive, used to inform clinical practice,
or referenced by the media as validated information.

Wandering Spleen with Extensive Infarction and Splenopancreatic Torsion in a 39-Year-Old Patient: A Case Report

Nebiat Embiale Mekonen
Bahir Dar University
Hailemariam Sema Woldie
Bahir Dar University
Tilahun Shebabw Eneyew
Bahir Dar University
Zelalem Tadele
Bahir Dar University
Yenebilew Abebe Tamir
Bahir Dar University
Oumer Ahmed Yessuf
Bahir Dar University
Samuel Debas Bayable
Samueldebas11@gmail.com
Bahir Dar University

Case Report

Keywords: Wandering spleen, splenic torsion, splenic infarction, pancreatic volvulus, splenectomy, case report

Posted Date: November 23rd, 2026

DOI: https://doi.org/10.21203/rs.3.rs-11552663/v1

License: This work is licensed under a Creative Commons Attribution 4.0 International License.
Read Full License

Additional Declarations: No competing interests reported.

Wandering Spleen with Extensive Infarction and Splenopancreatic Torsion in a 39-Year-Old Patient: A Case Report

Authors and affiliations

1. Dr. Nebiat Embiale Mekonen
Assistant Professor of Surgery; General and Hepatopancreatobiliary (HPB) Surgeon
Department of Surgery, College of Medicine and Health Sciences, Bahir Dar University, Bahir Dar, Ethiopia
Email: nebiatbdu@gmail.com

2. Mr. Hailemariam Sema Woldie
BSc; Graduate Assistant II in Anesthesia
Department of Anesthesia, College of Medicine and Health Sciences, Bahir Dar University, Bahir Dar, Ethiopia
Email: hailemariamsema22@gmail.com

3. Dr. Tilahun Shebabw Eneyew
BSc in Pharmacy, MD; General Surgery Resident (Year 4)/Lecturer
Department of Surgery, School of Medicine, Bahir Dar University, Bahir Dar, Ethiopia
Email: tilahun.shibabaw@gmail.com

4. Dr. Zelalem Tadele
MD; General Surgery Resident (Year 4)
Department of Surgery, School of Medicine, Bahir Dar University, Bahir Dar, Ethiopia
Email: ztadelet@gmail.com

5. Dr. Yenebilew Abebe Tamir
MD; General Surgery Resident (Year 4)
Department of Surgery, College of Medicine and Health Sciences, Bahir Dar University, Bahir Dar, Ethiopia
Email: yenebilewabebe@gmail.com

6. Dr. Oumer Ahmed Yessuf
MD; General Surgery Resident (Year 4)
Department of Surgery, College of Medicine and Health Sciences, Bahir Dar University, Bahir Dar, Ethiopia
Email: aniom1ahmed@gmail.com

7. Mr. Samuel Debas Bayable
BSc, MSc; Assistant Professor and Lecturer in Anesthesia
Department of Anesthesia, College of Medicine and Health Sciences, Bahir Dar University, Bahir Dar, Ethiopia
Email: Samueldebas11@gmail.com

Corresponding author

Samuel Debas Bayable*

Abstract

Background: Wandering spleen is a rare condition caused by abnormal mobility of the spleen due to deficient or lax suspensory ligaments. Torsion of spleen along its elongated vascular pedicle may cause venous congestion, ischemia and splenic infarction. Combined Pancreatic-tail involvement has also been described in individual case reports.

Case presentation: A 39-year-old woman presented to Tibebe Gihon Specialized Teaching Hospital, Bahir Dar, Ethiopia, with approximately six days of left-sided abdominal pain, distension and vomiting. Examination revealed tachycardia and a large, tender abdominal mass extending from the left lower quadrant to the umbilical level. Investigations demonstrated anemia, with a hemoglobin concentration of 8.3 g/dl, leukocytosis and thrombocytosis. CT was reported to demonstrate a wandering spleen with empty splenic fossa, and Splenopancreatic torsion along splenic vascular pedicle and splenic infarction.

Intervention and outcome: The patient underwent surgical exploration and splenectomy. The operative record described a 720-degree counterclockwise rotation and splenic infarction with viable but edematous pancreas. The spleen has no attachment with kidney, diaphragm and stomach and the splenic fossa was empty. One unit of whole blood was transfused intraoperatively. The patient remained stable during the procedure and was discharged fifth post-operative day.

Conclusion: Wandering spleen with torsion should be considered in patients presenting with acute abdominal pain and an abdominal mass. Although pancreatic involvement has been reported in the literature, pancreatic displacement, traction, injury and true combined torsion must be distinguished by careful radiological and operative assessment.

Keywords: Wandering spleen; splenic torsion; splenic infarction; pancreatic volvulus; splenectomy; case report.

Background: Wandering spleen is an uncommon anatomical abnormality in which the spleen occupies an ectopic position because of deficient, absent or lax suspensory ligaments. The gastrosplenic and splenorenal ligaments contribute to maintaining the spleen in its normal left upper-quadrant position. Abnormal ligamentous development or acquired laxity permits excessive splenic mobility and may result in an elongated vascular pedicle that predisposes the spleen to torsion [1, 2] .

Torsion of the splenic pedicle may obstruct venous drainage, leading to congestion and splenic enlargement, followed by arterial compromise, ischemia and infarction. Clinical presentation ranges from intermittent abdominal pain to an acute abdomen with a palpable mass. Because the symptoms are nonspecific, diagnosis may be delayed unless the possibility of splenic malposition is considered during imaging assessment[1].

The anatomical relationship between the splenic hilum and pancreatic tail raises the possibility of pancreatic displacement or traction when a wandering spleen undergoes torsion. Published case reports describe ectopic pancreatic anatomy and operative or radiological evidence of pancreatic-tail involvement [2-4]. However, displacement or traction does not necessarily establish true combined torsion of the spleen and pancreas.

This report describes a 39-year-old woman with a wandering spleen with empty splenic fossa, and Splenopancreatic torsion along splenic vascular pedicle and splenic infarction on CT and during surgery. The case highlights the importance of timely diagnosis, appropriate surgical management and cautious interpretation of the pancreatic findings.

Case presentation: A 39-year-old woman with a history of breast cancer who had undergone a modified radical mastectomy four years earlier presented to Tibebe Gihon Specialized Teaching Hospital, Bahir Dar, Ethiopia, with a six-day history of abdominal pain, predominantly localized to the left lower quadrant. Her symptoms were associated with abdominal distension, vomiting, fever, and loss of appetite.

Her medical history was significant for hepatitis C infection, with an unknown viral load, and right-sided breast cancer treated with modified radical mastectomy four years earlier. At the time

of presentation, there was no documented evidence of local recurrence or distant metastasis. She had no history of blood transfusion and reported no known allergies.

On examination, her blood pressure was 110/70 mmHg, pulse rate 108 beats/min, respiratory rate 20 breaths/min, temperature 37.3°C and peripheral oxygen saturation 96%. The recorded examination described pale conjunctiva, clear breath sounds and audible first and second heart sounds. Abdominal examination revealed bowel movement with respiration and a large, tender mass extending from the left lower quadrant to the level of the umbilicus. Digital rectal examination revealed stool on the examining finger without visible blood.



Figure 1. Preoperative Abdominal Examination Showing Abdominal Distension in a 39-Year-Old Patient With wandering spleen and Splenopancreatic torsion.

Laboratory investigations: The full blood count demonstrated a hemoglobin concentration of 8.3 g/dl, hematocrit of 22.4%, red blood cell count of (2.69 times 10^6/mu L), white blood cell count of (12.30 times 10^3/mu L) and platelet count of (596 times 10^3/mu L). These findings indicated anaemia, leukocytosis and thrombocytosis.

Serum amylase was 56.91 U/L and lipase was 59.19 U/L, both within the reference intervals supplied with the laboratory results. Prothrombin time was 12.3 seconds, activated partial thromboplastin time 27.5 seconds and INR 0.99.

The cause of the anemia and the clinical significance of the elevated platelet count remain undetermined.

Radiological findings: Contrast-enhanced CT demonstrated a markedly enlarged, ectopically positioned spleen in the left lower abdomen, with diffuse parenchymal non-enhancement consistent with extensive splenic infarction. Twisting of the splenic hilar vessels was evident, accompanied by torsion of the distal pancreatic body and tail along the splenic vascular pedicle, producing a characteristic whirl sign. No pancreatic ductal dilatation or ascites was identified. The liver, biliary system, kidneys, adrenal glands, bowel loops, and urinary bladder appeared unremarkable. No significant abnormality was detected in the visualized lung parenchyma. (Appendex1)

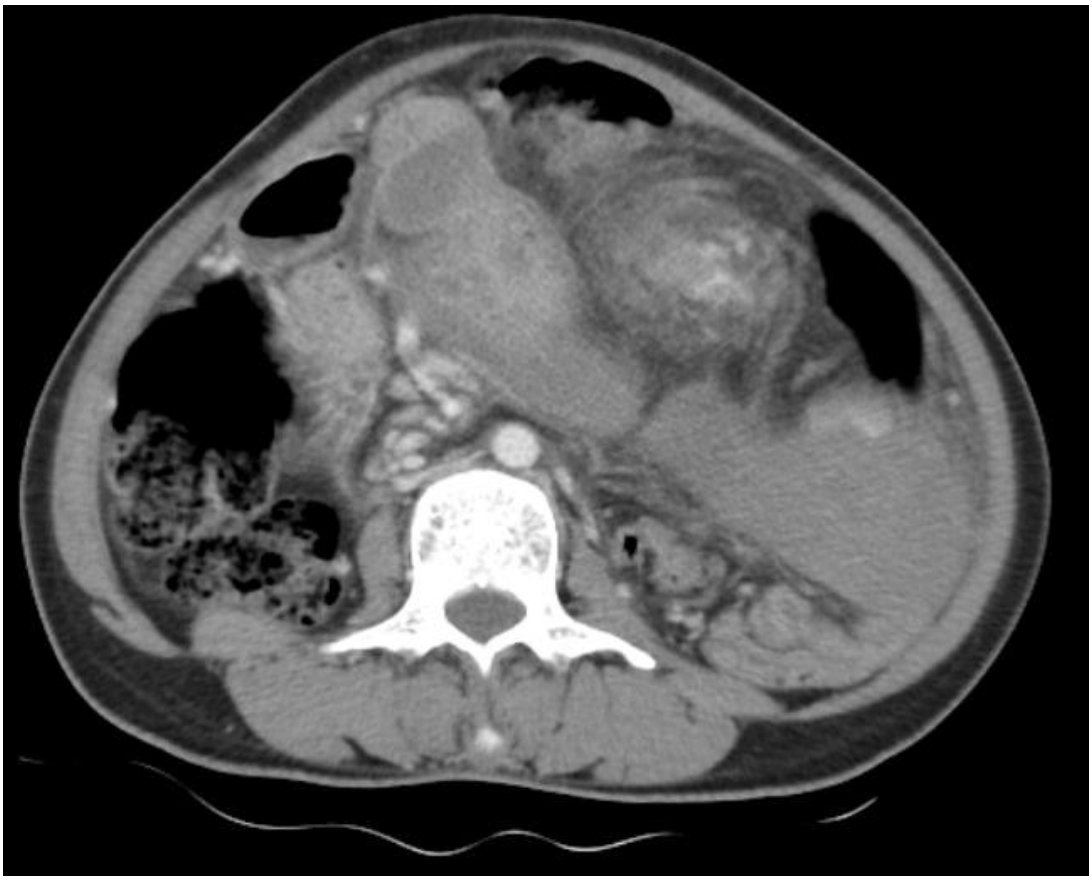

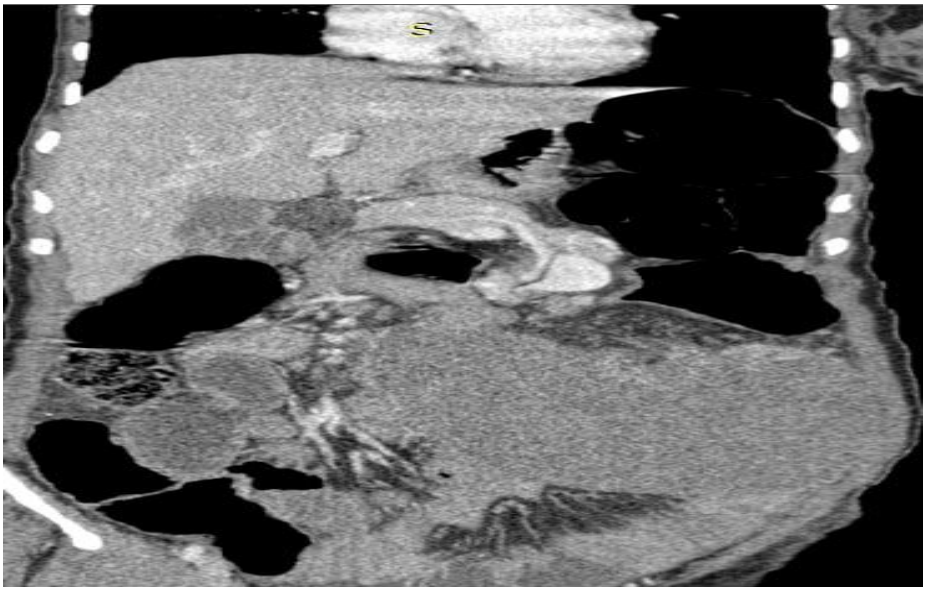
S





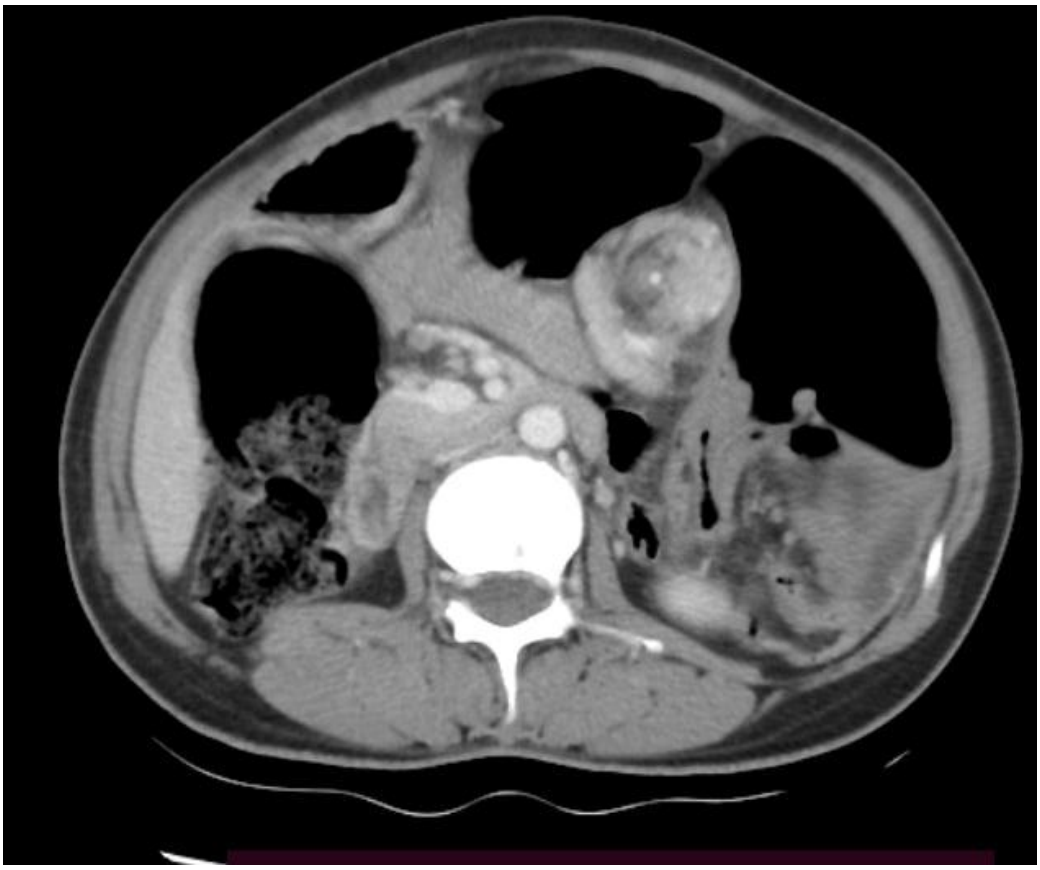

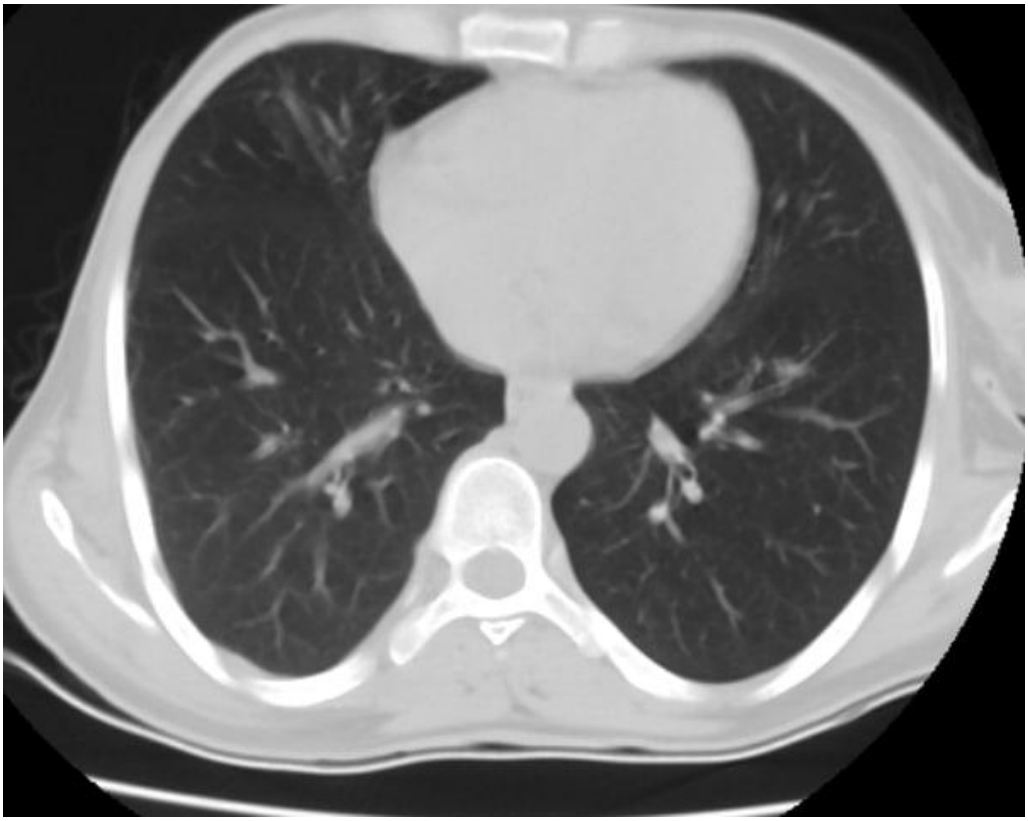

Figure 2. Contrast-Enhanced Computed Tomography Findings Demonstrating a Torsed splenopancreatic with Wandering Spleen and splenic in a 39-Year-Old Patient.

Operative management: Surgical exploration revealed a 720-degree counterclockwise torsion of the splenopancreatic complex around the splenic vascular pedicle, associated with extensive splenic infarction. The spleen was ectopically located, with an empty splenic fossa and absence of the supporting splenic ligaments. The twisted pedicle was carefully detorsed intraoperatively; however, the spleen remained nonviable, necessitating splenectomy. The pancreas was edematous but viable, allowing preservation of the pancreatic tail. The splenic vessels were ligated individually, and a drain was placed in the lesser sac.



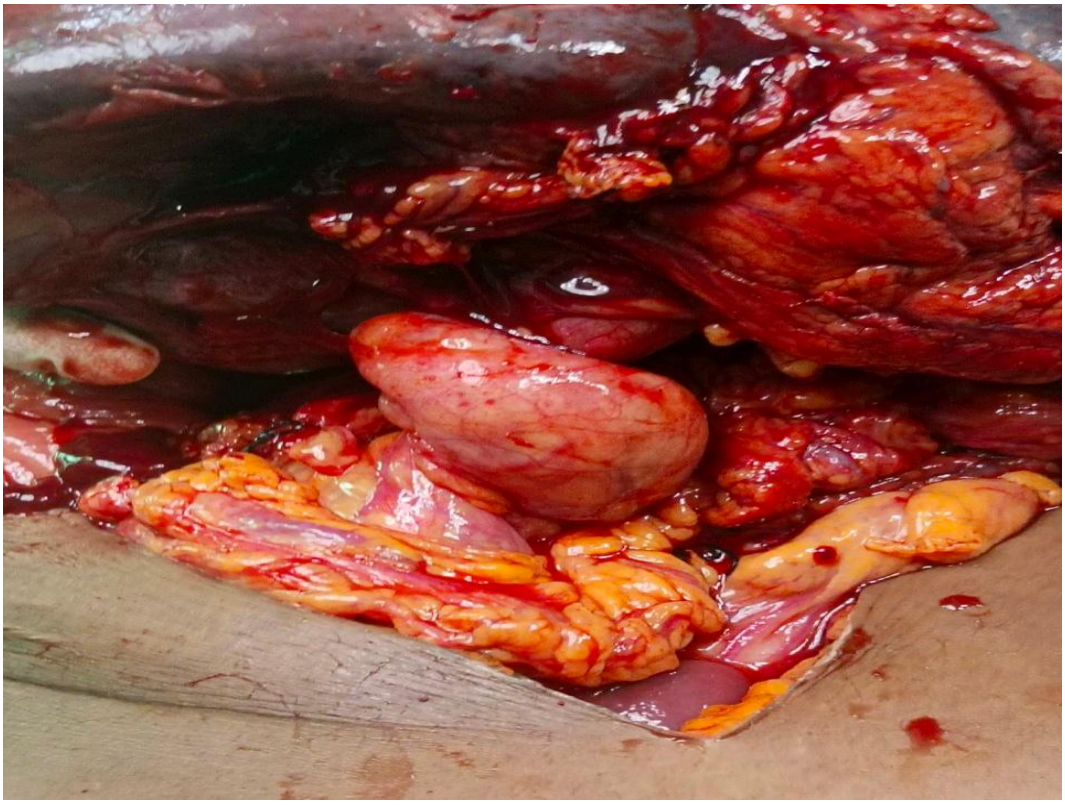

Figure 3. Intraoperative Findings of Splenopancreatic torsion with Wandering Spleen and Splenic Infarction in a 39-Year-Old Patient.

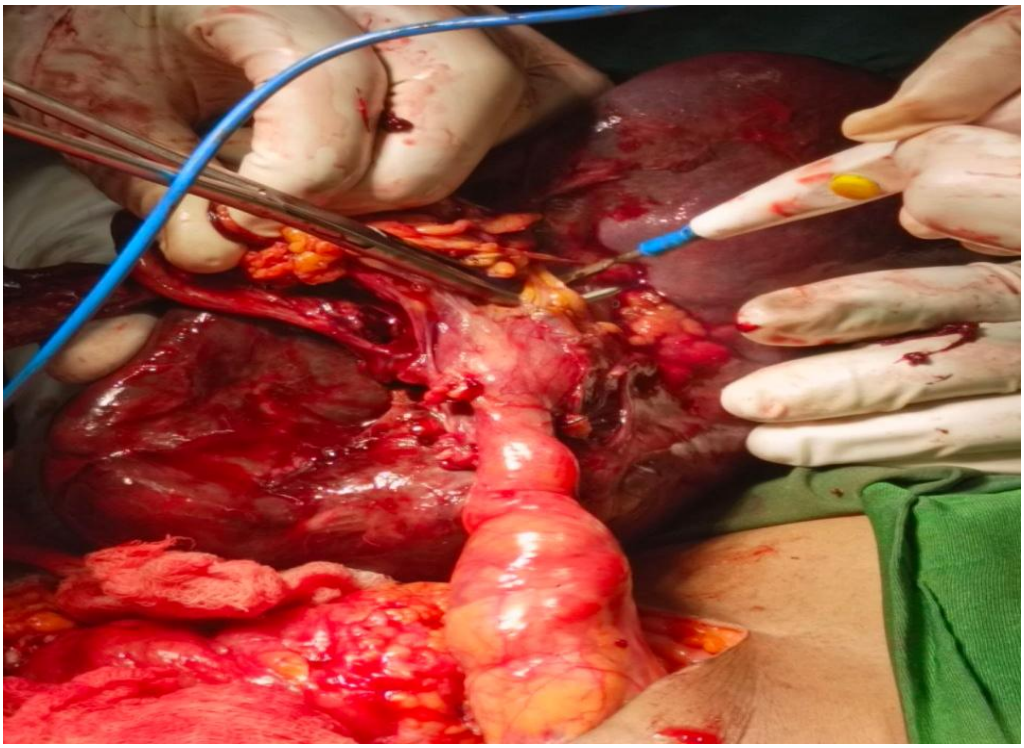

Figure 4. Intraoperative Findings Following Derotation of Splenopancreatic Torsion in a 39-Year-Old Patient.



Figure 5. Resected spleen of a 39-Year-Old Patient.

The patient was described as anemic and was monitored with invasive and non-invasive blood-pressure monitoring and standard anesthetic monitoring. She remained stable throughout the procedure despite one unit of whole blood was transfused intraoperatively.

General Anesthesia was induced using a 1:1 ketofol mixture (ketamine and propofol) and suxamethonium, and maintained with 1% isoflurane in oxygen at a flow rate of 5 L/min. Intraoperative analgesia included 4 mg of intravenous morphine and, 1 g of intravenous paracetamol was administered. Postoperatively

Ultrasound-guided rectus sheath and transversus abdominis plane (TAP) blocks were also performed for multimodal analgesia. The detailed intraoperative anesthesia records are provided in **Annex 2**.

Postoperative outcome: Following surgery, the patient was transferred to the recovery room and subsequently to the surgical ward for postoperative monitoring. Drain-fluid amylase and lipase levels were within normal limits, allowing removal of the drain on postoperative day 4. Histopathological examination of the resected spleen was not requested because the treating team considered it clinically unnecessary. The patient recovered uneventfully and was discharged in stable condition on postoperative day 5 with antibiotic therapy. Post splenectomy vaccination was neither planned nor documented. The patient was followed for three weeks through telephone communication and scheduled outpatient appointments.

Written informed consent was obtained from the patient for publication of this case report and the accompanying clinical images (Annex 3).

Discussion

Wandering spleen is a rare condition characterized by abnormal splenic mobility due to inadequate ligamentous fixation. Although patients may present with chronic or intermittent abdominal discomfort, torsion of the splenic pedicle can result in acute vascular compromise and splenic infarction [1, 5]. The present case describes a 39-year-old woman who presented with five days of left-sided abdominal pain, distension, vomiting, and a tender abdominal mass. Imaging reportedly demonstrated a wandering spleen with empty splenic fossa, and Splenopancreatic torsion along splenic vascular pedicle and splenic infarction. The combination of extensive splenic infarction, reported 720° rotation, and a suspected pancreatic hematoma represents a notable feature of this case.

The acute presentation is comparable to cases reported by Cui et al. (2024)[3] and Hamidi et al. (2024)[6], in which abdominal pain and imaging evidence of an ectopic, poorly perfused spleen suggested complicated wandering spleen. Cui et al. (2024)[3] described a twisted splenic pedicle and absent splenic enhancement, with infarction subsequently confirmed histologically. Hamidi et al. (2024)[6] similarly reported impaired splenic enhancement associated with 720° pedicle

rotation. These findings highlight the importance of considering wandering-spleen torsion in patients presenting with acute abdominal pain and a palpable mass.

In contrast, Colombo et al. (2020)[2] and Lebron et al. (2008)[7] described recurrent or chronic presentations associated with wandering spleen and pancreatic displacement. Colombo et al. reported recurrent abdominal pain and a multi-infarcted spleen, whereas Lebron et al[7]. described recurrent pancreatitis associated with displacement of the spleen and pancreatic tail. Compared with these presentations, the present case involved acute symptoms accompanied by extensive splenic infarction and a suspected pancreatic lesion. However, scholars agree that CT is particularly valuable in diagnosing wandering-spleen torsion because it can demonstrate splenic malposition, vascular pedicle twisting, and impaired parenchymal enhancement [1, 6].

Torsion of the splenic pedicle may obstruct venous drainage and subsequently compromise arterial perfusion, leading to congestion, ischemia, and infarction. The reported 720° rotation in this case is comparable to the 720° torsion described by Cui et al. (2024)[3] and Hamidi et al. (2024)[6]. Wubie et al. (2025)[8] reported an even greater degree of rotation, with 1080° counterclockwise torsion and an infarcted spleen identified at laparotomy. These reports demonstrate that substantial pedicle rotation can accompany severe splenic vascular compromise. Nevertheless, the degree of torsion alone should not be considered a direct measure of infarction severity, as the duration of vascular compromise and residual splenic perfusion may also influence tissue viability.

Pancreatic involvement is a distinctive aspect of the present case. Previous reports have described pancreatic displacement, traction, folding, or apparent torsion in association with wandering spleen, although the extent of pancreatic injury and its diagnostic confirmation have varied.

Feroci et al. (2008)[4] described ectopic positioning of the pancreatic body and tail in association with a wandering spleen and severe pedicle torsion. Colombo et al. (2020) [2]reported pancreatic-tail displacement or traction during surgery. Lebron et al. (year) described pancreatic-tail displacement and folding associated with recurrent pancreatitis. More recently, Cui et al. (2024) reported imaging and operative findings suggestive of pancreatic-tail torsion. Collectively, these reports indicate that abnormal splenic mobility may alter the anatomical relationship between the spleen and pancreatic tail, potentially resulting in displacement or traction.

The management of wandering spleen complicated by torsion depends principally on splenic viability and the extent of infarction. Splenopexy may be considered when the spleen remains viable after detorsion, whereas splenectomy is generally appropriate when extensive irreversible infarction or necrosis is present. In the present case, the spleen was ectopically located, with an empty splenic fossa and absence of the supporting splenic ligaments. The twisted pedicle was carefully detorsed intraoperatively; however, the spleen remained nonviable, necessitating splenectomy. The pancreas was edematous but viable, allowing preservation of the pancreatic tail. The splenic vessels were ligated individually, and a drain was placed in the lesser sac, this approach is consistent with the management described in previous reports, including Colombo et al. (2020)[2], Cui et al. (2024)[2], and Wubie et al. (2025)[8], and the patient was discharged on the fifth postoperative day, uneventfully.

This case highlights the importance of recognizing wandering-spleen torsion as a potential cause of acute abdominal pain and extensive splenic infarction. It also emphasizes the need to assess adjacent pancreatic structures when splenic pedicle torsion is suspected. Nevertheless, the available case reports are insufficient to establish the frequency of pancreatic involvement, define a distinct splenopancreatic torsion syndrome, or determine whether the degree of splenic rotation predicts pancreatic injury.

Conclusion: Wandering-spleen torsion is a rare but important cause of acute abdominal pain and may lead to extensive splenic infarction requiring splenectomy. This case highlights a 39-year-old woman with a wandering spleen complicated by extensive splenic infarction and suspected splenopancreatic torsion. Surgical exploration and splenectomy was performed, with an uneventful postoperative recovery and discharge on the fifth postoperative day.

Declarations

Ethics approval and Consent for publication

According to the policy of the Institutional Review Board (IRB) of the College of Medicine and Health Sciences, Bahir Dar University, ethical approval is waived for case reports. Written informed consent was obtained from the patient for publication of the case report and accompanying clinical images.

Availability of data and materials

The clinical information supporting this case report is available from the corresponding author upon reasonable request, subject to institutional requirements and protection of patient confidentiality.

Competing interests

The authors declare that they have no competing interests.

Funding

The authors received no specific funding for this work.

Authors' contributions

Dr. Nebiat and Samuel contributed to the conception and design of the case report. Dr. Tilahun, Dr. Zelalem, Dr. Yenebilew, Dr. Oumer, and Hailemariam contributed to the patient's clinical care and data collection. Dr. Nebiat, in collaboration with the radiology team, contributed to radiological interpretation. Samuel and Hailemariam contributed to anesthesia and perioperative management. Samuel and Dr. Nebiat contributed to the literature review and manuscript drafting. All authors critically reviewed the manuscript, approved the final version, and agree to be accountable for its content.

Acknowledgements

The authors sincerely thank the patient for consenting to the publication of this case report and the accompanying clinical images. The authors also acknowledge Tibebe Ghion Specialized Hospital for its support and for facilitating the patient's clinical care and documentation.

Patient perspective

The patient described her illness as severe but expressed satisfaction with the treatment she received. She reported a good recovery following surgery.

References

1. Ben Ely, A., et al., *The wandering spleen: CT findings and possible pitfalls in diagnosis.* Clin Radiol, 2006. **61**(11): p. 954-8.
2. Colombo, F., et al., *Torsion of wandering spleen involving the pancreatic tail.* Ann Med Surg (Lond), 2020. **50**: p. 10-13.
3. Cui, Q., et al., *Wandering spleen combined with pedicle torsion and splenic infarction: a rare case report and literature review.* Front Pediatr, 2024. **12**: p. 1429490.
4. Feroci, F., et al., *The torsion of a wandering pelvic spleen: a case report.* Cases Journal, 2008. **1**(1): p. 149.
5. Bough, G.M., et al., *Diagnosis, management and outcome of splenic torsion; a systematic review of published studies.* Surgeon, 2022. **20**(5): p. e296-e305.
6. Hamidi, H., H. Osmani, and R.M. Zahin, *Computed tomography features and surgical treatment of wandering spleen torsion: A case report.* Radiol Case Rep, 2024. **19**(12): p. 6213-6216.
7. Lebron, R., et al., *Wandering spleen presenting as recurrent pancreatitis.* Jsls, 2008. **12**(3): p. 310-3.
8. Gashaw Wubie, A., B. Yirga, and M.H. Goedert, *Splenic infarction following torsion of wandering spleen involving pancreatic tail successfully managed in resource limited setting: a case report.* J Med Case Rep, 2025. **19**(1): p. 41.

Supplementary Files

This is a list of supplementary files associated with this preprint. Click to download.

- Suplimentaryfile.docx