Research Square

Preprints are preliminary reports that have not undergone peer review.
They should not be considered conclusive, used to inform clinical practice,
or referenced by the media as validated information.

The role of histopathology and immunohistochemistry in diagnosing PCNSL with Atypical Radiological Presentations: A Five case series

Charusheela Gore
Dr D.Y Patil Medical College
Shraddha Khanke
Dr D.Y Patil Medical College
Sushama Gurwale
Dr D.Y Patil Medical College
Ashish Chugh
Dr D.Y Patil Medical College
Dhruv Rami
Dhruvrami1999@gmail.com

Dr D.Y Patil Medical College

Case Report

Keywords: Primary CNS lymphoma, diffuse large B-cell lymphoma, PCNSL, brain lymphoma, histopathology, immunohistochemistry, intracranial space occupying lesion

Posted Date: November 23rd, 2026

DOI: https://doi.org/10.21203/rs.3.rs-11547911/v1

License: This work is licensed under a Creative Commons Attribution 4.0 International License.
Read Full License

Additional Declarations: No competing interests reported.

Abstract

Background - Primary central nervous system lymphoma (PCNSL) is a rare and aggressive extranodal lymphoma. It predominantly comprises of diffuse large B cell lymphoma (DLBCL), which accounts for approximately 90 to 95% of cases.

Cases presentation - We present 5 histopathologically proven cases of primary CNS lymphoma diagnosed at a tertiary care center. The lesions involved the frontal, temporoparietal, temporal, hypothalamic, and parietal regions. The clinical manifestations included headache, seizures, gait imbalance, focal neurological deficits, visual disturbance, personality changes and bladder dysfunction. Radiological evaluation frequently favoured high-grade glioma or metastatic disease. Histopathological examination demonstrated diffuse infiltration of brain parenchyma by atypical cells with variable perivascular or angiocentric distribution along with brisk mitotic activity and areas of necrosis. Immunohistochemistry established B cell lineage and supported a diagnosis of DLBCL in all five cases.

Conclusions - Early diagnosis and multidisciplinary management are essential for improving patient outcomes.

Introduction

Primary central nervous system lymphoma (PCNSL) is an uncommon extranodal non-Hodgkin lymphoma restricted to the central nervous system, principally involving the brain, spinal cord, leptomeninges, and vitreoretinal compartment, without evidence of systemic lymphoma at the time of diagnosis.[1] It accounts for a small proportion of primary brain malignancies and less than 1% of non-Hodgkin lymphomas(NHL).[2] Approximately 90–95% of PCNSLs are diffuse large B-cell lymphomas(DLBCL), making primary CNS DLBCL the dominant histological form encountered in routine neuropathological practice.[2] The disease can occur in both immunocompetent and immunocompromised individuals, although the epidemiological profile and clinical setting differ between these groups.[3]

The clinical presentation is highly variable and depends on the anatomical site and extent of CNS involvement.[1] Patients may present with focal neurological deficits, cognitive or behavioural changes, seizures, gait abnormalities, visual disturbances, cranial neuropathies, or symptoms related to raised intracranial pressure.[2]

Radiological diagnosis can be challenging because its imaging appearance overlaps with several other intracranial neoplasms and inflammatory conditions.[4] Classically, PCNSL appears as an enhancing mass, often involving deep or periventricular structures, but atypical imaging patterns are well documented.[5] High-grade glioma and metastatic disease are among the most important radiological differential diagnoses.[6] Histopathological examination (HPE) therefore remains central to establishing the diagnosis.[4]

Case Series

Case 1

A 35-year-old male presented with personality changes, headache, difficulty in walking with imbalance, bladder incontinence, and one episode of seizure. Contrast-enhanced CT of the brain demonstrated a lobulated hyperdense lesion in the right basi frontal region showing post-contrast enhancement with surrounding perilesional edema. Additional well-defined nodular enhancing lesions were identified in the right lentiform nucleus, head of the right caudate nucleus, genu of the corpus callosum, left lentiform nucleus, and right parafalcine parietal lobe. Radiological differentials were glioma vs metastasis.**[**Figure 3 **- A]**

HPE showed fragments of tumor arranged in nesting and diffuse patterns. The tumor cells displayed highly pleomorphic, hyperchromatic nuclei and moderate amounts of eosinophilic cytoplasm. Some cells showed prominent nucleoli. Few tumor giant cells were identified. The intervening stroma showed mild to moderate infiltration by small lymphocytes along with areas of necrosis. Histopathological differential diagnoses were lymphoma, poorly differentiated metastatic carcinoma, melanoma and Hodgkin's lymphoma. Immunohistochemistry (IHC) showed positivity for LCA and CD20 in the tumor cells which confirmed B-cell lymphoid differentiation. BCL2 demonstrated patchy positivity while BCL6 showed positivity in scattered nuclei. CD3 highlighted the background of lymphocytic population. The tumor cells were negative for CD30, EMA, S100, ALK1 and CD10. The Ki-67 index was 60 to 70%. The lesion was diagnosed as DLBCL.

Case 2

A 70-year-old female presented with headache, hemiplegia, and gait imbalance. CT brain demonstrated a large ill-defined intra axial mass lesion in the right cerebral hemisphere involving gangliocapsular region and extension into the frontal, temporal, and insular regions, associated with extensive vasogenic edema and significant mass effect. The radiological findings favoured the diagnosis of glioma. **[**Figure 3 **- B]** HPE demonstrated neuroglial tissue infiltrated by medium to large lymphoid cells with scattered larger cells. IHC showed tumor-cell positivity for CD20, BCL2, and BCL6. CD3 highlighted numerous background lymphocytes. The tumor cells were negative for CD30 and EBV. ATRX expression was retained in the glial component. The Ki-67 index was around 60%. The lesion was diagnosed as High-grade B-cell lymphoma with double expression of BCL2 and BCL6 .

Case 3

A 53-year-old male presented with gait imbalance and decreased vision in his left eye. CT brain demonstrated an ill-defined enhancing lesion in the left anterior temporal region associated with mass effect. The differential diagnosis included glioma and metastasis. **[**Figure 3 **- C]**

HPE revealed a tumor composed of medium to large lymphoid cells arranged in loosely cohesive sheets along with prominent perivascular cuffing. The neoplastic cells exhibited vesicular nuclei, prominent nucleoli and scant cytoplasm. Extensive areas of necrosis were present with fragments of otherwise preserved brain parenchyma. IHC demonstrated strong positivity for CD20 in the tumor cells. BCL2 and BCL6 were positive in the neoplastic population of cells. CD3, CD2, CD5, and CD7 highlighted the background T lymphocyte rich population. The tumor cells were negative for GFAP, CD10 and EBV. The Ki-67 index was 60 to 70%. The overall morphological and immunophenotypic findings supported a diagnosis of DLBCL of the CNS.

Case 4

A 30-year-old female presented with two episodes of generalized tonic clonic seizures, intermittent fever occurring for one year associated with chills and rigor. CT revealed well-defined solid intracranial lesion showing intense homogeneous post contrast enhancement in the hypothalamic region and extending to the posterior portion of the optic chiasm. The differential diagnosis included hypothalamic glioma and hypothalamic craniopharyngioma. **[**Figure 3 **- D]**

HPE showed fragments of neurological tissue diffusely infiltrated by cells with large hyperchromatic nuclei and coarse chromatin. Some population of cells demonstrated prominent nucleoli and scant cytoplasm. The background contained small lymphocytes, occasional plasma cells and areas of sclerotic stroma. **[**Figure 1 **– A and B]** The histopathological differentials were germ cell tumor, metastasis and lymphoma. Immunohistochemistry demonstrated LCA and CD20 positivity in the neoplastic population. BCL2 and BCL6 were positive and the Ki-67 index was approximately 80%. The tumor cells were negative for CD30, CD117, panCK and ATRX. The findings were consistent with DLBCL involving the CNS. **[**Figure 2 **– A,B,C,D,E,F,G and H]**

Case 5

A 54-year-old male presented with headache and dizziness. MRI brain demonstrated a lesion involving the corpus callosum with satellite lesions, suggestive of a butterfly glioma, high grade glioma or glioblastoma, lymphoma in the differential diagnosis. **[**Figure 3 **- E]**

HPE showed complete effacement of the normal brain parenchyma by a diffuse dense proliferation of large atypical ? lymphoid cells with large nuclei and scant cytoplasm, vesicular chromatin, and prominent nucleoli. Focal areas of typical angiocentric arrangement of neoplastic cells and confluent areas of necrosis were also seen. **[**Figure 1 **– C and D]** Histopathological differential diagnosis were NHL, Hodgkin’s lymphoma and neuroendocrine tumor. The tumor cells showed positivity for LCA, CD20, MUM1, BCL6, and BCL2. While GFAP, CD10, CD30, and INSM1 were negative. The Ki-67 index was 60 to 70%. Diagnosis of DLBCL of the CNS was established.

Table 1
Clinicoradiological, Histopathological and Immunohistochemical Profile of all five Cases

Serial number	Age/Sex	Radiological diagnosis	Histopathology findings	IHC findings
1	35/M	CT Scan - Imaging features are suggestive of metastatic lesions. Other possible differential includes multicentric high grade glioma.	Nesting and diffuse tumor pattern with highly pleomorphic hyperchromatic cells, prominent nucleoli, giant cells and necrosis.	LCA+, CD20+, BCL2+, BCL6+; CD3 + background; Ki-67 60–70%. CD30−, EMA−, S100−, ALK1−, CD10−.
2	70/F	CT Scan - Findings are highly suggestive of neoplastic etiology-? glioma.	Neuroglial tissue infiltrated by small–medium lymphoid cells with few large cells; occasional mitosis; increased glial cells.	CD20+, BCL2+, BCL6+; CD3 + background; Ki-67 50–60%; CD30−, EBV−; ATRX retained.
3	53/M	CT scan - ?glioma ? metastasis. Needs clinical and histopathological correlation. Gliotic area in left occipital region.	Medium–large lymphocytes in loosely cohesive sheets with perivascular cuffing; vesicular nuclei, prominent nucleoli, scant cytoplasm and extensive necrosis.	CD20+, BCL2+, BCL6+; CD3/CD2/CD5/CD7 + background; Ki-67 60–70%; GFAP−, CD10−, EBV−.
4	30/F	CT scan - Features likely represent Neoplastic pathology. Possible differential diagnosis includes: 1. Optic pathway/ hypothalamic glioma 2. Hypothalamic craniopharyngioma	Neurological tissue diffusely infiltrated by large hyperchromatic cells with coarse chromatin, prominent nucleoli and scant cytoplasm; small lymphocytes, plasma cells and sclerosis.	LCA+, CD20+, BCL2+, BCL6+; Ki-67 ~ 80%; CD30−, CD117−, PanCK−, ATRX−.
5	54/M	CT Scan - neoplastic etiology - butterfly glioma-high grade glioma/ glioblastoma multiforme involving corpus callosum and above mentioned sites with satellite lesions. Differential-lymphoma needs consideration	Diffuse dense proliferation of large atypical lymphoid cells with vesicular chromatin, prominent nucleoli, angiocentric pattern and confluent necrosis.	LCA+, CD20+, MUM1+, BCL2+, BCL6+; Ki-67 60–70%; GFAP−, CD10−, CD30−, INSM1−.

Discussion

Primary CNS lymphoma is an uncommon but highly aggressive extranodal lymphoma with a distinctive clinicopathological profile. The present series of five histopathologically proven cases demonstrates the broad clinical and radiological spectrum of PCNSL and highlights the persistent difficulty in distinguishing it from high grade glioma, metastatic disease, and other intracranial neoplasms. Many a times on HPE also it is not a straight forward diagnosis. The predominance of DLBCL in our series is consistent with the overwhelming predominance of this histological subtype in PCNSL.[1]

The patients ranged from 30 to 70 years, reflecting the broad age spectrum, although the disease particularly occurs among older immunocompetent individuals.[2]The symptoms vary according to the anatomical location of the lesions, as in our series, rather than a specific lymphoma associated clinical syndrome.[3] Case 4 presented with panhypopituitarism as lesion involved hypothalamic area.

Radiologically, high grade glioma was the most common diagnosis offered (in all five cases) while metastatic disease was considered as a differential in two cases. This observation suggests that imaging findings alone may not reliably distinguish PCNSL from other aggressive intracranial tumors.[5] They usually presents as a solid, contrast enhancing lesion with marked diffusion restriction because of its high cellularity.[6] Deep periventricular structures, basal ganglia, corpus callosum, and thalamus are recognized sites of involvement but lesions may occur throughout the brain.[6] In our cases involved regions were frontal, temporoparietal, temporal, hypothalamus, parietal/corpus callosum. The multifocality was seen in case 1, while butterfly corpus callosum lesion mimicked glioblastoma in case 5.

As is with the radiological and clinical diagnosis challenges, histopathological diagnosis is also not straight forward in many cases. The differential diagnosis of PCNSL on histopathology is wide and includes all neuroepithelial tumors, in particular glioblastoma, metastatic lesions, particularly carcinoma metastasis, CNS metastasis of hematopoietic tumors like extracerebral DLBCL, particularly testicular and Intravascular DLBCL, EBV-positive DLBCL of the elderly, Hodgkin's lymphoma; histiocytic tumors, inflammatory disorders like multiple sclerosis, vasculitis etc.

The characteristic microscopic appearance of PCNSL-DLBCL consists of large atypical lymphoid cells arranged in solid sheets, with perivascular cuffing and brisk proliferative activity.[7] The neoplastic cells typically exhibit round to oval vesicular nuclei, prominent nucleoli, and moderate amounts of cytoplasm, with centroblastic and immunoblastic morphological patterns being recognized.[7] Perivascular or angiocentric growth was particularly evident in Case 3 and 5. This feature is an important diagnostic clue, although it is not absolutely specific for DLBCL because perivascular lymphoid infiltration can also be encountered in other primary CNS lymphomas.[8]Necrosis was present in four cases, making radiological diagnosis of glioblastoma a consideration. Recent reports confirm that necrosis and even microvascular proliferation on HPE can occasionally be encountered in PCNSL, potentially leading to misdiagnosis in small biopsies.[9]

All five cases demonstrated a B-cell phenotype, with CD20 expression being a major diagnostic feature. CD20 is among the principal markers used to establish B-cell lineage in PCNSL and is routinely incorporated into the diagnostic work up.[7]In PCNSL the immunohistochemical profile usually demonstrates expression of pan-B-cell markers, particularly CD20, CD79a, and PAX5, while BCL6, MUM1, BCL2, and CD10 show variable expression.[2] In our series, BCL6 and BCL2 expression was identified in all the cases, while CD10 was negative. This is in keeping with published data demonstrating that CD10 expression is uncommon in PCNSL-DLBCL, whereas BCL6 and MUM1 are expressed in the majority of cases, thus presence of CD10 expression in a CNS lymphoma should prompt careful evaluation for systemic DLBCL with secondary CNS involvement .[10] In this case series, the Ki-67 proliferative index ranged from approximately 50% to 80%, confirming the highly proliferative nature of the tumors. PCNS DLBCL is characteristically associated with a high proliferative index, which may reach approximately 90% in many cases.[10]

A rational IHC panel including CD20, CD3, GFAP, panCK, and Ki-67 is essential to exclude mimics. In case 1, CD30 was negative, ruling out Hodgkin lymphoma; negativity for CD30 and ALK1 ruled out anaplastic large cell lymphoma; EMA and panCK negativity excluded metastatic carcinoma; lack of S100 staining ruled out melanocytic tumor and negative GFAP ruled out glial tumor. In case 4, negative CD117 ruled out the diagnosis of germ cell tumor and negative panCK ruled out metastasis, which were the differentials on routine HPE. In case 5, INSM1 negativity excluded neuroendocrine tumor. In all 5 cases, CD30 negativity ruled out Hodgkin's lymphoma. In case 2 and 3, negative EBV and comparatively low Ki index, ruled out EBV positive DLBCL of elderly. Negative GFAP in case 1 and 5 ruled out glioblastoma or high grade glioma.

All five cases in the present series were diagnosed histopathologically, emphasizing the continuing importance of tissue diagnosis. Stereotactic biopsy remains the standard diagnostic approach for most patients with suspected PCNSL, particularly when lesions are deep seated, multifocal or located in eloquent areas.[11]Surgical excision is not routinely required solely for diagnosis because PCNSL is highly chemosensitive and extensive resection may expose patients to unnecessary neurological morbidity.[11]

The reporting pathologist should also be aware of corticosteroids mitigated PCNSL as steroids are widely used to lower increased intracranial pressure. Also, PCNSL may vanish on MRI and biopsy samples as malignant and non-malignant lymphocytes are highly susceptible to steroid induced apoptosis. On HPE, there is only slight increase in cellularity, B-cell blasts may be absent or scant. Foamy macrophages are seen. Reactive gliosis and microglial activation is prominent with sparse perivascular and parenchymal leukocytes. If the number of blasts is very low, pseudoclonality is a pitfall, like the background consisting entirely of T cells.[12] In our cases high number of background T cells may be due to prior steroid therapy as there was no clinical or radiological suspicion of lymphoma.

High dose methotrexate-based chemotherapy remains the cornerstone of treatment for primary CNS DLBCL.[11] The incorporation of rituximab into methotrexate-based treatment has contributed to

improved survival compared with historical treatment approaches.[11]Inclusion of whole brain irradiation may improve progression free survival however it increases the risk of neurotoxicity especially on patients more than 60 years. Consolidation strategies may involve autologous stem-cell transplantation or radiotherapy in selected patients, while treatment intensity must be individualized according to age, performance status, comorbidities and disease response. Relapse remains a major challenge requiring individualised salvage strategies.[1]

CNS-DLBCL has a worse outcome than systemic DLBCL. Older patients (> 65yrs) and transcobalamin missense variant TCN2:c.776C > Gp.P259R have shorter survival and neurotoxicity. The presence of reactive perivascular CD3 T-cell infiltrates on biopsy is associated with improved survival. BCL6 expression have conflicting conclusions whether it is a favourable or unfavourable marker. [13]

Conclusion

Primary CNS lymphoma (PCNSL) is a rare and aggressive malignancy with diverse clinical and radiological presentations, often mimicking glioblastoma or metastatic disease. This case series emphasizes the importance of considering PCNSL in the differential diagnosis of intracranial mass lesions. Histopathology with appropriate immunohistochemistry remains crucial for definitive diagnosis. A high index of suspicion with close clinico-radiological and pathological correlation are essential for early recognition, accurate diagnosis, and timely initiation of appropriate therapy.

Abbreviations

PCNSL
Primary central nervous system lymphoma
DLBCL
diffuse large B cell lymphoma
CNS
Central nervous system
NHL
Non-Hodgkin lymphoma
IHC
Immunohistochemistry
HPE
Histopathological examination
CT
Computed tomography

Declarations

Ethics approval and consent to participate -

The study was conducted in accordance with the ethical principles of the Declaration of Helsinki. Ethical approval was obtained from the Institutional Ethics Committee of DR D.Y. Patil medical college, hospital and research centre.

Competing interests -

The authors declare that they have no competing interests.

Conflict of interest

The authors have no conflict of interest

Funding

The authors received no specific funding.

Funding -

No specific grant was received from any funding agency in the public, commercial, or not-for-profit sectors for this study.

Author Contribution

CG contributed to the concepts, study design, definition of intellectual content, literature search, manuscript editing, manuscript review, and acted as a guarantor. DR contributed to the study design, definition of intellectual content, literature search, manuscript preparation, manuscript editing, and acted as a guarantor. SK contributed to the concepts, definition of intellectual content, manuscript editing, manuscript review, and acted as a guarantor. SG contributed to manuscript review and acted as a guarantor. AC contributed to manuscript review and acted as a guarantor.

Acknowledgements -

Department of Pathology, Department of Radiology, and the treating clinical teams at DR D.Y. Patil medical college, hospital and research centre for their support in the evaluation and management of these cases.

Availability of data and material -

The data supporting the findings of this case series are available from the corresponding author upon reasonable request, subject to institutional policies and applicable patient confidentiality requirements.

References

1. Ferreri AJM, Calimeri T, Cwynarski K, Dietrich J, Grommes C, Hoang-Xuan K, et al. Primary central nervous system lymphoma. Nat Rev Dis Primer. 2023;9(1):29. 10.1038/s41572-023-00439-0.
2. Lauw MIS, Lucas CHG, Ohgami RS, Wen KW. Primary Central Nervous System Lymphomas: A Diagnostic Overview of Key Histomorphologic, Immunophenotypic, and Genetic Features. Diagnostics. 2020;10(12):1076. 10.3390/diagnostics10121076.
3. Schaff LR, Grommes C. Primary central nervous system lymphoma. Blood. 2022;140(9):971–9. 10.1182/blood.2020008377 PubMed PMID: 34699590; PubMed Central PMCID: PMC9437714.
4. Luo S, Huang X, Li Y, Wang J. Primary central nervous system CD20-negative diffuse large B-cell lymphoma: a case report. BMC Neurol. 2022;22(1):504. 10.1186/s12883-022-03031-3.
5. Aqil B, Rouah E, Verstovsek G. Primary CNS Marginal Zone Lymphoma: A Case Report and Review of the Literature. Open J Pathol. 2013;03(02):55–9. 10.4236/ojpathology.2013.32010.
6. Menon MP, Nicolae A, Meeker H, Raffeld M, Xi L, Jegalian AG, et al. Primary CNS T-cell Lymphomas: A Clinical, Morphologic, Immunophenotypic, and Molecular Analysis. Am J Surg Pathol. 2015;39(12):1719–29. 10.1097/PAS.0000000000000503.
7. Zhu S, Jin J, Wang X, Xu H, Zhou F, Lai Y, et al. Overcoming missed diagnoses of primary central nervous system Lymphoma—The key role of cerebrospinal fluid cytology: a case report. Diagn Pathol. 2025;20:29. 10.1186/s13000-025-01626-1 . PubMed PMID: 40089740; PubMed Central PMCID: PMC11910839.
8. Ferreri AJM, Reni M, Foppoli M, Martelli M, Pangalis GA, Frezzato M, et al. High-dose cytarabine plus high-dose methotrexate versus high-dose methotrexate alone in patients with primary CNS lymphoma: a randomised phase 2 trial. Lancet. 2009;374(9700):1512–20. 10.1016/S0140-6736.(09)61416-1 PubMed PMID: 19767089.
9. Mittal A, Deopujari C, Mohanty C, Karmarkar V. Case Report Primary CNS Lymphoma & Role Of Surgery – A Narrative Review With Illustrative Cases: Surgery for Primary CNS Lymphoma. Bombay Hosp J. 2024;65(3). 10.15713/ins.bhj.153.
10. Ferreri AJM, Reni M, Pasini F, Calderoni A, Tirelli U, Pivnik A, et al. A multicenter study of treatment of primary CNS lymphoma. Neurology. 2002;58(10):1513–20. 10.1212/wnl.58.10.1513 . PubMed PMID: 12034789.
11. Tekkök IH, Tahta K, Erbengi A, Büyükpamukçu M, Ruacan S, Topçu M. Primary intracranial extradural Burkitt-type lymphoma. A unique presentation with unilateral loss of vision in a child. Childs Nerv Syst ChNS Off J Int Soc Pediatr Neurosurg. 1991;7(3):172–4. doi:10.1007/BF00776718 PubMed PMID: 1878874.
12. Smith C, editor. Greenfield's neuropathology. Tenth edition. Boca Raton: CRC; 2023.

13. WHO Classification of Tumours Editorial Board. Central nervous system tumours. 5th ed. Lyon (France): International Agency for Research on Cancer; 2021. (WHO classification of tumours; vol. 6).

Figures

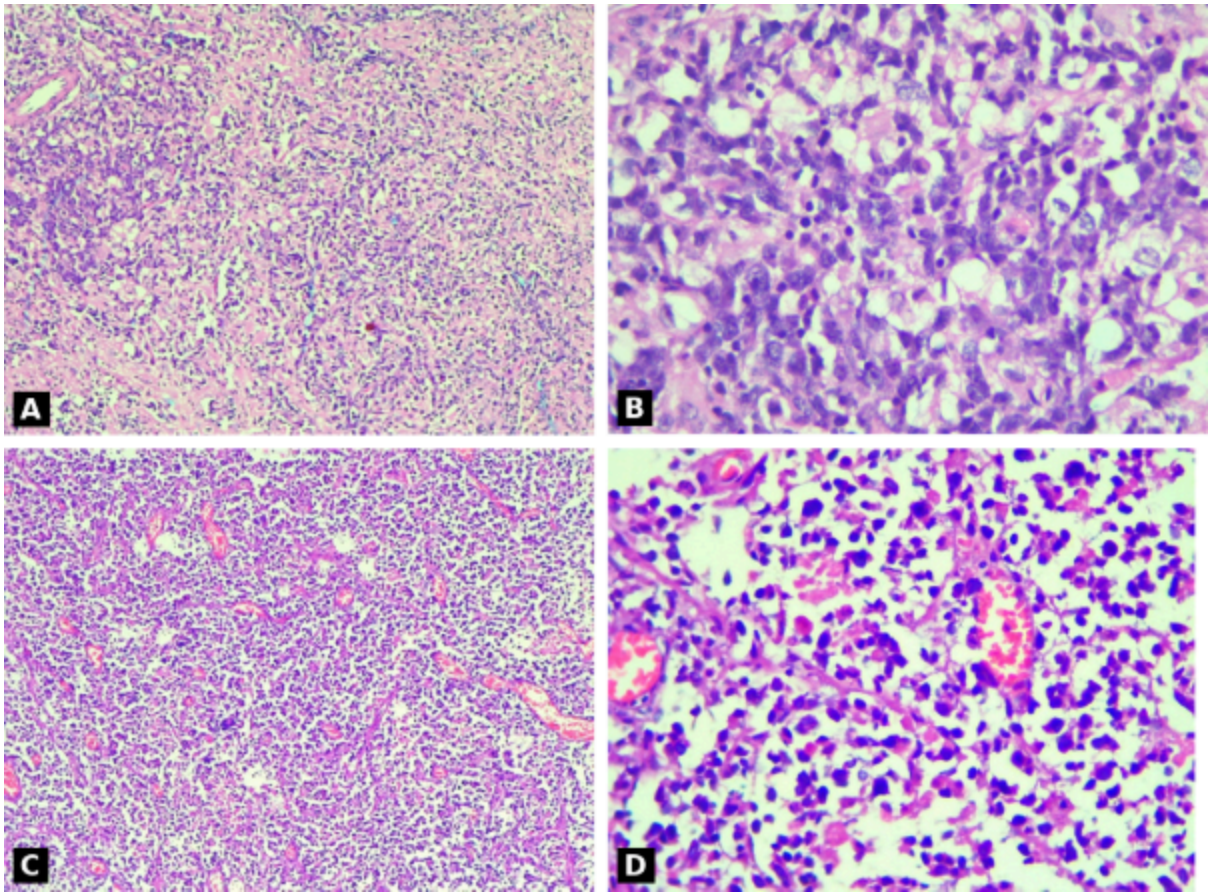

Figure 1

A, B, C and D - H and E microscopy image

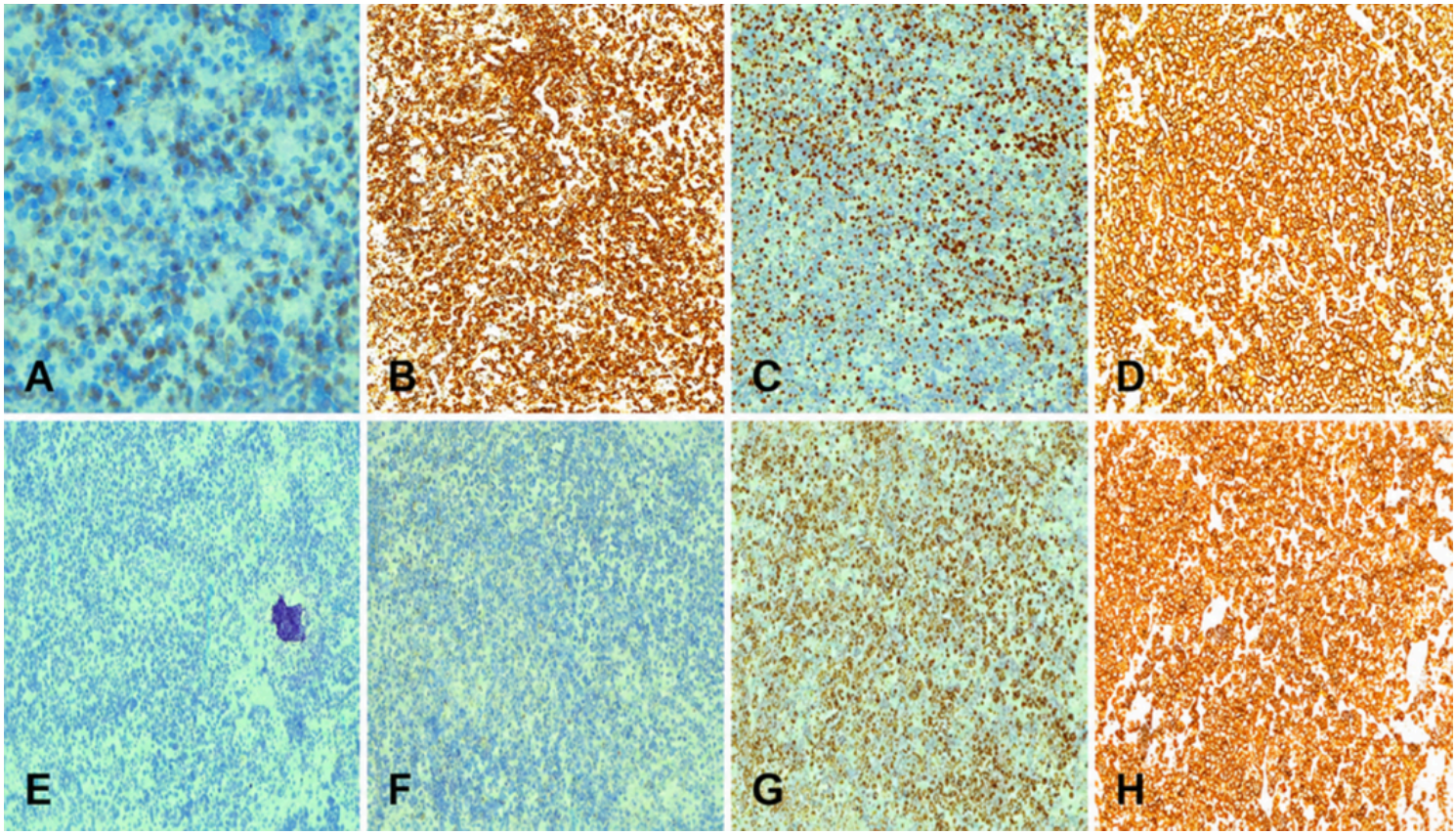

Figure 2

Immunohistochemistry microscopy images

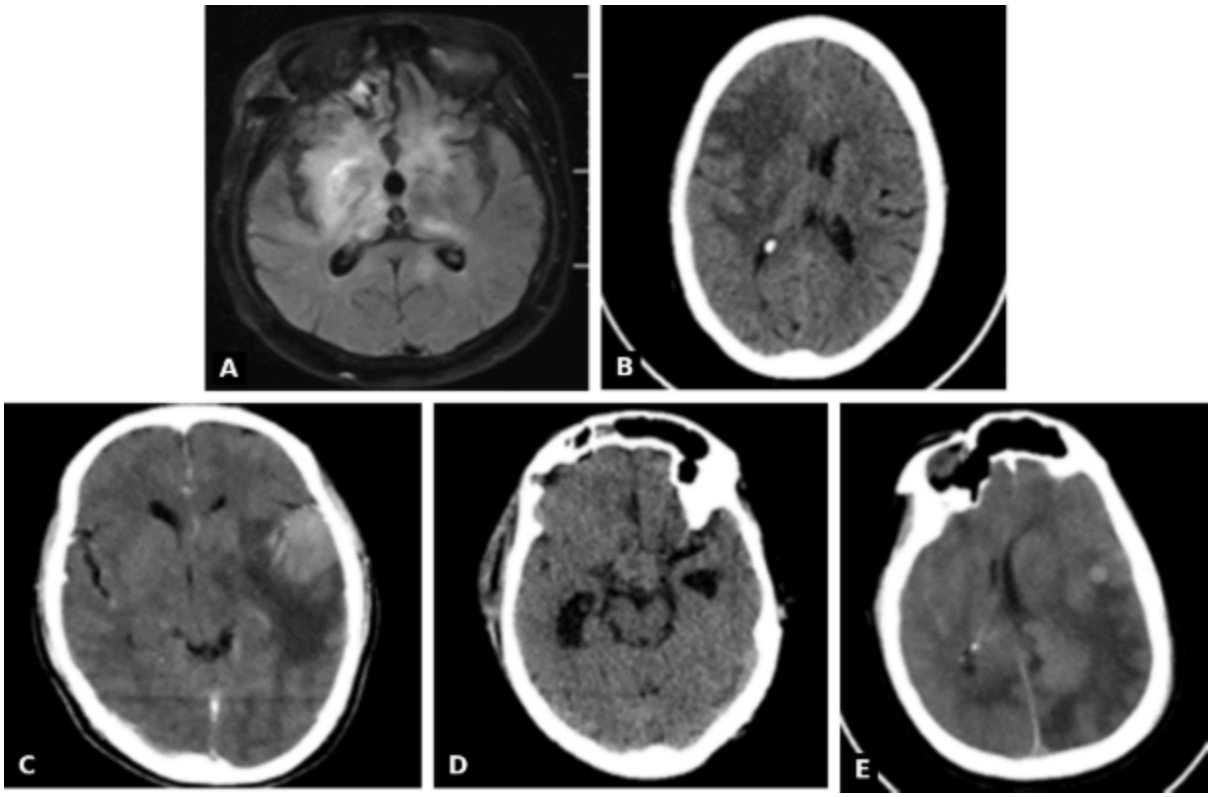

Figure 3

A, B, C, D and E – CT Scan images