Research Square

Preprints are preliminary reports that have not undergone peer review.
They should not be considered conclusive, used to inform clinical practice,
or referenced by the media as validated information.

Amiodarone-associated torsades de pointes after catheter ablation for atrial flutter and atrial fibrillation: a case report and literature review

Liuyan Zhang[1]

zly6021@126.com

Wujin Hospital Affiliated with Jiangsu University, The Wujin Clinical College of Xuzhou Medical University

Jianqiang Xiao[1]

Wujin Hospital Affiliated with Jiangsu University, The Wujin Clinical College of Xuzhou Medical University

Gaojun Cai[1]

Wujin Hospital Affiliated with Jiangsu University, The Wujin Clinical College of Xuzhou Medical University

Jun Gu

Wujin Hospital Affiliated with Jiangsu University, The Wujin Clinical College of Xuzhou Medical University

Case Report

Keywords: Amiodarone, Catheter ablation, QT interval, Torsades de pointes, Ventricular tachycardia

Posted Date: November 23rd, 2026

DOI: https://doi.org/10.21203/rs.3.rs-11539324/v1

License: This work is licensed under a Creative Commons Attribution 4.0 International License.
Read Full License

Additional Declarations: No competing interests reported.

Title page

Title: Amiodarone-associated torsades de pointes after catheter ablation for atrial flutter and atrial fibrillation: a case report and literature review

Authors: Liuyan Zhang[1]*; Jianqiang Xiao[1]; Gaojun Cai[1]; Jun Gu [1]

Affiliations: Department of Cardiology, Wujin Hospital Affiliated with Jiangsu University, The Wujin Clinical College of Xuzhou Medical University, Changzhou, Jiangsu, China.

*Corresponding Author: Liuyan Zhang

Department of Cardiology, Wujin Hospital Affiliated with Jiangsu University, The Wujin Clinical College of Xuzhou Medical University, Changzhou, Jiangsu, China.

No. 2 Yongning Road, Xinbei District, Changzhou, Jiangsu Province, China

zly6021@126.com

Orcid ID:0000-0003-1929-9316

Word Count: 4524

Abstract

Background Amiodarone, a class III antiarrhythmic agent, is widely prescribed for its proven antiarrhythmic efficacy, yet it carries risks of multiorgan toxicities involving the heart, thyroid gland, lung, liver, and ocular structures. Although amiodarone-related torsades de pointes (TdP) is uncommon, this life-threatening arrhythmia may lead to syncope and even cardiac arrest.

Case Presentation We describe the clinical course of a 76-year-old female patient with a dual-chamber pacemaker who was admitted due to chest tightness and palpitations. Coronary angiography ruled out significant coronary artery disease. The patient underwent radiofrequency catheter ablation for atrial flutter and atrial fibrillation. Intravenous amiodarone was initiated about 1 hour after the procedure, followed by oral maintenance therapy. The first clinical event (syncope) occurred approximately 36 hours after the ablation, and the first TdP confirmed by Holter monitoring occurred approximately 51 hours after the ablation. Electrocardiograms (ECG) revealed a prolonged QT interval. QTc interval was 446 ms (baseline) → 490 ms (immediately post-albation, pre-amiodarone) → 528 ms (near TdP onset). Pacemaker interrogation documented the arrhythmia episodes. Complete clinical recovery was attained following the cessation of amiodarone administration and intravenous replenishment of potassium and magnesium.

Conclusion Measurable QTc lengthening occurred shortly after ablation before amiodarone was started. This case underscores the critical need for close surveillance of the QTc interval

when amiodarone is administered during the early post-ablation period.

Keywords Amiodarone; Catheter ablation; QT interval; Torsades de pointes; Ventricular tachycardia

---

Background

Amiodarone is a well-established class III antiarrhythmic drug with additional electrophysiological properties corresponding to classes I, II, and IV antiarrhythmics. It is indicated for both supraventricular and ventricular arrhythmias, especially among patients with structural heart disease, but it can exert adverse effects across multiple organ systems, including the heart, thyroid, lung, liver, and eyes [1]. Its toxicities are largely dose- and cumulative-dose-dependent, with an overall adverse-event incidence ranging from 30% to 90% across cohorts. Approximately 15% of long-term users develop adverse reactions within the first year of therapy, and this proportion rises to 50% with prolonged exposure. Major non-cardiac adverse manifestations encompass thyroid dysfunction, hepatic injury, and pulmonary toxicity [1-4]. Cardiac electrophysiological complications include sinus bradycardia, atrioventricular conduction block, QT interval prolongation, and, infrequently, TdP [5-7].

Among class III antiarrhythmic agents, amiodarone is considered to confer a relatively low proarrhythmic risk [6,7]. In a pooled analysis of 17 studies enrolling 2,878 patients receiving oral long-term amiodarone (≥6 months), Hohnloser et al. reported an overall proarrhythmia incidence of 2%; one-third of these proarrhythmic events were TdP, yielding a pooled TdP incidence of 0.7%, with an estimated overall risk of amiodarone-associated TdP below 1% [7]. It should be emphasized that this estimate was derived from non-randomized, uncontrolled studies; placebo-controlled trials have documented no amiodarone-related proarrhythmic events, implying that the true risk may be even lower. Retrospective real-world cohorts have reported intravenous-amiodarone-related TdP incidences of 0.54% and approximately 1.5% in Thai and Indian patient populations, respectively [8,9]. TdP is a polymorphic ventricular tachycardia mediated by QT prolongation, which may progress to syncope, ventricular fibrillation, and sudden cardiac death [10]. Acute management consists of immediate withdrawal of QT-prolonging medications, correction of hypokalemia and hypomagnesemia, direct-current defibrillation for hemodynamic collapse, and acceleration of heart rate using temporary pacing or isoproterenol to suppress pause-dependent arrhythmia triggers [10,11]. Despite its low absolute incidence, the high mortality potential of amiodarone-induced TdP highlights the clinical importance of timely recognition and prompt intervention. Herein, we present a 76-year-old woman with no prior documented QT prolongation who developed QT prolongation and subsequent TdP after radiofrequency ablation for atrial flutter and atrial fibrillation, for whom amiodarone was prescribed for post-procedural arrhythmia prophylaxis.

In accordance with the 2009 AHA/ACCF/HRS recommendations for the standardization and interpretation of the electrocardiogram (Part IV: The ST segment, T and U waves, and the QT interval) [12] and the ICH E14 guideline on the clinical evaluation of QT/QTc interval prolongation and proarrhythmic potential for non-antiarrhythmic drugs [13], heart rate–corrected QTc values in this study were calculated using the Fridericia formula: QTc = QT / (RR)^(1/3). This correction method has substantially lower systematic error across both tachycardic and bradycardic ranges and has become a preferred standard in contemporary clinical practice, particularly in general cardiology, cardio-oncology, and regulatory drug safety assessment. When QRS prolongation is present, as in bundle branch block or ventricular pacing, the measured QT interval is artificially prolonged by delayed ventricular conduction rather than by true repolarization delay. In such cases, the JT interval (JT = QT − QRS) provides a more direct and physiologically accurate estimate of ventricular repolarization duration. The clinically accepted thresholds for prolonged corrected JT (JTc= JT / (RR)^(1/3)) are approximately 330–340 ms in males and 340–350 ms in females, although normative validation for JTc remains less robust than that for conventionally corrected QTc. Given this patient's concurrent clinical features—including atrial flutter, complete right bundle branch block (RBBB), ventricular pacing, marked ventricular rate variability, and intrinsic QRS prolongation—the Fridericia formula was selected as the primary correction strategy for deriving QTc. JT and corresponding JTc values were calculated in parallel to provide a more comprehensive and unbiased assessment of the underlying ventricular repolarization status. The aforementioned ECG parameters were provided by an intelligent ECG system and have been individually confirmed through manual measurement. The primary QTc threshold for prolongation was based on the 2009 AHA/ACCF/HRS guidelines (men > 450 ms, women > 460 ms). We also referenced the 2025 Chinese expert consensus, which recommends slightly higher thresholds for the Chinese population (post-pubertal men ≥ 470 ms, women ≥ 480 ms) [14].

Case Presentation

A 76-year-old woman was admitted on August 19, 2026, with a 9-year history of intermittent chest tightness and palpitations, which had recurred symptomatically in the week prior to admission. She had undergone double-chamber pacemaker implantation in 2017 for sick-sinus syndrome and had continued to experience episodic chest discomfort and palpitations afterwards. ECG obtained on August 13 and August 19 demonstrated atrial flutter complicated by complete RBBB. On admission, metoprolol succinate 47.5 mg once daily was initiated; this beta-blocker was discontinued on August 25. Her comorbidities included hypertension and type 2 diabetes mellitus, both chronically managed with oral pharmacotherapy with satisfactory blood-pressure and glycemic control. She had no personal or family history of QT prolongation.

Baseline laboratory workup including liver and renal biochemistry, serum electrolytes(K 4.5mmol/L, Mg 0.92mmol/L), thyroid-function tests, and NT-proBNP fell within reference ranges. Transthoracic echocardiography yielded a left-ventricular ejection fraction (LVEF) of 51%. On

August 20, the ECG showed a ventricular paced rhythm as the device had mode-switched to VVI due to atrial flutter (HR 67 beats/min, QT 430 ms, QTc 446 ms, JTc 291 ms). Pacemaker interrogation revealed a baseline DDD programming with automatic mode switch (AMS) enabled, with an estimated remaining battery longevity of 2.5 years, lower rate 60 ppm (nocturnal sleep-mode lower rate 50 ppm, active 22:00–04:00), upper tracking rate 130 ppm, atrial pacing percentage 75.4%, and ventricular pacing percentage 4.9%. Since the preceding device interrogation (December 12, 2023), 1,786 atrial high-rate episodes had been logged, commencing December 23, 2023; one episode reached an atrial rate exceeding 400 beats/min. A 24-hour Holter monitor performed on August 20 revealed atrial flutter with a ventricular paced rhythm. The mean heart rate was 62 beats/min, atrial pacing was 0.1%, and ventricular pacing was 69.2%. Coronary angiography performed on August 24, 2026, demonstrated 40% luminal stenosis in the proximal left anterior descending coronary artery (LAD) and mid-segment of right coronary artery(RCA), with no flow-limiting stenosis in the remaining coronary vasculature.

Electrophysiological study and radiofrequency catheter ablation were completed on August 25 under local infiltration anesthesia. Electroanatomic mapping identified the index atrial flutter as a dual-loop reentrant circuit encircling the mitral annulus, with an anterior-wall low-voltage zone, sharing a common conduction isthmus located at the mitral-annular margin inferior to the left atrial anterior wall. The ablation procedure targeting this anatomical critical isthmus led to the successful restoration of sinus rhythm. Considering the pacemaker-documented quantitative burden of atrial high-rate episodes that confirmed the clinical suspicion of paroxysmal atrial fibrillation, bilateral circumferential pulmonary vein antral isolation was consequently performed as the targeted interventional step. Atrial burst pacing reproduced five distinct tachyarrhythmias: perimitral-anterior-wall reentrant atrial flutter, left-atrial-appendage-mediated reentrant atrial flutter, right-pulmonary-vein-related reentrant atrial flutter, tricuspid-isthmus-dependent atrial flutter, and focal atrial tachycardia originating near the base of the left atrial appendage. All induced tachycardias were terminated by targeted ablation. The post-procedural 12-lead ECG (August 25) showed sinus rhythm with intermittent ventricular pacing, frequent atrial premature contractions (PACs), short runs of atrial tachycardia, ventricular premature contractions, and complete RBBB (HR 75 beats/min, QT 455 ms, QTc 490 ms, JTc 335 ms). Intravenous amiodarone 300 mg was infused at a rate of 1 mg/min, starting at 21:00 on the same day (approximately 1 hour after the ablation). An additional 300 mg intravenous amiodarone infusion (at 1 mg/min) was administered on August 26, in combination with oral amiodarone 0.2 g three times daily.

At 07:47 on August 27, while resting supine in bed, the patient experienced an abrupt transient loss of consciousness lasting approximately 5 seconds. Bedside cardiac telemetry showed sinus rhythm with paced rhythm, frequent ventricular premature complexes, and short bursts of non-sustained ventricular tachycardia. Oral metoprolol succinate 47.5 mg once daily was re-initiated, and intravenous electrolyte repletion was given (potassium chloride 0.6 g, magnesium sulfate 1 g). Urgent non-contrast head computed tomography excluded acute cerebrovascular

events, and a 24-hour Holter recording was obtained. Holter monitoring documented sinus bradycardia and a paced rhythm (atrial pacing 89.5%, ventricular pacing 0.1%) along with ectopic activity, with a mean heart rate of 57 beats/min. The recorded arrhythmias included R-on-T ventricular premature beats, polymorphic ventricular tachycardia, and definite TdP associated with marked QT prolongation; one episode of TdP occurred at 23:09 on August 27 (Figure 1A). A 12-lead ECG (August 28) demonstrated an atrial-paced rhythm and prolonged QT interval (HR 60 beats/min, QT 528 ms, QTc 528 ms, JTc 392 ms) (Figure 1B). The administration of amiodarone was permanently ceased without delay, and intravenous replenishment of potassium and magnesium was sustained. The patient experienced no further syncope or palpitations. Sequential ECG tracings revealed a progressive reduction in the QT interval, although QT prolongation persisted .The slow recovery of repolarization is expected due to the long half-life of amiodarone. Figure 1C illustrates the time course of the QT, QTc, and JTc intervals.

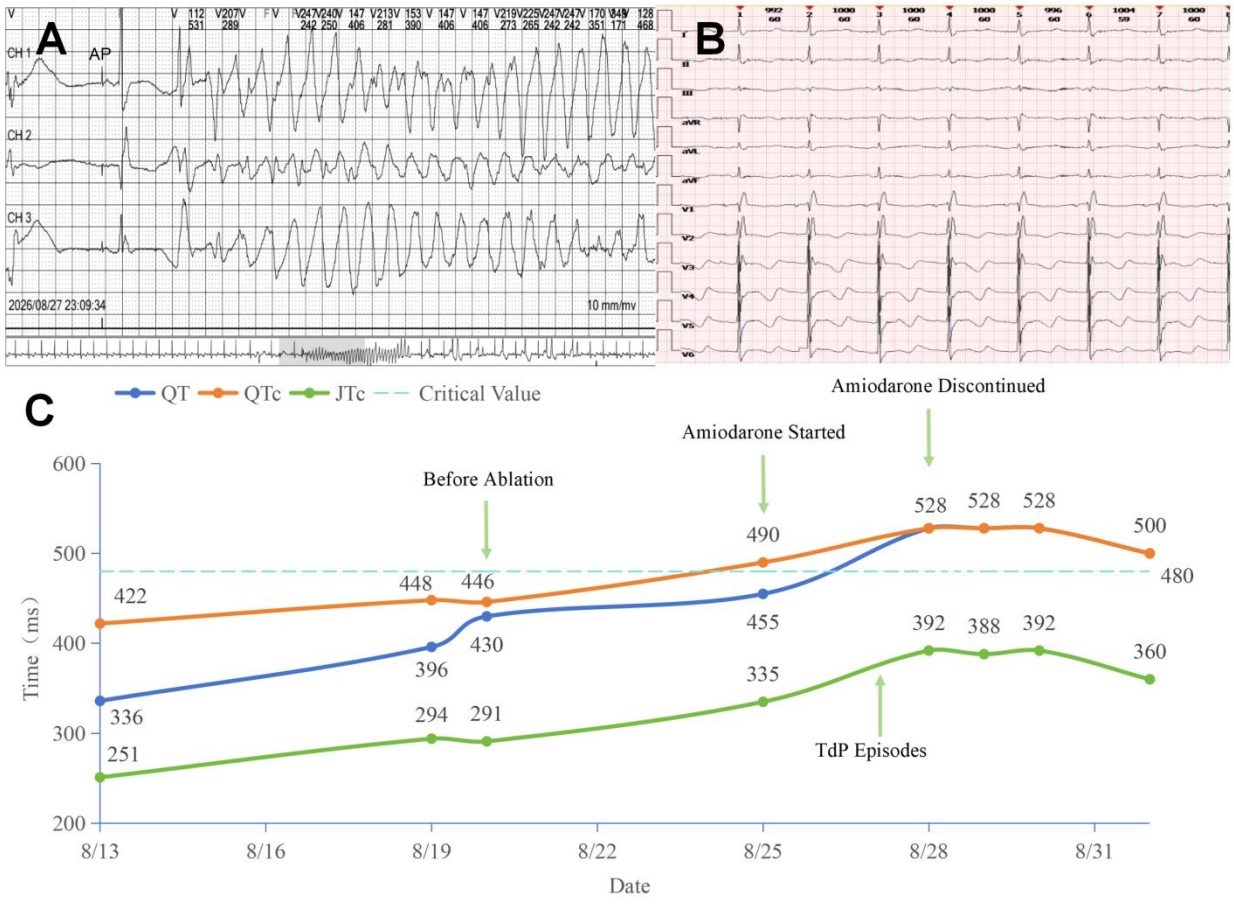

Figure 1 Electrocardiographic recordings and serial QT/QTc/JT dynamics in a case of amiodarone-associated torsades de pointes.

A. Holter recording (August 27-28): R-on-T ventricular premature complex triggering torsades de pointes under atrial-paced rhythm.

B. 12-lead ECG (August 28): atrial-paced rhythm with marked QTc prolongation (528ms).

C. Hospital-course serial QT/QTc/JTc-interval trends (Fridericia formula: QTc = QT / (RR)^(1/3)). QTc increased from 446 ms at baseline to 490 ms immediately post-ablation (pre-amiodarone) and further to 528 ms near TdP onset. The QTc threshold for prolongation in Chinese post-pubertal women (≥ 480 ms) is established based on the 2025 Chinese expert consensus.

Details of all the ECGs are in Table 1. Pacemaker interrogation performed on September 1 identified 415 ventricular high-rate episodes accumulated across 12 days(54 atrial high-rate episodes prior to August 25; no such episodes were observed after radiofrequency ablation), including one ventricular-tachycardia episode recorded at 04:05 on August 27 (mean ventricular rate 180 beats/min, duration 20 seconds). The longest episode of ventricular tachycardia, which occurred at 07:47 on August 27, lasted 29 seconds with an average ventricular rate of 197 beats per minute, temporally corresponding to the clinical loss of consciousness. Two brief 6-second runs of ventricular tachycardia were documented on August 29; no further ventricular arrhythmias occurred subsequently. The patient was discharged on September 4. At the outpatient follow-up one month after discharge, the patient reported feeling well and remained asymptomatic.

Table 1 Details of all the 12-lead ECGs.

Date/Time	HR (bpm)	QRS (ms)	QT (ms)	QTc (ms)	JT (ms)	JTc (ms)	Clinical Diagnosis / Notes
08-13 (16:08)	119	136	336	422	200	251	Atrial flutter/tachycardia (2:1 conduction), complete RBBB; left ventricular high voltage with ST-T wave abnormalities.
08-19 (10:15)	87	136	396	448	260	294	Atrial flutter (variable AV conduction), complete RBBB; left ventricular high voltage with ST-T abnormalities.
08-20 (13:36)	67	150	430	446	280	291	Atrial flutter and paced rhythm, complete RBBB; left ventricular high voltage with ST-T abnormalities, device mode-switched to VVI pacing, normal pacemaker function.
08-25 (20:37)	75	144	455	490	311	335	Sinus and paced rhythm, frequent PACs, short runs of atrial tachycardia, ventricular premature contractions, complete RBBB; left ventricular high voltage with ST-T abnormalities, QT prolongation, device programmed to DDD mode (exhibiting AAI and VAT behaviors due to restored/intermittent AV conduction). normal pacemaker
08-28 （10:30)	60	136	528	528	392	392	Atrial pacing rhythm (device operating in AAI mode), complete RBBB; Left ventricular hypertrophy with ST-T-U abnormalities, significant QT/JT prolongation, normal pacemaker function.
08-29 (05:58)	60	140	528	528	388	388	Atrial pacing rhythm (device operating in AAI mode), complete RBBB; left ventricular high voltage with ST-T-U abnormalities, significant QT/JT prolongation,normal pacemaker function.
08-30 (06:06)	60	136	528	528	392	392	Atrial pacing rhythm (device operating in AAI mode), complete RBBB; left ventricular high voltage with ST-T-U abnormalities, significant QT /JT prolongation, normal pacemaker function.
09-01 (05:39)	60	140	500	500	360	360	Atrial pacing rhythm (device operating in AAI mode), complete RBBB; left ventricular high voltage with ST-T-U abnormalities, QT /JT prolongation. QT/JT intervals decreased compared with previous days.

QTc = QT / (RR)^(1/3),JT = QT − QRS;Abbreviations: RBBB: right bundle branch block; PAC: premature atrial contractions; VVI: ventricular pacing,ventricular sensing, and an Inhibited response to sensed events; AAI: atrial pacing, atrial sensing, and an Inhibited response to sensed atrial events; VAT: ventricular pacing, atrial sensing, and a Triggered response.

Discussion and Conclusions

We searched MEDLINE/PubMed on 25 September 2026 with no date or language limit, combining terms for torsades de pointes and related repolarisation abnormalities with terms for catheter ablation. The full strategy returned 455 records, of which 144 were indexed as case reports and none as meeting abstracts. After screening of titles and abstracts, 21 publications were assessed in full. Fourteen publications were excluded after full-text assessment, and seven articles reporting eight patients were included in the comparison presented in Table 2.

Table 2 Reported cases of torsades de pointes during or after catheter ablation for atrial arrhythmias, including the present case.

Reference	Age/Sex	Basic Arrhythmia	Procedure	Suspected Trigger	QTc Change	TdP Onset	Outcome	Pacing Device	Key Features & Novelty
Mantziari et al[15]. 2011	66 y / F	Long-lasting, drug-refractory fast atrial flutter; ischemic and valvular heart disease with systolic dysfunction	Radiofrequency ablation of the cavotricuspid isthmus	Bradycardia-dependent (relative sinus bradycardia); no antiarrhythmic drug	QTc 480 ms; single measurement only; formula not specified	2 days (48 h) after ablation	TdP-induced cardiac arrest; successful resuscitation; further TdP episodes treated with temporary pacing; ICD implanted	Temporary pacemaker + subsequent ICD	Structural heart disease with baseline repolarisation prolongation; relative bradycardia after rate control as the trigger; no culprit drug (pure substrate-driven); absence of serial QTc data
Park et al[16]. 2017	79 y / F	Paroxysmal atrial fibrillation; ischemic heart disease; LVEF 74%	Pulmonary vein isolation (PVI) + ganglionated plexus (GP) ablation	Flecainide 50 mg bid (started >3 months before the procedure; resumed 3 days after ablation)	Baseline 495 ms; 592 ms on day 3 after ablation; no serial QTc data; formula not specified	10 days after ablation	TdP resolved with isoproterenol infusion; no recurrence; no device implanted	None	Neural modulation by ablation proposed as the main mechanism; culprit drug present but not newly started after the procedure; no serial QTc data
Chikata et al[17]. 2021	60 y / F	Long-standing persistent atrial fibrillation; no structural heart disease; no inherited arrhythmia	Bilateral circumferential pulmonary vein isolation (radiofrequency, deep sedation)	No antiarrhythmic drug (none before or after); bisoprolol withdrawn 2 days before the procedure; dexmedetomidine sedation	QT 427 / QTc 449 ms before; QT 540 / QTc 549 ms on day 2; QT 362 / QTc 440 ms on day 3 after atrial fibrillation recurred (Fridericia)	17 hours after ablation	Self-terminating TdP; persisted after correction of mild hypomagnesaemia (1.6 mg/dL); disappeared when atrial fibrillation recurred	None	Pure autonomic mechanism: PVI transecting the major atrial ganglionated plexi; the only complete case of TdP after PVI without any antiarrhythmic drug; peri-procedural beta-blocker withdrawal (parallel to the present case); Fridericia correction; TdP disappeared with recurrence of atrial fibrillation
Nakagawa et al[18]. 2022	85 y / M	Persistent atrial flutter with congestive heart failure (suspected tachycardia-induced cardiomyopathy)	Radiofrequency ablation of the cavotricuspid isthmus	Takotsubo cardiomyopathy triggered by severe procedural pain and anxiety; no antiarrhythmic drug (landiolol used for rate control)	QTc 555 ms (Bazett) / 512 ms (Fridericia) at the time of TdP; peak QTc 658 ms (Bazett) / 611 ms (Fridericia) 2 days after ablation; QTc still not normalised more than 1 month later	The day after ablation (heart failure re-exacerbated approximately 2 h after the procedure)	TdP degenerated into ventricular fibrillation; cardioversion at 100 J restored sinus rhythm; magnesium sulphate and potassium chloride administered; no further TdP	None	Pain/anxiety-triggered takotsubo cardiomyopathy as the sole mechanism; reports QTc by both Bazett and Fridericia, allowing direct comparison; giant negative T wave; one of the two male patients among the reported cases; QTc remained abnormal beyond one month
Font et al[19]. 2023, case 1	68 y / F	Persistent atrial fibrillation	Atrial fibrillation catheter ablation	Dofetilide (long-term, >= 8 months; not newly started periprocedurally); fever 38.6 C with suspected pneumonia treated with piperacillin-tazobactam; K+ 3.7, Mg2+ 1.4 mEq/L	429-491 ms during loading and follow-up; 437 ms on admission and 426 ms at discharge; 426 ms on the day of presentation (HR 86) rising to 577 ms the next day (HR 55, Bazett)	2-3 days after ablation	Dofetilide withdrawn together with intravenous magnesium and potassium; no further ventricular arrhythmia; QTc normalised	None	Chronic class III drug on a background of multiple periprocedural triggers (fever/infection, electrolyte shifts, bradycardia); QTc normal on the day of admission but markedly prolonged the next day, supporting a periprocedural vulnerable window; electrolyte values at the time of TdP reported
Font et al[19]. 2023, case 2	68 y / F	Paroxysmal atrial fibrillation	Atrial fibrillation catheter ablation under general anaesthesia	Sotalol (long-term, > 6 years); bradycardia after induction of anaesthesia	399-473 ms during follow-up; 467 ms on presentation (HR 54) rising to 640 ms after induction of anaesthesia (HR 34); formula not specified	Intraprocedural (immediately after induction of anaesthesia)	Successful defibrillation at 200 J; one further self-terminating polymorphic VT; sotalol withdrawn; no recurrence over 2 days; ablation completed	Temporary coronary sinus pacing (to prevent bradycardia)	Bradycardia after general anaesthesia (54 -> 34 bpm) directly triggered TdP; heart-rate-dependent mechanism; a preventable periprocedural window
Yamashita et al[20]. 2024	75 y / F	Persistent atrial fibrillation with tachycardia-induced cardiomyopathy (LVEF 40% on admission)	PVI + left atrial posterior wall isolation + superior vena cava isolation (day 5 of admission)	Bepridil 100 mg/day (started 1 month before admission; plasma level 146 ng/mL, below the reference range 250-800); hypokalaemia K+ 2.7 mmol/L	QTc 450 ms at referral (HR 104); 470 ms immediately after ablation (HR 68); 750 ms on day 7 with giant negative T waves and T-wave alternans; 400 ms 6 weeks after discharge; formula not specified	Day 6 of admission (about 24 h after ablation); recurrent on day 7	Bepridil withdrawn with magnesium sulphate, isoproterenol and temporary pacing at 80 bpm; QT prolongation, giant negative T waves and left ventricular function improved without further treatment; discharged on day 21	Temporary pacemaker (80 bpm)	Class III drug level below the reference range plus hypokalaemia on a background of tachycardia-induced cardiomyopathy; TdP on the first day after ablation; giant negative T waves and T-wave alternans; LQTS genetic testing negative; complete reversal within 6 weeks
Iimura et al[21]. 2026	62 y / M	Atrial fibrillation (redo procedure); LVEF 62%; no structural abnormality	Redo pulsed-field ablation (PFA) including pulmonary vein, posterior wall and superior vena cava isolation	Delayed-onset takotsubo cardiomyopathy attributed to autonomic/neurohumoral mechanisms after an extensive lesion set; bradycardia with high-grade atrioventricular block; no QT-prolonging drug	QT prolongation with high-grade atrioventricular block documented 3 h after the procedure (shown in figures; no numerical QTc reported in the text)	3 hours after the procedure	TdP progressed to refractory ventricular fibrillation with cardiac arrest; return of spontaneous circulation after approximately 25 min of resuscitation; Impella CP mechanical circulatory support; device weaned on day 5; extubated on day 10 with full neurological recovery	None (mechanical circulatory support with Impella CP)	First reported case of TdP after pulsed-field ablation; earliest onset (3 h) among reported cases; bradycardia with high-grade atrioventricular block preceding TdP, closely paralleling the present case; supports the concept of delayed catastrophic events after PFA
Present case	76 y / F	Paroxysmal atrial fibrillation + typical atrial flutter + sick sinus syndrome (SNRTmax 4665 ms) + complete right bundle branch block; no structural heart disease; LVEF 51%	Left atrial anterior wall, left atrial appendage ostium, cavotricuspid isthmus + pulmonary vein isolation	Intravenous amiodarone started 1 h after the procedure + metoprolol withdrawal	446 ms (baseline) -> 490 ms (after PVI, before amiodarone) -> 528 ms (near TdP onset), Fridericia;	About 36 hours after ablation	Multiple TdP episodes; resolved after discontinuation of amiodarone, correction of electrolytes and device reprogramming; no recurrence	Dual-chamber pacemaker (DDD) recording 415 ventricular high-rate episodes	The only case in which intravenous amiodarone was started in the immediate post-procedural period; pacemaker-recorded burden of 415 ventricular high-rate episodes, not quantified in any previous report; device reprogramming as a therapeutic intervention; severe sinus node dysfunction constituting a pause-dependent substrate

TdP, torsades de pointes; PVI, pulmonary vein isolation; CTI, cavotricuspid isthmus; PFA, pulsed-field ablation; GP, ganglionated plexus; AV, atrioventricular; ICD, implantable cardioverter-defibrillator; LVEF, left ventricular ejection fraction; SNRT, sinus node recovery time. Only reports published as full-length, peer-reviewed articles and explicitly diagnosing torsades de pointes were eligible; conference abstracts and other non-peer-reviewed material were excluded. Reports describing only polymorphic ventricular tachycardia without an explicit diagnosis of torsades de pointes were excluded, as were reports in which catheter ablation was performed for an arrhythmia other than an atrial arrhythmia, and reports of atrioventricular junction or His bundle ablation performed for rate control of atrial fibrillation. Each case within a multi-case report is counted separately. QTc values are reproduced as reported in the original publications with the stated correction formula; values are not directly comparable between rows when the formula was not specified. The present case, Chikata et al. and Nakagawa et al. used Fridericia correction.

Consistent with prior reports, TdP in our case arose from a multifactorial perioperative context rather than a single drug or procedural insult. However, three features distinguish the present case from the eight previously reported atrial ablation-associated TdP cases across seven published articles. First, the dominant precipitant was intravenous amiodarone initiated within 1 hour of ablation, rather than chronic oral antiarrhythmic therapy or severe procedural complication. Four prior cases involved QT-prolonging agents (flecainide, dofetilide, sotalol, bepridil) that had been prescribed long-term before ablation, while two cases were driven by stress-induced takotsubo cardiomyopathy without QT-prolonging drug exposure, and two were attributed to isolated bradycardia or beta-blocker withdrawal. To our knowledge, no prior report has described immediate post-ablation initiation of intravenous amiodarone as the trigger for TdP in the absence of hypokalaemia, fever, anaesthetic bradycardia, or direct ganglionic plexus injury. Second, TdP occurred in a patient with a pre-existing dual-chamber pacemaker programmed to a default lower rate of 60 bpm, rather than in an unpaced patient or a patient paced after intentional atrioventricular junction ablation. No prior atrial-level ablation case reported pre-existing permanent pacing; temporary pacing was used only for acute high-grade block in one case, and all others were managed with magnesium, rate-augmenting drugs, or cardioversion. Device intracardiac electrograms in our patient quantified 415 nonsustained ventricular high-rate episodes—far more than the clinically apparent events captured by bedside monitoring—all of which could been resolved completely after reprogramming the lower rate to 80 bpm and optimising AV intervals, without need for isoprenaline, long-term pacing upgrade, or ICD implantation. Third, TdP was triggered by the combination of three routine perioperative decisions, rather than a single severe adverse event: baseline conduction system disease (sinus node dysfunction with complete right bundle branch block) reducing repolarisation reserve, temporary beta-blocker withdrawal increasing autonomic fluctuation (extending the observation of Chikata et al. [17] to patients exposed to concurrent amiodarone), and acute IKr blockade from intravenous amiodarone. While Iimura et al. [21] reported TdP as early as 3 hours after pulsed field ablation in the setting of takotsubo and high-grade block, and Nakagawa et al. [18] described pain-induced takotsubo after flutter ablation, our case demonstrates that TdP can occur in the absence of structural stress injury or conduction block, purely from the combined effect of common, modifiable perioperative factors.These observations carry three practical implications: (1) intravenous amiodarone should not be assumed to be low risk in the immediate post-ablation period, even in patients without structural heart disease; (2) pre-existing permanent pacemakers do not universally protect against bradycardia-dependent TdP during amiodarone therapy, and temporary elevation of the lower rate to 70–80 bpm may be considered; (3) abrupt beta-blocker withdrawal in patients scheduled to receive perioperative amiodarone may increase repolarization instability, and continuation or early reinstatement should be considered where hemodynamically tolerated. All QTc intervals in this report were corrected using the Fridericia formula to enable direct comparison with prior cases.

Well-established clinical risk factors for TdP include female sex, congenital long-QT syndrome, significant structural heart disease, marked bradycardia (<50 beats/min), endocrine and nutritional derangements, electrolyte imbalance, and impaired hepatic or renal drug clearance [11]. In the present case, the patient was an elderly female. Significant ischemia and heart failure were excluded; A programmed base pacing rate of 60 ppm precluded severe spontaneous bradycardia; admission-level serum electrolytes and hepatic-renal function remained normal. The baseline QTc was normal. Underlying sick-sinus syndrome may have contributed to myocardial electrophysiological remodeling, and long-standing type 2 diabetes may have been associated with cardiac autonomic dysfunction, conferring intrinsic individual arrhythmia susceptibility. Noticeable QTc prolongation was already evident on the immediate post-ablation ECG, and clinical syncope occurred approximately 35 hours after the initiation of amiodarone, indicating that amiodarone further augmented QT prolongation and precipitated ventricular arrhythmia. If feasible, genetic testing for long-QT-syndrome-related variants could help rule out inherited channelopathy and strengthen the causal link between QTc prolongation and amiodarone exposure. Of particular clinical relevance, measurable QTc lengthening occurred shortly after ablation before amiodarone was started. This observation suggests that the early post-ablation period itself constitutes a vulnerable arrhythmic window, during which amiodarone use warrants heightened caution.

Radiofrequency ablation may perturb ventricular repolarization through several mechanisms and create a transient proarrhythmic state in the immediate post-procedural phase. First, when ablation lesions involve the mitral annulus and anterior-wall low-voltage zone, they may lie anatomically close to left-ventricular lateral-wall activation pathways. Thermal injury in this region can alter local ventricular activation sequences, increasing spatial dispersion of repolarization, creating a substrate for reentry, and increasing the propensity for early after-depolarization (EAD)-mediated triggered activity. Second, atrial ablation may induce acute autonomic modulation. Thermal injury to intrinsic cardiac ganglionated plexuses clustered around the pulmonary-vein ostia and the posterior left atrium has been associated with QTc prolongation and secondary ventricular arrhythmias. Park et al. reported a case of profound QTc prolongation followed by TdP after paroxysmal atrial-fibrillation ablation and attributed the QTc lengthening predominantly to ablation-mediated neural modulation [16]. Third, acute regional myocardial inflammation and tissue edema in the early post-ablation phase may transiently alter repolarization properties, potentially through changes in autonomic tone, atrioventricular conduction, or ventricular activation. Large-cohort investigations have shown significant QTc prolongation during the acute period after pulmonary-vein isolation, with values returning to baseline within one month post-procedure [22]; these observations are consistent with a transient ablation-related effect. Serial Holter recordings have shown progressive QT/QTc prolongation, suggesting that acute changes in heart rate and ventricular activation may destabilize repolarization and predispose to ventricular ectopy and TdP [23]. Mantziari et al.

reported TdP-mediated cardiac arrest 48 hours after successful atrial-flutter ablation, associated with relative sinus bradycardia and acquired QT prolongation [15].

In our patient, the QTc interval increased from 446 ms before ablation to 490 ms immediately after ablation, prior to amiodarone administration, indicating that the ablation procedure itself significantly altered ventricular repolarization. Amiodarone, initiated on the day of ablation, produced further QTc prolongation; this cumulative effect precipitated TdP. This case suggests that early post-ablation amiodarone administration carries non-negligible proarrhythmic potential. A distinctive feature of our report is the presence of a pre-existing dual-chamber (DDD) pacemaker; stored device interrogation data provided objective documentation of ventricular arrhythmia episodes and allowed assessment of the modulatory role of the basal pacing rate in TdP genesis. Collectively, this case indicates that in the early post-ablation setting, particularly in patients with underlying autonomic dysfunction, combined intravenous-to-oral amiodarone should be used with caution.

In this patient, the pacemaker lower rate limit was programmed to 60 ppm. Although this setting prevented marked bradycardia, it may have contributed to the long cycle length within "long-short-long" sequences that predispose to TdP. Given the high atrial pacing burden (75.4%), temporarily increasing the lower pacing rate to 70-80 ppm may become a reasonable therapeutic consideration. A higher pacing rate would shorten RR intervals, thereby limiting the window for EAD formation and suppressing ventricular premature beats; such an approach could theoretically address both the arrhythmic substrate and the triggering ectopy of TdP. However, this strategy of increasing the pacing rate is primarily based on mechanistic reasoning and requires further validation in similar patient populations.

This case report has inherent limitations. First, genetic screening for long-QT-syndrome-associated variants was not performed; therefor occult congenital long-QT syndrome cannot be definitively excluded. Second, metoprolol succinate had been discontinued only two days preceding TdP onset, so sympathetic-tone rebound after beta-blocker withdrawal might have exerted a contributing proarrhythmic influence. Third, this represents a single-center, single-patient observational report; the proposed pacing-rate-modification strategy is hypothesis-generating rather than evidence-established and requires corroboration in larger clinical series.

Amiodarone remains a highly effective and widely used antiarrhythmic agent, yet it carries the potential for multi-organ toxicity. Its clinical use requires regular monitoring of serum electrolytes, hepatic and renal function, and thyroid function. Because amiodarone can prolong the QTc interval, serial electrocardiographic assessment of the QTc interval is recommended, especially in the early period of ablation. When substantial QTc prolongation occurs, clinicians should remain vigilant for TdP. Once TdP is recognized, amiodarone should be discontinued

promptly, and intravenous potassium and magnesium repletion should be initiated. Immediate electrical cardioversion is indicated in hemodynamically unstable patients. In bradycardia-dependent TdP, temporary rapid ventricular pacing or intravenous isoproterenol may be used to increase the heart rate and suppress the arrhythmia.

Abbreviations

TdP: torsades de pointes
ECG: electrocardiogram
QTc: corrected QT interval
RBBB: right bundle branch block
LVEF: left-ventricular ejection fraction
LAD: left anterior descending coronary artery
RCA: right coronary artery
PAC: premature atrial contraction
EAD: early after-depolarization
PVI: pulmonary vein isolation
ICD: implantable cardioverter-defibrillator
VVI: Ventricular pacing, Ventricular sensing, and an Inhibited response to sensed events
DDD: Dual-chamber pacing, Dual-chamber sensing, and Dual response (triggered and inhibited) to sensing
AAI: atrial pacing, atrial sensing, and an Inhibited response to sensed atrial events
VAT: Ventricular pacing, atrial sensing, and a Triggered response

Declarations

Ethics approval and consent to participate

Ethical approval for this case report was waived by the Medical Ethics Committee of Wujin Hospital Affiliated with Jiangsu University (Changzhou, Jiangsu, China), in accordance with its policy that single-patient case reports not involving a research intervention do not require full board review. Written informed consent to participate was obtained from the patient. The study was conducted in accordance with the Declaration of Helsinki.

Consent for publication

Written informed consent was obtained from the patient for publication of this case report and accompanying images.

Availability of data and materials

The data supporting the findings of this study are available from the corresponding author upon reasonable request.

Competing interests

The authors declare no conflicts of interest.

Funding

There was no financial support for this case report.

Authors' contributions

Liuyan Zhang contributed to writing of the manuscript. Jianqiang Xiao contributed to literature search. Jun Gu contributed to imaging. Gaojun Cai contributed to revising and editing the manuscript. All authors read and approved the final manuscript.

Acknowledgements

Not applicable.

Cliniacl trial number

Not applicable.

References

1. Colunga Biancatelli RM, Congedo V, Calvosa L, Ciacciarelli M, Polidoro A, Iuliano L. Adverse reactions of amiodarone. J Geriatr Cardiol. 2019;16(7):552-566.

2. Medić F, Bakula M, Alfirević M, Bakula M, Mucić K, Marić N. Amiodarone and thyroid dysfunction. Acta Clin Croat. 2022;61(2):327-341.

3. Eusébio S, Soares AR, Fiúza P, Garcia T. Amiodarone-induced interstitial pneumonia: a cause of respiratory failure. Cureus. 2024;16(11):e74253.

4. Rankin S, Elder DH, Ogston S, George J, Lang CC, Choy AM. Population-level incidence and monitoring of adverse drug reactions with long-term amiodarone therapy. Cardiovasc Ther. 2017;35(3).

5. Goldschlager N, Epstein AE, Naccarelli G, Olshansky B, Singh B. Practical guidelines for clinicians who treat patients with amiodarone. Arch Intern Med. 2000;160(12):1741-1748. doi: 10.1001/archinte.160.12.1741. PMID: 10871966.

6. Hohnloser SH. Proarrhythmia with class III antiarrhythmic drugs: types, risks, and management. Am J Cardiol. 1997;80(8A):82G-89G.

7. Hohnloser SH, Klingenheben T, Singh BN. Amiodarone-associated proarrhythmic effects: a

review with special reference to torsade de pointes tachycardia. Ann Intern Med. 1994;121(7):529-535.

8. Wongsalap Y, Miliam W, Deesham S, Riewpaiboon M, Phrommintikul A. Incidence and risk factors of QT prolongation and torsades de pointes following intravenous amiodarone administration for atrial fibrillation: a cohort study. Arch Acad Emerg Med. 2025;13(1):e70.

9. Shenthar J, Rachaiah JM, Pillai V, Pandurangi U, Naik N. Incidence of drug-induced torsades de pointes with intravenous amiodarone. Indian Heart J. 2017;69(6):707-713.

10. Viskin S, Chorin E, Viskin D, Hochstadt A, Schwartz AL, Rosso R. Polymorphic ventricular tachycardia: terminology, mechanism, diagnosis, and emergency therapy. Circulation. 2021;144(10):823-839.

11. De Ponti F, Poluzzi E, Cavalli A, Recanatini M, Montanaro N. Safety of non-antiarrhythmic drugs that prolong the QT interval or induce torsade de pointes: an overview. Drug Saf. 2002;25(4):263-286.

12. Rautaharju PM, Surawicz B, Gettes LS, Bailey JJ, Childers R, Deal BJ, et al. AHA/ACCF/HRS recommendations for the standardization and interpretation of the electrocardiogram: part IV: the ST segment, T and U waves, and the QT interval: a scientific statement from the American Heart Association Electrocardiography and Arrhythmias Committee, Council on Clinical Cardiology; the American College of Cardiology Foundation; and the Heart Rhythm Society. Circulation. 2009;119(10):e241-e250.

13. International Conference on Harmonisation of Technical Requirements for Registration of Pharmaceuticals for Human Use. ICH harmonised tripartite guideline: the clinical evaluation of QT/QTc interval prolongation and proarrhythmic potential for non-antiarrhythmic drugs (E14). Geneva, Switzerland: International Conference on Harmonisation; 2005. https://database.ich.org/sites/default/files/E14_Guideline.pdf. Accessed 27 September 2026.

14. Chinese Society of Cardiology, Chinese Medical Association; Editorial Board of Chinese Journal of Cardiology. Expert consensus on the monitoring and risk assessment of QT interval prolongation. Zhonghua Xin Xue Guan Bing Za Zhi. 2025 Dec 24;53(12):1335-1351. Chinese. doi: 10.3760/cma.j.cn112148-20251030-00763. PMID: 41402097.

15. Mantziari AA, Vassilikos VP, Chatzizisis YS, Dakos G, Stavropoulos G, Paraskevaidis S, et al. Cardiac arrest caused by torsades de pointes tachycardia after successful atrial flutter radiofrequency catheter ablation. Open Cardiovasc Med J. 2011;5:1-3.

16. Park YM, Cha MS, Kang WC, Shin MS, Kim YH, Choi IS, et al. Torsades de pointes associated with QT prolongation after catheter ablation of paroxysmal atrial fibrillation. Indian Pacing Electrophysiol J. 2017 Sep-Oct;17(5):146-149. doi: 10.1016/j.ipej.2017.07.008. Epub

2017 Jul 13. PMID: 29192591; PMCID: PMC5652273.

17. Chikata A, Kato T, Usuda K, Fujita S, Otowa KI, Maruyama M, et al. Torsade de Pointes Due to QT Prolongation after Pulmonary Vein Isolation for Persistent Atrial Fibrillation. Intern Med. 2021 Jul 1;60(13):2089-2092. doi: 10.2169/internalmedicine.6627-20. Epub 2021 Feb 1. PMID: 33518578; PMCID: PMC8313932.

18. Nakagawa Y, Furusho H, Kamiya Y, Nishikawa R, Miwa K, Yasuda T. A case of torsades de pointes due to takotsubo cardiomyopathy after common atrial flutter ablation. J Cardiol Cases. 2022;25(5):275-278. doi:10.1016/j.jccase.2021.11.001.

19. Font CM, Tran CT. Class III Antiarrhythmics and Periprocedural Torsades de Pointes. JACC Case Rep. 2023 Sep 1;23:101998. doi: 10.1016/j.jaccas.2023.101998. PMID: 37954945; PMCID: PMC10635876.

20. Yamashita D, Fujimoto N, Kagawa Y, Fujita S, Dohi K. QT Prolongation and Torsade De Pointes After Catheter Ablation for Persistent Atrial Fibrillation in a Patient With Tachycardia-Induced Cardiomyopathy: A Case Report. Cureus. 2024 Jun 4;16(6):e61640. doi: 10.7759/cureus.61640. PMID: 38966463; PMCID: PMC11223721.

21.Iimura K, Yagishita A, Iijima A, Amino M, Ikari Y, Yoshioka K. Delayed-onset life-threatening Takotsubo cardiomyopathy following pulsed-field ablation. JACC Case Rep. 2026;31(31):108758. doi:10.1016/j.jaccas.2026.108758.

22. Nguyen DD, Akoum N, Hourmozdi J, Prutkin JM, Robinson M, Tregoning DM, et al. Catheter ablation of atrial fibrillation results in significant QTc prolongation in the postoperative period. Heart Rhythm O2. 2021;2(5):500-510.

23. Waldmann V, Marijon E, Combes N. Holter-monitored sudden cardiac arrest after atrioventricular junction ablation. Pacing Clin Electrophysiol. 2018 Apr;41(4):422-424. doi: 10.1111/pace.13140. Epub 2017 Jul 12. PMID: 28617967.



Figure 2　Timeline of the present case.