Research Square

Preprints are preliminary reports that have not undergone peer review.
They should not be considered conclusive, used to inform clinical practice,
or referenced by the media as validated information.

Febrile jaundice mistaken for a urological emergency: probable severe malaria with multi-organ dysfunction and sight-threatening retinal haemorrhage in a conscious adult from a malaria-elimination setting — a case report

Iftekhar Ahmed Sakib
sakibiftekharahmed@gmail.com
Shaheed Suhrawardy Medical College and Hospital
Md. Mazaharul Islam
Shaheed Suhrawardy Medical College and Hospital
Tanvir Ahmed
Shaheed Suhrawardy Medical College and Hospital
Md. Adnan Sifat
Shaheed Suhrawardy Medical College and Hospital
Md. Asif Hossain
Shaheed Suhrawardy Medical College and Hospital
Md. Sadman Sakib Eram
Shaheed Suhrawardy Medical College and Hospital
MD. Nebir Akter Sokal
Shaheed Suhrawardy Medical College and Hospital
Ahmad Monjurul Aziz
Shaheed Suhrawardy Medical College and Hospital

Case Report

Keywords: Severe malaria, Diagnostic error, Febrile jaundice, Acute kidney injury, Sub-hyaloid haemorrhage, Nd:YAG hyaloidotomy, Rapid diagnostic test, Emergency department, Case report

Posted Date: November 26th, 2026

DOI: https://doi.org/10.21203/rs.3.rs-11515439/v1

License: This work is licensed under a Creative Commons Attribution 4.0 International License.
Read Full License

Additional Declarations: No competing interests reported.

Abstract

Background

Emergency physicians in malaria-elimination settings increasingly encounter the disease only in travellers and migrant workers, where it is easily mistaken for a surgical or urological emergency. Parasitological confirmation may also fail, leaving clinicians to act on incomplete information.

Case presentation

A previously healthy man in his twenties presented to the emergency department after prolonged residence in a malaria-endemic district of Bangladesh, with eight days of fever followed by jaundice, dark urine, haematuria and epigastric and flank pain. He was admitted under surgery as suspected cholestatic jaundice with ureteric colic; computed tomography was normal, and a low alkaline phosphatase (28 U/L) with a bilirubin of 36.3 mg/dL argued against obstruction. He remained fully conscious throughout. A rapid diagnostic test was positive for *Plasmodium falciparum*, but blood films were negative at two laboratories and a reference-laboratory test ten days later reported *P. vivax* with negative microscopy; polymerase chain reaction was unavailable. He developed acute kidney injury requiring two haemodialysis sessions, severe anaemia (haemoglobin 3.8 g/dL, seven units transfused), thrombocytopenia, acute pancreatitis (lipase 1312 U/L) and a compensated coagulopathy. Intravenous artesunate and broad-spectrum antibacterials were started on the same day, and he recovered. On day 11 he developed blurred vision; fundoscopy showed bilateral Roth spots and a boat-shaped sub-hyaloid haemorrhage over the right macula, with acuity falling to counting fingers. Neodymium-doped yttrium aluminium garnet laser hyaloidotomy restored vision to 6/6 bilaterally.

Conclusions

This is reported as probable, parasitologically unconfirmed malaria: World Health Organization research criteria could not be satisfied, scrub typhus and dengue were never tested, and the simultaneous start of antimalarial and antibacterial therapy makes the treatment response uninterpretable. Three lessons stand independent of the aetiology. Febrile jaundice with flank pain after endemic exposure warrants malaria testing before an operative pathway. A low alkaline phosphatase with marked conjugated hyperbilirubinaemia argues against obstruction. Visual symptoms in any severely anaemic, thrombocytopenic patient warrant urgent fundoscopy, because a treatable pre-macular haemorrhage may be present.

Background

Malaria caused an estimated 282 million cases and 610,000 deaths worldwide in 2024 [1]. Bangladesh has reduced its burden by more than 90% since 2008 and targets elimination by 2030, but transmission

now persists almost entirely in the three Chittagong Hill Tracts districts, which account for roughly nine in ten national cases [2, 3]. This creates a diagnostic trap: physicians outside those districts see malaria rarely, while mobile workers continue to import it into urban emergency departments.

Two problems compound this. First, severe malaria may present with abdominal or flank pain and jaundice, mimicking a surgical or urological emergency [4]. Second, in low-transmission settings parasitological confirmation frequently fails: microscopy detects only 50–100 parasites per microlitre, sequestration may empty the peripheral blood of mature parasites, and histidine-rich protein 2 persists for weeks after an earlier infection [5–7]. The emergency physician must therefore act on probability rather than proof.

We report an adult who presented as a urological emergency, developed multi-organ dysfunction while remaining fully conscious, was persistently smear-negative, and later developed a sight-threatening pre-macular haemorrhage that was reversed by laser hyaloidotomy. We present it deliberately as probable, parasitologically unconfirmed malaria, and use the diagnostic uncertainty itself as the teaching point. Reporting follows the CARE guideline [8].

Case presentation

A previously healthy man in his twenties, weighing approximately 61 kg, presented to the emergency department after prolonged residence in a malaria-endemic district of the Chittagong Hill Tracts. He had eight days of high-grade intermittent fever reaching 39.4°C, then jaundice, dark urine, haematuria, epigastric and left flank pain, and vomiting. He had no relevant comorbidity, no prior transfusion and no family history of haemolytic disorder, and had taken a non-steroidal anti-inflammatory drug for loin pain in preceding months.

He was ill-looking, febrile, deeply icteric and clinically anaemic (blood pressure 110/70 mmHg, pulse 98–110 beats/min, oxygen saturation 90–97% on room air). The abdomen was soft with epigastric tenderness and no organomegaly. He was admitted under surgery as suspected cholestatic jaundice with ureteric colic and started on ceftriaxone. Critically, he remained conscious and fully oriented (Glasgow Coma Scale 15/15) throughout admission. Surgery referred him to medicine the same day, noting the endemic-area residence (Fig. 1, Table 1).

Table 1
Clinical timeline.

Day	Event	Key findings
Pre-admission	High-grade intermittent fever for ~ 8 days in a malaria-endemic district, then jaundice, dark urine, epigastric and flank pain, vomiting, haematuria	Temperature to 39.4°C
1	Emergency admission under Surgery as suspected cholestatic jaundice / ureteric stone; same-day referral and transfer to Medicine	GCS 15/15; BP 110/70 mmHg; Hb 9.1 g/dL; platelets 58 × 10⁹/L; ALT 100.7, AST 220.5 U/L; creatinine 1.42 mg/dL
1	Empirical ceftriaxone commenced	—
2	Non-contrast CT of kidneys, ureters and bladder	Reported as a normal study; no calculus, no obstruction
4	Progressive jaundice and epigastric pain; pancreatitis identified	Bilirubin 35.63 mg/dL (direct 20.24); lipase 1312 U/L; ALP 28 U/L; albumin 2.6 g/dL
5	Malaria rapid diagnostic test and blood film	RDT positive for P. falciparum, negative for P. vivax; blood film NEGATIVE
6	Profound anaemia; intravenous artesunate AND meropenem both commenced	Hb 3.8 g/dL; ESR 115 mm/h; creatinine 3.18 mg/dL; bicarbonate 18 mmol/L
7	Peak hepatic and renal derangement; haemolysis and coagulation work-up	Bilirubin 36.3 mg/dL; creatinine 3.46 mg/dL; LDH 3357 U/L; CRP 198 mg/L; D-dimer 9.96 mg/L; DAT negative; reticulocytes 2.0%
8–9	First haemodialysis; packed cell transfusion; bicarbonate nadir	Urea 128 mg/dL; bicarbonate 16 mmol/L; lipase > 600 U/L; five units transfused
10	Final artesunate dose; G6PD assayed (post-transfusion)	G6PD 9.1 IU/g Hb (male reference > 9.52); creatinine 2.75 mg/dL
11	Oral artemether–lumefantrine commenced; onset of blurred vision	Hb 10.7 g/dL; platelets 270 × 10⁹/L; creatinine 2.09 mg/dL
14–15	Second haemodialysis; hyponatraemia; ophthalmology referral	Sodium 129 mmol/L; platelets 580 × 10⁹/L; LDH 1158 U/L; reticulocytes 1.5%
16	Ophthalmology review; sample to national reference laboratory	Roth spots and boat-shaped retinal haemorrhages, right macula involved; ferritin > 1650 ng/mL; reference RDT

Day 1 denotes the day of admission to the tertiary centre; all timings are relative and no calendar dates are given. ALP alkaline phosphatase, ALT alanine aminotransferase, AST aspartate aminotransferase, CRP C-reactive protein, CT computed tomography, DAT direct antiglobulin test, ESR erythrocyte sedimentation rate, GCS Glasgow Coma Scale, G6PD glucose-6-phosphate dehydrogenase, LDH lactate dehydrogenase, Nd:YAG neodymium-doped yttrium aluminium garnet, OCT optical coherence tomography, RDT rapid diagnostic test.

Day	Event	Key findings
		reported as P. vivax with NEGATIVE microscopy
17–18	OCT macula and colour fundus photography	Visual acuity right 6/60, left 6/12; central subfield thickness 568 µm
20	Nd:YAG laser hyaloidotomy, right eye	Right eye counting fingers at 2 feet pre-procedure; creatinine 1.31 mg/dL; bilirubin 4.2 mg/dL
21	Discharged, systemically recovered	Multi-organ dysfunction resolved
34	Outpatient follow-up	Hb 11.4 g/dL; creatinine 1.29 mg/dL; bilirubin 2.3 mg/dL; ALT 76 U/L
37	Ophthalmic follow-up	Visual acuity 6/6 both eyes

Day 1 denotes the day of admission to the tertiary centre; all timings are relative and no calendar dates are given. ALP alkaline phosphatase, ALT alanine aminotransferase, AST aspartate aminotransferase, CRP C-reactive protein, CT computed tomography, DAT direct antiglobulin test, ESR erythrocyte sedimentation rate, GCS Glasgow Coma Scale, G6PD glucose-6-phosphate dehydrogenase, LDH lactate dehydrogenase, Nd:YAG neodymium-doped yttrium aluminium garnet, OCT optical coherence tomography, RDT rapid diagnostic test.

Non-contrast computed tomography of the kidneys, ureters and bladder on day 2 was normal, excluding calculus and obstruction. Ultrasonography showed hepatomegaly with coarse echotexture, gallbladder sludge and wall thickening, mild ascites and small pleural effusions; the pancreas appeared normal and the biliary tree was not dilated.

Serial values are given in Table 2 and Fig. 2, with haemolysis, coagulation and inflammatory indices in Table 3. Haemoglobin fell from 9.1 to 3.8 g/dL by day 6; platelets reached 58 × 10^9/L, later rebounding to 580 × 10^9/L. Creatinine rose from 1.42 to 3.46 mg/dL with urea 128 mg/dL. Total bilirubin peaked at 36.3 mg/dL, predominantly conjugated, with only modest, rapidly falling transaminases and a strikingly low alkaline phosphatase of 28 U/L. Lipase was 1312 U/L. Lactate dehydrogenase reached 3357 U/L with a negative direct antiglobulin test and an inappropriately low reticulocyte count of 2.0%. D-dimer was 9.96 mg/L with normal prothrombin time and fibrinogen.

Table 2
Serial haematological and biochemical parameters.

Parameter	D1	D6	D7	D8	D9	D11	D15	D34
Haemoglobin (g/dL)	9.1	3.8	4.3	6.4	9.7	10.7	8.1	11.4
Haematocrit (%)	26.8	11.0	12.9	19.1	28.9	30.8	25.1	34.5
Platelets (×10⁹/L)	58	160	160	218	215	270	580	250
Leucocytes (×10⁹/L)	11.06	9.92	10.5	8.5	8.5	11.0	6.86	13.0
ESR (mm/1st h)	—	115	30	> 140	39	38	69	44
Reticulocytes (%)	—	—	2.0	—	—	—	1.5	—
Creatinine (mg/dL)	1.42	3.18	3.46	3.24	2.43	2.09	1.76	1.29
Urea (mg/dL)	—	83	—	128	85	61	37	—
Total bilirubin (mg/dL)	—	35.63[a]	36.3	23.8	—	—	6.1[b]	2.3
ALT / AST (U/L)	100.7 / 220.5	—	94 / 86	—	—	—	—	76 / —
Sodium (mmol/L)	135	138	—	143	140	—	142	139
Bicarbonate (mmol/L)	—	18	21.1	16	25.7	—	25.4	24.1

D day of admission. [a]Obtained on day 4. [b]Obtained on day 14. Dashes indicate the test was not performed at that time point. ALT alanine aminotransferase, AST aspartate aminotransferase, ESR erythrocyte sedimentation rate.

Table 3
Haemolysis, coagulation, inflammatory and iron indices.

Investigation	Result	Reference range	Interpretation
Haemolysis and erythropoiesis			
Lactate dehydrogenase (day 7)	3357 U/L	85–227	Markedly raised; brisk haemolysis
Lactate dehydrogenase (day 15)	1158 U/L	225–450	Falling but persistently raised
Direct antiglobulin test	Negative	Negative	Excludes autoimmune haemolysis; does not exclude non-immune haemolysis
Indirect antiglobulin test	Negative	Negative	No alloantibody detected
Reticulocyte count (day 7)	2.0%	0.5–2.5	Inappropriately low for Hb 4.3 g/dL; suggests dyserythropoiesis
Reticulocyte count (day 15)	1.5%	0.5–2.5	Persistently inadequate response
Haptoglobin	Not measured	—	Precludes formal assessment of delayed haemolysis
G6PD (day 10, post-transfusion)	9.1 IU/g Hb	> 9.52 (male)	Uninterpretable in this context (see Discussion)
Coagulation			
Prothrombin time / INR (day 7)	14.0 s / 1.03	11.0–16.0 s	Normal
Activated partial thromboplastin time	39.7 s (control 30.0)	24.0–36.0	Mildly prolonged
Fibrinogen	3.10 g/L	2–4	Normal
D-dimer	9.96 mg/L	< 0.5	Markedly raised; compensated, non-overt coagulopathy
Inflammation and iron status			
C-reactive protein (day 7 / day 8)	198 / 135 mg/L	< 3.0	Markedly raised, falling
Ferritin (day 16)	> 1650 ng/mL	22–322 (male)	Above assay ceiling

G6PD glucose-6-phosphate dehydrogenase, Hb haemoglobin, INR international normalised ratio, TIBC total iron-binding capacity.

Investigation	Result	Reference range	Interpretation
Haemolysis and erythropoiesis			
Serum iron / TIBC	85 / 218 µg/dL	65–175 / 250–450	Low TIBC; anaemia of inflammation
Transferrin saturation	39%	—	Below the threshold for iron overload
Other			
Creatine phosphokinase	157 U/L	39–308 (male)	Normal; excludes rhabdomyolysis
Albumin / total protein	2.6 / 4.41 g/dL	3.6–5.2 / 6.4–8.2	Hypoalbuminaemia
Alkaline phosphatase	28 U/L	42–120	LOW; argues against biliary obstruction
Calcium / magnesium	8.0 / 2.8 mg/dL	8.5–10.1 / 1.8–2.4	Hypocalcaemia; hypermagnesaemia

G6PD glucose-6-phosphate dehydrogenase, Hb haemoglobin, INR international normalised ratio, TIBC total iron-binding capacity.

The differential work-up is set out in Table 4. Viral hepatitis serology was negative. A single leptospiral IgM at approximately illness day 12 was negative, and blood and urine cultures taken after ceftriaxone showed no growth. Scrub typhus and dengue were not tested.

Table 4
Differential diagnosis, showing which alternatives were excluded and which were not.

Differential diagnosis	Test performed	Result	Status
Malaria	RDT ×2; blood film ×2; PCR not available	RDT positive (Pf, then Pv at reference laboratory); films NEGATIVE	PROBABLE — parasitologically unconfirmed
Hepatitis A	Anti-HAV IgM	Negative	Excluded
Hepatitis E	Anti-HEV IgM	Negative	Excluded
Hepatitis B	HBsAg (ELISA)	Negative (OD 0.028)	Excluded
Hepatitis C	Anti-HCV (ELISA)	Negative (OD 0.008)	Excluded
Leptospirosis	Single IgM and IgG ELISA (~ illness day 12). No MAT, no PCR	Negative (IgM index 0.683; cut-off 0.828)	NOT ADEQUATELY EXCLUDED — single acute IgM has limited sensitivity
Bacterial sepsis / enteric fever	Blood and urine culture AFTER ceftriaxone	No growth	NOT EXCLUDED — pre-treatment reduces yield
Scrub typhus	NOT PERFORMED	—	NOT EXCLUDED — principal unaddressed alternative
Dengue	NOT PERFORMED	—	NOT EXCLUDED — though bilirubin 36 mg/dL would be exceptional
Rhabdomyolysis	Creatine phosphokinase	Normal	Excluded
Obstructive uropathy / calculus	Non-contrast CT KUB	Normal study	Excluded
Biliary obstruction	ALP; ultrasonography	ALP 28 U/L (low); non-dilated biliary tree	Excluded
Autoimmune haemolysis	Direct antiglobulin test	Negative	Excluded
Haemophagocytic lymphohistiocytosis	Partial (3/8 HLH-2004 criteria assessed)	Fibrinogen normal; no splenomegaly	NOT FORMALLY EXCLUDED

This table is presented in full because the diagnosis remained parasitologically unconfirmed. ELISA enzyme-linked immunosorbent assay, HAV hepatitis A virus, HBsAg hepatitis B surface antigen, HCV hepatitis C virus, HEV hepatitis E virus, HLH haemophagocytic lymphohistiocytosis, KUB kidneys/ureters/bladder, MAT microscopic agglutination test, OD optical density, PCR polymerase chain reaction, RDT rapid diagnostic test.

Malaria testing produced a discordant sequence. A rapid immunochromatographic test on day 5 was positive for

Plasmodium falciparum and negative for *P. vivax*, while blood films were negative at two accredited laboratories; parasite density was therefore never quantified. A sample sent to the Central Malaria Reference Laboratory on day 16, ten days after artesunate was begun, returned a rapid test reported as *P. vivax* with negative microscopy. Polymerase chain reaction was unavailable.

Intravenous artesunate 150 mg (2.44 mg/kg) was commenced on day 6 at 0, 12, 24, 48, 72 and 96 hours, followed by a full oral artemether–lumefantrine course. Meropenem was started the same day, and metronidazole and rifaximin the next. He received two haemodialysis sessions and seven units of blood (Table 5).

Table 5
Therapeutic interventions during admission.

Category	Agent, dose and route
Antimalarial	Intravenous artesunate 150 mg (2.44 mg/kg) at 0, 12, 24, 48, 72 and 96 h (days 6–10); then oral artemether 20 mg + lumefantrine 120 mg, four tablets per dose at 0, 8, 24, 36, 48 and 60 h (days 11–13)
Antibacterial	Ceftriaxone 1 g IV 12-hourly (from day 1); meropenem 500 mg IV 12-hourly (from day 6); metronidazole 500 mg IV 8-hourly (from day 7); rifaximin 550 mg twice daily (from day 7)
Renal replacement	Haemodialysis, two sessions (days 9 and 11)
Transfusion	Seven units of blood in total; five units of packed cells by day 9
Hepatobiliary / GI	Ursodeoxycholic acid 300 mg twice daily; lactulose; omeprazole 40 mg IV twice daily; ondansetron 8 mg IV as required; domperidone 10 mg three times daily
Haematological	Phytomenadione 1 ampoule IV daily for three days
Supportive	Tramadol and metamizole as required; paracetamol; calcium gluconate 10% 10 mL IV; oxygen 2–4 L/min; nebulised bronchodilator and budesonide; IV crystalloid; urinary catheterisation with strict fluid balance
Ocular	Topical nepafenac, brimonidine and corticosteroid (empirical, no established evidence base); Nd:YAG laser hyaloidotomy of the right eye on day 20

Note that intravenous artesunate and meropenem were commenced on the same day, which precludes attribution of the subsequent clinical improvement to either agent. GI gastrointestinal, IV intravenous, Nd:YAG neodymium-doped yttrium aluminium garnet.

On day 11, as systemic indices improved, he reported blurred vision. Ophthalmic review on day 16 recorded acuity of 6/60 right and 6/12 left, with deep scleral jaundice, clear media, and bilateral Roth spots and boat-shaped pre-retinal haemorrhages, the right involving the macula (Fig. 3). Optical coherence tomography showed a central subfield thickness of 568 µm with a dense pre-retinal collection

and posterior shadowing (Fig. 4). By day 20 right-eye acuity had fallen to counting fingers, and neodymium-doped yttrium aluminium garnet (Nd:YAG) laser hyaloidotomy was performed.

He was discharged on day 21 with multi-organ dysfunction resolved. At review on day 34 haemoglobin was 11.4 g/dL, creatinine 1.29 mg/dL and bilirubin 2.3 mg/dL. On day 37 visual acuity was 6/6 in both eyes.

Discussion

Diagnostic certainty: why we report this as probable malaria

This case was not parasitologically confirmed. Under World Health Organization terminology, a compatible illness without a confirmatory parasitological test is a presumed, not a confirmed, case [9]. The research definitions of severe malaria further pair the jaundice and anaemia thresholds with minimum parasite densities, never demonstrated here [10]; the full assessment of this patient against those criteria, showing which were met and which could not be satisfied without a parasite count, is set out in Table 6. Several weaknesses deserve acknowledgement rather than argument.

Table 6
Assessment against World Health Organization criteria for severe malaria.

WHO severe-malaria criterion	Threshold	This patient	Met
Severe anaemia	Hb < 7 g/dL with parasitaemia > 10,000/µL	3.8 g/dL; parasitaemia never demonstrated	Clinically yes; criterion not formally satisfiable
Renal impairment	Creatinine > 3 mg/dL or urea > 20 mmol/L	3.46 mg/dL; urea 128 mg/dL	Yes
Jaundice	Bilirubin > 3 mg/dL with parasitaemia > 100,000/µL	36.3 mg/dL; parasitaemia never demonstrated	Clinically yes; criterion not formally satisfiable
Acidosis	Bicarbonate < 15 mmol/L or lactate ≥ 5 mmol/L	Bicarbonate 16 mmol/L; lactate not measured	Borderline
Significant bleeding	Spontaneous bleeding	Retinal haemorrhage; haematuria	Arguable
Impaired consciousness	GCS < 11	GCS 15/15 throughout	No
Hypoglycaemia	< 2.2 mmol/L	Never documented	No
Shock	Compensated or decompensated	Blood pressure maintained	No
Pulmonary oedema	Radiological or clinical	Small pleural effusions only	No
Hyperparasitaemia	> 10%	Not quantifiable; films negative	Not assessable

The WHO research definitions pair the anaemia and jaundice thresholds with minimum parasite densities, which could not be demonstrated in this patient; the criteria are therefore shown as clinically but not formally satisfied. GCS Glasgow Coma Scale, Hb haemoglobin, WHO World Health Organization.

Smear-negative severe malaria is documented but uncommon: in a large paediatric series a negative slide with positive antigen testing occurred in under 1% of severe cases, and those patients still had measurable antigen biomass, which we did not quantify [11]. A positive histidine-rich protein 2 test may reflect infection weeks earlier, since half remain positive about 15 days after treatment, and rheumatoid factor causes false positives in 2–13% of samples [6, 12]. The later

P. vivax result almost certainly does not indicate a second species: high-density *P. falciparum* generates false-positive vivax pLDH lines in 8–29% of tests depending on brand [13]. We therefore interpret the sequence as one infection plus assay artefact, and we withdraw any suggestion of mixed infection.

Equally important is what was not tested. Scrub typhus accounts for roughly 17% of febrile hospitalised adults in Chittagong, causes jaundice, acute kidney injury and thrombocytopenia, shows an eschar in only about 4% of cases, and survives untreated in approximately 94% — so neither the absent eschar nor recovery without doxycycline excludes it [14, 15]. Dengue was untested, although a bilirubin of 36 mg/dL would be exceptional [16]. A single acute leptospiral IgM has a sensitivity of only 39–53% and cannot exclude the diagnosis without paired serology or polymerase chain reaction [17]. Cultures were drawn after ceftriaxone, which reduces yield by roughly 12 percentage points [18].

Finally, the therapeutic response is not evidence. Artesunate and meropenem began on the same day, after five days of deterioration on ceftriaxone, so improvement cannot be attributed to the antimalarial rather than to antibacterial escalation, dialysis, transfusion or natural resolution.

What remains is strong but circumstantial: prolonged residence in the country's only endemic region, a compatible syndrome, a positive species-specific antigen test, and recovery after a full artemisinin course. We consider malaria the most probable diagnosis while accepting that it is unproven.

The emergency-department lesson

The patient reached a surgical ward because flank pain, haematuria and jaundice form a coherent urological picture. Two inexpensive findings redirected the pathway: a normal computed tomogram, and an alkaline phosphatase of 28 U/L — below the lower reference limit — alongside a bilirubin of 36.3 mg/dL. Mechanical obstruction characteristically raises alkaline phosphatase more than threefold, so this combination argues against obstruction and towards a haemolytic and hepatopathic process [19, 20]. Where imaging access is limited, this relationship deserves more attention than it usually receives.

The ocular findings are non-specific — and that is the point

The retinal appearances are not diagnostic of malaria. Roth spots and pre-retinal haemorrhage occur in infective endocarditis, leukaemia, severe anaemia, diabetes, hypertension and human immunodeficiency virus infection. Retinopathy occurs in roughly 38% of patients with coexisting anaemia and thrombocytopenia but is rare with either alone, and severe combinations produce retinal haemorrhage in 44–70% irrespective of cause [21]. With haemoglobin 3.8 g/dL and platelets 58 × 10⁹/L, this patient had precisely that substrate. Classical malarial retinopathy — retinal whitening and vessel discoloration — was absent, and he was never comatose [22, 23]. Bilateral sub-hyaloid haemorrhage has nonetheless been described previously in a conscious adult with falciparum malaria, so the finding is not without precedent [30].

The useful message is operational, not aetiological. A conscious, improving patient developed a dense pre-macular haemorrhage reducing acuity to counting fingers, and Nd:YAG hyaloidotomy restored 6/6 vision. Hyaloidotomy achieves anatomical success in 86–97% of eyes when performed early, for haemorrhages larger than three disc diameters, before the clot organises [24, 25]. The delay between

symptom onset and formal ophthalmic referral here was avoidable: any severely anaemic, thrombocytopenic patient reporting visual blurring warrants same-day fundoscopy, whatever the underlying infection.

Other observations

The glucose-6-phosphate dehydrogenase value of 9.1 IU/g haemoglobin is uninterpretable: drawn on day 10 after five units of transfusion and during active haemolysis, all of which falsely raise measured activity; guidelines require repeat testing at three months [26]. This matters because the patient had taken a non-steroidal anti-inflammatory drug, making oxidant haemolysis a credible contributor. The low reticulocyte count additionally indicates dyserythropoiesis and argues against pure oxidative haemolysis [27]. Post-artesunate delayed haemolysis could not be diagnosed, since the haemoglobin nadir preceded artesunate and haptoglobin was never measured [28]. The raised D-dimer with normal prothrombin time and fibrinogen does not meet International Society on Thrombosis and Haemostasis criteria for overt disseminated intravascular coagulation and is better termed compensated coagulopathy [29].

Limitations

Parasite density was never quantified; species assignment rests on antigen testing alone; polymerase chain reaction, quantitative histidine-rich protein 2, haptoglobin, scrub typhus and dengue testing were all unavailable or not performed; leptospirosis was not adequately excluded; and the glucose-6-phosphate dehydrogenase result is uninterpretable with no repeat arranged. This is a single unconfirmed case, and the mechanistic explanations offered are inferential.

Conclusions

Severe febrile illness after endemic exposure may present as a urological emergency, may never be parasitologically confirmed, and may threaten sight while sparing consciousness. We report this as probable rather than confirmed malaria, and that uncertainty is itself instructive for emergency practice in elimination settings: antigen testing should precede an operative pathway after endemic exposure; a low alkaline phosphatase with marked conjugated hyperbilirubinaemia argues against obstruction; discordant rapid-test species results reflect assay artefact and need molecular resolution; and visual blurring in a severely anaemic, thrombocytopenic patient demands same-day fundoscopy, because a pre-macular haemorrhage may be fully reversible with timely laser hyaloidotomy.

Figure 1 Clinical timeline. Schematic representation of the illness from symptom onset through initial surgical admission, recognition of probable severe malaria, the nadir of multi-organ dysfunction, the onset of visual symptoms, laser hyaloidotomy and recovery. Day 1 denotes the day of admission to the tertiary centre. All timings are relative; no calendar dates are shown.

Figure 2 Serial laboratory trends during admission. a Serum creatinine (solid line, left axis) and urea (dashed line, right axis). b Total bilirubin. c Haemoglobin, nadir 3.8 g/dL on day 6. d Platelet count, nadir 58 × 10^9/L on admission with subsequent reactive rebound to 580 × 10^9/L. e Lactate dehydrogenase. f C-reactive protein and erythrocyte sedimentation rate. Vertical lines mark initiation of intravenous artesunate and meropenem (red dashed, day 6), haemodialysis (green dash-dot, days 9 and 11) and onset of visual blurring (blue dotted, day 11). Grey horizontal lines indicate reference thresholds.

Figure 3 Annotated colour fundus photographs, day 18. a Right eye; b left eye. White arrowheads indicate retinal haemorrhages, several with pale centres consistent with Roth spots. The dashed yellow ellipse labelled SH outlines a large boat-shaped pre-retinal (sub-hyaloid) haemorrhage at the posterior pole of the right eye, temporal to the optic disc and involving the macula, with the horizontal upper fluid level characteristic of blood trapped beneath the posterior hyaloid face. Dashed blue circles labelled D mark the optic disc. The left eye shows scattered retinal haemorrhages without macular involvement. These appearances are not specific to malaria and are recognised in severe anaemia with thrombocytopenia of any cause. All patient identifiers have been removed.

Figure 4 Annotated spectral-domain optical coherence tomography of the right macula, day 17. a Macular thickness map (internal limiting membrane to retinal pigment epithelium/Bruch membrane); the dashed white outline encloses a central zone of off-scale thickening exceeding the 500 µm ceiling of the colour scale, approximately 2.6 × 1.3 mm. b Horizontal B-scan through the fovea: the interrupted blue line marks the internal limiting membrane level in the unaffected periphery, the red arrow indicates an elevated hyper-reflective pre-retinal collection, and the yellow bracket spans dense posterior optical shadowing. This combination is the characteristic tomographic signature of a dense pre-retinal haemorrhage and corresponds to the lesion in Fig. 3a. c Early Treatment Diabetic Retinopathy Study nine-sector thickness map; the circled central subfield measured 568 µm. Patient identifiers redacted.

Declarations

Ethics approval and consent to participate

This report describes a single patient and does not constitute human-subjects research requiring formal ethical review under the policies of Shaheed Suhrawardy Medical College and Hospital, Dhaka, Bangladesh. Institutional Review Board approval was therefore not required and no approval number was issued. Written informed consent to participate was obtained from the patient.

Consent for publication

Written informed consent was obtained from the patient for publication of this case report and accompanying images. A copy of the signed consent form is available for review by the Editor-in-Chief of this journal on request.

Availability of data and materials

All data generated or analysed during this case are included in this published article. Source clinical records are held at Shaheed Suhrawardy Medical College and Hospital and are not publicly available in order to protect patient privacy.

Competing interests

The authors declare that they have no competing interests.

Funding

No funding was received for this work.

Authors’ contributions

IAS conceptualised the report, curated the data, prepared the figures and wrote the original draft. MMI and MAH collected clinical data and contributed to drafting. TA and MAS interpreted the clinical and laboratory findings and critically revised the manuscript. MSSE and MNAS contributed to data collection and manuscript revision. AMA supervised the clinical management and critically revised the manuscript for important intellectual content. All authors read and approved the final manuscript.

Acknowledgements

The authors thank the staff of the Departments of Medicine, Surgery, Ophthalmology and Radiology at Shaheed Suhrawardy Medical College and Hospital, and the National Institute of Ophthalmology and Hospital, Dhaka. Above all we thank the patient for permitting publication of his case.

Use of artificial intelligence

A large language model was used to assist with language editing and formatting of the manuscript. No artificial intelligence tool was used to generate clinical data, interpret results, or produce the scientific content. The authors reviewed and verified all content and accept full responsibility for the integrity of the work.

Reporting guideline

This case report was prepared in accordance with the CARE (CAse REport) guidelines; a completed CARE checklist is submitted as an additional file.

Patient perspective

“My illness began with high fever, yellowing of my eyes and skin, dark urine and vomiting. At first I was told it might be a problem with my bile duct or a stone. When no surgical cause was found and I was told that malaria had affected several of my organs, I realised how serious my condition was. The hardest period was when my blood count and kidneys worsened and I needed transfusions and dialysis. Although I stayed awake and aware throughout, I felt very weak and worried about recovering. Just as I began to improve, my vision blurred, especially in the right eye, and learning that there was bleeding at the back of my eye was frightening. After the laser treatment my sight returned completely, which was an enormous relief. I hope sharing my experience helps doctors think of malaria early in patients who have been to areas where it is common.”

References

1. World Health Organization. World malaria report 2025. Geneva: World Health Organization; 2025.
2. Haldar K, Alam MS, Koepfli C, Lobo NF, Phru CS, Islam MN, et al. Bangladesh in the era of malaria elimination. Trends Parasitol. 2023;39:760–73.
3. Matin MA, Sarkar NDP, Phru CS, Ley B, Thriemer K, Price RN, et al. Precarity at the margins of malaria control in the Chittagong Hill Tracts in Bangladesh: a mixed-methods study. Pathogens. 2020;9:840.
4. Seshadri P, Dev AV, Viggeswarpu S, Sathyendra S, Peter JV. Acute pancreatitis and subdural haematoma in a patient with severe falciparum malaria: case report and review of literature. Malar J. 2008;7:97.
5. Wongsrichanalai C, Barcus MJ, Muth S, Sutamihardja A, Wernsdorfer WH. A review of malaria diagnostic tools: microscopy and rapid diagnostic test (RDT). Am J Trop Med Hyg. 2007;77(6 Suppl):119–27.
6. Dalrymple U, Arambepola R, Gething PW, Cameron E. How long do rapid diagnostic tests remain positive after anti-malarial treatment? Malar J. 2018;17:228.
7. Silamut K, White NJ. Relation of the stage of parasite development in the peripheral blood to prognosis in severe falciparum malaria. Trans R Soc Trop Med Hyg. 1993;87:436–43.
8. Gagnier JJ, Kienle G, Altman DG, Moher D, Sox H, Riley D, CARE Group. The CARE guidelines: consensus-based clinical case reporting guideline development. J Med Case Rep. 2013;7:223.
9. World Health Organization. WHO malaria terminology, 2021 update. Geneva: World Health Organization; 2021.
10. World Health Organization. Severe malaria. Trop Med Int Health. 2014;19(Suppl 1):7–131.

11. Hendriksen ICE, Mwanga-Amumpaire J, von Seidlein L, Mtove G, White LJ, Olaosebikan R, et al. Diagnosing severe falciparum malaria in parasitaemic African children: a prospective evaluation of plasma PfHRP2 measurement. PLoS Med. 2012;9:e1001297.
12. Lee JH, Jang JW, Cho CH, Kim JY, Han ET, Yun SG, et al. False-positive results for rapid diagnostic tests for malaria in patients with rheumatoid factor. J Clin Microbiol. 2014;52:3784–7.
13. Maltha J, Gillet P, Cnops L, van den Ende J, van Esbroeck M, Jacobs J. Malaria rapid diagnostic tests: Plasmodium falciparum infections with high parasite densities may generate false positive Plasmodium vivax pLDH lines. Malar J. 2010;9:198.
14. Kingston HWF, Hossain M, Leopold S, Anantatat T, Tanganuchitcharnchai A, Sinha I, et al. Rickettsial illnesses as important causes of febrile illness in Chittagong, Bangladesh. Emerg Infect Dis. 2018;24:638–45.
15. Taylor AJ, Paris DH, Newton PN. A systematic review of mortality from untreated scrub typhus (Orientia tsutsugamushi). PLoS Negl Trop Dis. 2015;9:e0003971.
16. Samanta J, Sharma V. Dengue and its effects on liver. World J Clin Cases. 2015;3:125–31.
17. Niloofa R, Fernando N, de Silva NL, Karunanayake L, Wickramasinghe H, Dikmadugoda N, et al. Diagnosis of leptospirosis: comparison between microscopic agglutination test, IgM-ELISA and IgM rapid immunochromatography test. PLoS ONE. 2015;10:e0129236.
18. Cheng MP, Stenstrom R, Paquette K, Stabler SN, Akhter M, Davidson AC, et al. Blood culture results before and after antimicrobial administration in patients with severe manifestations of sepsis: a diagnostic study. Ann Intern Med. 2019;171:547–54.
19. Anand AC, Puri P. Jaundice in malaria. J Gastroenterol Hepatol. 2005;20:1322–32.
20. Bhalla A, Suri V, Singh V. Malarial hepatopathy. J Postgrad Med. 2006;52:315–20.
21. Carraro MC, Rossetti L, Gerli GC. Prevalence of retinopathy in patients with anemia or thrombocytopenia. Eur J Haematol. 2001;67:238–44.
22. Maude RJ, Beare NAV, Abu Sayeed A, Chang CC, Charunwatthana P, Faiz MA, et al. The spectrum of retinopathy in adults with Plasmodium falciparum malaria. Trans R Soc Trop Med Hyg. 2009;103:665–71.
23. Abu Sayeed A, Maude RJ, Hasan MU, Mohammed N, Hoque MG, Dondorp AM, et al. Malarial retinopathy in Bangladeshi adults. Am J Trop Med Hyg. 2011;84:141–7.
24. Khadka D, Bhandari S, Bajimaya S, Thapa R, Paudyal G, Pradhan E. Nd:YAG laser hyaloidotomy in the management of premacular subhyaloid hemorrhage. BMC Ophthalmol. 2016;16:41.
25. Durukan AH, Kerimoglu H, Erdurman C, Demirel A, Karagul S. Long-term results of Nd:YAG laser treatment for premacular subhyaloid haemorrhage owing to Valsalva retinopathy. Eye (Lond). 2008;22:214–8.
26. Roper D, Layton M, Rees D, Lambert C, Vulliamy T, De la Salle B, et al. Laboratory diagnosis of G6PD deficiency: a British Society for Haematology guideline. Br J Haematol. 2020;189:24–38.
27. White NJ. Anaemia and malaria. Malar J. 2018;17:371.

28. Jauréguiberry S, Ndour PA, Roussel C, Ader F, Safeukui I, Nguyen M, et al. Postartesunate delayed hemolysis is a predictable event related to the lifesaving effect of artemisinins. Blood. 2014;124:167–75.
29. Taylor FB Jr, Toh CH, Hoots WK, Wada H, Levi M. Scientific Subcommittee on DIC of the ISTH. Towards definition, clinical and laboratory criteria, and a scoring system for disseminated intravascular coagulation. Thromb Haemost. 2001;86:1327–30.
30. Abdali N, Malik AM, Shamim MD, Rizvi SW. Bilateral subhyaloid haemorrhage in a conscious patient: a new spectrum of ocular involvement by Plasmodium falciparum. BMJ Case Rep. 2014;2014:bcr2013202811.

Figures

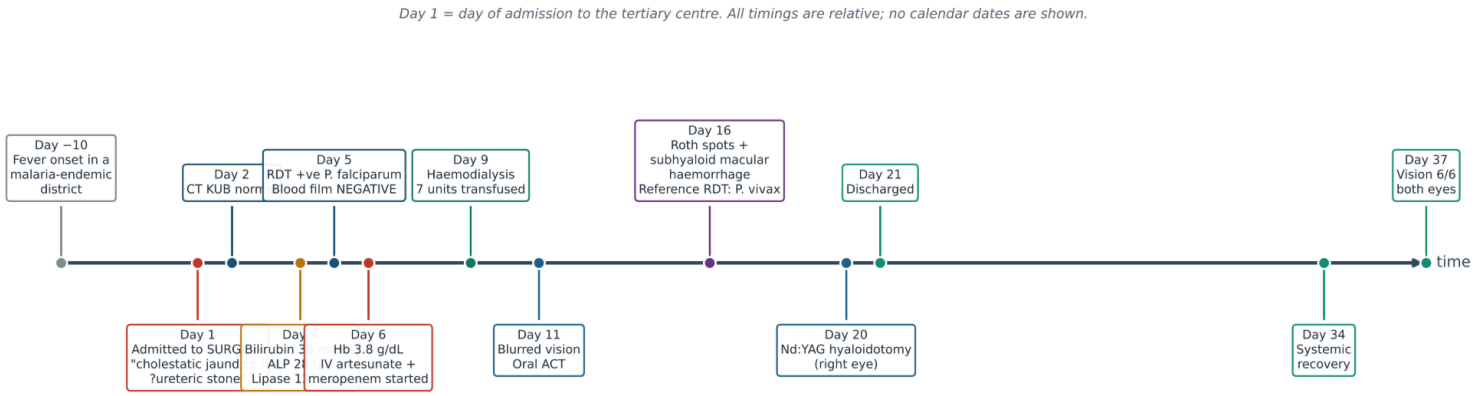

Figure 1

Clinical timeline. Schematic representation of the illness from symptom onset through initial surgical admission, recognition of probable severe malaria, the nadir of multi-organ dysfunction, the onset of visual symptoms, laser hyaloidotomy and recovery. Day 1 denotes the day of admission to the tertiary centre. All timings are relative; no calendar dates are shown.

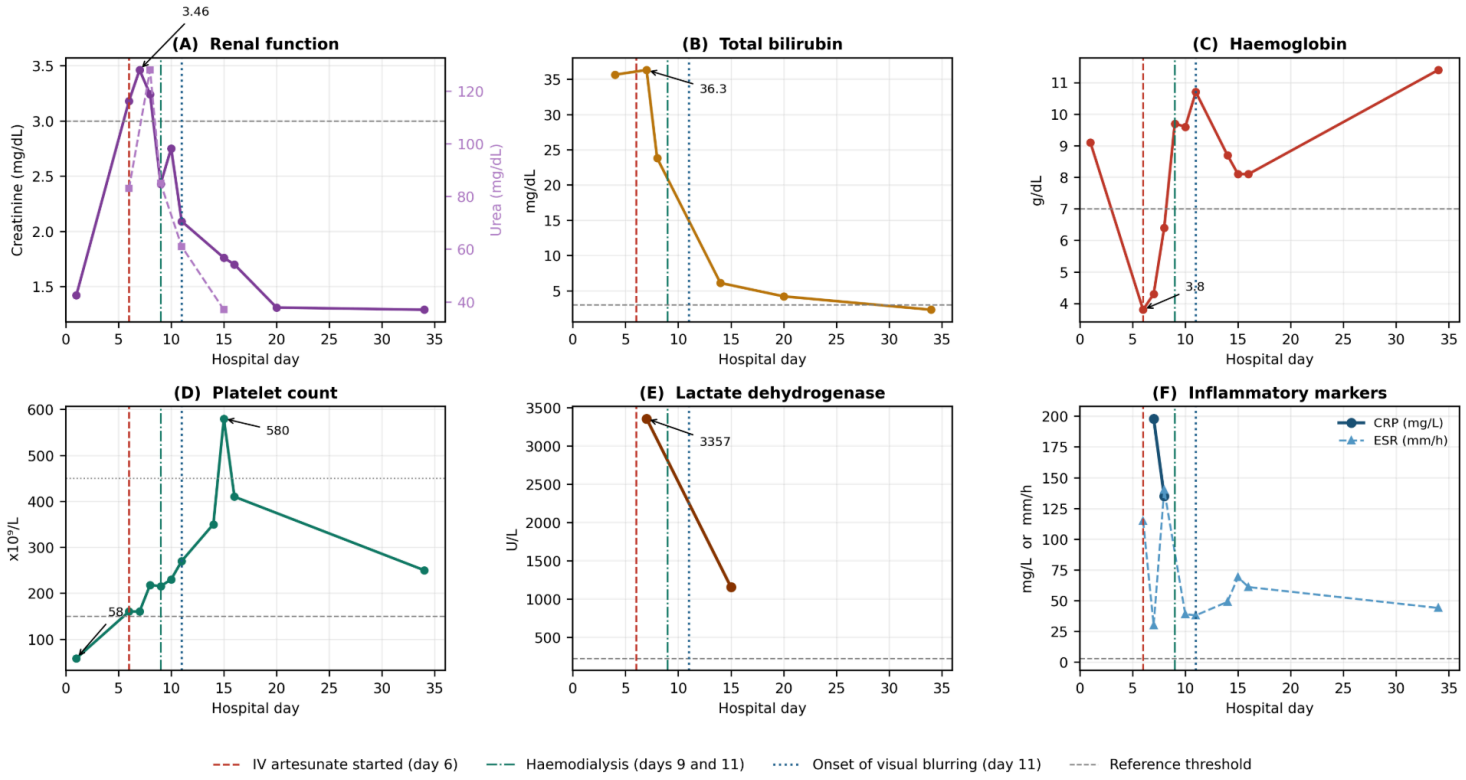

Figure 2

Serial laboratory trends during admission. a Serum creatinine (solid line, left axis) and urea (dashed line, right axis). b Total bilirubin. c Haemoglobin, nadir 3.8 g/dL on day 6. d Platelet count, nadir 58 × 10⁹/L on admission with subsequent reactive rebound to 580 × 10⁹/L. e Lactate dehydrogenase. f C-reactive protein and erythrocyte sedimentation rate. Vertical lines mark initiation of intravenous artesunate and meropenem (red dashed, day 6), haemodialysis (green dash-dot, days 9 and 11) and onset of visual blurring (blue dotted, day 11). Grey horizontal lines indicate reference thresholds.

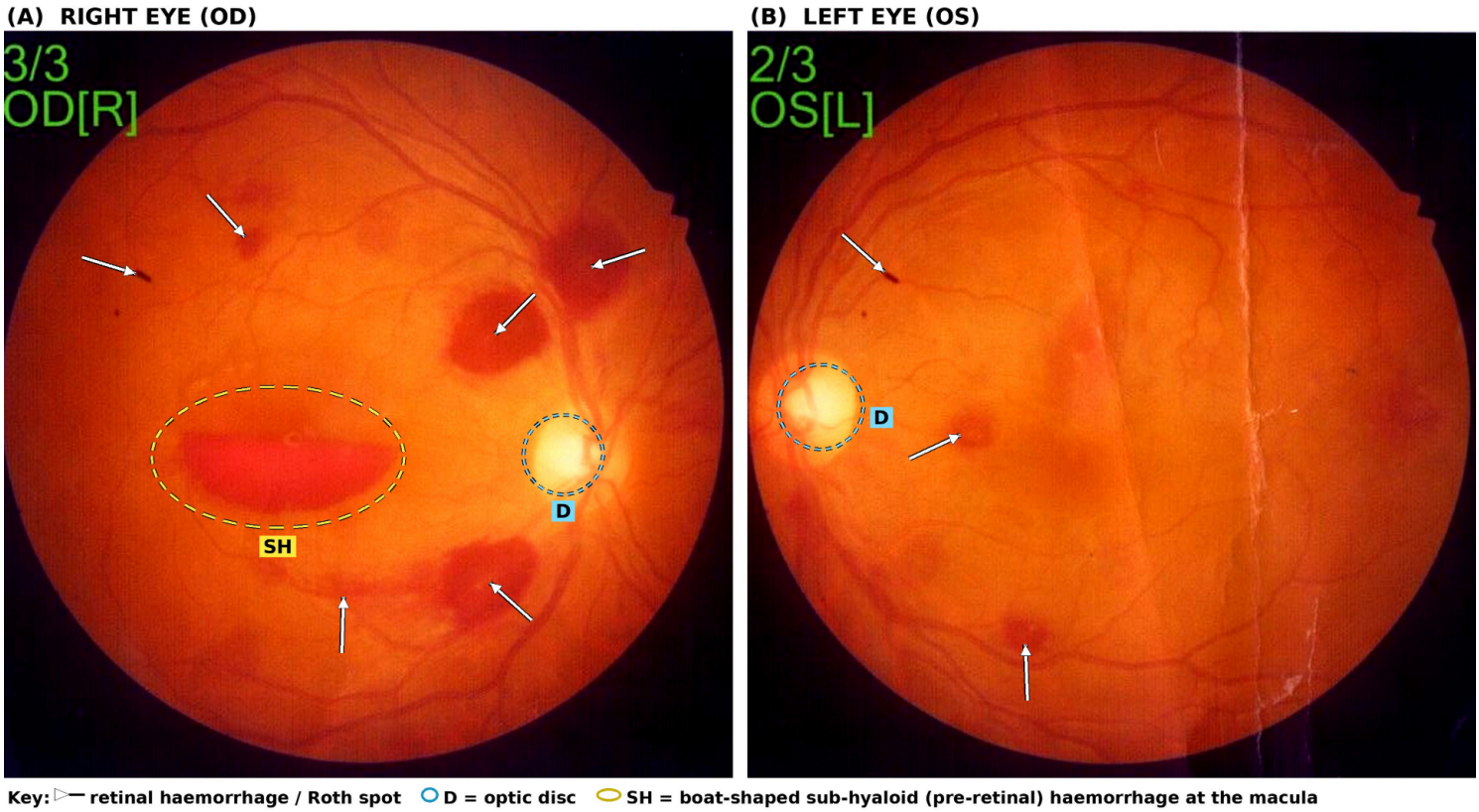

Figure 3

Annotated colour fundus photographs, day 18. a Right eye; b left eye. White arrowheads indicate retinal haemorrhages, several with pale centres consistent with Roth spots. The dashed yellow ellipse labelled SH outlines a large boat-shaped pre-retinal (sub-hyaloid) haemorrhage at the posterior pole of the right eye, temporal to the optic disc and involving the macula, with the horizontal upper fluid level characteristic of blood trapped beneath the posterior hyaloid face. Dashed blue circles labelled D mark the optic disc. The left eye shows scattered retinal haemorrhages without macular involvement. These appearances are not specific to malaria and are recognised in severe anaemia with thrombocytopenia of any cause. All patient identifiers have been removed.

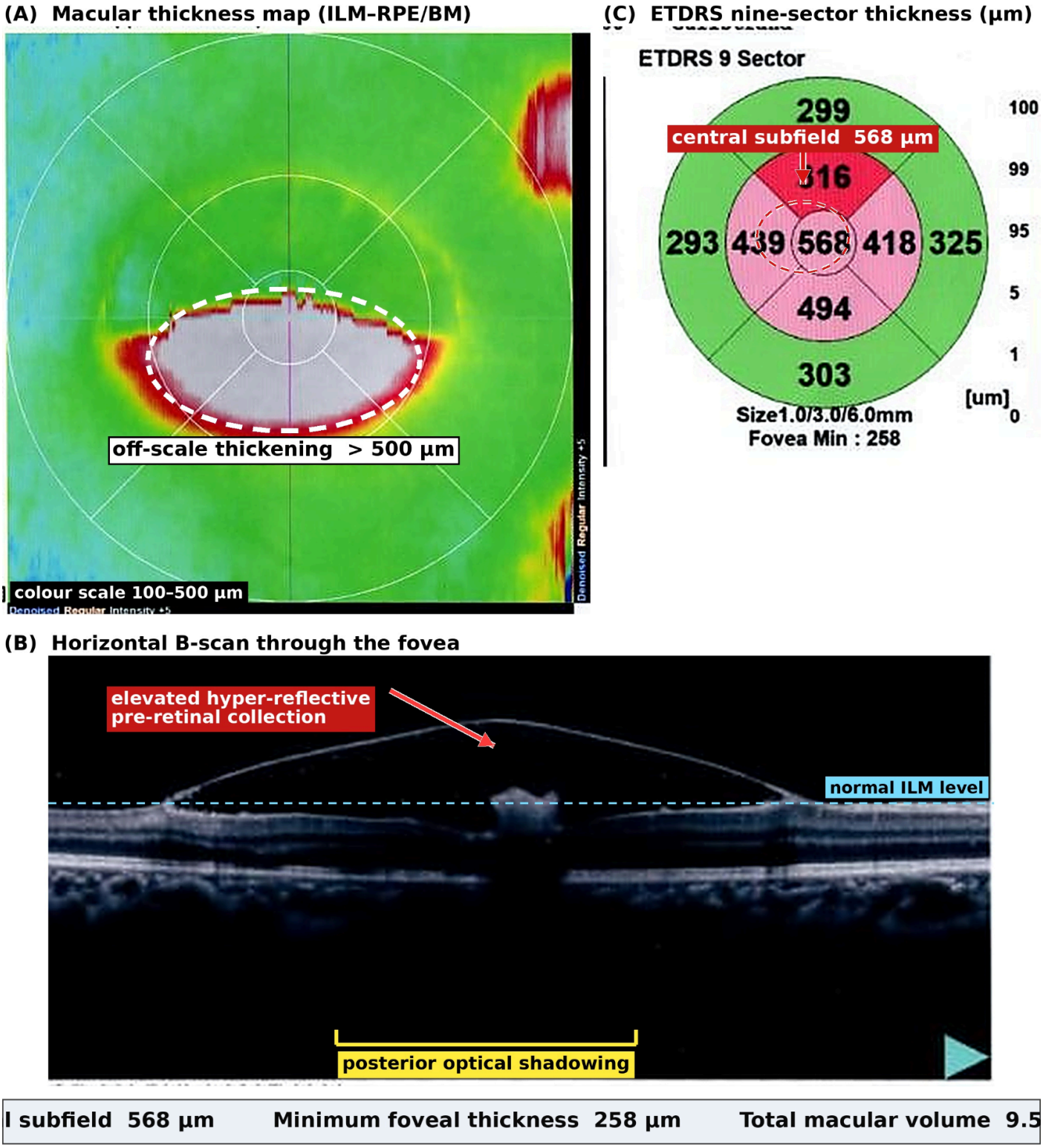

Figure 4

Annotated spectral-domain optical coherence tomography of the right macula, day 17. a Macular thickness map (internal limiting membrane to retinal pigment epithelium/Bruch membrane); the dashed white outline encloses a central zone of off-scale thickening exceeding the 500 µm ceiling of the colour scale, approximately 2.6 × 1.3 mm. b Horizontal B-scan through the fovea: the interrupted blue line marks the internal limiting membrane level in the unaffected periphery, the red arrow indicates an

elevated hyper-reflective pre-retinal collection, and the yellow bracket spans dense posterior optical shadowing. This combination is the characteristic tomographic signature of a dense pre-retinal haemorrhage and corresponds to the lesion in Fig. 3a. c Early Treatment Diabetic Retinopathy Study nine-sector thickness map; the circled central subfield measured 568 µm. Patient identifiers redacted.