Research Square

Preprints are preliminary reports that have not undergone peer review.
They should not be considered conclusive, used to inform clinical practice,
or referenced by the media as validated information.

Clinical Efficacy Analysis of Montgomery T-Tube Placement for Malignant Upper Airway Stenosis

Keyi Chen
Gansu Provincial Second People's Hospital
qingcuoji a
Gansu Provincial Second People's Hospital
Yanxia Yang
497534365@qq.com

Gansu Provincial Second People's Hospital
Shuangxu Ren
Gansu Provincial Second People's Hospital
Suzhen Wei
Gansu Provincial Second People's Hospital
Bin Ma
Gansu Provincial Second People's Hospital
Xiaoping Liu
Gansu Provincial Second People's Hospital

Research Article

Keywords: Montgomery T-tube, Interventional therapy, Clinical efficacy

Posted Date: November 24th, 2026

DOI: https://doi.org/10.21203/rs.3.rs-11513588/v1

License: This work is licensed under a Creative Commons Attribution 4.0 International License.
Read Full License

Additional Declarations: No competing interests reported.

Abstract

Objective To investigate the efficacy of Montgomery T-tube placement in patients with malignant upper airway stenosis.

Methods A retrospective analysis was conducted on the clinical data of 16 patients with malignant airway stenosis who underwent Montgomery T-tube placement in Gansu Provincial Second People's Hospital from January 2020 to June 2026. Changes in the modified Medical Research Council dyspnea scale (mMRC), Eating Assessment Tool-10 (EAT-10), Voice Handicap Index-10 (VHI-10), and Karnofsky Performance Status (KPS) score before and after treatment were compared.

Results All 16 patients successfully underwent Montgomery T-tube placement. After treatment, the mMRC score [3 (2, 3)] was lower than that before treatment [4 (3, 4)], the VHI-10 score [20.5 (16, 25.5)] was lower than that before treatment [27 (21, 34)], the EAT-10 score [21 (16.5, 24)] was lower than that before treatment [27 (19, 32.5)], and the KPS score [50 (40, 60)] was higher than that before treatment [30 (20, 30)], with all differences being statistically significant ($P<0.05$). One patient developed hypoventilation due to coexisting interstitial pulmonary fibrosis and was subsequently switched to a tracheostomy tube connected to mechanical ventilation. The remaining patients had stable treatment courses, and no severe complications such as cartilage damage or bronchial perforation occurred.

Conclusion Montgomery T-tube placement can effectively improve dyspnea, voice function, swallowing function, and overall functional status in patients with malignant airway stenosis. It is relatively safe and has high clinical application value.

Introduction

Malignant upper airway stenosis is primarily caused by primary malignant tumors of the thyroid, larynx, or pharynx, as well as by direct invasion or compression of the airway by metastatic cervical lymph nodes. In the early stages, symptoms are often subtle or may manifest only as mild hoarseness and are therefore easily overlooked. Because the upper airway is anatomically narrow, patients may rapidly develop dyspnea once severe stenosis occurs, resulting in profound hypoxia and even fatal asphyxia [1–2]. For patients who are not candidates for surgical resection or who require long-term maintenance of airway patency, prompt relief of airway obstruction and improvement of ventilation are critical to treatment.The Montgomery T-tube combines the functions of dilating the stenotic airway, maintaining airway patency, and preserving phonation. Its soft and biocompatible material causes relatively little irritation to the airway mucosa [3]. Moreover, the tube can be customized according to the location and extent of stenosis. The external limb facilitates sputum expectoration and emergency airway management, offering the advantages of simple operation, minimal trauma, and a favorable safety profile [4]. Therefore, this retrospective study analyzed the clinical data of patients with malignant upper airway stenosis who underwent Montgomery T-tube placement. The modified Medical Research Council dyspnea scale (mMRC), Eating Assessment Tool-10 (EAT-10), Voice Handicap Index-10 (VHI-10), and Karnofsky Performance Status (KPS) were compared before and after treatment to evaluate dyspnea,

swallowing function, voice function, and overall functional status, respectively. The aim was to investigate the clinical efficacy of Montgomery T-tube placement and provide a reference for airway management in this patient population.

1. Materials and Methods

1.1 Clinical Data

A total of 16 patients with malignant upper airway stenosis treated between January 2020 and June 2026 were included in this study. The cohort comprised 12 men and 4 women, aged 58–84 years, with a mean age of 69.25 ± 8.14 years. The primary diseases were thyroid malignancy in 6 patients (37.5%), laryngeal malignancy in 6 (37.5%), vocal cord malignancy in 1 (6.25%), tracheal malignancy in 1 (6.25%), esophageal malignancy in 1 (6.25%), and glottic malignancy in 1 (6.25%).The inclusion criteria were as follows: (1) malignant airway stenosis confirmed by pathological examination, imaging, or bronchoscopy; (2) clinically evident symptoms of airway obstruction with unsatisfactory response to conventional treatment; and (3) suitability for and receipt of Montgomery T-tube placement. The exclusion criteria were as follows: (1) incomplete clinical or follow-up data; (2) severe cardiopulmonary dysfunction precluding surgery; and (3) severe coagulation disorders.This study was reviewed and approved by the Medical Ethics Committee of the hospital (approval No. GSSEY2026-KY001-12).

1.2 Surgical Procedure

A comprehensive preoperative evaluation was performed to assess the location, extent, and severity of airway stenosis, as well as the patient's tolerance to anesthesia. Patients were placed in the supine position and received oxygen supplementation and intravenous general anesthesia. Ventilation was maintained using an anesthesia machine, while continuous electrocardiographic monitoring was initiated. Heart rate, blood pressure, and blood oxygen saturation were closely monitored throughout the procedure.A bronchoscope was inserted through an endotracheal tube, laryngeal mask airway, or tracheostomy stoma, and airway secretions were removed. The nature, location, length, and severity of the stenosis were assessed, and lesion tissue was obtained for pathological examination when necessary. For intraluminal tumors or scar tissue, the lesion was removed and the airway lumen enlarged according to the characteristics of the lesion using one or more of the following techniques: grasping with biopsy forceps, snare resection, scraping or mechanical resection with the outer sheath of a rigid bronchoscope, high-frequency electrocautery, and laser ablation.An appropriately sized T-tube was selected according to the location and length of the stenosis. When necessary, the upper and lower limbs of the T-tube were trimmed and polished to ensure complete coverage of the stenotic segment while avoiding interference with the glottis, carina, or the orifices of the main bronchi. In patients with a pre-existing tracheostomy, the original tracheostomy tube was removed and the T-tube was inserted through the tracheostomy stoma. In patients without a tracheostomy, an appropriate intercartilaginous space was punctured under bronchoscopic guidance. After insertion of a guidewire, the puncture needle

was withdrawn, and the access tract was sequentially dilated with dilators along the guidewire to establish a safe channel for T-tube placement.The Montgomery T-tube was then inserted under the guidance of a bronchoscope or rigid bronchoscope. The positions of the upper and lower limbs were adjusted to ensure that the T-tube completely covered the stenotic segment and was well apposed to the airway wall and adequately expanded. Secretions in the airway and pharynx were cleared, and the bronchoscope was withdrawn after confirming the absence of active bleeding. Once the patient had recovered from anesthesia and vital signs were stable, the patient was transferred to the ward. Continuous electrocardiographic and oxygen saturation monitoring was maintained, and supportive treatment, including oxygen supplementation, anti-infective therapy, hemostatic treatment, and measures to promote sputum expectoration, was administered. Representative findings are shown in Figs. 1 and 2.

1.3 Outcome Measures

The mMRC, VHI-10, EAT-10, and KPS scores were assessed before treatment and 7 days after T-tube placement.mMRC score: Grade 0 indicates dyspnea only with strenuous exercise; grade 1 indicates dyspnea when walking quickly or ascending a slight incline; grade 2 indicates walking more slowly than individuals of the same age on level ground because of dyspnea, or the need to stop and rest when walking at one's own pace; grade 3 indicates the need to stop and rest after walking approximately 100 m or for several minutes on level ground; and grade 4 indicates an inability to leave the home because of severe dyspnea or the development of dyspnea when dressing or undressing. Higher scores indicate more severe dyspnea.VHI-10 score: The scale consists of 10 items, each scored from 0 to 4 according to the frequency of symptoms, yielding a total score of 0–40. Higher scores indicate more severe voice impairment and a greater impact on quality of life.EAT-10 score: The scale consists of 10 items, each scored from 0 to 4 according to symptom severity, yielding a total score of 0–40. Higher scores indicate more severe swallowing dysfunction.

KPS score: The score ranges from 0 to 100 in 10-point increments. A score of 100 indicates normal activity without disease-related symptoms or signs; 90 indicates normal activity with minor symptoms or signs; 80 indicates normal activity with some effort and the presence of certain symptoms or signs; 70 indicates the ability to care for oneself but an inability to perform normal activities or work; 60 indicates that the patient is able to meet most personal needs but occasionally requires assistance from others; 50 indicates markedly limited self-care ability, with frequent need for assistance and medical care; 40 indicates an inability to care for oneself, requiring special care and assistance; 30 indicates severe inability to care for oneself, requiring hospitalization but without an immediate threat to life; 20 indicates severe illness requiring hospitalization and active supportive treatment; 10 indicates a critically ill state with impending death; and 0 indicates death. Higher scores indicate better functional status and ability to perform activities of daily living.

1.4 Statistical Analysis

Statistical analyses were performed using SPSS version 26.0 (IBM Corp., Armonk, NY, USA). The VHI-10 and EAT-10 scores were treated as continuous variables. Because these scores did not follow a normal distribution according to the normality test, they were expressed as M (P25, P75), and pre- and post-treatment comparisons were performed using the Wilcoxon signed-rank test. The mMRC and KPS scores were treated as ordinal variables and expressed as M (P25, P75); pre- and post-treatment comparisons were also performed using the Wilcoxon signed-rank test. Categorical data were expressed as the number of cases and percentage [n (%)]. A two-sided P value < 0.05 was considered statistically significant.

2. Results

Table 1
Changes in clinical scores before and after T-tube placement

Variable	Before T-tube placement (n = 16)	After T-tube placement (n = 16)	Z	P-value
mMRC score, median (IQR)	4 (3, 4)	3 (2, 3)	−3.207	0.001
VHI-10 score, median (IQR)	27 (21, 34)	20.5 (16, 25.5)	−3.413	0.001
EAT-10 score, median (IQR)	27 (19, 32.5)	21 (16.5, 24)	−3.070	0.002
KPS score, median (IQR)	30 (20, 30)	50 (40, 60)	−3.555	< 0.001

Note: Data are presented as median (IQR). Comparisons were performed using the Wilcoxon signed-rank test. mMRC, modified Medical Research Council; VHI-10, 10-item Voice Handicap Index; EAT-10, Eating Assessment Tool-10; KPS, Karnofsky Performance Status.

Among the 16 patients, significant improvements were observed in symptom burden and functional status after T-tube placement (Table 1). Specifically, the mMRC score decreased from 4 (3, 4) before placement to 3 (2, 3) after placement (Z = − 3.207, P = 0.001), the VHI-10 score decreased from 27 (21, 34) to 20.5 (16, 25.5) (Z = − 3.413, P = 0.001), and the EAT-10 score decreased from 27 (19, 32.5) to 21 (16.5, 24) (Z = − 3.070, P = 0.002). In contrast, the KPS score increased from 30 (20, 30) before placement to 50 (40, 60) after placement (Z = − 3.555, P < 0.001). These findings indicate that T-tube placement was associated with significant improvements in dyspnea, voice-related handicap, swallowing function, and overall performance status.

Regarding safety, 1 patient developed hypoventilation due to concomitant pulmonary interstitial fibrosis. After comprehensive evaluation, the Montgomery T-tube was replaced with a tracheostomy tube connected to a ventilator for assisted ventilation. The remaining patients had a stable clinical course, and no serious complications, such as airway cartilage injury or airway perforation, were observed. Overall, Montgomery T-tube placement was generally well tolerated and safe in this cohort.

3. Discussion

Malignant airway stenosis is most commonly caused by direct invasion of the airway by primary lung cancer or adjacent malignant tumors, extraluminal compression, or intraluminal tumor growth. Some patients may have multiple mechanisms of obstruction simultaneously, resulting in a more complex clinical condition. As the airway lumen gradually narrows, patients may develop progressively worsening dyspnea and obstructive pulmonary complications, and may even experience respiratory failure. Most of these patients have intermediate- or advanced-stage tumors and have generally lost the opportunity for curative surgical resection. Although radiotherapy, chemotherapy, targeted therapy, and immunotherapy may control tumor progression, they often cannot promptly relieve severe mechanical airway obstruction [5]. Therefore, the rapid restoration of airway patency and improvement of ventilatory function are critical components of the comprehensive treatment of these patients.

Previous studies have shown that airway stent placement can rapidly improve dyspnea, ventilatory function, and oxygenation in patients with malignant central airway obstruction [6]. Although endoscopic metallic and silicone stents have been widely used for airway stenosis in recent years, conventional intraluminal stents used for malignant stenosis of the subglottic region and upper trachea have a relatively high risk of migration. They may also irritate the vocal cords, causing severe coughing and potentially affecting swallowing and phonation [7]. In contrast, the Montgomery T-tube offers distinct advantages in patients with subglottic and high cervical tracheal stenosis. Its unique lateral limb provides firm physical anchoring, thereby reducing the risk of migration in the subglottic region while also supporting the airway wall. One study reported that most patients with complex high-level malignant stenosis who underwent Montgomery T-tube placement were able to resume spontaneous breathing through the upper airway [8].

The results of the present study showed that the mMRC score decreased after Montgomery T-tube placement, indicating an improvement in dyspnea. This may be attributable to the longitudinal limb of the T-tube, which provides continuous support to the stenotic airway, maintains luminal patency, and increases the effective cross-sectional area for ventilation. These effects reduce airflow resistance and improve distal pulmonary ventilation and secretion drainage. Previous clinical studies have also demonstrated that Montgomery T-tubes are highly safe and effective for maintaining long-term patency in complex airways [9].

The present study also observed an increase in KPS scores after treatment, suggesting improvements in patients' daily activity capacity and overall functional status. As an important indicator of general condition and self-care ability in patients with cancer, an increased KPS score generally indicates reduced dependence in activities of daily living and greater exercise tolerance, thereby creating more favorable conditions for subsequent antitumor treatment. Thus, T-tube treatment not only improved the ventilatory impairment caused by local airway stenosis but also improved patients' overall condition to some extent, facilitating the implementation of subsequent comprehensive treatment.

In addition, both EAT-10 and VHI-10 scores decreased after treatment. This improvement may be closely related to the structural characteristics of the Montgomery T-tube. The upper limb of the tube provides stable support to the subglottic stenotic region. While maintaining local airway patency, it may reduce interference with normal vocal-cord closure and vibration. Once the patient's condition stabilizes and the lateral limb is capped, exhaled airflow can pass through the glottis via the upper airway again, thereby restoring phonation that more closely resembles the physiological process. The reestablishment of airflow through the larynx may also help restore laryngeal sensory stimulation and part of the glottic protective function, thereby improving swallowing coordination and phonation. Therefore, the simultaneous decreases in EAT-10 and VHI-10 scores may, to some extent, indicate that T-tube placement not only improves local mechanical stenosis but also contributes to the recovery of upper-airway-related physiological functions.

However, these functional improvements cannot be consistently achieved in all patients. Treatment efficacy is still influenced by factors such as T-tube position, local tissue response, and the extent of the underlying lesion. If the upper end of the T-tube is positioned too high or too close to the glottis, it may cause mechanical irritation of the aryepiglottic region or subglottic mucosa, resulting in a foreign-body sensation, irritative cough, or even impaired coordination of vocal-cord closure. Local granulation tissue proliferation or secretion retention after tube placement may also aggravate swallowing discomfort, increase the risk of aspiration, and impair voice quality. Therefore, during preoperative assessment, bronchoscopy and chest and neck imaging should be combined to accurately evaluate the location and length of the stenosis and its distance from the glottis, thereby facilitating the appropriate selection of T-tube size and length [10]. For patients with preexisting significant dysphagia, a history of aspiration, or laryngeal dysfunction, further swallowing-function assessment should be performed. When necessary, a multidisciplinary evaluation involving otolaryngology and rehabilitation medicine should be conducted to improve the specificity and safety of the tube-placement plan.

Although the Montgomery T-tube has unique advantages in maintaining long-term patency of the upper airway, it is nevertheless a foreign body retained in the airway for an extended period and carries risks of complications, including secretion retention, tube obstruction, granulation tissue proliferation, and local infection. In particular, in the setting of continued malignant tumor progression, tumor regrowth, irritation by the tube ends, and chronic inflammatory responses may all contribute to recurrent stenosis at the tube ends or around the stenotic segment [11–12]. Therefore, during follow-up, in addition to routinely intensifying airway humidification, standardizing suction procedures, and providing health education, clinicians should consider the patient's symptom changes and follow-up endoscopic findings. Bronchoscopic interventional techniques, such as cryotherapy, argon plasma coagulation, and high-frequency electrosurgery, should be applied promptly when appropriate to remove granulation tissue or restore luminal patency, thereby maintaining airway patency and prolonging the efficacy of T-tube treatment [13].

At present, clinical studies related to Montgomery T-tubes have primarily focused on benign tracheal stenosis, tracheomalacia, and complex subglottic stenosis, whereas studies on malignant airway

stenosis remain limited. Compared with benign stenosis, malignant stenosis is characterized by more rapid disease progression, more complex mechanisms of obstruction, and a higher risk of tumor-related bleeding. In addition, patients differ substantially in expected survival and subsequent treatment plans. Therefore, the long-term outcomes of tube placement in patients with benign stenosis cannot be directly extrapolated to those with malignant airway stenosis. The present study provides preliminary clinical data on the use of T-tubes for malignant airway stenosis. Treatment efficacy in these patients should be comprehensively evaluated with attention to airway recanalization, relief of dyspnea, duration of T-tube patency, incidence of complications, and the feasibility of subsequent antitumor treatment.

In conclusion, the Montgomery T-tube may serve as an airway-support option for selected patients with malignant airway stenosis, particularly those with lesions located in the subglottic region or upper trachea who have undergone tracheostomy and require ongoing airway management. It can rapidly restore and maintain airway patency, relieve dyspnea, and improve ventilation and oxygenation, thereby creating favorable conditions for subsequent comprehensive antitumor treatment. Strict adherence to indications, accurate selection of the T-tube size, and strengthened postoperative airway humidification, secretion-clearance management, and bronchoscopic follow-up are essential for ensuring treatment efficacy and reducing complications.

At present, relatively few studies have directly evaluated the use of Montgomery T-tubes for malignant airway stenosis, and their long-term efficacy and potential advantages over other airway stents require further validation. Future studies should include larger samples and multicenter, prospective designs, and should incorporate multidimensional outcomes—including survival, symptom improvement, functional status, and quality of life—to further clarify the appropriate patient population, optimal timing, and long-term clinical value of Montgomery T-tubes in the comprehensive treatment of malignant airway stenosis.

Abbreviations

mMRC modified Medical Research Council dyspnea scale

EAT-10 Eating Assessment Tool-10

VHI-10 Voice Handicap Index-10

KPS Karnofsky Performance Status

Declarations

Ethics approval and consent to participate

The present study was approved by the Ethics Committee of Gansu Provincial Second People's Hospital, which is affiliated with Gansu Provincial Second People's Hospital (approval No. GSSEY2026-KY001-12). The requirement for written informed consent was waived because of the retrospective nature of the

study. All study procedures were performed in accordance with relevant guidelines and regulations, including the Declaration of Helsinki.

Consent for publication

Not applicable.

Availability of data and materials

The data that support the findings of this study are available from the corresponding author upon reasonable request.All study procedures were performed in accordance with relevant guidelines and regulations.

Competing interests

The authors declare no competing interests.

Funding

This study was supported by the Longyuan Young Talents Program (Provincial Talent Work Leading Group Document No. 11 [2024]).

Author'contributions

AQCJ, RSX, WSZ, MB, performed data collection. YXY and LXP contributed to the study design and interpretation. KYC ,WSZ and MB performed the statistical analysis. KYC wrote the first draft of the manuscript. All authors were involved in manuscript preparation and approved the final draft.

Acknowledgements

Not applicable.

References

1. Ernst A, Feller-Kopman D, Becker HD, et al. Central airway obstruction. Am J Respir Crit Care Med. 2004;169:1278–97.
2. Choi S, Chaddha U. Narrative review of malignant central airway obstruction: management updates. J Thorac Dis. 2025;17:7390.
3. Hu HH, Wu FJ, Zhang JS, et al. Treatment of secondary benign airway stenosis after tracheotomy with Montgomery T-tube. Math Biosci Eng. 2019;16:7839–49.
4. Wu FJ, Yao YW, Chen EG, et al. Efficacy and safety profile of Montgomery T-tube implantation in patients with tracheal stenosis. Can Respir J. 2020;2020:2379814.
5. Mahmood K, Frazer-Green L, Gonzalez AV, et al. Management of central airway obstruction: an American College of Chest Physicians clinical practice guideline. Chest. 2025;167:283–95.

6. Scanagatta P, Inzirillo F, Naldi G, Giorgetta CE, Ravalli E, Ancona G, Cagnetti S. Long-term outcomes of interventional bronchoscopy for central airway obstruction in a single-center retrospective study: a subgroup analysis of malignant and benign lesions. J Clin Med. 2025;14:2155.
7. Chen DF, Chen Y, Zhong CH, et al. Long-term efficacy and safety of the Dumon stent for benign tracheal stenosis: a meta-analysis. J Thorac Dis. 2021;13:82.
8. Ozkul Y, Songu M, Ozturkcan S, et al. Is T-tube treatment effective in Meyer-Cotton grade 3 tracheal stenosis: long-term outcomes. Acta Otolaryngol. 2016;136:933–6.
9. Jin B, Wang J, Wang Y, et al. Efficacy and safety of Montgomery T-tube placement in the treatment of benign complex subglottic tracheal stenosis: an analysis of 29 cases. Chin J Tuberc Respir Dis. 2021;44:1064–70.
10. Bibas BJ, Terra RM, Minamoto H, Cardoso PFG, Cremonese MR, Elias JP, et al. Risk factors for complications after Montgomery T-tube placement in benign tracheal stenosis: results from a prospective study. Ann Thorac Surg. 2026;121:321–8.
11. Muraleedharan M, Ramavat AS, Bakshi J, et al. Duration of stenting with Montgomery T-tubes in severe laryngotracheal stenosis: does it matter? J Laryngol Otol. 2022;136:354–9.
12. Roodenburg SA, Pouwels SD, Slebos DJ. Airway granulation response to lung-implantable medical devices: a concise overview. Eur Respir Rev. 2021;30:161.
13. Halawa ARR, Farooq S, Amjad MA, et al. Role of interventional pulmonology in intensive care units: a scoping review. World J Crit Care Med. 2025;14:99654.

Figures

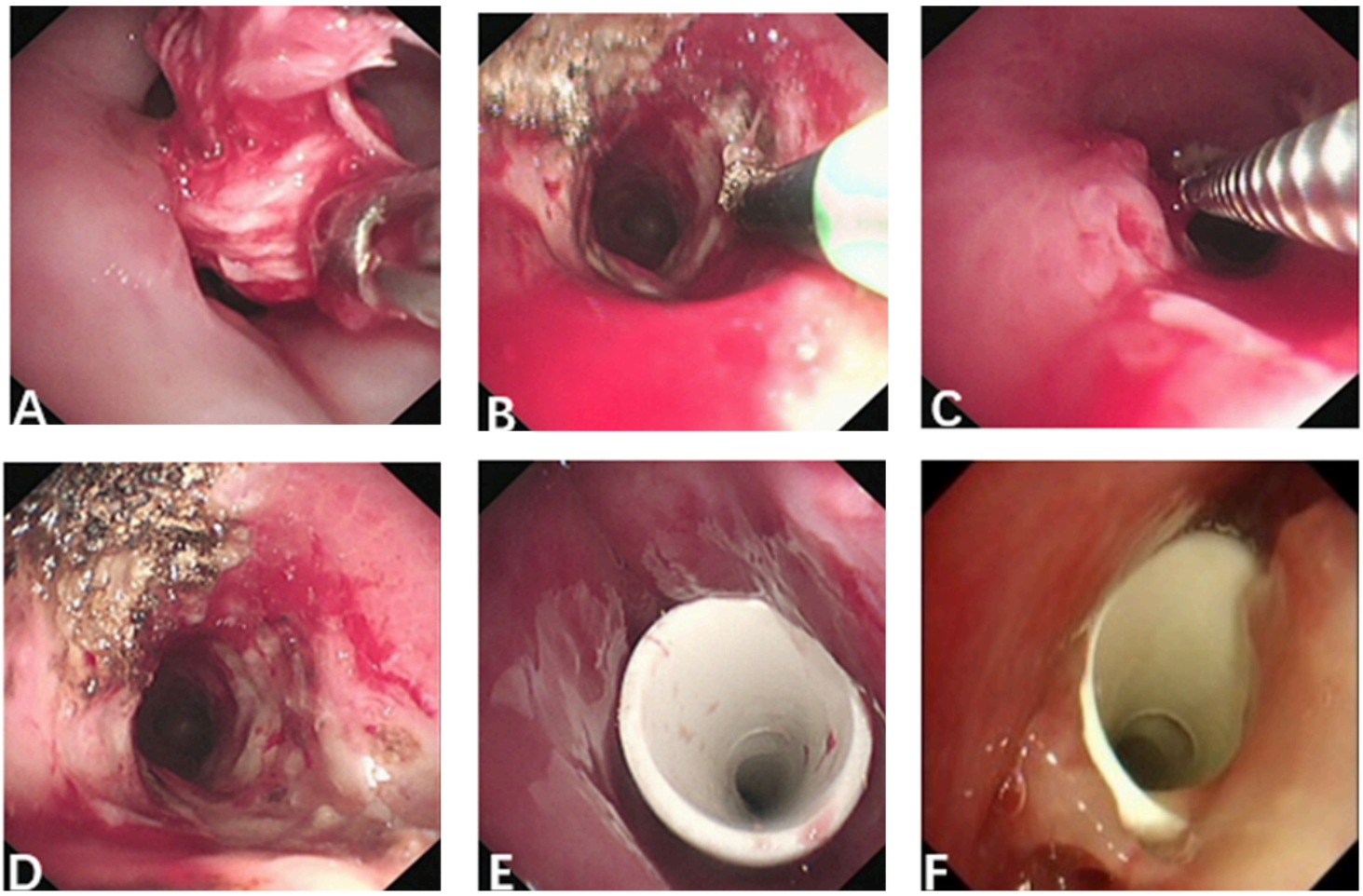

Figure 1

Bronchoscopic treatment and placement of the Montgomery T-tube.A: Tumor invasion of the upper tracheal wall; B: High-frequency electrocautery under bronchoscopic guidance; C: Resection of tumor tissue using the outer sheath of a rigid bronchoscope; D: Restoration of tracheal lumen patency after treatment; E: Appearance after T-tube placement; F: Follow-up bronchoscopy 3 days after T-tube placement.

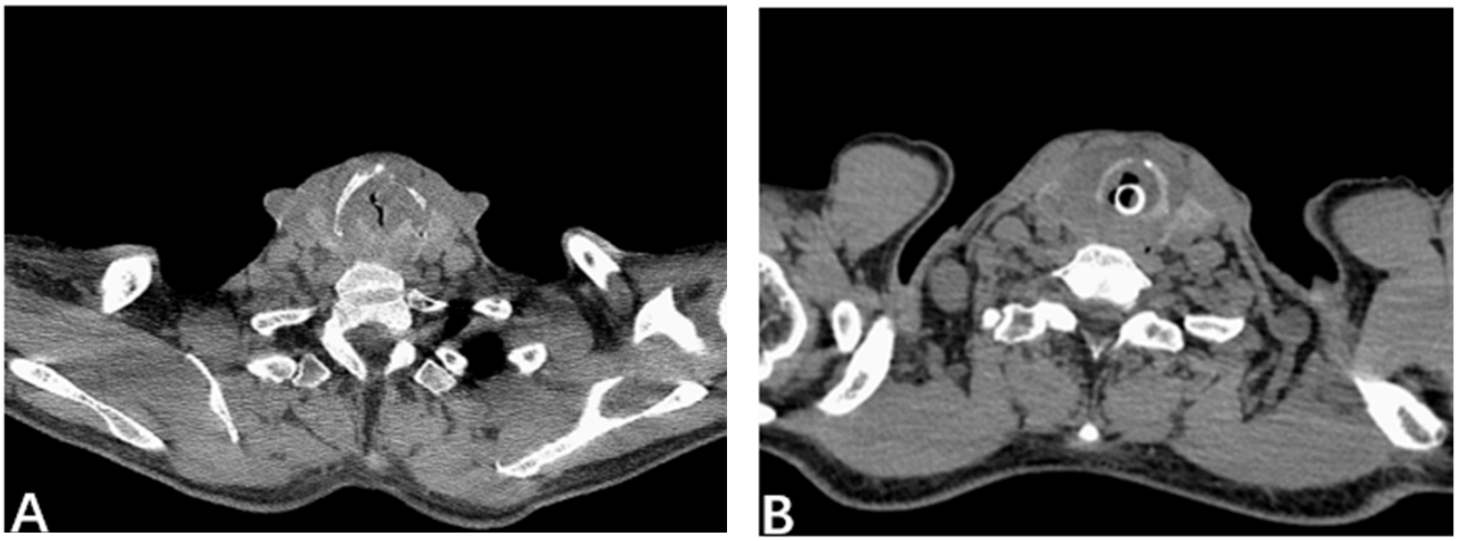

Figure 2

Comparison of computed tomography (CT) images before and after treatment.A: CT image before treatment; B: CT image after treatment.