Research Square

Preprints are preliminary reports that have not undergone peer review.
They should not be considered conclusive, used to inform clinical practice,
or referenced by the media as validated information.

Group B Streptococcus (Streptococcus agalactiae) bacteremia following arthroscopic anterior cruciate ligament reconstruction: a case report

Li Jingyuan
Air Force General Hospital PLA
Dong Chu
Air Force General Hospital PLA
Jing Xue
drxuejing@163.com

Air Force General Hospital PLA
Hongxing Zhang
Air Force General Hospital PLA
Zhiqiang Chen
Air Force General Hospital PLA

Case Report

Keywords: Group B Streptococcus, Streptococcus agalactiae, Anterior cruciate ligament reconstruction, Bacteremia, Surgical site infection, Clindamycin

Posted Date: November 25th, 2026

DOI: https://doi.org/10.21203/rs.3.rs-11500687/v1

License: This work is licensed under a Creative Commons Attribution 4.0 International License.
Read Full License

Additional Declarations: No competing interests reported.

Abstract

Background

Postoperative infection following arthroscopic anterior cruciate ligament reconstruction (ACLR) is a rare but serious complication, and Group B Streptococcus (GBS; Streptococcus agalactiae) has exceptionally rarely been implicated. We report a case of GBS bacteremia occurring after arthroscopic ACLR in a previously healthy young man, in a distinctive epidemiological context: his spouse had delivered their second child approximately 40 days before his admission, and clindamycin had been used for surgical prophylaxis because of a documented cefuroxime allergy.

Case presentation:

A 39-year-old Chinese man with a complete right anterior cruciate ligament rupture underwent uneventful arthroscopic single-bundle ACLR using a quadrupled hamstring tendon graft. Fever and leukocytosis developed on postoperative day 3, and blood cultures subsequently grew S. agalactiae that was resistant to the clindamycin used for perioperative prophylaxis. Despite sequential empirical regimens (vancomycin; vancomycin plus piperacillin–tazobactam; linezolid) together with arthroscopic joint debridement and lavage, fever and inflammatory markers persisted until high-dose combination therapy with vancomycin and penicillin was administered, after which the patient defervesced and all inflammatory markers normalized. He was discharged after 2 weeks of penicillin therapy with a well-functioning knee and no evidence of residual infection.

Conclusions

GBS is a rare but potentially significant pathogen of bacteremia after ACLR. Recent childbirth in the patient's spouse and clindamycin-based surgical prophylaxis may represent under-recognized risk factors. When GBS infection is confirmed, penicillin-based therapy is effective, and this case highlights the potential inadequacy of clindamycin prophylaxis in patients with specific GBS exposure risks.

Background

Streptococcus agalactiae, commonly known as Group B Streptococcus (GBS), is a Gram-positive, facultatively anaerobic coccus that typically colonizes the gastrointestinal and genitourinary tracts of healthy adults [1].

While GBS has traditionally been recognized as a leading cause of perinatal infections, including early-onset and late-onset neonatal sepsis, pneumonia, and meningitis, as well as chorioamnionitis and postpartum endometritis in pregnant women, its significance as an emerging pathogen in non-pregnant adults has gained increasing attention over the past two decades [3–6].

In the last two decades, the implementation of GBS screening and risk-based intrapartum chemoprophylaxis has significantly reduced neonatal and maternal mortality. However, a remarkable increase in GBS invasive infection in immunocompromised non-pregnant adults has been observed [8].

In recent years, invasive GBS infection presenting as bacteremia has shown an upward trend. This phenomenon is supported by a study conducted in Latin America that comprehensively evaluated all cases of GBS infection over a 17-year period; the proportion of bacteremia associated with GBS increased from 37% (1994–2001) to 60% (2004–2012), and among bacteremia episodes, adult patients accounted for 35.3% of isolates in the first period versus 70.2% in the second [7].

We report a case of bacteremia after arthroscopic ACLR due to GBS. To the best of the authors' knowledge, this combination has not previously been reported in the English-language literature.

Case presentation

Patient information and clinical findings

A 39-year-old Chinese man, a current smoker (20 pack-years) with no remarkable past medical history, was admitted to our department on 16 March 2021 because of pain and swelling of the right knee persisting for more than 3 months after trauma. Notably, his spouse had given birth to their second child approximately 40 days before his admission. On examination, his body mass index was 28.4 kg/m^2; the right knee had a range of motion of 0–150°, with positive Lachman and anterior drawer tests.

Diagnostic assessment

Laboratory tests revealed elevated serum uric acid, total cholesterol, triglycerides, and low-density lipoprotein cholesterol; other routine tests were unremarkable. Magnetic resonance imaging showed a complete rupture of the anterior cruciate ligament (ACL), a grade III tear of the posterior horn of the medial meniscus, and a grade II tear of the lateral meniscus. The preoperative diagnosis was rupture of the right ACL. Preoperative antibiotic skin testing suggested allergy to cefuroxime sodium; clindamycin was therefore substituted as the agent for surgical antimicrobial prophylaxis.

Therapeutic intervention

On 22 March 2021, arthroscopic single-bundle ACL reconstruction of the right knee was performed under general anesthesia using a quadrupled hamstring tendon graft. The femoral end of the graft was fixed with suspensory fixation (TightRope RT, Arthrex, Naples, FL, USA), and the tibial end was fixed with a biocomposite interference screw (Arthrex, Naples, FL, USA). The procedure was uneventful.

Postoperative course and follow-up

On postoperative day (POD) 3, the patient developed fever (maximum 38.5°C); the WBC was 15.81 × 10^9/L. Blood cultures were drawn, and vancomycin (1 g every 12 hours) was started. Fever peaked at 39.0°C during the night, accompanied by notable pain around the knee incisions with local warmth and moderate swelling.

Two days later, the blood culture flagged Gram-positive cocci in clusters; Streptococcus agalactiae was subsequently isolated and found to be resistant to clindamycin, the agent used for perioperative prophylaxis. Penicillin was initially planned but was withheld after a positive penicillin skin test.Antimicrobial therapy was escalated to vancomycin combined with piperacillin–tazobactam. Erythema subsequently appeared over the anteromedial aspect of the knee; routine wound care revealed a serous, non-turbid, odorless exudate from the medial arthroscopic portal. The skin sutures were removed and gentamicin-soaked dressings were applied; fungal, anaerobic, and routine bacterial cultures of the puncture fluid and exudate(Fig. 1). later showed no growth.

Gross appearance of the knee joint aspirate and surgical incision exudate. Hemorrhagic (blood-tinged) synovial fluid obtained by arthrocentesis of the right knee; serosanguineous discharge from the surgical incision. No purulent exudate or obvious signs of infection were observed.

From POD 9 to 12, the patient had intermittent nocturnal fever (up to 39.0°C). The draining portal had healed without exudate, the knee was not obviously swollen, and the surgical incisions were well healed with no definite per-articular tenderness; however, the morning leukocyte count was 15.65 × 10^9/L and high-sensitivity C-reactive protein was 74.29 mg/L. Joint aspiration was performed and sent for bacterial culture (which later showed no growth), and on the same day the patient underwent (1) arthroscopic debridement of the knee joint with indwelling tube irrigation and drainage, and (2) debridement and drainage of the tibial surgical incision.

Intraoperatively, marked hemarthrosis was noted, with congested and edematous synovium covered by a layer of dark-red coagulum and intra-articular blood clots, but no purulent exudate(Fig. 2). The reconstructed ACL was continuous and intact, and both menisci were well preserved. The joint was irrigated with a total of 45,000 mL of saline containing gentamicin, and shaver and radiofrequency devices were used to clear clots and inflammatory tissue; inflamed tissue was sent for pathological examination. After hemostasis, an accessory incision was made superolateral to the knee and a drainage tube was placed. The original sutures of the incision medial to the tibial tubercle were removed, a 2-mm rim of skin edge was excised, and the tibial incision was found to communicate with the accessory arthroscopic portal; the surrounding inflamed subcutaneous tissue was completely excised and the area irrigated, and a subcutaneous drainage tube was placed inferomedial to the tibial tubercle. Piperacillin and vancomycin were continued postoperatively as combined anti-infective therapy.

Intraoperative arthroscopic view of the knee. The reconstructed anterior cruciate ligament (ACL) graft shows good tension with an intact surface, and no purulent exudate is observed.

On the second day after debridement, the patient again developed high fever (maximum 40.0°C) with rising leukocyte and C-reactive protein levels. Combined piperacillin and vancomycin was considered ineffective and was discontinued; after a 24-hour washout interval, therapy was switched to linezolid. Nocturnal fever nevertheless persisted (up to 38.8°C). Following a hospital-wide and multidisciplinary consultation, high-dose vancomycin combined with penicillin was administered, after which the body temperature and infection markers returned to normal.

Seven days after debridement, the treatment was judged effective: vancomycin was discontinued and penicillin was continued for 2 weeks. During this period, no signs of infection were observed, routine blood tests and inflammatory markers remained normal, and the patient was discharged. At discharge and throughout the approximately two-year follow-up period, the patient's infection-related markers remained within normal limits, the surgical incision healed uneventfully, and long-term joint function met expectations. Follow-up MRI(Fig. 3). at 12 months postoperatively demonstrated favorable signal intensity of the reconstructed ligament.

Follow-up magnetic resonance imaging (MRI) of the right knee at 12 months postoperatively. Sagittal/coronal, T2-weighted fat-suppressed images show the integrity of the reconstructed ACL graft, with no obvious joint effusion or signs of recurrent infection.

Timeline of the postoperative course

Date / time point	Event	Intervention
16 Mar 2021	Admission: right knee pain and swelling > 3 months after trauma	History, examination, MRI, laboratory tests
22 Mar 2021 (surgery)	Arthroscopic single-bundle ACLR with quadrupled hamstring graft	Clindamycin prophylaxis (cefuroxime allergy)
POD 3	Fever 38.5–39.0°C; WBC 15.81 × 10^9/L	Blood cultures × 2; vancomycin 1 g q12h
POD 5	Blood culture: Gram-positive cocci; later S. agalactiae, clindamycin-resistant; local portal exudate (serous)	**penicillin allergy**, Vancomycin + piperacillin–tazobactam; suture removal, gentamicin dressings; exudate cultures (no growth)
POD 9–12	Intermittent nocturnal fever up to 39.0°C; WBC 15.65 × 10^9/L; CRP 74.29 mg/L	Joint aspiration for culture (no growth); arthroscopic debridement + lavage (45,000 mL), drainage tubes placed
Debridement + 2 d	Fever up to 40.0°C; rising inflammatory markers	Discontinue piperacillin/vancomycin; linezolid
Debridement + 3–6 d	Persistent nocturnal fever up to 38.8°C	Multidisciplinary consultation; high-dose vancomycin + penicillin
Debridement + 7 d → discharge	Afebrile; inflammatory markers normalized	Vancomycin stopped; penicillin continued 2 weeks; discharge

Discussion

Postoperative infection following ACLR is a rare but serious complication, with reported incidence rates ranging from 0.32% to 1.8%, and recent large series have demonstrated infection rates declining to below 0.4% [9, 10]. Within the pathogen spectrum of ACLR infections, coagulase-negative staphylococci and Staphylococcus aureus are the most common causative organisms [11], while anaerobes, Gram-negative bacteria, and streptococci are involved with lower frequency [12]. Streptococcal species, including GBS, are extremely rarely reported in ACLR postoperative infections.

GBS bacteremia is even rarer after orthopedic surgery, as most postoperative GBS infections are typically associated with localized inflammatory responses at the surgical site, such as septic arthritis or wound infections [13], and GBS has been reported to cause septic arthritis after total knee arthroplasty. The distinctive feature of the present case is the presentation as primary bacteremia without definitive evidence of surgical site infection: the patient exhibited almost no knee joint redness, swelling, heat, or pain; there was no wound drainage; and joint fluid cultures were negative. This suggests that the pathogen likely entered the bloodstream through transient bacteremia rather than through direct colonization or infection of the surgical site.

Peripartum spousal transmission of GBS

An important epidemiological feature of this case is that the patient's spouse delivered their second child approximately 40 days before his admission, suggesting that the patient may have acquired GBS colonization through his spouse and subsequently developed invasive infection following surgery.

GBS primarily colonizes the human gastrointestinal and genitourinary tracts, with approximately 15–40% of healthy adult women demonstrating vaginal or rectal GBS colonization [14]. In postpartum women, GBS colonization rates may change because of antibiotic exposure during delivery; intrapartum antibiotic prophylaxis can significantly reduce the maternal vaginal GBS load but does not completely eradicate colonization [15]. Day 40 postpartum falls within the puerperal recovery period, and the puerperium confers a markedly elevated risk of invasive GBS infection (20-fold), substantially surpassing the 2-fold increase observed during pregnancy [17]; the spouse may therefore still have carried GBS at the time of the patient's surgery.

GBS transmission between sexual partners has been documented in the literature. Although GBS is not considered a classic sexually transmitted pathogen, studies have demonstrated that GBS can be transmitted between partners through close physical contact, including sexual activity [16]. Beyond sexual transmission, close daily contact (such as shared sanitary facilities and skin contact) may also facilitate GBS transmission. After gastrointestinal colonization, GBS can serve as a persistent reservoir, triggering invasive disease when host immune function is compromised.

In this case, no postpartum fever, endometritis, or other infectious manifestations were reported in the spouse; however, postpartum asymptomatic GBS bacteriuria or mild endometritis may go unrecognized. If the spouse had undiagnosed GBS infection, the patient, as a close contact exposed to a high-load GBS environment, would face a significantly increased infection risk. Although male genitourinary GBS colonization is typically asymptomatic, colonizing organisms may enter the bloodstream and cause bacteremia under conditions of surgical stress or transient immunosuppression.

Limitations of clindamycin as surgical prophylaxis

The patient demonstrated allergy to cefuroxime sodium on preoperative antibiotic skin testing, prompting substitution of clindamycin for surgical infection prophylaxis. This modification of the antimicrobial regimen may be associated with the occurrence of GBS bacteremia in this case.

GBS maintains universal susceptibility to β-lactams (ampicillin, cephalosporins, and carbapenems). For severe β-lactam allergy, clindamycin, macrolides, fluoroquinolones, or vancomycin may serve as alternatives, but these should only be used when β-lactams are contraindicated and susceptibility is confirmed [18–22]; vancomycin resistance has also been reported [23]. According to the CDC guidelines (subsequently updated by ACOG in 2020), for penicillin-allergic pregnant women with GBS colonization, clindamycin is recommended for intrapartum antibiotic prophylaxis only when clindamycin susceptibility

has been confirmed [24]. The resistance rate of GBS to clindamycin varies significantly across regions and populations, with overall rates of approximately 15–30% [24, 25].

In a large cohort study, clindamycin demonstrated effectiveness similar to that of cephalosporins in preventing infection-related revision after cemented primary total knee arthroplasty [28]. However, while clindamycin is recommended as an alternative agent for surgical prophylaxis in patients with β-lactam allergies, limited data are available regarding its efficacy against specific organisms such as GBS in the orthopedic setting; cephalosporins offer superior coverage against GBS and should remain the preferred choice when β-lactam antibiotics are not contraindicated [27].

The pharmacokinetic properties of clindamycin may also compromise its prophylactic efficacy. Clindamycin has a half-life of approximately 2.5–3 hours; when administered 30–60 minutes before surgical incision, redosing is required if the procedure exceeds 3–4 hours [26].

This case suggests that for patients with cephalosporin allergy undergoing implant-related surgery such as ACL reconstruction, if a GBS exposure risk exists (e.g., recent postpartum GBS carriage in the spouse), clindamycin alone as prophylaxis may be insufficient. In such circumstances, the following alternatives may be considered: (1) switching to an alternative broad-spectrum antimicrobial agent for surgical prophylaxis; and (2) intraoperative use of a vancomycin-soaked graft, which has been reported to reduce the postoperative infection rate after ACLR to 0% [29].

Mechanisms of primary postoperative GBS bacteremia

This case presented with primary GBS bacteremia without definitive evidence of surgical site infection. Two mutually non-exclusive mechanisms merit discussion.

Selective pressure of clindamycin. Clindamycin prophylaxis may have exerted a “selective effect” on the occurrence of GBS bacteremia in this case. If the patient had pre-existing clindamycin-resistant GBS colonization, clindamycin prophylaxis would not only fail to eradicate the colonizing organisms but might also suppress other susceptible bacterial populations, leading to dominance of resistant GBS. Clindamycin demonstrates antimicrobial activity against Gram-positive organisms (including staphylococci and streptococci) but has relatively limited impact on intestinal Gram-negative bacteria [30]. This selective spectrum may have altered the patient’s postoperative intestinal microbiota, allowing GBS to overgrow in the intestine and increasing the risk of translocation across the intestinal barrier into the bloodstream.

Surgical stress–induced immunosuppression. Postoperative immunosuppression arises from multifactorial mechanisms initiated by surgical trauma. Activation of the hypothalamic–pituitary–adrenal and sympathetic–adrenal–medullary axes promotes the release of glucocorticoids and catecholamines, resulting in immunosuppression [31]. Concurrently, cell-mediated immunity is compromised through reduced $CD8^+$ T-cell proliferation, downregulated T-cell receptor expression, and diminished antigen-presenting capacity of monocytes [32]. Innate immunity is similarly affected, with

reduced natural killer cell cytotoxicity and neutrophil dysfunction persisting for 48–72 hours postoperatively [33]. This immunosuppressive state provides an opportunity for opportunistic pathogens such as GBS to invade and proliferate.

Diagnosis and treatment

In our patient, GBS bacteremia after arthroscopic ACLR was diagnosed on the basis of elevated inflammatory markers (C-reactive protein and leukocytosis) in blood, with blood cultures playing a decisive role in identifying the causative organism. Once the organism was isolated, the patient received combined coverage with piperacillin and vancomycin; however, the clinical response was suboptimal, with poor infection control. He ultimately received penicillin-class antibiotic therapy based on susceptibility results, with a favorable outcome. This suggests that for patients with cefuroxime sodium allergy (which may represent cross-reactivity), penicillin-class antibiotics may be attempted under close monitoring once GBS infection is confirmed.

Clinical implications

This case suggests that for surgical patients whose spouses have recently delivered (particularly within 3 months postpartum), vigilance for GBS infection risk is warranted. Preoperative history-taking should include detailed inquiry regarding the spouse's pregnancy outcome, delivery mode, intrapartum antibiotic usage, and postpartum recovery. For such patients with cephalosporin and penicillin allergy who require alternative agents for prophylaxis, consideration may be given to adding antibiotics that cover GBS (such as vancomycin) or employing an intraoperative vancomycin-soaked graft technique.

Conclusion

GBS is an exceptionally rare but potentially significant cause of bacteremia after arthroscopic ACLR. Recent childbirth in the patient's spouse may constitute an under-recognized epidemiological exposure, and clindamycin-based prophylaxis may be inadequate when specific GBS exposure risks exist. Blood cultures are essential for patients with postoperative fever, and once GBS is confirmed, penicillin-based therapy is effective. Surgeons should take a targeted history of household peripartum exposure and consider GBS-active prophylaxis in high-risk patients with β-lactam allergy.

Declarations

Ethics approval and consent to participate:

All enrolled patients signed informed consent forms and expressed sup- port for our study. This study was complied with the Declaration of Helsinki and was approved by the committee on the ethics of medicine, Air Force Medical Center of PLA.

Consent for publication:

Written informed consent was obtained from the patient for publication of this case report and any accompanying images.

Competing interests:

The authors declare that they have no competing interests.

Funding:

This research received no external funding.

Author Contribution

Jingyuan Li,Jing Xue: Conceptualization, Writing – original draft. Jing Xue,Dong Chun: Investigation, Data curation. Hongxing Zhang: Writing – review & editing.Zhiqiang Chen: Supervision, Project administration. All authors read and approved the final manuscript.

Availability of data and materials:

All data generated or analyzed during this case are included in this article. Further details are available from the corresponding author on reasonable request.

References

1. Lancefield RC. A serological differentiation of human and other groups of hemolytic streptococci. J Exp Med. 1933;57:571–95. 10.1084/jem.57.4.571.
2. Fry RM. Fatal infections by hemolytic streptococcus group B. Lancet. 1938;1:199–201.
3. Braunstein H, Tucker EB, Gibson BC. Identification and significance of Streptococcus agalactiae (Lancefield group B). Am J Clin Pathol. 1969;51:207–13. 10.1093/ajcp/51.2.207.
4. Eickhoff TC, Klein JO, Daly AK, Ingall D, Finland M. Neonatal sepsis and other infections due to group B beta-hemolytic streptococci. N Engl J Med. 1964;271:1221–8. 10.1056/NEJM196412102712401.
5. Lazarus JM, Sellers DP, Marine WM. Meningitis due to the group B beta-hemolytic Streptococcus. N Engl J Med. 1965;272:146–7. 10.1056/NEJM196501212720308.
6. Mannik M, Baringer JR, Stokes J III. Infections due to group B beta-hemolytic streptococci. Report of three cases and review of the literature. N Engl J Med. 1962;266:910–3. 10.1056/NEJM196205032661803.
7. Crespo-Ortíz Mdel P, Castañeda-Ramírez CR, Recalde-Bolaños D, Vélez-Londoño JD. Emerging trends in invasive and noninvasive isolates of Streptococcus agalactiae in a Latin American

hospital: a 17-year study. BMC Infect Dis. 2014;14:428.

8. Schrag SJ, Zywicki S, Farley MM, Reingold AL, Harrison LH, Lefkowitz LB, Hadler JL, Danila R, Cieslak PR, Schuchat A. Group B streptococcal disease in the era of intrapartum antibiotic prophylaxis. N Engl J Med. 2000;342:15–20.
9. Septic arthritis after. anterior cruciate ligament reconstruction: microbiological epidemiology, treatment, and outcome: a 95 case series among 12,650 patients. Clin Surg J. 2022. [Authors/journal details to be completed].
10. ESSKA and EBJIS recommendations for the. management of infections after anterior cruciate ligament reconstruction (ACL-R): prevention, surgical treatment and rehabilitation. Knee Surg Sports Traumatol Arthrosc. 2023. [Authors/details to be completed].
11. Renz N, Madjarevic T, Ferrari M, et al. Recommendations on diagnosis and antimicrobial treatment of infections after anterior cruciate ligament reconstruction (ACL-R) endorsed by ESSKA and EBJIS. J Infect. 2023;86(6):543–51. 10.1016/j.jinf.2023.03.021.
12. Balato G, Ascione T, Iorio P, et al. Knee septic arthritis caused by α-hemolytic Streptococcus in a patient with a recent history of knee arthroscopy: a case report. BMC Infect Dis. 2019;19(1):887. 10.1186/s12879-019-4556-4.
13. Diarra A, Gachet B, Beltrand E, et al. Outcomes in orthopedic device infections due to Streptococcus agalactiae: a retrospective cohort study. BMC Infect Dis. 2024;24(1):424. 10.1186/s12879-024-09175-6.
14. Group B. streptococcal maternal colonization and neonatal disease: molecular mechanisms and preventative approaches. Front Pediatr. 2018. [Authors/details to be completed].
15. A case of. late-onset group B Streptococcus infection in fraternal twins. Contemporary Pediatrics. [Year/pages to be completed].
16. Sexual transmission and reinfection of group B streptococci. Aust N Z J Obstet Gynaecol. 1999. [Authors/details to be completed].
17. Deutscher M, Lewis M, Zell ER, et al. Incidence and severity of invasive Streptococcus pneumoniae, group A Streptococcus, and group B Streptococcus infections among pregnant and postpartum women. Clin Infect Dis. 2011;53(2):114–23. 10.1093/cid/cir325.
18. Seki T, Kimura K, Reid ME, et al. High isolation rate of MDR group B streptococci with reduced penicillin susceptibility in Japan. J Antimicrob Chemother. 2015;70(10):2725–8. 10.1093/jac/dkv203.
19. Hawkins PA, Law CS, Metcalf BJ, et al. Cross-resistance to lincosamides, streptogramins A and pleuromutilins in Streptococcus agalactiae isolates from the USA. J Antimicrob Chemother. 2017;72(7):1886–92.
20. Wehbeh W, Rojas-Diaz R, Li X, et al. Fluoroquinolone-resistant Streptococcus agalactiae: epidemiology and mechanism of resistance. Antimicrob Agents Chemother. 2005;49(6):2495–7. 10.1128/AAC.49.6.2495-2497.2005.

21. Hays C, Louis M, Plainvert C, et al. Changing epidemiology of group B Streptococcus susceptibility to fluoroquinolones and aminoglycosides in France. Antimicrob Agents Chemother. 2016;60(12):7424–30.
22. Piccinelli G, Gargiulo F, Corbellini S, et al. Emergence of the first levofloxacin-resistant strains of Streptococcus agalactiae isolated in Italy. Antimicrob Agents Chemother. 2015;59(4):2466–9. 10.1128/AAC.05127-14.
23. Park SY, Park Y, Chung JW, et al. Group B streptococcal bacteremia in non-pregnant adults: results from two Korean centers. Eur J Clin Microbiol Infect Dis. 2014;33(10):1785–90. 10.1007/s10096-014-2140-9.
24. Prevention of group B streptococcal. early-onset disease in newborns: ACOG Committee Opinion, Number 797. Obstet Gynecol. 2020;135(2):e51–72. 10.1097/AOG.0000000000003668.
25. Boyanov VS, Alexandrova AS, Hristova PM, Hitkova HY, Gergova RT. Antibiotic resistance and serotypes distribution in Streptococcus agalactiae Bulgarian clinical isolates during the years of 2021–2024. Pol J Microbiol. 2024;73(4):505–14. 10.33073/pjm-2024-042.
26. Bratzler DW, Dellinger EP, Olsen KM, et al. Clinical practice guidelines for antimicrobial prophylaxis in surgery. Am J Health Syst Pharm. 2013;70(3):195–283. 10.2146/ajhp120568.
27. Bratzler DW, Dellinger EP, Olsen KM, et al. Clinical practice guidelines for antimicrobial prophylaxis in surgery. Am J Health Syst Pharm. 2013;70(3):195–283. 10.2146/ajhp120568. [duplicate of reference 26 — to be consolidated].
28. Pawloy K, Fenstad AM, Leta T, et al. No difference in risk of revision due to infection between clindamycin and cephalosporins as antibiotic prophylaxis in cemented primary total knee replacements: a report from the Norwegian Arthroplasty Register 2005–2020. Acta Orthop. 2023;94:404–9. 10.2340/17453674.2023.16907.
29. Carney J, Heckmann N, Mayer EN, et al. Should antibiotics be administered before arthroscopic knee surgery? A systematic review of the literature. World J Orthop. 2018;9(11):262–70. 10.5312/wjo.v9.i11.262.
30. Mohiuddin M. Chronic antibiotic use, gut microbiota dysbiosis, and increased risk of colorectal cancer: an emerging threat. Health Sci Rep. 2026;9(2):e71866. 10.1002/hsr2.71866.
31. Acharya K, Rout DK, Kapadia NA, et al. Surgical stress response: a physiological review of the endocrine, immune, and metabolic changes. Cureus. 2025;17(12):e100101. 10.7759/cureus.100101.
32. Angele MK, Faist E. Clinical review: immunodepression in the surgical patient and increased susceptibility to infection. Crit Care. 2002;6(4):298–305. 10.1186/cc1514.
33. Amodeo G, Bugada D, Franchi S, et al. Immune function after major surgical interventions: the effect of postoperative pain treatment. J Pain Res. 2018;11:1297–305. 10.2147/JPR.S158230.

Figures



Figure 1

Gross appearance of the knee joint aspirate and surgical incision exudate. Hemorrhagic (blood-tinged) synovial fluid obtained by arthrocentesis of the right knee; serosanguineous discharge from the surgical incision. No purulent exudate or obvious signs of infection were observed.

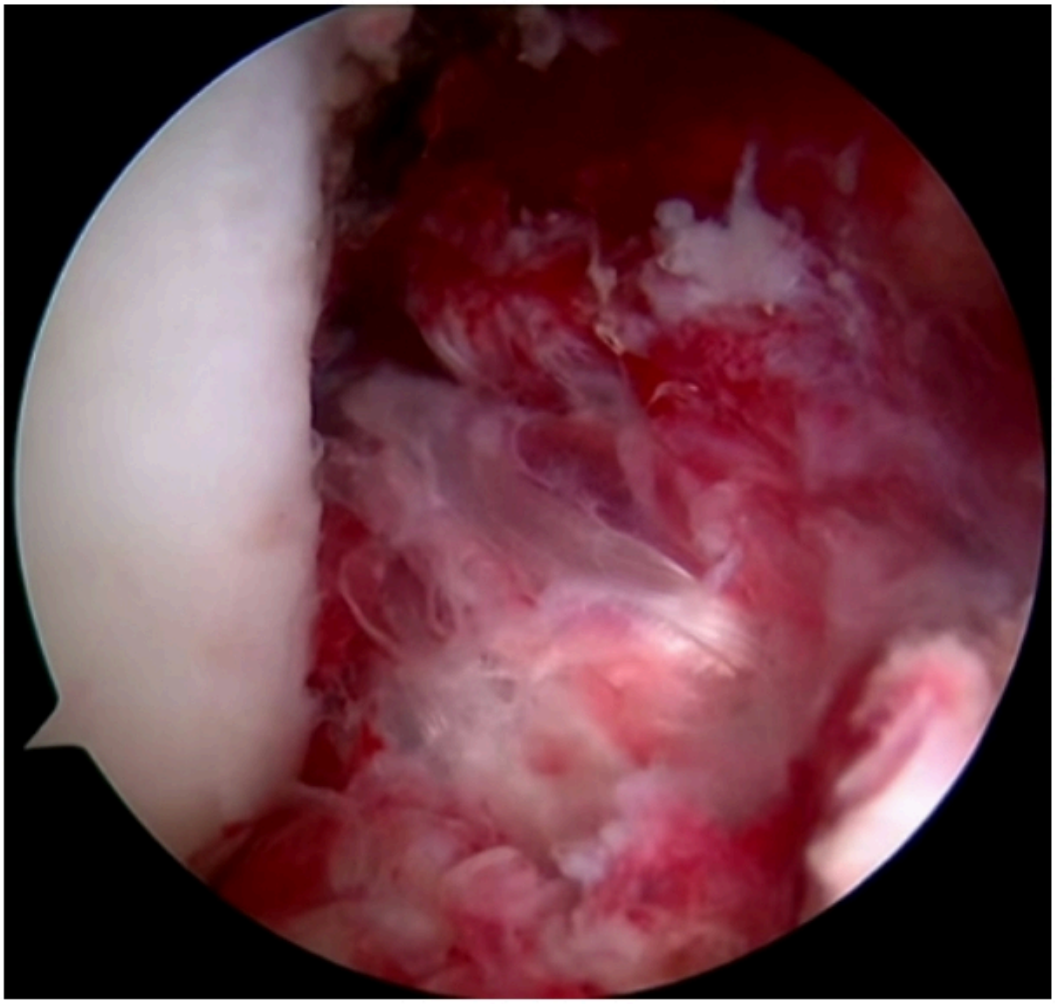

Figure 2

Intraoperative arthroscopic view of the knee. The reconstructed anterior cruciate ligament (ACL) graft shows good tension with an intact surface, and no purulent exudate is observed.

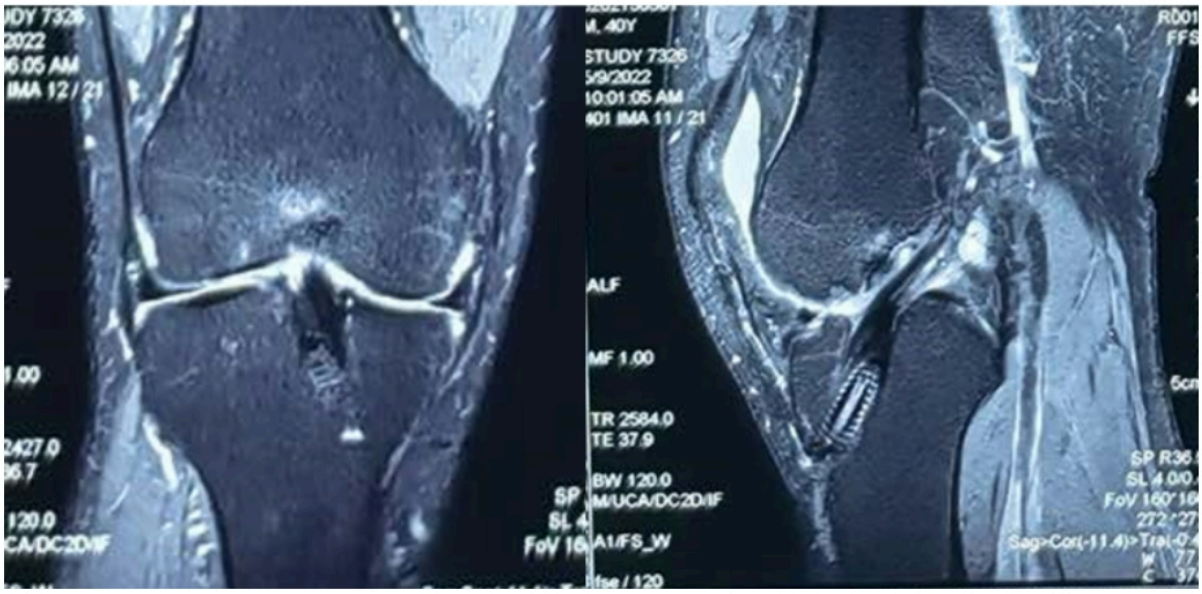

Figure 3

Follow-up magnetic resonance imaging (MRI) of the right knee at 12 months postoperatively. Sagittal/coronal, T2-weighted fat-suppressed images show the integrity of the reconstructed ACL graft, with no obvious joint effusion or signs of recurrent infection.