Research Square

Preprints are preliminary reports that have not undergone peer review.
They should not be considered conclusive, used to inform clinical practice,
or referenced by the media as validated information.

Early outcome trade-offs and radiographic placement surrogates after CCS versus cannulated screw fixation of femoral neck fractures

Jie Zhang
Department of Trauma, Beijing Fengsheng Hospital of Traditional Chinese Medicine Orthopedics and Traumatology, Beijing, China

Zixuan Zheng
Department of Trauma, Beijing Fengsheng Hospital of Traditional Chinese Medicine Orthopedics and Traumatology, Beijing, China

Yanxu Dong
Department of Trauma, Beijing Fengsheng Hospital of Traditional Chinese Medicine Orthopedics and Traumatology, Beijing, China

Yun Tong
Department of Trauma, Beijing Fengsheng Hospital of Traditional Chinese Medicine Orthopedics and Traumatology, Beijing, China

Likun Jin
Department of Trauma, Beijing Fengsheng Hospital of Traditional Chinese Medicine Orthopedics and Traumatology, Beijing, China

Ye Li
Department of Trauma, Beijing Fengsheng Hospital of Traditional Chinese Medicine Orthopedics and Traumatology, Beijing, China

Gongxu Yang
tcdyanggx@hbhtcm.com

Hubei Provincial Hospital of Traditional Chinese Medicine, Affiliated Hospital of Hubei University of Chinese Medicine, Wuhan, Hubei, China

Yuefeng Qi
Department of Trauma, Beijing Fengsheng Hospital of Traditional Chinese Medicine Orthopedics and Traumatology, Beijing, China

---

Research Article

Keywords: femoral neck fracture, internal fixation, angular-stable fixation, cannulated screws, cost, tip-apex distance, Harris Hip Score

Posted Date: November 25th, 2026

DOI: https://doi.org/10.21203/rs.3.rs-11432438/v1

License: This work is licensed under a Creative Commons Attribution 4.0 International License.
Read Full License

Additional Declarations: No competing interests reported.

Early outcome trade-offs and radiographic placement surrogates after CCS versus cannulated screw fixation of femoral neck fractures

Jie Zhang[1#]; Zixuan Zheng[1#]; Yanxu Dong[1]; Yun Tong[1]; Likun Jin[1]; Ye Li[1]; Gongxu Yang2*; Yuefeng Qi[1]*

[1] Department of Trauma, Beijing Fengsheng Hospital of Traditional Chinese Medicine Orthopedics and Traumatology, Beijing, China

[2] Hubei Provincial Hospital of Traditional Chinese Medicine, Affiliated Hospital of Hubei University of Chinese Medicine, Wuhan, Hubei, China

#These authors contributed equally to this work.

* Corresponding authors: Gongxu Yang, tcdyanggx@hbhtcm.com;

Yuefeng Qi, yunzhong.ri@163.com

Abstract

Background: Angular-stable constructs are increasingly used for femoral neck fracture fixation, but their early clinical advantages must be interpreted alongside operative burden, cost, and the uncertain value of radiographic placement metrics. We compared early outcomes, treatment burden, and radiographic placement surrogates between an angular-stable composite compression system (CCS) and conventional cannulated screws (CS). **Methods:** We retrospectively reviewed 82 adults with femoral neck fractures treated with CCS (n = 41) or CS (n = 41) at a single centre between June 2022 and July 2025. Clinical outcomes, operative time, length of stay, total cost, and complications were compared in the full cohort. Post-operative anteroposterior radiographic placement surrogates (tip-apex surrogate and screw-shaft angle) were explored in multivariable models of the Harris Hip Score in 79 matched patients. **Results:** CCS was associated with higher Harris Hip Scores (90.2 vs 87.6; P = 0.011) and faster union (12.7 vs 14.7 weeks; P = 0.045) but required longer surgery (61.0 vs 49.4 min; P = 0.001) and higher total cost (44,630 vs 30,461 CNY; P < 0.001). Osteonecrosis and screw back-out were numerically less frequent after CCS but did not differ significantly. In exploratory regression, neither the tip-apex surrogate (P = 0.623) nor the screw-shaft angle (P = 0.848) predicted the Harris Hip Score, whereas CS remained associated with a lower score (base-model beta = -3.20; 95% CI, -4.79 to -1.61; P < 0.001). **Conclusions:** CCS fixation may offer better early function and faster union than cannulated screws, but at greater operative and economic cost. Simple anteroposterior radiographic placement surrogates did not explain the observed functional difference and should be interpreted cautiously across structurally different implants.

Keywords: femoral neck fracture; internal fixation; angular-stable fixation; cannulated screws; cost; tip-apex distance; Harris Hip Score

1. Background

Femoral neck fractures are common injuries with substantial functional, social, and economic consequences [1, 2]. In patients selected for femoral head preservation, internal fixation remains an important treatment strategy [3]. It avoids the morbidity of primary arthroplasty and preserves the option of later reconstruction if fixation subsequently fails [4]. Complications such as nonunion and osteonecrosis nonetheless remain common after femoral neck fractures in younger patients [5]. Three cannulated screws have long been a standard method for internal fixation [6]. This construct remains widely used in younger or physiologically active patients [7]. More recently, angular-stable femoral-neck constructs, including femoral-neck-system-type devices, have been adopted to improve resistance to shear, rotation, and femoral-neck shortening [8]. Femoral-neck shortening in particular is

associated with inferior hip function [9]. It occurs frequently after both screw and femoral-neck-system fixation [10].

Existing comparative studies suggest that femoral-neck-system-type fixation may provide better short-term outcomes than cannulated screws. Pooled analyses have reported higher functional scores [11]. Faster union has been described in cohort studies [12]. Fewer fixation-related complications have also been reported [13]. Yet these findings are drawn largely from retrospective cohorts with modest sample sizes and variable follow-up [14], and their clinical interpretation requires attention to trade-offs. Angular-stable constructs may improve early recovery, but they can also increase operative time and treatment cost. In addition, commonly used radiographic placement metrics, such as tip-apex distance and screw-shaft angle, may not have equivalent meaning across implants with different intrinsic geometry.

The present study was therefore designed around three linked questions rather than a single implant-versus-placement dichotomy. We first compared early clinical outcomes after composite compression system (CCS) and cannulated screw (CS) fixation. We then examined the trade-off between clinical benefit and treatment burden, focusing on operative time and total cost. Finally, as an exploratory analysis, we tested whether pragmatic anteroposterior radiographic placement surrogates were associated with the Harris Hip Score and whether they materially changed the association between construct type and function. This design treats radiographic geometry as a secondary explanatory layer, not as a perfectly homologous measure across different implants.

2. Methods

This study was designed and is reported in accordance with the STROBE statement for observational studies [15]. It was approved by the institutional review board of Beijing Fengsheng Hospital of Traditional Chinese Medicine Orthopedics and Traumatology (FSLL2026-01); the requirement for informed consent was waived owing to the retrospective design.

Study design and participants

We retrospectively reviewed consecutive adult patients who underwent internal fixation of a femoral neck fracture at a single tertiary centre between June 7, 2022, and July 4, 2025, according to the recorded surgery dates. Inclusion criteria were age 18 years or older, a femoral neck fracture (AO/OTA 31B) treated with either an angular-stable construct or three cannulated screws, and available post-operative radiographs and follow-up records. Exclusion criteria were pathological fracture, multiple ipsilateral injuries, primary arthroplasty, and follow-up shorter than 3 months. The decision between constructs was made by the treating surgeon according to individual patient and fracture characteristics and was not randomized.

The final clinical cohort comprised 82 patients (CCS, n = 41; CS, n = 41). These patients were included in the comparison of clinical outcomes, operative time, length of stay, total cost, and complications. Post-operative placement geometry was aggregated at the patient level and linked to the clinical dataset by name and treatment group. Geometry was unambiguously matched to the clinical record in 79 patients (CCS, n = 38; CS, n = 41); three patients were excluded from the radiographic and regression analyses because the available identifiers did not permit unambiguous linkage between the annotated image and the clinical record. The fixation concepts and study workflow are shown in Figure 1.

Surgical implants and technique

CCS fixation used the Composite Compression System (Double Medical Technology Inc., Xiamen, China), an angular-stable, fixed-angle femoral neck construct conceptually analogous to the Femoral Neck System (FNS; DePuy Synthes). It comprises a tapered-thread compression screw (10.2 mm), an anti-rotation screw (6.0 mm) set at a manufacturer-fixed 5 degree divergence from the lag screw, a short lateral plate at a fixed 130 degree caput-collum-diaphyseal angle, and a transverse locking screw. The inter-screw angle and plate angle are determined by the implant and were therefore treated as construct properties rather than patient-level placement variables. CS fixation used three (6.5 mm) partially threaded cannulated screws placed in an inverted-triangle configuration. All procedures were performed under fluoroscopic guidance; post-operative rehabilitation followed a standardised protocol consisting of early ankle-pump and quadriceps exercises, progressive hip range-of-motion training, and protected ambulation with crutches or a walker. Partial weight-bearing was initiated after early post-operative pain control and radiographic confirmation of stable fixation, and weight-bearing gradually advanced according to fracture healing, implant stability, and the treating surgeon's assessment during follow-up. Representative pre-operative and immediate post-operative radiographs of both constructs are shown in Figure 2.

Radiographic annotation and placement surrogates

Post-operative anteroposterior hip and pelvic radiographs were annotated with a purpose-built tool (line_annotator). Because some hip studies carried incorrect DICOM body-part labels, eligible views were identified by image content. For each radiograph, the screw axis and length, femoral shaft axis, femoral head centre and diameter, and the greater and lesser trochanters were marked. All annotations were performed by a single investigator and were then manually re-inspected; erroneous landmark placements, including the greater trochanter reference points, were corrected before analysis. The tip-apex distance surrogate was measured on the single anteroposterior view as the distance from the screw tip to the femoral head centre after pixel-to-millimetre calibration using an assumed femoral head diameter of approximately 50 mm. For the three-screw construct, this value was averaged across screws. For the angular-stable construct, the measurement was based on the principal compression screw rather than the anti-rotation screw, consistent with prior femoral-neck-system studies [13]. The screw-shaft angle was defined as the angle between the mean screw axis and the femoral shaft axis. Because CCS and CS have different intrinsic designs, these measurements were interpreted as pragmatic radiographic placement surrogates rather than perfectly homologous quantities across constructs. The tip-apex surrogate was derived from a single anteroposterior view and is therefore not equivalent to the classical biplanar tip-apex distance. Absolute values may also be affected by radiographic projection and by the assumed femoral head diameter. These limitations were considered when interpreting the exploratory placement analysis.

Outcome measures

The primary clinical outcome was the Harris Hip Score [16] at final follow-up. Secondary outcomes were time to union, femoral head osteonecrosis, screw back-out, operative time, length of stay, total cost, and follow-up duration. Operative time and total cost were analysed as treatment-burden outcomes to describe the clinical trade-off associated with adopting CCS.

Definition of screw back-out

Screw back-out was recorded from the clinical record in millimetres. To capture both the frequency and magnitude of migration in a single measure, patients without back-out were assigned 0 mm in the whole-cohort analysis; the event rate is also reported. Because neither the event rate nor whole-cohort magnitude of back-out differed significantly between groups, back-out is interpreted descriptively rather than as a primary inferential endpoint.

Statistical analysis

Continuous variables are summarised as mean ± standard deviation and compared with the Mann-Whitney U test; categorical variables are compared with the chi-square or Fisher exact test. The primary comparison described early clinical outcomes between CCS and CS fixation in the full clinical cohort. Operative time and total cost were then interpreted as treatment-burden outcomes. The exploratory radiographic analysis examined the relationship between placement surrogates and Harris Hip Score using ordinary-least-squares regression in the 79-patient geometric cohort. The base model regressed Harris Hip Score on age, Garden type, and implant group; each placement surrogate was then added individually to test its incremental value. Garden type was modelled as an ordinal variable [17]; a sensitivity analysis dichotomising Garden I-II versus III-IV gave consistent estimates (implant effect beta = -2.98, P = 0.001; TAD surrogate P = 0.60). Given the exploratory nature of the radiographic analyses, no formal correction for multiple testing was applied. Two-sided $P < 0.05$ was considered significant. Analyses were performed in Python 3.13.9 using SciPy 1.16.3 and statsmodels 0.14.5.

3. Results

Baseline characteristics and radiographic placement context

The two treatment groups were similar in age and baseline fracture severity. In the full clinical cohort, mean age was 57.3 ± 9.9 years in the CCS group and 59.0 ± 9.2 years in the CS group (P = 0.477), and mean Garden type was 2.6 ± 1.2 versus 2.4 ± 1.2 (P = 0.340) (Table 1). Baseline balance was similar in the geometric analysis cohort (age, P = 0.464; Garden type, P = 0.229). The tip-apex surrogate was higher after CS than CCS (16.6 ± 2.4 vs 14.8 ± 2.8 mm; P = 0.008), while the screw-shaft angle showed a non-significant trend in the same direction (41.7 ± 7.1 degrees vs 38.9 ± 6.7 degrees; P = 0.057). These findings show that measurable placement surrogates were not identical between constructs, but they should be interpreted as construct-specific radiographic descriptors rather than direct proof that one implant was placed better than the other.

CCS fixation was associated with better early function and faster union

Clinical outcomes differed between groups in the full cohort (Table 2; Figure 3). Patients treated with CCS had higher Harris Hip Scores than those treated with CS (90.2 ± 4.2 vs 87.6 ± 4.9; P = 0.011) and a shorter time to union (12.7 ± 2.4 vs 14.7 ± 4.2 weeks; P = 0.045). Representative follow-up radiographs at three and six months after surgery are shown in Figure 4. Screw back-out was numerically greater after CS (3.6 ± 5.6 vs 1.4 ± 2.8 mm), but this difference was not statistically significant in either whole-cohort magnitude (P = 0.186) or event rate (32% vs 24%; P = 0.624). Femoral head osteonecrosis was also numerically more frequent after CS (5/41, 12%) than CCS (1/41, 2%), but the difference did not reach statistical significance (P = 0.201). These complication comparisons should be interpreted cautiously because the CCS group had shorter follow-up (7.9 ± 5.2 vs 11.4 ± 6.5 months; P = 0.005), which limits detection of late migration and osteonecrosis.

Clinical benefit came with longer surgery and higher cost

The observed early functional and union advantages of CCS were accompanied by greater treatment burden. Operative time was longer after CCS than CS (61.0 ± 18.9 vs 49.4 ± 15.5 min; P = 0.001), and total cost was substantially higher (44,630 ± 5,135 vs 30,461 ± 7,468 CNY; P < 0.001). Length of stay did not differ meaningfully between groups (16.1 ± 4.5 vs 16.5 ± 4.1 days; P = 0.729). Taken descriptively, the mean cost difference was approximately 14,170 CNY, alongside an unadjusted Harris Hip Score difference of 2.6 points and a union-time difference of about 2 weeks. These figures frame CCS not as an unequivocally superior option in all patients, but as a treatment associated with early functional and healing advantages at the expense of greater operative time and financial cost.

Placement surrogates were not associated with Harris Hip Score in exploratory analysis

In exploratory analysis, neither the tip-apex surrogate nor the screw-shaft angle showed a clear relationship with the Harris Hip Score. In the base multivariable model (n = 79; R2 = 0.47), older age (beta = -0.19 per year; 95% CI, -0.28 to -0.11; P < 0.001), higher Garden type (beta = -2.26; 95% CI, -2.94 to -1.57; P < 0.001), and CS fixation (beta = -3.20; 95% CI, -4.79 to -1.61; P < 0.001) were associated with lower Harris Hip Score (Table 3). When the placement surrogates were added individually, neither was independently associated with function: the coefficient was -0.08 for the tip-apex surrogate (95% CI, -0.39 to 0.24; P = 0.623) and -0.01 for screw-shaft angle (95% CI, -0.13 to 0.11; P = 0.848). The implant-group coefficient remained similar after adding each metric, suggesting that the measured anteroposterior placement surrogates did not account for the observed functional difference between constructs. Representative annotated radiographs illustrate how the measurements were extracted from each construct type (Figure 5).

Discussion

This retrospective cohort study identified a clinically relevant trade-off between CCS and cannulated screw fixation for femoral neck fractures. CCS was associated with higher early Harris Hip Scores and faster union than CS, but these advantages were accompanied by longer operative time and substantially higher total cost. Differences in osteonecrosis and screw back-out were numerically favourable to CCS but were not statistically significant and should be interpreted cautiously given the limited and imbalanced follow-up. In exploratory analysis, the measured anteroposterior placement surrogates, including the tip-apex surrogate and screw-shaft angle, were not independently associated with Harris Hip Score and did not account for the observed functional difference between constructs.

Our clinical findings are consistent with previous comparative studies of femoral-neck-system-type fixation. Better short-term function has been reported in pooled analyses [18]. Faster union has been described in cohort series [19]. Fewer fixation-related complications have been reported in comparisons with the dynamic hip screw [20]. Similar early advantages have been observed in younger patients [21]. The present study adds a treatment-burden perspective by placing these early benefits alongside operative time and total cost. This is important because the Harris Hip Score difference, although statistically significant, was modest; therefore, CCS should be interpreted as a potentially beneficial but higher-burden option rather than as universally preferable.

The tip-apex distance was originally developed and validated for extracapsular peritrochanteric fixation [22], and its prognostic value has since been examined in cephalomedullary nailing [23, 24]. Femoral-neck-system-type implants, however, differ substantially in load transfer and angular stability [25, 26]. Our exploratory radiographic findings align with recent single-construct studies questioning whether tip-apex distance retains the same prognostic role in femoral neck fixation [27, 28], although the literature remains mixed [13]. Because our TAD measure was a single-view surrogate and CCS and CS differ intrinsically in geometry, these findings should be interpreted cautiously and should not be taken to mean that placement quality is unimportant.

Clinically, these findings support a selective rather than universal preference for CCS. The construct may be attractive when early function and faster union are priorities, particularly in patients at greater risk of mechanical compromise, but the longer operation and higher cost should be weighed against the modest magnitude of functional gain. Because osteonecrosis and screw back-out did not differ significantly, this study cannot claim a clear short-term complication-prevention advantage. CS may therefore remain reasonable for lower-risk fractures or resource-constrained settings. The radiographic analysis should be interpreted as secondary: the measured AP placement surrogates did not explain the functional difference, but this does not imply that surgical technique is unimportant. Appropriate reduction, central head placement, avoidance of cortical breach, and stable fixation remain essential, while simple AP surrogate measures may not fully capture the relevant mechanics of structurally different constructs.

This study combines clinical outcomes, operative and economic burden, and exploratory radiographic placement analysis in the same cohort, providing a broader view of construct choice than a simple implant comparison. However, the findings should be interpreted in light of the retrospective, single-centre, non-randomised design and the non-contemporaneous use of the two constructs. Follow-up was shorter in the CCS group, limiting assessment of late osteonecrosis and screw migration. The Harris Hip Score difference was statistically significant but modest, and the radiographic metrics were single-view surrogates that are not perfectly comparable across structurally different implants. These findings should therefore be considered exploratory and require confirmation in prospective cohorts with longer, balanced follow-up.

Conclusions

CCS fixation was associated with better early function and faster union than cannulated screws, but at the cost of longer surgery and higher treatment expense. Complication differences were not statistically significant, and simple AP placement surrogates did not explain the functional difference between constructs. CCS should therefore be interpreted as a potentially useful but higher-burden option for selected patients rather than as a universally superior fixation strategy.

Declarations

Ethics approval and consent to participate

This retrospective study was approved by the Institutional Review Board of Beijing Fengsheng Hospital of Traditional Chinese Medicine Orthopedics and Traumatology (Approval No. FSLL2026-01; approval date: 23 December 2025). The requirement for individual informed consent was waived by the Institutional Review Board owing to the retrospective nature of the study. The study was conducted in accordance with the principles of the Declaration of Helsinki.

Consent for publication

Not applicable.

Availability of data and materials

The data that support the findings of this study are available from the corresponding author upon reasonable request.

Competing interests

The authors declare that they have no competing interests.

Funding

This study received no external funding.

Authors' contributions

JZ and ZZ contributed equally to this work. JZ, ZZ, GY, and YQ conceived and designed the study. JZ, YD, YT, LJ, and YL collected and curated the clinical data. ZZ curated the radiographic dataset and performed radiographic annotation. ZZ and YQ conducted the statistical analysis. JZ and ZZ drafted the manuscript. GY and YQ supervised the study. All authors interpreted the data, critically revised the manuscript, and approved the final version for submission.

Acknowledgements

Not applicable.

References

1. Szymski D, Walter N, Lang S. Incidence and treatment of intracapsular femoral neck fractures in Germany. Arch Orthop Trauma Surg. 2023;143:2529–37. https://doi.org/10.1007/s00402-022-04504-3.

2. Veronese N, Maggi S. Epidemiology and social costs of hip fracture. Injury. 2018;49:1458–60. https://doi.org/10.1016/j.injury.2018.04.015.

3. Bhandari M, Swiontkowski M. Management of acute hip fracture. N Engl J Med. 2017;377:2053–62. https://doi.org/10.1056/NEJMcp1611090.

4. Florschutz A, Langford J, Haidukewych G, Koval K. Femoral neck fractures: current management. J Orthop Trauma. 2015;29:121–9. https://doi.org/10.1097/BOT.0000000000000291.

5. Slobogean G, Sprague S, Scott T, Bhandari M. Complications following young femoral neck fractures. Injury. 2015;46:484–91. https://doi.org/10.1016/j.injury.2014.10.010.

6. Ma J, Kuang M, Xing F. Sliding hip screw versus cannulated cancellous screws for fixation of femoral neck fracture in adults: a systematic review. Int J Surg. 2018;52:89–97. https://doi.org/10.1016/j.ijsu.2018.01.050.

7. Panteli M, Rodham P, Giannoudis P. Biomechanical rationale for implant choices in femoral neck fracture fixation in the non-elderly. Injury. 2015;46:445–52. https://doi.org/10.1016/j.injury.2014.12.031.

8. Stoffel K, Zderic I, Gras F. Biomechanical evaluation of the femoral neck system in unstable Pauwels III femoral neck fractures: a comparison with the dynamic hip screw and cannulated screws. J Orthop Trauma. 2017;31:131–7. https://doi.org/10.1097/BOT.0000000000000739.

9. Felton J, Slobogean G, Jackson S. Femoral neck shortening after hip fracture fixation is associated with inferior hip function: results from the FAITH trial. J Orthop Trauma. 2019;33:487–96. https://doi.org/10.1097/BOT.0000000000001551.

10. Wang K, Lin D, Chen P, Lin C, Feng T, Liu J. Incidence and factors influencing neck shortening after screw fixation of femoral neck fractures with the femoral neck system. J Orthop Surg Res. 2023;18:317. https://doi.org/10.1186/s13018-023-03787-5.

11. Patel S, Kumar V, Baburaj V, Dhillon M. The use of the femoral neck system (FNS) leads to better outcomes in the surgical management of femoral neck fractures in adults compared to fixation with cannulated screws: a systematic review and meta-analysis. Eur J Orthop Surg Traumatol. 2023;33:2101–9. https://doi.org/10.1007/s00590-022-03407-8.

12. Zhang Y, Lin Y, Li C. A comparative analysis of femoral neck system and three cannulated screws fixation in the treatment of femoral neck fractures: a six-month follow-up. Orthop Surg. 2022;14:686–93. https://doi.org/10.1111/os.13235.

13. Su M, He Z, Huang N, Lin X, Fang K, Dai Z. Superior short-term outcomes of FNS in combination with a cannulated screw in treating femoral neck fractures. BMC Musculoskelet Disord. 2023;24:823. https://doi.org/10.1186/s12891-023-06959-w.

14. Rajnish R, Srivastava A, Rathod P. Does the femoral neck system provide better outcomes compared to cannulated screws fixation for the management of femoral neck fracture in young adults? A systematic review of literature and meta-analysis. J Orthop. 2022;32:52–9. https://doi.org/10.1016/j.jor.2022.05.007.

15. von Elm E, Altman D, Egger M, Pocock S, Gøtzsche P, Vandenbroucke J. The Strengthening the Reporting of Observational Studies in Epidemiology (STROBE) statement: guidelines for reporting observational studies. Lancet. 2007;370:1453–7. https://doi.org/10.1016/S0140-6736(07)61602-X.

16. Harris W. Traumatic arthritis of the hip after dislocation and acetabular fractures: treatment by mold arthroplasty. J Bone Jt Surg Am. 1969;51:737–55. https://doi.org/10.2106/00004623-196951040-00012.

17. Garden R. Low-angle fixation in fractures of the femoral neck. J Bone Jt Surg Br. 1961;43-B:647–63. https://doi.org/10.1302/0301-620X.43B4.647.

18. Gupta G, Rai A, Mandal S. Comparison of femoral neck system versus cannulated cancellous screws for the fixation of femoral neck fracture in young adults: a systematic review and meta-analysis. Cureus. 2022;14:e32011. https://doi.org/10.7759/cureus.32011.

19. Davidson A, Blum S, Harats E. Neck of femur fractures treated with the femoral neck system: outcomes of one hundred and two patients and literature review. Int Orthop. 2022;46:2105–15. https://doi.org/10.1007/s00264-022-05414-0.

20. Schuetze K, Burkhardt J, Pankratz C. Is new always better: comparison of the femoral neck system and the dynamic hip screw in the treatment of femoral neck fractures. Arch Orthop Trauma Surg. 2023;143:3155–61. https://doi.org/10.1007/s00402-022-04551-w.

21. Hu H, Cheng J, Feng M, Gao Z, Wu J, Lu S. Clinical outcome of femoral neck system versus cannulated compression screws for fixation of femoral neck fracture in younger patients. J Orthop Surg Res. 2021;16:370. https://doi.org/10.1186/s13018-021-02517-z.

22. Baumgaertner M, Curtin S, Lindskog D, Keggi J. The value of the tip-apex distance in predicting failure of fixation of peritrochanteric fractures of the hip. J Bone Jt Surg Am. 1995;77:1058–64. https://doi.org/10.2106/00004623-199507000-00012.

23. Khanna V, Tiwari M. Significance of tip apex distance in intertrochanteric fracture femur managed with proximal femoral nailing. Orthop Traumatol Surg Res. 2021;107:103009. https://doi.org/10.1016/j.otsr.2021.103009.

24. Nüchtern J, Ruecker A, Sellenschloh K. Malpositioning of the lag screws by 1- or 2-screw nailing systems for pertrochanteric femoral fractures: a biomechanical comparison of Gamma 3 and InterTan. J Orthop Trauma. 2014;28:276–82. https://doi.org/10.1097/BOT.0000000000000008.

25. Moon J, Lee J, Hwang K, Yang J, Park Y, Park K. Biomechanical comparison of the femoral neck system and the dynamic hip screw in basicervical femoral neck fractures. Sci Rep. 2022;12:7915. https://doi.org/10.1038/s41598-022-11914-1.

26. Teng Y, Zhang Y, Guo C. Finite element analysis of femoral neck system in the treatment of Pauwels type III femoral neck fracture. Med Baltim. 2022;101:e29450. https://doi.org/10.1097/MD.0000000000029450.

27. Leung H, Wong J, Fang C, Tsoi C. Tip-to-apex distance does not predict fixation failure regardless of reduction quality in intra-capsular neck of femur fractures treated with femoral neck system. J Orthop Trauma Rehabil. 2024;31:55–9. https://doi.org/10.1177/22104917231191804.

28. Cheong T, Heng C, Wong MK. Is the tip-apex distance a reliable predictor of implant failure in surgical fixation of femoral neck fractures with the synthes femoral neck system device? BMC Musculoskelet Disord. 2026;27:91. https://doi.org/10.1186/s12891-025-09429-7.

Figure legends

Figure 1. Fixation concepts and study workflow. (A) Schematic illustration of cannulated screw fixation and CCS fixation concepts. The schematic is intended to clarify the fixation constructs compared in this study and does not represent a specific proprietary implant. (B) Study workflow showing the full clinical cohort and the matched radiographic geometry cohort.

Figure 2. Representative pre-operative and immediate post-operative radiographs. (A) Pre-operative anteroposterior and lateral radiographs of a femoral neck fracture subsequently treated with CCS. (B) Immediate post-operative radiographs of the same patient after CCS fixation. (C) Pre-operative radiographs of a femoral neck fracture subsequently treated with cannulated screws. (D) Immediate post-operative radiographs of the same patient after fixation with three cannulated screws in an inverted-triangle configuration.

Figure 3. Early clinical benefit and treatment burden by fixation construct. Individual patient values with mean and standard deviation are shown for Harris Hip Score, union time, operative time, and total cost in the full clinical cohort (CCS, n = 41; CS, n = 41). CCS was associated with higher Harris Hip Scores and shorter union time, but also longer operative time and higher total cost.

Figure 4. Representative follow-up radiographs at three and six months after surgery. (A, B) Anteroposterior and lateral radiographs of a patient treated with cannulated screws at 3 months (A) and 6 months (B) after surgery. (C, D) Radiographs of a patient treated with CCS at 3 months (C) and 6 months (D) after surgery, showing progressive fracture healing in both constructs.

Figure 5. Representative annotated post-operative radiographs. Representative anteroposterior radiographs of CCS and cannulated screw fixation are shown with measurement overlays, including screw axes, the femoral shaft axis, the fitted femoral head circle, and the greater and lesser trochanter reference points. The greater trochanter points shown are based on the corrected relabelled annotations.

Tables

Table 1. Baseline characteristics and radiographic placement context

Variable	CCS	CS	P value
Age (years)	57.3 ± 9.9	59.0 ± 9.2	0.477
Male sex	14/41 (34%)	16/41 (39%)	0.819
Garden type	2.6 ± 1.2	2.4 ± 1.2	0.340
Preoperative wait (days)	2.1 ± 1.2	2.0 ± 1.0	0.848
Tip-apex surrogate (mm)	14.8 ± 2.8	16.6 ± 2.4	0.008
Screw-shaft angle (deg)	38.9 ± 6.7	41.7 ± 7.1	0.057

Values are mean ± standard deviation or n/N (%). Baseline variables use the full clinical cohort (CCS, n = 41; CS, n = 41); radiographic placement surrogates use the geometric cohort (CCS, n = 38; CS, n = 41). CCS, Composite Compression System; CS, cannulated screws.

Table 2. Clinical outcomes and treatment burden by fixation construct

Outcome	CCS (n = 41)	CS (n = 41)	P value
Harris Hip Score	90.2 ± 4.2	87.6 ± 4.9	0.011
Union time (weeks)	12.7 ± 2.4	14.7 ± 4.2	0.045
Operative time (min)	61.0 ± 18.9	49.4 ± 15.5	0.001
Total cost (CNY)	44,630.4 ± 5,134.9	30,460.8 ± 7,467.7	<0.001
Length of stay (days)	16.1 ± 4.5	16.5 ± 4.1	0.729
Follow-up (months)	7.9 ± 5.2	11.4 ± 6.5	0.005
Osteonecrosis	1/41 (2%)	5/41 (12%)	0.201
Back-out event	10/41 (24%)	13/41 (32%)	0.624
Screw back-out (mm, non-events scored as 0)	1.4 ± 2.8	3.6 ± 5.6	0.186

Values are mean ± standard deviation or n/N (%). CCS, Composite Compression System; CS, cannulated screws.

Table 3. Exploratory multivariable models for Harris Hip Score

Model	Predictor	Coefficient	95% CI	P value	R2
Base	CS vs CCS	-3.196	-4.786 to -1.607	<0.001	0.469
+TAD surrogate	CS vs CCS	-3.069	-4.748 to -1.390	<0.001	0.471
+TAD surrogate	Tip-apex surrogate	-0.078	-0.391 to 0.236	0.623	0.471
+Screw-shaft angle	CS vs CCS	-3.160	-4.804 to -1.517	<0.001	0.469
+Screw-shaft angle	Screw-shaft angle	-0.011	-0.130 to 0.107	0.848	0.469

The geometric regression cohort included 79 patients. Models were adjusted for age and Garden type; only the implant and exploratory placement terms are shown for brevity. Coefficients are ordinary-least-squares beta estimates. TAD, tip-apex distance.

A

Fixation concepts

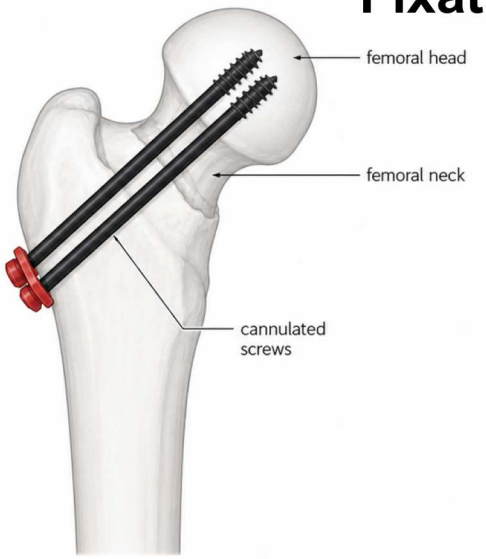

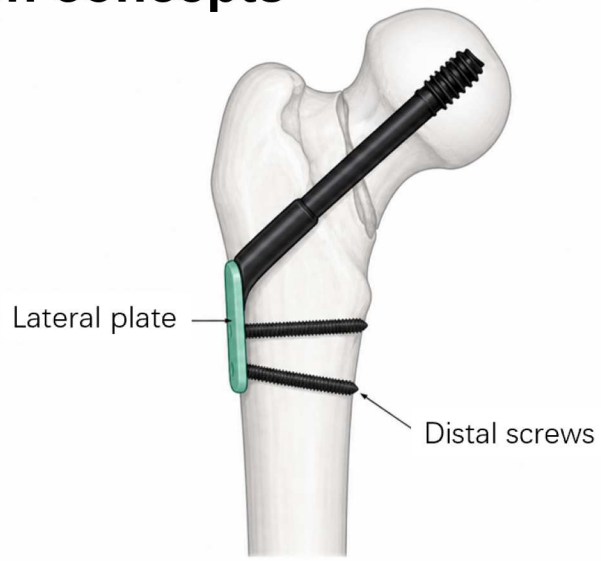

B

Study workflow

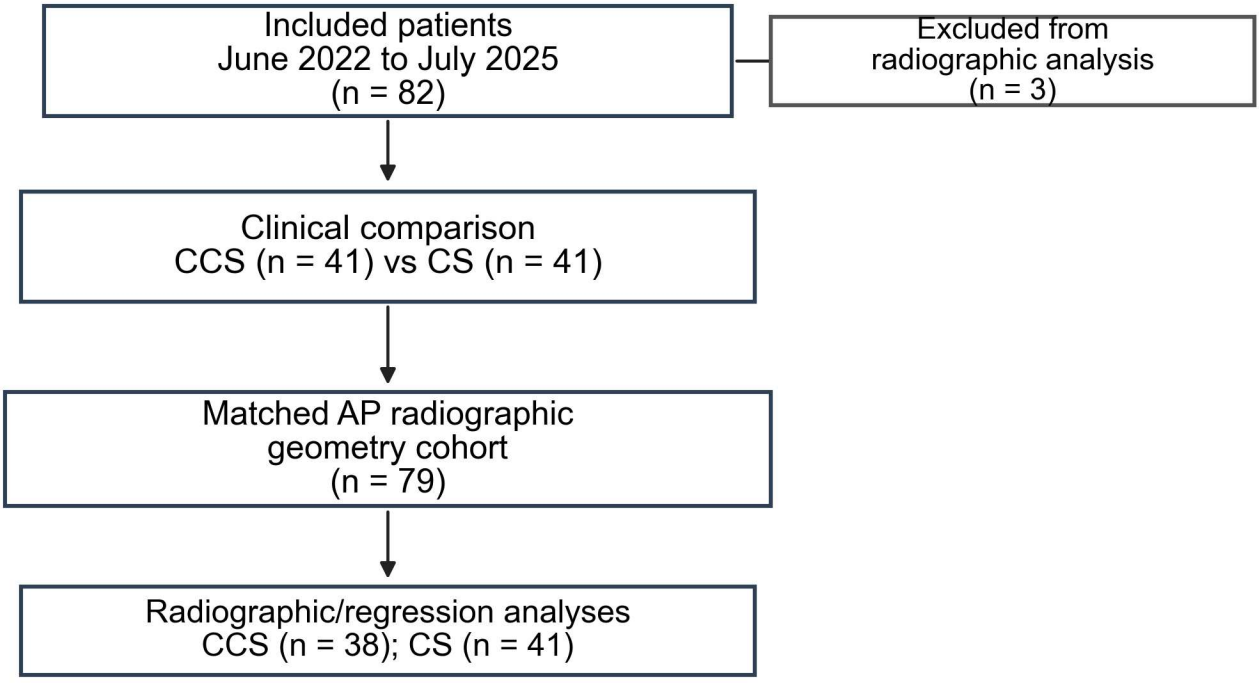

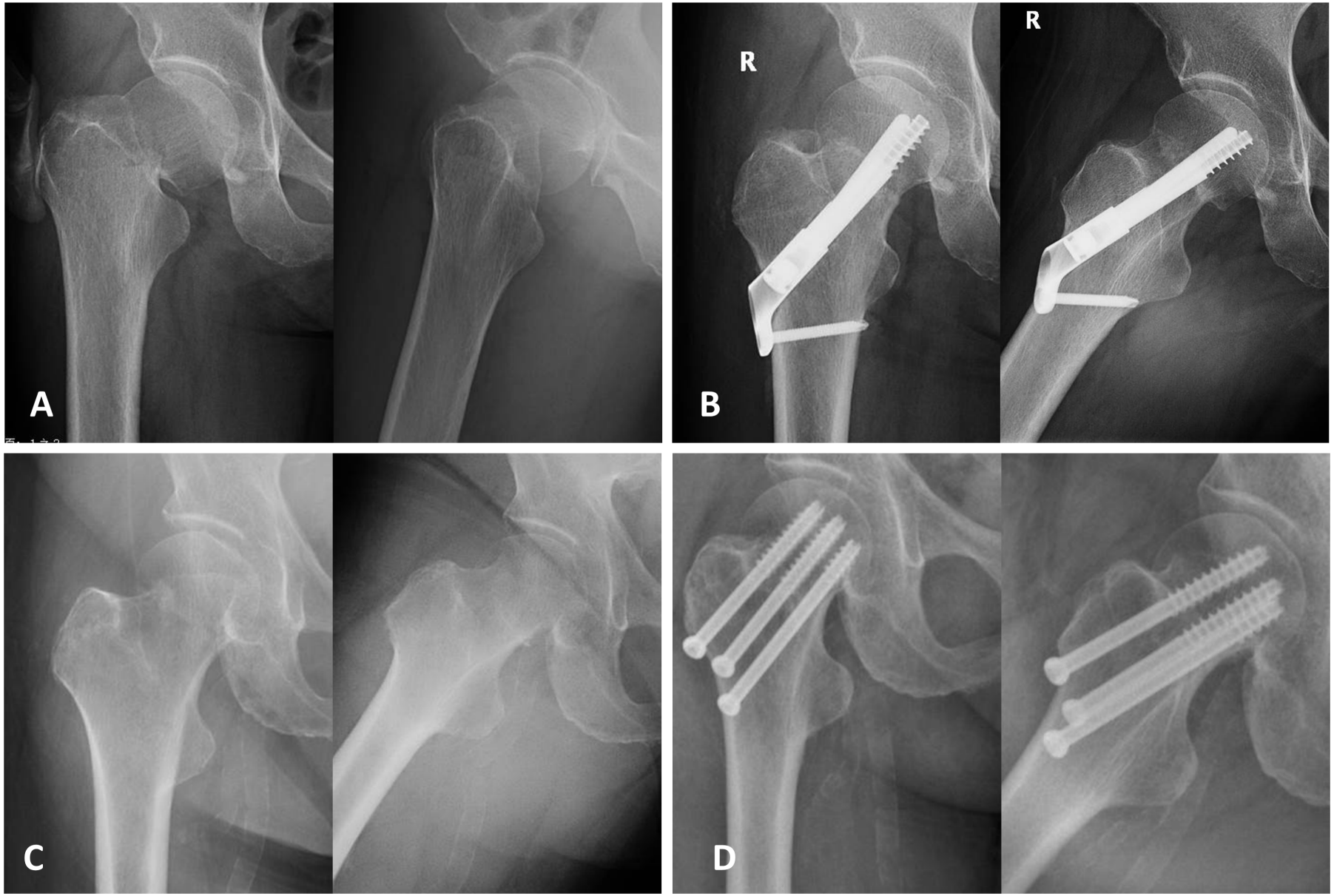
A
R
B
R
C
D

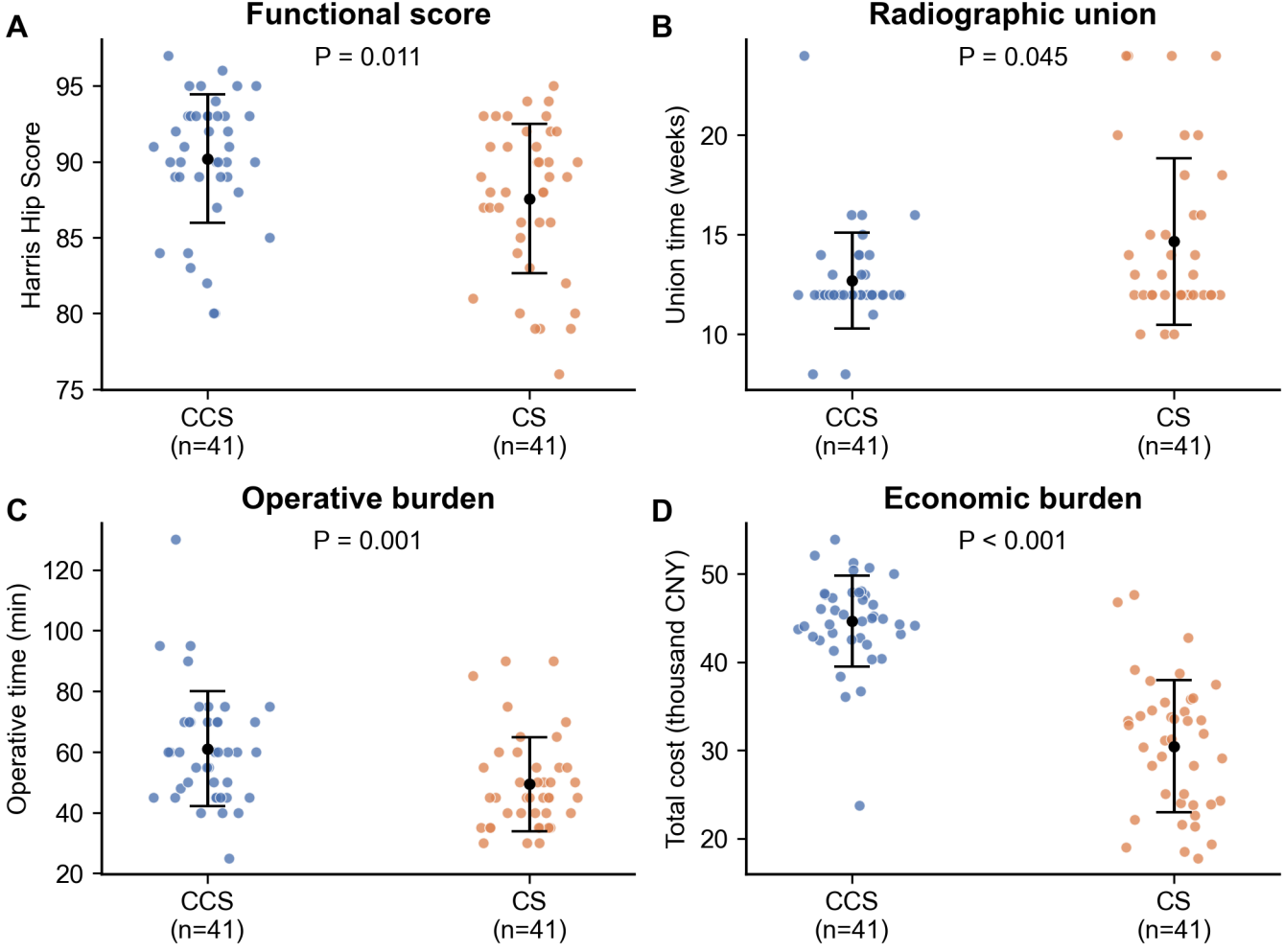
A
Functional score
P = 0.011
Harris Hip Score
95
90
85
80
75
CCS
(n=41)
CS
(n=41)
B
Radiographic union
P = 0.045
Union time (weeks)
20
15
10
CCS
(n=41)
CS
(n=41)
C
Operative burden
P = 0.001
Operative time (min)
120
100
80
60
40
20
CCS
(n=41)
CS
(n=41)
D
Economic burden
P < 0.001
Total cost (thousand CNY)
50
40
30
20
CCS
(n=41)
CS
(n=41)

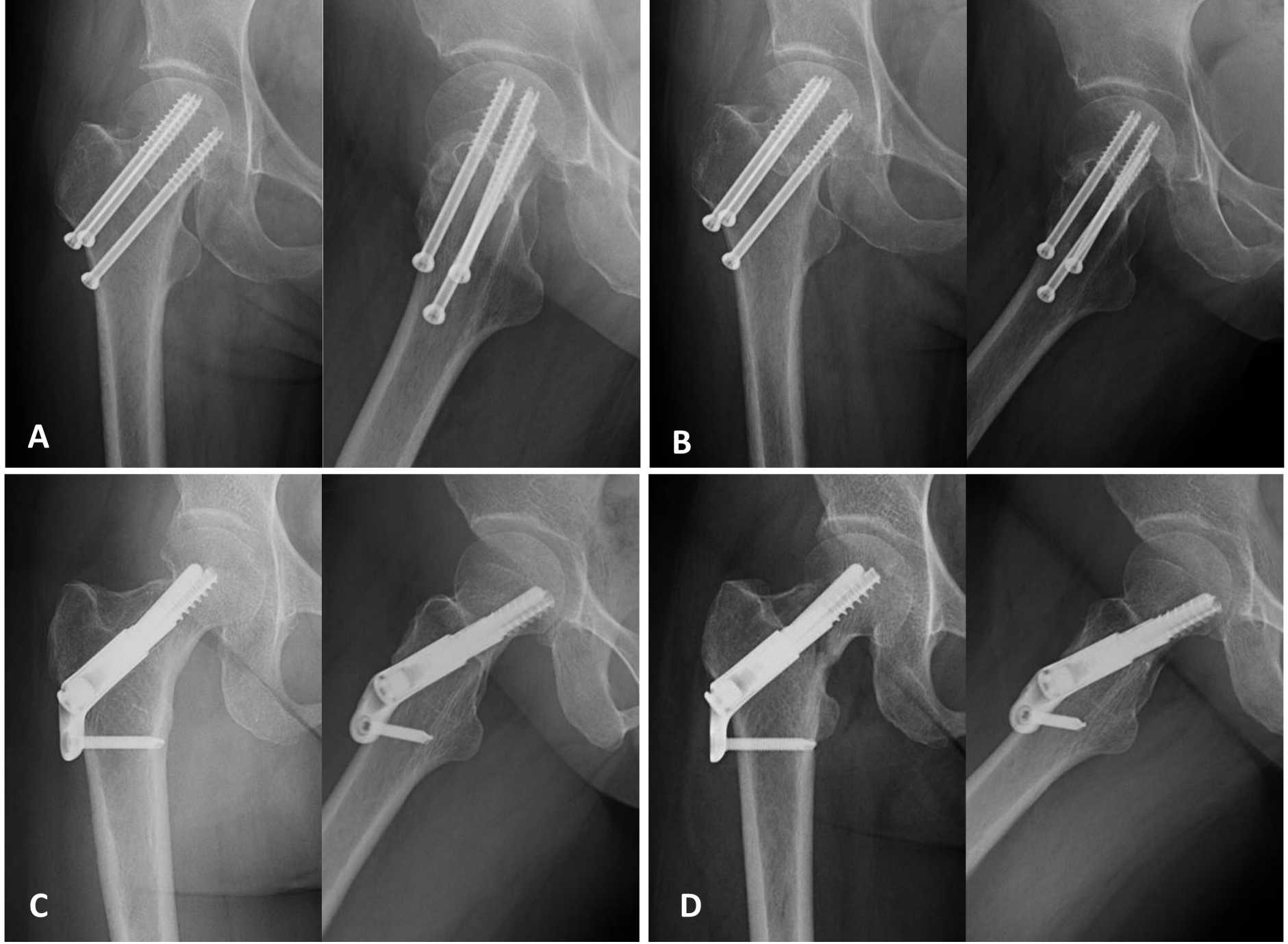
A
B
C
D

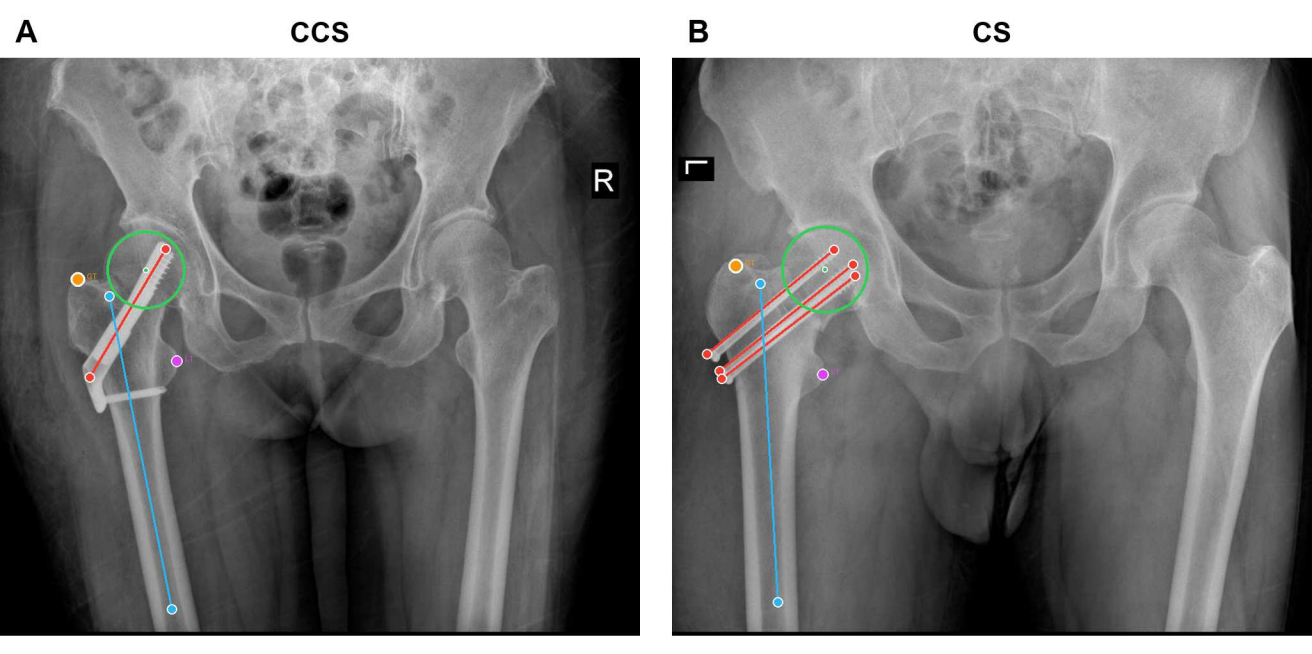
A
CCS
R
B
CS