Supplementary Information

Histological evaluation of a fully synthetic self-assembling peptide-based submucosal injection solution following cap-assisted endoscopic mucosal resection in a porcine model

Shuhei Hayasaka, Masayoshi Ono, Zijian Yang, Keiko Yamamoto, Erina Ishibe, Hiroki Egami, Sae Nakajima, Masayuki Higashino, Takayuki Sone, Xinhan Zhang, Masaki Inoue, Shuichi Miyamoto, Noriyuki Otsuka, Yusuke Watanabe, Naoya Sakamoto, Shoko Ono

Supplementary Figure S1. Procedure of cap-assisted endoscopic mucosal resection and ulcer measurement

a	b
c	d

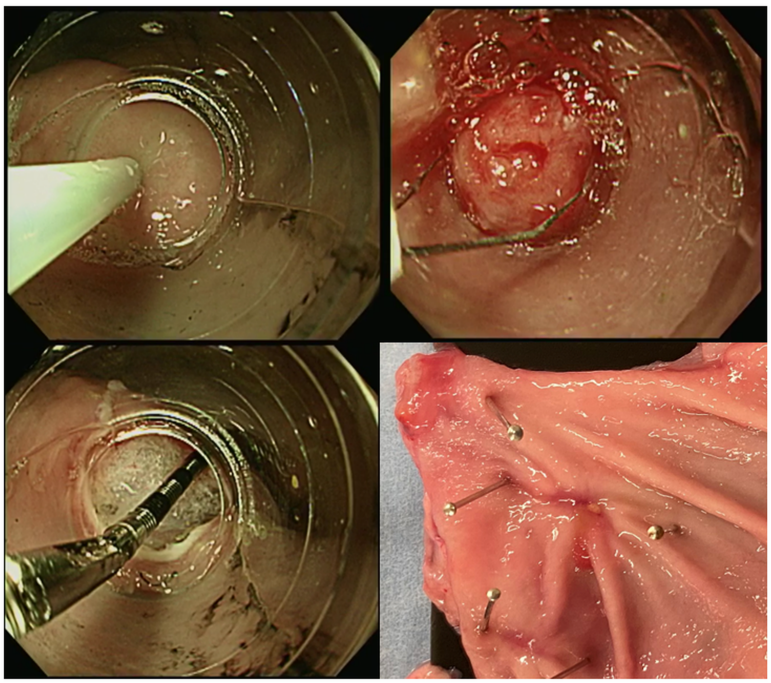

Representative images revealing the submucosal injection of each solution (a); cap-assisted endoscopic mucosal resection (CEMR) (b); endoscopic measurement of ulcer diameter on days 1, 8, and 15 (c); and macroscopic measurement on day 22 following euthanasia (d).

Supplementary Figure S2. Experimental protocol for the gastric cap-assisted endoscopic mucosal resection (CEMR) model

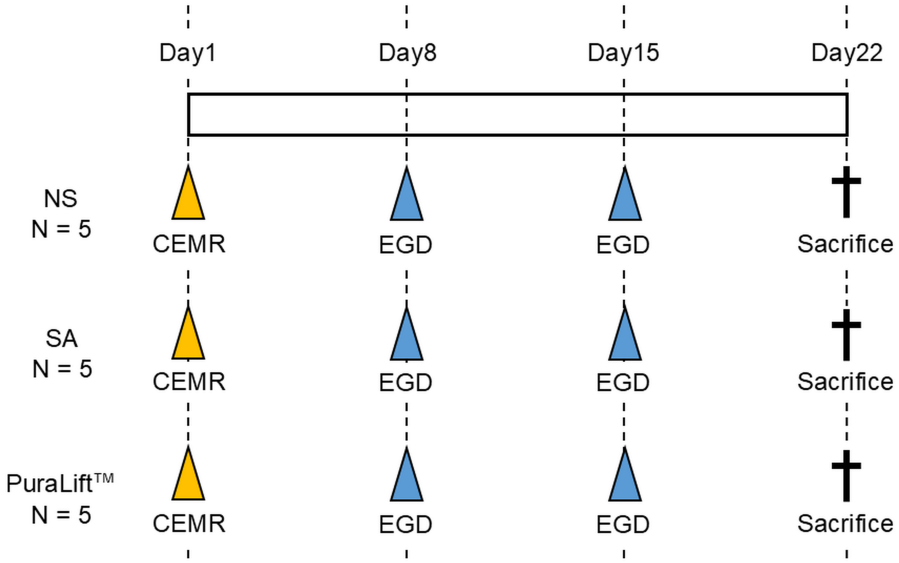

Gastric CEMR is performed in five live pigs using three injection materials: NS, SA, and PuraLift™. Each solution is injected at a volume of 3 mL per site. Ulcer diameters are measured endoscopically on days 1, 8, and 15; all pigs are euthanized for histological evaluation on day 22.

NS, normal saline; SA, sodium alginate; EGD, esophagogastroduodenoscopy. Each group comprises five gastric sites, one in each of the same five pigs.

Supplementary Figure S3. Fibrotic layer thickness measurement

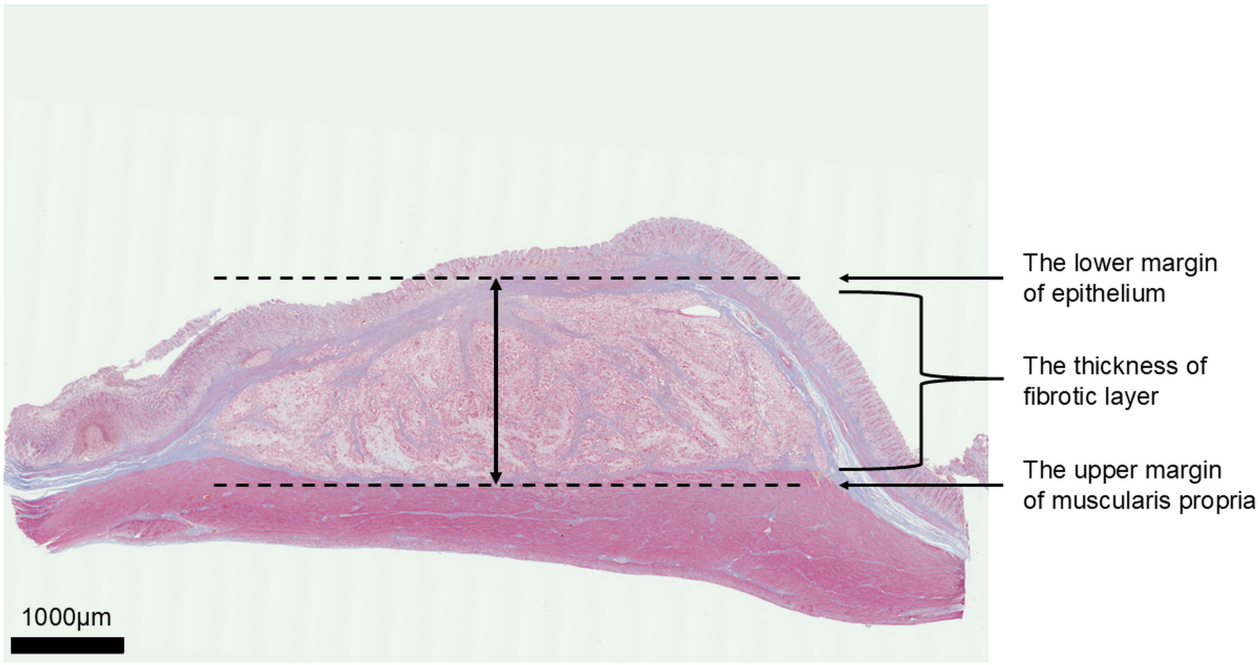

Fibrotic layer thickness is defined as the maximum distance from the lower margin of the epithelium to the upper margin of the muscularis propria on Masson’s trichrome staining.