Research Square

Preprints are preliminary reports that have not undergone peer review.
They should not be considered conclusive, used to inform clinical practice,
or referenced by the media as validated information.

Comparison of one-stage triple-incision versus two-stage quadruple-incision unilateral biportal endoscopic decompression for two-level degenerative lumbar canal stenosis: A retrospective cohort study

Chengwu Yang
the eighth people's hospital of hefei
Dewen Shi
the eighth people's hospital of hefei
Zaibao Wang
the eighth people's hospital of hefei
Guixia Cao
the eighth people's hospital of hefei
Weixiang Sun
sunwx_2250126.com
the eighth people's hospital of hefei

Research Article

Keywords: unilateral biportal endoscopy, two-level lumbar stenosis, one-stage decompression, triple-incision

Posted Date: November 25th, 2026

DOI: https://doi.org/10.21203/rs.3.rs-11428106/v1

License: This work is licensed under a Creative Commons Attribution 4.0 International License.
Read Full License

Additional Declarations: No competing interests reported.

Comparison of one-stage triple-incision versus two-stage quadruple-incision unilateral biportal endoscopic decompression for two-level degenerative lumbar canal stenosis: A retrospective cohort study

Chengwu Yang [1], Dewen Shi[1], Zaibao Wang[1], Guixia Cao[1] and Weixiang Sun[1,*]

[1]Pain Department, the eighth people's hospital of hefei, Hefei, China;
*Correspondence: sunwx_225@126.com; Tel.: +86 0551-82152515

Abstract

Background: Unilateral biportal endoscopy (UBE) is increasingly used for degenerative lumbar canal stenosis (DLCS), yet the optimal surgical strategy for two-level involvement remains unclear. This study compared the clinical outcomes, safety, and cost-effectiveness of one-stage triple-incision UBE versus two-stage quadruple-incision UBE for two-level DLCS.

Methods: A retrospective cohort study was conducted on 155 consecutive patients who underwent UBE decompression for two-level DLCS between January 2023 and February 2025. Patients were divided into Group A (one-stage triple-incision UBE, n=82) and Group B (two-stage quadruple-incision UBE, n=73). Perioperative parameters, clinical outcomes (VAS for back and leg pain, JOA scores, ODI, modified MacNab criteria), and radiographic outcomes (CSDA, facet joint preservation rate, segmental stability, disc height) were compared. The minimum follow-up was 12 months.

Results: Group A demonstrated significantly shorter total operative time, total fluoroscopy time, less blood loss, shorter total incision length, reduced hospital stay, and lower total hospital costs (all $P<0.001$). Both groups achieved significant improvements in all clinical parameters (all within-group $P<0.01$). Group A showed superior outcomes in VAS back pain, JOA scores, and ODI at all postoperative time points (all $P<0.05$), while VAS leg pain scores were comparable between groups (all $P>0.05$). The excellent/good rates were 90.24% and 89.04%, respectively ($P>0.05$). CSDA increased significantly in both groups ($P<0.001$) with comparable increase rates ($P>0.05$). Facet joint preservation rates were similar between groups (all $P>0.05$). Although no patient in either group developed clinical instability, Group B showed significantly greater progression in vertebral translation distance and range of motion at the L4/5 level ($P<0.05$). Complication rates were comparable between groups (9.76% vs. 9.59%, $P>0.05$).

Conclusions: One-stage triple-incision UBE achieves comparable neural decompression efficacy and safety to two-stage UBE for two-level DLCS, while offering superior perioperative efficiency, better functional recovery, and reduced healthcare costs, with a more favorable profile of paraspinal muscle protection and segmental stability preservation. These findings support the one-stage approach as a safe and cost-effective alternative for appropriately selected patients.

Keywords: unilateral biportal endoscopy; two-level lumbar stenosis; one-stage decompression; triple-incision

1. Background

Degenerative lumbar canal stenosis (DLCS) is a common age-related degenerative condition of the lumbar spine, with an incidence rate of approximately 9.3%[1, 2]. The clinical manifestations mainly include lower back pain, leg pain, and intermittent claudication[3]. Some patients may also experience stenosis in two or even multiple segments of the spinal canal.

The current conventional treatment methods include conservative management and surgical intervention[4]. With the goal of decompressing the spinal canal, surgical options include open surgery and minimally invasive procedures. With the rise of spinal endoscopic technology, some studies have applied percutaneous transforaminal endoscopic discectomy (PTED) technique to treat DLCS[5, 6], and some researchers have attempted to use dual-channel PTED to simultaneously address two-segmental spinal stenosis[7, 8]. However, due to factors such as limited operative space and interference between the two channels, the decompression under the endoscope is not always thorough. The Unilateral biportal endoscopic (UBE) technique, which emerged in 2013[9], has gained attention for its unique advantages. These include independent observation and operating channels, a broader endoscopic view, greater flexibility in operation, a more extensive decompression range, and more complete decompression. It is gradually being applied to the treatment

of DLCS, with significant clinical outcomes[10, 11]. In patients with two-level DLCS, traditional two-stage UBE decompression increases the risks associated with repeated anesthesia, elevates healthcare costs, and requires four incisions in total, leading to greater tissue trauma and prolonged recovery. Recently, we treated several patients with two-level DLCS using the one-stage triple-incision UBE decompression. However, no study has directly compared the clinical outcomes, safety, and cost-effectiveness of one-stage triple-incision versus two-stage quadruple-incision UBE for two-level DLCS. Therefore, this study was conducted to compare these two surgical strategies, with the hypothesis that one-stage UBE achieves comparable efficacy while reducing surgical trauma and costs.

2. Methods

Patient selection

This study was approved by the Ethics Committee of The Eighth People's Hospital of Hefei (ethical approval number: 2024060701), which complied with the Declaration of Helsinki. Written informed consent to participate was obtained from all participants included in this study. From January 2023 to February 2025, consecutive patients who underwent UBE decompression for two-level DLCS at our institution were retrospectively reviewed. Patients were divided into two groups based on the surgical strategy: Group A (one-stage triple-incision UBE) and Group B (two-stage quadruple-incision UBE). In accordance with the selection and exclusion criteria described below, Group A comprised 82 participants and Group B comprised 73 participants. There were no statistically significant differences in the demographic data between the two groups, indicating comparability (Table 1).

Table 1. Comparison of baseline demographic and clinical characteristics between the two groups

Variables	Group A (n=82)	Group B (n=73)	t or χ^2	P
Age (years)	67.5±11.85	68.64±12.36	0.588	0.557
Sex (M/F)	40/42	36/37	0.004	0.947
Symptom duration (months)	20.93±8.87	20.01±8.47	0.654	0.514
Surgical levels (L3-4&L4-5 / L4-5&L5-S1)	28/54	21/52	0.517	0.472
Stenosis type (Central/Lateral/Mixed)/segments	52/36/76	44/32/70	0.104	0.949
Decompression side (Right/Left)	26/56	23/50	0.001	0.979
follow-up duration (months)	23.71±7.24	23.84±7.90	0.105	0.916

Selection criteria: (I)Patients diagnosed with two-level DLCS confirmed by computed tomography (CT) and magnetic resonance imaging (MRI). (II) Patients suffered from the following clinical symptoms, such as persistent radicular leg pain, neurological deficits, or neurogenic intermittent claudication. (III) It was refractory to conservative treatment for at least 6 months.

Exclusion criteria: (I) Patients with single-level, three or more levels, or skipped two-level lumbar spinal stenosis; (II) CT examination showed isthmus disconnect; (III) Accompanied by more than grade I degenerative spondylolisthesis; (IV) Accompanied by segmental instability, which was defined as translation of more than 4 mm or 10 degrees of angular motion between flexion and extension on upright lateral radiographs; (V) pre-existing degenerative lumbar scoliosis (Cobb angle >20°); (VI) Accompanied by other spinal diseases, such as ankylosing spondylitis, spinal tumors, fractures or neurological diseases; (VII) Previous history of lumbar spine surgery; (VIII) Abnormal coagulation function.

Surgical techniques

The decision regarding the decompression side was determined by the patient's clinical presentation and imaging findings. Bilateral decompression was performed if the clinical presentation demonstrated bilateral lower extremity symptoms accompanied by imaging evidence of mixed-type stenosis, severe central canal stenosis, or bilateral lateral recess stenosis; or in cases of unilateral lower extremity symptoms combined with severe central canal stenosis and bilateral lateral recess stenosis. Unilateral decompression was indicated for patients presenting with unilateral lower extremity symptoms and imaging findings of non-severe central canal stenosis or unilateral lateral recess stenosis.

One-stage triple-incision UBE technique

For instance, a patient underwent a two-level surgery addressing the L4-5 and L5-S1 levels from the left side. After induction of general anesthesia, the patient is positioned prone on the operating table. To facilitate better surgical operation, the patient's abdomen is supported with a cushion, and the operating table is adjusted to a folded knife position, ensuring that the patient's waist is level and parallel to the ground. Fluoroscopic guidance is used to locate the needle entry points (Fig. 1A). We typically locate the ipsilateral medial pedicle line, the intervertebral space, and the ipsilateral spino-laminar junction. To acquire an accurate anterior-posterior image, the fluoroscope must be positioned parallel to the disc space. The operation is made from the left side. The skin incision lines are designed under fluoroscopy, referring to the marked points on the X-ray and the fluoroscopy markers (Fig. 1 B, C).

The skin and the surgical field are prepared in the usual manner. For improved surgical visibility, continuous irrigation with saline solution is required. An arthroscopic system with a 30-degree scope is essential. Prepare sterile instruments for the procedure, including a drill bit (model JZM40DRWS, made in Chongqing, China), a bipolar radiofrequency surgical electrode (model FS C04-11, made in Shanghai, China), and a radiofrequency plasma surgical electrode (model BML04L1438A, made in Hefei, China). Using a scalpel, make three incisions based on the skin landmarks. The first incision is a horizontal cut approximately 8mm long, made at the intersection of the lower edge of the left L4 pedicle and the medial pedicle line. The second incision is a vertical cut approximately 8-10mm long, made using the inner edge of the left L5 pedicle as a reference. The third incision is a horizontal cut approximately 8mm long, made at the intersection of the upper edge of the left S1 pedicle and the medial pedicle line.

Serial dilatators up to 10 mm are employed to separate the paraspinal muscles and carefully loosen the soft tissues from the interlaminar region to expand the channel. The upper channel is used to position the endoscopic system and serves as the irrigation inlet, while the lower channel is used for inserting surgical instruments and functions as the drainage outlet (Fig. 2A). The imaging system is adjusted for clear images, and the endoscope is used to observe the site while continuous irrigation with saline solution is performed. The initial target area for decompression is at the spino-laminar junction (the junction of the spinous process and the lower laminar margin of the superior vertebra). Radiofrequency ablation is applied to the soft tissues at the posterior aspect of the lamina. The inferior edge of the L4 lamina, superior edge of the L5 lamina, facet joints, spinous processes, and ligamentum flavum between the laminae are exposed (Fig. 2 B, C, D).

The decompression procedures are performed according to the following steps.
(I) Drill the ipsilateral lamina from its lower margin cranially until the origin of ligamentum flavum is exposed using an electric high-speed drill bit (Fig. 2E).
(II) Drill the upper laminar margin of the lower vertebra and then detach the ligamentum flavum from its caudal attachment.
(III) Separate the adhesions between the dura mater and the ligamentum flavum by a blunt nerve dissector.
(IV) In the cases of lateral recess stenosis, remove part of the facet joints to expose the lateral recess and the outside margin of ligamentum flavum (Fig. 2 F, G). The facet drilling should be very conservative to preserve the facet joint as much as possible.
(V) Perform additional bone removal at the spinous process base, followed by contralateral lamina undersurface drilling to expand the laminotomy window, which can facilitate improved visualization and instrument access to the contralateral lateral recess. (Fig. 2H). Note that the ligamentum flavum must be preserved as a protector for the underlying neural tissue.
(VI) Remove the ipsilateral half of the ligamentum flavum and free the ipsilateral dural sac (Fig. 2 I, J). Note decompression of the ligamentum flavum and bone in the lateral recess area to free the traversing nerve root (Fig. 2 K, L).
(VII) For cases with ventral disc herniation, the nerve root is gently retracted using a nerve hook to expose the ventral intervertebral disc. The nucleus is grasped with a disc forceps to extract the degenerated and herniated disc tissue, and a plasma blade is inserted into the disc to perform multiple points of ablation (Fig. 2 M).
(VIII) Remove the contralateral half of the ligamentum flavum and decompress the lower surface of the contralateral facet joint to free the contralateral traversing nerve root (Fig. 2 N, O).

(IX) Under the scope, pulsations of the dura mater and nerve roots were observed, and the outer blood vessels were filled. No residual bone and no significant bleeding were visible under the scope. The arthroscope and instruments were withdrawn, and residual irrigation fluid was removed.
(X) The decompression of the next intervertebral space is performed following the same procedure as described above.
(XI) Suture the incisions (Fig. 2 P).

Postoperatively, the patient is routinely administered antibiotics to prevent infection, along with medications for pain relief, dehydration and swelling reduction, and nerve nutrition. After one day of bed rest, the patient is instructed to wear a lumbar brace before getting out of bed and engaging in rehabilitation exercises.

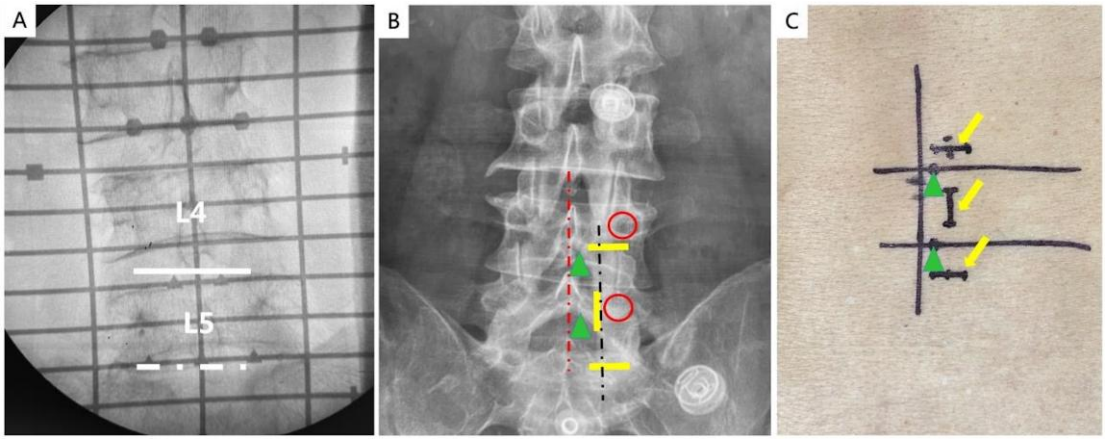

Figure 1. Perspective and skin incision design
(A) The solid white line represents the L4-5 intervertebral space; the dashed white line represents the L5-S1 intervertebral space; (B) the dashed red line represents the spinous process midline; the dashed black line represents the inner edge of the facet joint; the red circles represent the left-sided pedicles of L4 and L5; the solid yellow line indicates the incision line under fluoroscopy; the green triangle represents the intersection of the spinous process and the lamina; (C) the yellow arrows indicate the skin incision lines, with the horizontal incisions at the top and bottom, and the vertical incision in the middle; the green arrow marks the intersection of the left-sided spinous process and lamina on the skin, which is the target point for the procedure.

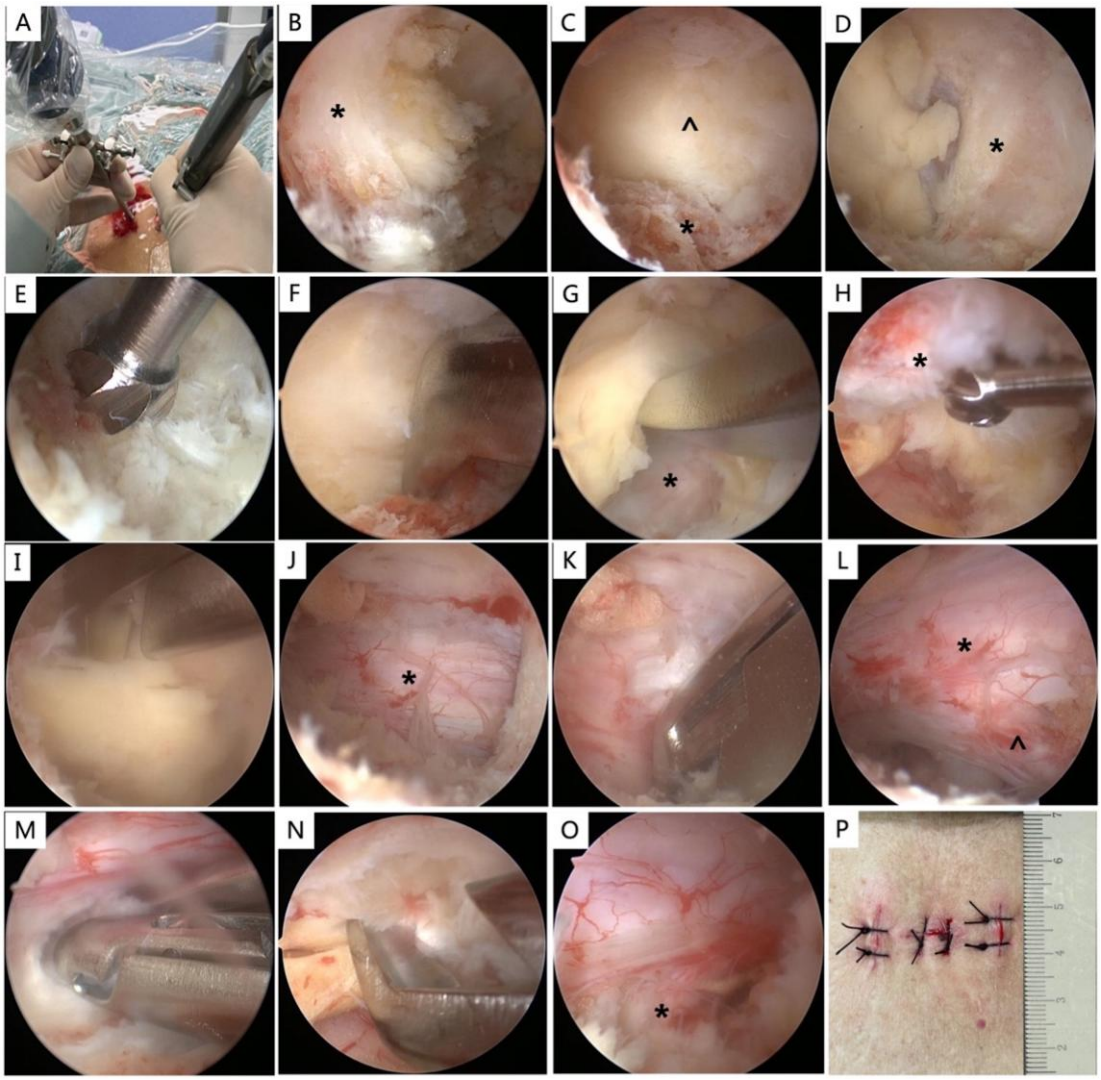

Figure 2. In this case, the UBE decompression was performed with left side approach using a 30 - degree arthroscope. (A) insert endoscopic system and surgical instruments; (B) expose inferior edge of the L4 lamina (*); (C) expose facet joints (*) and ligamentum flavum(^); (D) expose superior edge of the L5 lamina(*); (E) drill the ipsilateral lamina; (F) remove part of facet joints; (G) expose the outside margin of ligamentum flavum(*); (H) remove more bone of the spinous process(*); (I) remove the ipsilateral half of the ligamentum flavum; (J) free the ipsilateral dural sac(*); (K) decompress the lateral recess area; (L) free the traversing nerve root (^) and dural sac(*); (M) extract the degenerated and herniated disc tissue; (N) remove the contralateral half of the ligamentum flavum; (O) free the contralateral traversing nerve root(*);(P) suture the incisions.

Two-stage quadruple-incision UBE technique

In group B, patients underwent UBE decompression for each affected level in separate surgical sessions. For the first level, under general anesthesia and with the patient positioned prone on a radiolucent table, fluoroscopic guidance was used to identify the target intervertebral space and the ipsilateral medial pedicle line. Two longitudinal skin incisions (each approximately 8–10 mm in length) were made: the cranial incision at the junction of the inferior border of the upper pedicle and the medial pedicle line (serving as the viewing portal), and the caudal incision at the junction of the superior border of the lower pedicle and the medial pedicle line (serving as the working portal). Serial dilators were introduced to create a working space, followed by insertion of a 30° arthroscope and surgical instruments. Decompression was performed in the same stepwise manner as described for the one-stage technique, including ipsilateral laminotomy, flavectomy, contralateral decompression (if indicated), and any necessary discectomy. After completion, the incisions were closed, and the patient received routine postoperative care. The second-level surgery was performed after an interval of 2 weeks, depending on the patient's recovery status and clinical condition, using identical two-incision UBE technique at the adjacent level. Thus, a total of four skin incisions were used for the entire two-level decompression.

Outcomes evaluation

Perioperative outcomes were evaluated using the following parameters: total operative time, extra-canal time (from skin incision to spinal canal entry), intracanal decompression time (from spinal canal entry to procedure completion), total incision length, total fluoroscopy time, estimated blood loss, length of postoperative hospital stay, and total hospital expenses. Given the inherent differences in surgical strategy between the two groups, the definition of certain parameters was adapted accordingly. For Group A, total operative time, total fluoroscopy time, and estimated blood loss were recorded as the cumulative values from the single surgical session, whereas for Group B, these parameters were calculated as the sum of both surgical sessions. Similarly, total incision length was defined as the sum of three incisions in Group A and four incisions in Group B. Length of postoperative hospital stay was defined as the total duration from surgery to discharge; for Group B, this represented the combined hospital stay for both admissions. Total hospital expenses were calculated as the overall cost incurred during the entire treatment period, including both surgical sessions for Group B. Additionally, postoperative complications such as dural tears, nerve root injuries, wound hematomas, wound infections, transient dysesthesia, and motor deficits were recorded in both groups.

Clinical outcomes were evaluated for both groups using the visual analog scale (VAS) for back pain and lower leg symptoms, the Japanese Orthopedic Association (JOA) scores for functional recovery, and the Oswestry Disability Index (ODI) for degrees of disability. VAS was an 11-point (0 to 10) visual scale to measure pain intensity, where 0 corresponded to no pain, and 10 indicated the worst pain. The JOA score (0-29) represented pain-related dysfunction, with lower scores showing more pronounced dysfunction. ODI (0 to 100) assessed physical impairment related to pain, and a higher score indicated worse function. These evaluations were performed at pre-operation, 1 month, 3 months, 12 months post-operation, and the final follow-up. In Group B, assessment was initiated after the completion of the second operation.

At the final follow-up, the overall treatment outcomes were assessed based on the modified MacNab criteria. An "Excellent" outcome signified complete symptom resolution, allowing the patient to resume their previous work and lifestyle. A "Good" outcome denoted occasional pain but the ability to perform light work. A "Fair" outcome indicated symptom improvement, though persistent pain prevented the patient from working. A "Poor" outcome was characterized by ongoing signs of nerve root compression, necessitating additional surgical intervention.

Imaging Protocol and Quantitative Analysis for both groups (Fig. 3)

1. The Dural Sac Decompression Assessment
Axial T2-weighted MRI sequences were acquired preoperatively and at 3-month follow-up. The cross-sectional dural area (CSDA)[12] was quantified at the level of maximal stenosis using Medical Image Viewer.

2. Facet Joint Preservation Analysis
The preservation rate of the facet joint was assessed on preoperative and postoperative thin-slice CT scans (1.0 mm). Measurements were performed at the pedicle-level axial slice of each operated lumbar segment. The bony area of the intact and residual facet joint was manually outlined. The preservation rate [13]was calculated using the formula: (residual facet joint area [S'] / intact facet joint area [S]) × 100%, where S represents the baseline facet joint area measured preoperatively and S' denotes the residual facet joint area measured postoperatively. The facet joint area was measured in Medical Image Viewer.Two independent reviewers performed measurements blinded to clinical outcomes.

3. Dynamic Stability Evaluation
Weight-bearing lumbar flexion-extension radiographs in preoperative and final follow-up were analyzed using Medical Image Viewer to obtain the segmental range of motion (ROM) and vertebral translation distance (VTD). The segmental ROM was defined as the angular variation between flexion/extension positions. The segmental VTD was represented as anteroposterior displacement on flexion/extension views.
Segmental instability was defined by either Segmental ROM >10° or VTD >4mm.

4. Disc Height Quantification

Mid-sagittal disc height (DH) was measured on lateral radiographs preoperatively and at final follow-up using the following method: DH = (Anterior height + Posterior height) / 2.

All measurements were performed in triplicate by two blinded doctors to ensure measurement reliability.

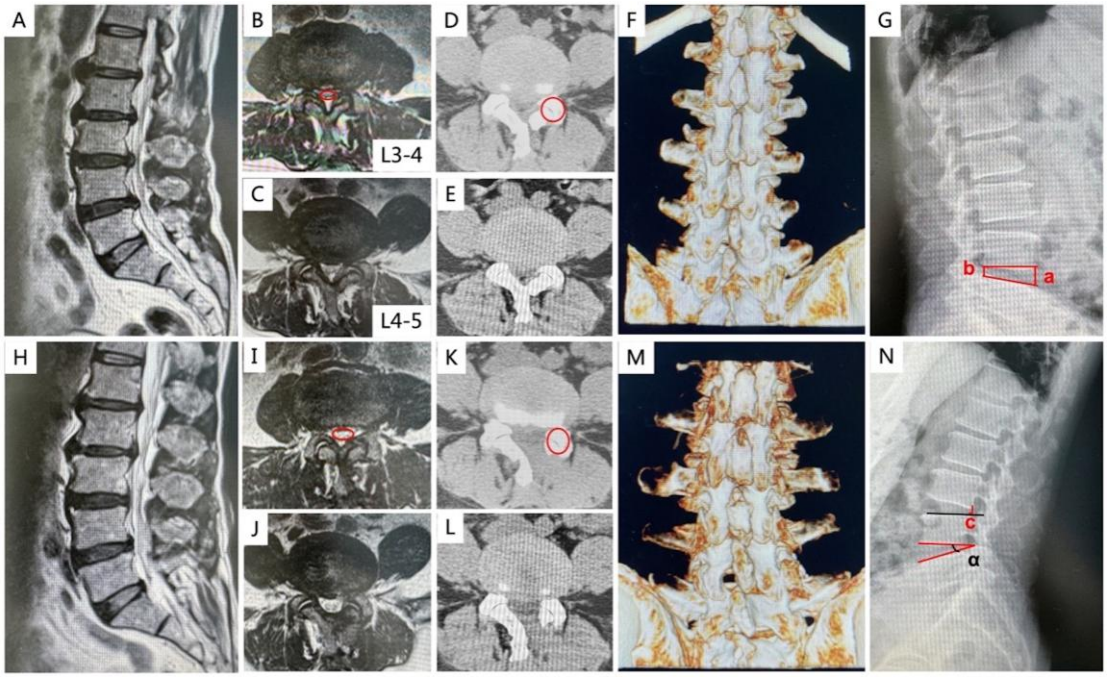

Figure 3. A 63-year-old male patient with two-level lumbar spinal stenosis (LSS) at L3-4 and L4-5 underwent one-stage three-portal unilateral biportal endoscopic (UBE) bilateral decompression.

Preoperative imaging: A-F: MRI and CT scans demonstrating L3-4 and L4-5 central canal stenosis and bilateral neural foraminal stenosis at L4-5 with disc herniation and facet joint hypertrophy. B: Red circle indicates preoperative measurement of CSDA. D: Red circle denotes preoperative ipsilateral facet joint area measurement. G: Preoperative lateral lumbar radiograph demonstrating disc height (DH) measurement using (a+b)/2 formula.

Postoperative imaging: H-M: MRI and CT scans showing adequate central canal decompression with significantly increased cross-sectional area and well-preserved facet joints. I: Red circle indicates postoperative CSDA measurement. K: Red circle denotes post-operative ipsilateral facet joint area measuremen. N: Postoperative hyperextension radiograph demonstrating segmental displacement (c) and angular motion (α) measurements.

Statistical analyses

Statistical analyses were performed using SPSS software (version 27.0; IBM Corp., Armonk, NY, USA). Continuous data were first tested for normality using the Shapiro–Wilk test. Normally distributed data were presented as mean ± standard deviation, while non-normally distributed data were expressed as median with interquartile range [M (Q1, Q3)]. For continuous variables, intergroup differences were assessed using independent t-tests for normally distributed data or Mann–Whitney U tests for non-normally distributed data. Categorical variables were compared using the chi-square test or Fisher's exact test, as appropriate. For longitudinal data across multiple time points (preoperative, 1, 3, 6, and 12 months postoperatively), one-way repeated-measures analysis of variance (ANOVA) was employed within each group. When the assumption of sphericity was violated, the Greenhouse–Geisser correction was applied. Post-hoc pairwise comparisons were conducted using the Bonferroni adjustment to identify specific time points with significant differences. All statistical tests were two-tailed, and a P-value < 0.05 was considered statistically significant.

3. Results

As summarized in Table 2, Group A demonstrated significantly shorter total operative time (80.09±2.72 min vs. 98.78±4.43 min, t=32.0269, P<0.001), shorter extradural time (34.38±2.02 min vs. 46.91±2.67 min, t=33.1574, P<0.001), and

smaller total incision length (25.39±2.02 mm vs. 35.51±2.36 mm, t=28.7617, P<0.001). Although the intracanal decompression time was slightly longer in Group A (54.72±2.61 min vs. 51.88±3.31 min), the difference was also statistically significant (t=5.9623, P<0.001). Total fluoroscopy time (5.59±1.02 s vs. 9.89±1.78 s, t=18.7009, P<0.001), estimated blood loss (33.78±5.01 mL vs. 50.71±6.33 mL, t=18.557, P<0.001), total hospital stay (5.24±1.12 days vs. 12.52±2.47 days, t=24.062, P<0.001), and total hospital costs (RMB 17,957.26±510.41 vs. 25,952.01±702.08, t=81.6912, P<0.001) were all significantly lower in Group A.

The overall complication rate was comparable between Group A and Group B (9.76% vs. 9.59%, P>0.05). Dural tears occurred in 3 patients in Group A and 2 patients in Group B, with no significant intergroup difference (P=0.747). Transient lower extremity paresthesia was observed in 5 patients in each group (P=0.849). All paresthesia cases resolved spontaneously within 3 months following conservative management. No wound infections, hematomas, or neurological deficits were recorded in either group, as detailed in Table 2.

Table 2. Comparison of perioperative outcomes between the two groups

Perioperative Outcomes	**Group A (n=82)**	**Group B (n=73)**	***t***	***P***
Total operative time (min)	89.1±2.72	98.78±4.43	16.164	<0.001
- Extradural time	34.38±2.02	46.9±2.67	32.665	<0.001
- Intracanal time	54.72±2.61	51.88±3.31	5.892	<0.001
Total incision length (mm)	25.39±2.02	35.51±2.36	28.747	<0.001
Total fluoroscopy time (s)	5.6±1.02	9.89±1.78	18.170	<0.001
Estimated blood loss (ml)	33.78±5.00	50.71±6.33	18.316	<0.001
Total hospital stay (days)	5.24±1.12	12.52±2.47	23.174	<0.001
Total hospital costs (RMB)	17957.26±510.41	25952.01±702.08	80.231	<0.001
Perioperative omplications				
dural tear	3	2	0.104	0.747
lower extremity paresthesia	5	5	0.036	0.849

The mean follow-up duration was 23.71±7.24 months in Group A and 23.84±7.9 months in Group B, with no significant difference between groups (t=0.1069, P=0.915). Both groups demonstrated significant improvements in all clinical parameters over time compared with baseline values (all within-group P < 0.01 by repeated-measures ANOVA). Regarding intergroup comparisons at each time point (Table 3), baseline scores were comparable between Group A and Group B for all measures (all P > 0.05). At 1, 3, and 12 months postoperatively as well as at final follow-up, Group A exhibited significantly lower VAS back pain scores (all P < 0.05) and higher JOA scores (all P < 0.01) than Group B. Group A also showed significantly better ODI scores at all postoperative time points (all P < 0.05). In contrast, VAS leg pain scores did not differ significantly between the two groups at any postoperative assessment (all P > 0.05). The excellent/good rate according to modified MacNab criteria at final follow-up was 90.24% in Group A and 89.04% in Group B (P > 0.05).

Table 3. Comparison of clinical outcomes between the two groups

	Group A (n=82)	**Group B (n=73)**	***t* or χ2**	***P***
VAS back				
Preoperative	6.13±0.98	6.07±0.90	0.432	0.666
Postoperative (1 mo.)	3.13±0.52	3.33±0.55	2.255	0.026
Postoperative (3 mo.)	2.59±0.49	2.78±0.53	2.364	0.019
Postoperative (12 mo.)	2.24±0.56	2.45±0.58	2.281	0.024
Final follow-up	1.71±0.48	2.05±0.40	4.866	<0.001
VAS leg				
Preoperative	6.39±0.86	6.58±0.85	1.348	0.180
Postoperative (1 mo.)	2.72±0.69	2.77±0.75	0.410	0.682
Postoperative (3 mo.)	2.11±0.74	2.01±0.69	0.831	0.407
Postoperative (12 mo.)	1.76±0.59	1.78±0.61	0.255	0.799

Final follow-up	1.63±0.58	1.67±0.67	0.371	0.711
JOA				
Preoperative	12.19±1.75	12.27±1.85	0.273	0.785
Postoperative (1 mo.)	16.55±1.13	15.74±1.31	4.115	<0.001
Postoperative (3 mo.)	20.82±0.89	20.04±1.05	4.986	<0.001
Postoperative (12 mo.)	23.44±0.77	22.53±1.03	6.135	<0.001
Final follow-up	25.48±0.83	24.78±0.82	5.213	<0.001
ODI				
Preoperative	50.90±4.27	50.96±4.02	0.085	0.933
Postoperative (1 mo.)	24.49±2.79	25.42±2.52	2.185	0.030
Postoperative (3 mo.)	18.44±2.46	19.23±2.28	2.077	0.039
Postoperative (12 mo.)	14.29±1.67	14.92±1.56	2.395	0.018
Final follow-up	11.79±1.82	12.41±1.93	2.054	0.042
Modified MacNab evaluation				
Excellent	48	43	0.497	0.919
Good	26	22		
Fair	6	7		
Poor	2	1		

Radiographic outcomes – Dural sac decompression

The cross-sectional dural area (CSDA) was measured preoperatively and at 3 months postoperatively. In both groups, CSDA at each surgical level (L3/4, L4/5, L5/S1) increased significantly from baseline to 3-month follow-up (all within-group paired t-test $P < 0.001$). The overall mean CSDA increased from 56.46±8.09 mm^2 to 126.51±10.49 mm^2 in Group A and from 56.33±6.78 mm^2 to 128.12±8.89 mm^2 in Group B, corresponding to mean increase rates of 127.92±32.66% and 129.83±24.16%, respectively.

Intergroup comparisons revealed no significant differences in preoperative CSDA, postoperative CSDA, or the percentage increase at any level (all $P > 0.05$), as detailed in Table 4.

Table 4. Comparison of preoperative and postoperative CSDA（mm^2) between the two groups

	Group A (n=82)	**Group B (n=73)**	***t***	***P***
L3/4				
Preoperative	60.04±6.34	59.33±5.16	0.415	0.680
Postoperative (3 mo.)	127.43±12.24	124.48±12.15	0.838	0.406
L4/5				
Preoperative	53.09±8.98	53.75±7.72	0.494	0.622
Postoperative (3 mo.)	123.17±10.01	125.95±7.90	1.925	0.056
L5/S1				
Preoperative	59.72±4.77	58.73±4.13	1.142	0.256
Postoperative (3 mo.)	131.11±8.35	132.65±6.74	1.044	0.299
Total				
Preoperative	56.46±8.10	56.33±6.78	0.150	0.880
Postoperative (3 mo.)	126.51±10.49	128.12±8.89	1.463	0.144
Increase rate (%)	127.92±32.66	129.83±24.16	0.581	0.562

Radiographic outcomes – facet-joint preservation rate

Ipsilateral and contralateral facet joint areas were measured preoperatively and at 3 months postoperatively. Within each group, facet joint areas decreased significantly at all surgical levels (L3/4, L4/5, L5/S1) from baseline to 3-month follow-up (all within-group paired t-test $P < 0.001$). As expected, contralateral preservation rates were consistently higher than ipsilateral rates in both groups. The mean ipsilateral preservation rates ranged from 70.43±4.83% to

77.41±5.67% in Group A and from 70.62±4.49% to 76.08±5.02% in Group B across the three levels. The corresponding contralateral preservation rates ranged from 87.04±4.75% to 87.69±3.94% in Group A and from 84.84±5.08% to 86.96±5.03% in Group B. Intergroup comparisons revealed no significant differences in preoperative facet area, postoperative facet area, or preservation rate for either ipsilateral or contralateral facets at any level (all P > 0.05), as detailed in Table 5.

Table 5. Comparison of preservation of ipsilateral and contralateral facet - joints at each surgical segment between the two groups

	Group A (n=82)	Group B (n=73)	*t*	*P*
Ipsilateral facet joint (cm²)				
L3/4				
Preoperative	1.90±0.21	1.92±0.18	0.348	0.729
Postoperative (3 mo.)	1.34±0.20	1.36±0.19	0.341	0.735
Preservation rate	70.43±4.83	70.62±4.49	0.134	0.894
L4/5				
Preoperative	2.08±0.19	2.03±0.16	1.937	0.055
Postoperative (3 mo.)	1.55±0.14	1.51±0.18	1.516	0.132
Preservation rate	74.46±4.38	74.36±5.33	0.122	0.903
L5/S1				
Preoperative	2.50±0.23	2.51±0.20	0.230	0.819
Postoperative (3 mo.)	1.94±0.22	1.91±0.21	0.567	0.572
Preservation rate	77.41±5.67	76.08±5.02	1.274	0.205
Contralateral facet joint (cm²)				
L3/4				
Preoperative	1.93±0.12	1.94±0.14	0.155	0.877
Postoperative (3 mo.)	1.68±0.15	1.64±0.14	0.927	0.359
Preservation rate	87.04±4.75	84.84±5.08	1.561	0.125
L4/5				
Preoperative	2.10±0.22	2.05±0.18	1.620	0.107
Postoperative (3 mo.)	1.84±0.21	1.78±0.17	1.961	0.052
Preservation rate	87.60±3.60	86.96±5.03	0.902	0.369
L5/S1				
Preoperative	2.44±0.24	2.49±0.14	1.406	0.163
Postoperative (3 mo.)	2.14±0.22	2.16±0.15	0.679	0.499
Preservation rate	87.69±3.94	86.76±3.81	1.238	0.219

Radiographic outcomes – Segmental stability and disc height

Segmental vertebral translation distance (VTD), range of motion (ROM), and disc height (DH) were evaluated preoperatively, at 3 months postoperatively, and at final follow-up. In both groups, none of the values exceeded the established thresholds for clinical instability (VTD < 4 mm, ROM < 10°) at all time points. Within each group, repeated-measures ANOVA revealed no significant changes in VTD, ROM, or DH over time at any level (all within-group P > 0.05), indicating that segmental stability was maintained postoperatively.

Intergroup comparisons showed no significant differences in VTD, ROM, or DH at the L3/4 and L5/S1 levels across all time points (all P > 0.05). However, at the L4/5 level, Group B demonstrated significantly greater VTD at 3 months (P=0.0204) and at final follow-up (P=0.0001), as well as significantly greater ROM at 3 months (P=0.0076) and at final follow-up (P<0.001), compared with Group A. Despite these statistically significant intergroup differences, the absolute values in both groups remained within the clinically stable range. Disc height showed a slight decreasing trend over time at all levels in both groups, but no significant intergroup differences were observed at any time point (all P > 0.05), as detailed in Table 6.

Table **6**. Comparison of Segmental stability and disc height at each surgical segment between the two groups

	Group A (n=82)	Group B (n=73)	*t*	*P*
Segmental VTD (mm)				
L3/4				
Preoperative	1.59±0.42	1.41±0.35	1.628	0.110
Postoperative (3 mo.)	1.68±0.41	1.54±0.34	1.278	0.208
Final follow-up	1.85±0.44	1.67±0.39	1.484	0.144
L4/5				
Preoperative	1.71±0.60	1.65±0.52	0.569	0.570
Postoperative (3 mo.)	1.87±0.58	2.08±0.53	2.292	0.023
Final follow-up	2.03±0.57	2.53±0.69	4.982	<0.001
L5/S1				
Preoperative	1.23±0.47	1.22±0.39	0.121	0.904
Postoperative (3 mo.)	1.38±0.46	1.39±0.37	0.107	0.915
Final follow-up	1.54±0.47	1.57±0.36	0.353	0.725
Segmental ROM (°)				
L3/4				
Preoperative	5.12±0.67	5.24±0.65	0.658	0.514
Postoperative (3 mo.)	5.28±0.69	5.38±0.66	0.542	0.590
Final follow-up	5.53±0.73	5.61±0.68	0.413	0.682
L4/5				
Preoperative	5.65±0.53	5.47±0.68	1.807	0.073
Postoperative (3 mo.)	5.80±0.52	6.03±0.55	2.622	0.010
Final follow-up	6.02±0.50	6.60±0.56	6.791	<0.001
L5/S1				
Preoperative	4.80±0.64	4.65±0.56	1.233	0.220
Postoperative (3 mo.)	5.01±0.61	4.85±0.52	1.444	0.152
Final follow-up	5.26±0.60	5.11±0.53	1.367	0.174
DH (mm)				
L3/4				
Preoperative	9.51±0.94	9.60±0.99	0.309	0.759
Postoperative (3 mo.)	9.18±0.82	9.31±0.83	0.550	0.585
Final follow-up	8.97±0.70	8.93±0.69	0.190	0.850
L4/5				
Preoperative	9.77±0.96	9.58±0.91	1.212	0.227
Postoperative (3 mo.)	9.40±0.84	9.25±0.79	1.173	0.243
Final follow-up	9.07±0.68	8.99±0.67	0.688	0.493
L5/S1				
Preoperative	9.62±0.92	9.71±0.92	0.518	0.605
Postoperative (3 mo.)	9.26±0.80	9.42±0.83	0.984	0.327
Final follow-up	8.99±0.70	9.10±0.64	0.823	0.412

4、Discussion

Degenerative lumbar canal stenosis (DLCS), caused by factors such as thickening of the ligamentum flavum, herniated discs, and facet joint hypertrophy, manifests clinically as lower back pain, radiating pain and numbness in the lower extremities, and intermittent claudication[14]. Current clinical practice reveals an increasing prevalence of multilevel DLCS, with bilevel DLCS being the most common presentation[15]. Two-level lumbar spinal canal decompression was performed in these patients owing to their severe clinical manifestations. In recent years, as an alternative to traditional open laminectomy, the less-invasive unilateral biportal endoscopy (UBE) has gradually emerged for treating DLCS[16]. By creating endoscopic and working channels via two small incisions, UBE enables clear visualization through an en-

doscope under continuous normal saline irrigation, and decompression is accomplished with conventional spinal surgical instruments through the working channel. However, only one lumbar segment can be decompressed via these two incisions. For patients with two-level stenosis, conventional management consists of staged decompression, entailing two separate surgeries and four incisions. We utilized a midline longitudinal incision to accomplish two-level spinal canal decompression in one-stage setting, converting the conventional quadruple-incision staged approach to a triple-incision technique.

This study represents the first direct comparison between one-stage triple-incision UBE and two-stage quadruple-incision UBE for two-level DLCS. The key findings demonstrate that while both techniques achieve comparable and significant neural decompression as well as equivalent relief of radicular symptoms, the one-stage approach confers superior outcomes in terms of low back pain relief, functional recovery , perioperative efficiency, and preservation of segmental stability, with a more favorable profile of paraspinal muscle protection. The comparable improvement in leg pain and the equivalent increase in CSDA across groups suggest that both surgical strategies achieve similarly effective neural decompression. In this study, CSDA increased by 127.92%±32.66% in the one-stage group and 129.83%±24.16% in the two-stage group at each decompressed level, which is consistent with those of Hu et al[17]. The overall clinical efficacy rates were 90.24% and 89.04% in the two groups, respectively, consistent with previously reported outcomes of UBE for single-level lumbar spinal stenosis[18, 19]. This is clinically meaningful, as it indicates that the one-stage triple-incision technique does not compromise decompression quality despite fewer incisions. The shared use of the longitudinal midline portal between adjacent levels appears to provide adequate working access without sacrificing the extent of bony or ligamentous resection required for adequate neural release. And the total incision length (25.39 ± 2.02 mm) demonstrates significant reduction compared to the (35.51 ± 2.36 mm) in two-satge group in this study and 3.2 ± 0.4 cm reported by Zhang et al[20].

The superior outcomes observed in the one-stage group regarding low back pain, JOA, and ODI merit particular attention. Several interrelated mechanisms may explain this difference. First, the one-stage approach requires only three dilations of fascia and muscle, whereas the two-stage strategy involves four separate dilations performed on two occasions, with the second procedure being conducted through previously scarred tissue. The staged group inevitably sustains more severe cumulative soft-tissue damage, which results from repeated muscle stripping, prolonged retraction of the soft tissues, and thermal injury caused by the radiofrequency ablation procedure.
Second, the shared longitudinal portal in the one-stage technique serves as both a viewing and working channel depending on the level being addressed, allowing dynamic instrument maneuvering through the same muscle interval and reducing the area of paraspinal muscle exposed to mechanical friction. Third, the interval between staged procedures may allow partial recovery of muscle integrity, but repeated surgical insult to the multifidus and erector spinae complexes can still accumulate fatty infiltration and atrophy over time. This muscle damage and degeneration is a common source of postoperative axial pain and a diminished dynamic load-bearing capacity[21]. This compromised muscular support disrupts normal force distribution and thus elevates axial loading on the spinal structures[22], because the muscles involved are the primary dynamic stabilizers of the lumbar spine—the psoas major in the anterior compartment and the multifidus / erector spinae complexes in the posterior compartment. Each contributes to stability in its own way: the psoas major maintains lumbar lordosis and sagittal balance, the multifidus provides segmental rotational control, and the erector spinae participates in flexion–extension kinematics[23]. We did not directly assess muscle quality in this study, but the better pain relief and functional recovery observed in the one-stage group fit the interpretation that this approach entails less iatrogenic muscle injury.

During UBE procedures, partial medial facetectomy is essential to achieve adequate decompression, particularly for optimal foraminal enlargement and lateral recess clearance. Biomechanical studies quantify the critical load-bearing role of facet joints: these structures bear up to 25% of axial compressive loads and 40-65% of rotational shear stresses in lumbar spinal segments[24]. Finite element modeling reveals that facet resection exceeding 30% significantly increases segmental ROM, facet contact forces, and intradiscal pressure in proportion to resection extent[25]. Teo et al.'s cadaveric study[26]demonstrated that 50% facet resection induces statistically significant alterations in translational and rotational stability indices. Current clinical consensus maintains that unilateral facet resection ≤50% preserves postoperative spinal stability, as evidenced by multiple biomechanical analyses[27]. Following the principle that maximal facet preservation helps minimize post-decompression instability, we maintained ipsilateral facet preservation rates above 70% and contralateral rates of 85% or higher in both groups. Notably, despite the reduced number of incisions in the one-stage

approach, facet preservation was comparable between the two groups. This suggests that the intermediate longitudinal portal can be repositioned flexibly along the craniocaudal axis, allowing the same decompression field to be achieved without more extensive facet resection. Because the longitudinal incision serves as the viewing portal for one level and the working portal for the adjacent level, a single muscle interval can support both visualization and instrument access. This arrangement also avoids repeated sheath friction against the multifidus, which may account for the muscle-protective effect observed in the one-stage group.

Neither group developed clinically defined lumbar instability during follow-up, but the two-stage group showed significantly greater progressive increases in vertebral translation and range of motion at L4–5. These changes remained within established safe thresholds, yet they align with the cumulative paraspinal muscle injury sustained in that group and its effect on dynamic stabilization. The multifidus and erector spinae are the key muscles for rotational control and flexion–extension. As more extensive surgical trauma compromises their function, the spine depends increasingly on passive osteoligamentous structures, which may manifest as subtle increases in segmental motion.The clinical significance of these radiographic differences remains uncertain, but they raise the possibility that the two-stage approach may carry a slightly higher long-term risk of progressive segmental degeneration or late instability, particularly under conditions of increased dynamic loading. Disc height, in contrast, showed similar trends over time in both groups, which is expected given that disc degeneration is primarily driven by intrinsic biological factors rather than surgical technique in the short to medium term. However, the subtle increase in dynamic load observed in the two-stage group could theoretically accelerate disc height loss over extended follow-up, although this remains speculative.

The complication profiles were comparable between groups, with no evidence that performing both levels in a single session increases intraoperative or early postoperative risks. Literature documents dural tears as the most frequent UBE complication (4.5%-13.2%)[28, 29]. Our cohort demonstrated a 3.66% incidence (3/82 cases) in one-stage group and 2.74% incidence (2/73 cases) in two-stage group. Among these cases, three patients presented with severe central spinal canal stenosis, while two patients demonstrated ligamentum flavum hypertrophy with calcification. Intraoperative findings revealed dense adhesions between the dural sac and ligamentum flavum. Following partial removal of the ligamentum flavum, expansion of the dural sac subsequently led to dural tears during further decompression procedures. Notably, the arachnoid mater remained intact in both patients without evidence of cauda equina herniation. Primary dural repair was not attempted intraoperatively. Postoperative management included intravenous hydration and symptomatic management, which successfully prevented cerebrospinal fluid leakage. Based on our experience, we recommend the following sequence for UBE decompression. First, expose the ligamentum flavum completely, from its origin to its insertion. Use a dissector to lift the ligament away from its central portion, then continue with gentle dissection until the ligamentum flavum is fully separated from the dural sac. Remove the freed ligament with pituitary or Kerrison rongeurs of suitable size. For the contralateral ligamentum flavum, begin the same way with a dissector, then use a curette to excavate the remaining ligamentous tissue layer by layer, which markedly lowers the risk of dural injury. When dense focal adhesions make safe separation impossible, leave the adherent inner layer alone: remove the outer and middle laminar layers while preserving the layer attached to the dura. This still yields adequate decompression and normal dural expansion without compromising dural integrity.

Several limitations of this study should be acknowledged. The retrospective, non-randomized design introduces potential selection bias, despite comparable baseline characteristics between groups. The single-center nature limits generalizability, and the sample size, while adequate for the primary comparisons, may not be sufficient for robust subgroup analyses. Although the mean follow-up extended to nearly two years, longer-term outcomes—particularly regarding adjacent segment degeneration, progressive instability, and late functional decline—remain unknown. Additionally, direct assessment of paraspinal muscle quality using MRI or ultrasound was not performed, so the proposed muscle-protective mechanism, while biologically plausible, remains indirect. Future studies incorporating quantitative muscle evaluation and longer follow-up would be valuable to confirm these findings.

5. Conclusions

This study provides evidence that one-stage triple-incision UBE is a safe, effective, and muscle-sparing alternative to two-stage UBE for selected patients with two-level DLCS. The comparable decompression efficacy, coupled with superior functional outcomes, better perioperative efficiency, and more favorable stability parameters, supports the adoption

of the one-stage approach when clinically appropriate. Prospective, multicenter randomized trials with extended follow-up and comprehensive muscle imaging are warranted to validate these observations and further elucidate the mechanisms underlying the observed differences.

6. List of abbreviations

The following abbreviations are used in this manuscript:

DLCS	Degenerative Lumbar Canal Stenosis
PTED	Percutaneous Transforaminal Endoscopic Discectomy
UBE	Unilateral Biportal Endoscopic
VAS	Visual Analog Scale
JOA	Japanese Orthopedic Association
ODI	Oswestry Disability Index
CSDA	Cross-sectional Dural Area
ROM	Range of Motion
VTD	Vertebral Translation Distance
DH	Disc Height

7. Declarations

Clinical trial number: Not applicable.

Ethics approval and consent to participate : The study was conducted in accordance with the Declaration of Helsinki, and approved by the Ethics Committee of The Eighth People's Hospital of Hefei (protocol code 2024060701 and date of approval 2024-06-07) for studies involving humans.

Consent for publication： Not Applicable.

Availability of data and materials： All the data and material generated during the current study are available from the corresponding author upon reasonable request (sunwx_225@126.com).

Competing interests： The authors declare no conflicts of interest.

Funding: This research was funded by Key Natural Science Project of Bengbu Medical University for Member Institutions of the Health Alliance and Non-directly Affiliated Hospitals (2024byzd433).

Authors' contributions: Conceptualization, Chengwu Yang; methodology, Chengwu Yang; data curation, Dewen Shi, Zaibao Wang, Guixia Cao; writing—original draft preparation, Chengwu Yang ; writing—review and editing, Chengwu Yang and Weixiang Sun. All authors have read and agreed to the published version of the manuscript.

Acknowledgments: We would like to thank Director Huang Ying from the Pain Department of Nanjing Drum Tower Hospital for her guidance and assistance in this research.

References

1. Schroeder, G.D., M.F. Kurd, and A.R. Vaccaro, *Lumbar Spinal Stenosis: How Is It Classified?* J Am Acad Orthop Surg, 2016. 24(12): p. 843-852.

2. Bai, Q., et al., *Current understanding of tandem spinal stenosis: epidemiology, diagnosis, and surgical strategy.* EFORT Open Rev, 2022. 7(8): p. 587-598.

3. Katz, J.N., et al., *Diagnosis and Management of Lumbar Spinal Stenosis: A Review.* JAMA, 2022. 327(17): p. 1688-1699.

4. Malik, K.N., et al., *Pain Management Interventions in Lumbar Spinal Stenosis: A Literature Review.* Cureus, 2023. 15(8): p. e44116.

5. Bao, B.X., et al., *Transforaminal Endoscopic Discectomy and Foraminoplasty for Treating Central Lumbar Stenosis.* Orthop Surg, 2019. 11(6): p. 1093-1100.

6. Zou, H.J., et al., *Percutaneous Endoscopic Transforaminal Lumbar Discectomy via Eccentric Trepan foraminoplasty Technology for Unilateral Stenosed Serve Root Canals.* Orthop Surg, 2020. 12(4): p. 1205-1211.

7. Ahn, Y. and J.H. Jung, *Transforaminal Endoscopic Lumbar Lateral Recess Decompression for Octogenarian Patients.* J Clin Med, 2024. 13(2).

8. Li, J., X. Xu, and Y. Shui, *Percutaneous endoscopic transforaminal decompression surgery for symptomatic double-level lumbar spinal stenosis with ossification.* Medicine (Baltimore), 2024. 103(37): p. e39704.

9. Soliman, H.M., *Irrigation endoscopic discectomy: a novel percutaneous approach for lumbar disc prolapse.* 2013. 22(5): p. 1037-1044.

10. Soliman, H.M., *Irrigation endoscopic decompressive laminotomy. A new endoscopic approach for spinal stenosis decompression.* The Spine Journal, 2015. 15(10): p. 2282-2289.

11. Gandham, E.J., N.R. Uvaraj, and J.H. Eum, *Unilateral Biportal Percutaneous Transforaminal Endoscopic Lumbar Foraminal Decompression and Discectomy: A Technical Note.* Neurol India, 2022. 70(2): p. 510-514.

12. Zhang Jing, W.F., Yang Li, Ma Yuanbo, Li Na, Wang Peira, *Correlation between the quartering method of nerve root subsidence sign and the cross-sectional area of the narrow segment thecal sac in patients with lumbar spinal stenosis.* Journal of Chinese Physician, 2023. 25(8): p. 1219-1224.

13. Li Dong yue, S.Q.j., Zhang Xi nuo, Tao Lu ming, Hai Yong, *Unilateral biportal endoscopy for the treatment of multilevel degenerative lumbar disease.* Orthopedic Journal of China, 2024. 32(19): p. 1807-1810+1815.

14. Park, D.K., et al., *Unilateral Biportal Endoscopy for Lumbar Spinal Stenosis and Lumbar Disc Herniation.* JBJS Essent Surg Tech, 2023. 13(2).

15. Sharma, E., et al., *Minimally invasive decompression versus open laminectomy in multilevel lumbar stenosis: A systematic review and meta-analysis.* World Neurosurg, 2025: p. 124031.

16. Choi, C.M., et al., *How I do it? Biportal endoscopic spinal surgery (BESS) for treatment of lumbar spinal stenosis.* Acta Neurochir (Wien), 2016. 158(3): p. 459-63.

17. Hu, Y., et al., *Clinical efficacy and imaging outcomes of unilateral biportal endoscopy with unilateral laminotomy for bilateral decompression in the treatment of severe lumbar spinal stenosis.* Front Surg, 2022. 9: p. 1061566.

18. Kim, J.E. and D.J. Choi, *Unilateral biportal endoscopic decompression by 30 degrees endoscopy in lumbar spinal stenosis: Technical note and preliminary report.* J Orthop, 2018. 15(2): p. 366-371.

19. Li, C., et al., *Efficacy and safety of unilateral biportal endoscopy compared with microscopic decompression in the treatment of lumbar spinal stenosis: A protocol for systematic review and meta-analysis.* Medicine (Baltimore), 2021. 100(50): p. e27970.

20. Zhang, Y., et al., *[Early-effectiveness of unilateral biportal endoscopic laminectomy in treatment of two-level lumbar spinal stenosis].* Zhongguo Xiu Fu Chong Jian Wai Ke Za Zhi, 2023. 37(6): p. 706-712.

21. Yamamoto, S., et al., *The Effect of Posterior Lumbar Spinal Surgery on Biomechanical Properties of Rat Paraspinal Muscles 13 Weeks After Surgery.* Spine (Phila Pa 1976), 2021. 46(21): p. E1125-E1135.

22. Kang, S., et al., *The Effects of Paraspinal Muscle Volume on Physiological Load on the Lumbar Vertebral Column: A Finite-Element Study.* Spine (Phila Pa 1976), 2021. 46(19): p. E1015-E1021.

23. Vives, M.J., *The paraspinal muscles and their role in the maintenance of global spinal alignment. Another wrinkle in an already complex problem.* Spine J, 2016. 16(4): p. 459-61.

24. Naserkhaki, S., J.L. Jaremko, and M. El-Rich, *Effects of inter-individual lumbar spine geometry variation on load-sharing: Geometrically personalized Finite Element study.* J Biomech, 2016. 49(13): p. 2909-2917.

25. Ahuja, S., et al., *Lumbar stability following graded unilateral and bilateral facetectomy: A finite element model study.* Clin Biomech (Bristol), 2020. 75: p. 105011.

26. Teo, E.C., et al., *The biomechanics of lumbar graded facetectomy under anterior-shear load.* IEEE Trans Biomed Eng, 2004. 51(3): p. 443-9.

27. Kim, J.E., et al., *Biportal Endoscopic Spinal Surgery for Lumbar Spinal Stenosis.* Asian Spine J, 2019. 13(2): p. 334-342.

28. Park, H.J., et al., *Dural Tears in Percutaneous Biportal Endoscopic Spine Surgery: Anatomical Location and Management.* World Neurosurg, 2020. 136: p. e578-e585.

29. Lee, H.G., et al., *Dural Injury in Unilateral Biportal Endoscopic Spinal Surgery.* Global Spine J, 2021. 11(6): p. 845-851.