Research Square

Preprints are preliminary reports that have not undergone peer review.
They should not be considered conclusive, used to inform clinical practice,
or referenced by the media as validated information.

Delayed Full-Thickness Macular Hole After Acute Postoperative Macular Ischemia Following Combined Vitreoretinal Surgery: A Case Report

Haibo Li

hyberlee@163.com

Xiamen Eye Center and Eye Institute of Xiamen University

Yiling Zhou

Xiamen Eye Center and Eye Institute of Xiamen University

Shuxin Cai

Xiamen Eye Center and Eye Institute of Xiamen University

Xiaohu Zhang

Xiamen Eye Center and Eye Institute of Xiamen University

Research Article

Keywords: macular infarction, macular hole, retinal detachment, vitrectomy, silicone oil

Posted Date: November 25th, 2026

DOI: https://doi.org/10.21203/rs.3.rs-11425333/v1

License: This work is licensed under a Creative Commons Attribution 4.0 International License.
Read Full License

Additional Declarations: No competing interests reported.

Delayed Full-Thickness Macular Hole After Acute Postoperative Macular Ischemia Following Combined Vitreoretinal Surgery: A Case Report

Haibo Li, MD[1,2]; Yiling Zhou[1,2]; Shuxin Cai, MD[1]; Xiaohu Zhang[1]

1, Xiamen Eye Center and Eye Institute of Xiamen University, School of Medicine, Xiamen 361000, Fujian Province, China

2, Department of Fundus Disease, Shenzhen Nanshan Huaxia Eye Hospital, Shenzhen 518000, China.

Correspondence: Haibo Li, Email: hyberlee@163.com;

Abstract

Background

Ischemic macular holes are rare complications of retinal vascular occlusive disease. However, the development of a full-thickness macular hole (FTMH) following acute postoperative macular ischemic injury has rarely been documented.

Case presentation

A 53-year-old man with rhegmatogenous retinal detachment underwent combined pars plana vitrectomy, scleral buckling, and silicone oil tamponade. Preoperative optical coherence tomography (OCT) showed a normal macular contour. No indocyanine green or Brilliant Blue G was used, and the internal limiting membrane (ILM) was not peeled. On postoperative day 1, central macular whitening with a cherry-red foveal appearance was observed. OCT demonstrated marked thickening and hyperreflectivity of the inner retinal layers, consistent with acute macular ischemic injury. The patient was managed conservatively. Two weeks later, metamorphopsia developed, and OCT revealed an FTMH measuring 388 μm in minimum diameter with temporal ILM schisis. The hole progressively enlarged during the following month. Silicone oil removal combined with macular hole repair was subsequently performed. The macular hole achieved complete anatomical closure, and best corrected visual acuity improved to 20/200 and remained stable during 6 months of follow-up.

Conclusions

Acute postoperative focal macular ischemia maybe followed by delayed FTMH formation and rapid enlargement. Serial OCT in this case suggests that ischemic injury to the inner retina and foveal structural framework may contribute to progressive foveal dehiscence.

Keywords: macular infarction; macular hole; retinal detachment; vitrectomy; silicone oil.

Background

Full-thickness macular hole is traditionally associated with vitreofoveal traction, but secondary macular holes may also occur after retinal vascular occlusion. Several reports have described macular hole formation following retinal arterial or combined retinal vascular occlusion, suggesting that severe retinal ischemia can produce foveal structural disruption independent of vitreofoveal traction [1-3].

Acute retinal ischemia produces characteristic OCT changes, including inner retinal thickening and hyperreflectivity, followed by retinal thinning and atrophy [4-6]. Internal limiting membrane abnormalities have also been observed in severe acute retinal ischemia, including cases accompanied by macular hole formation[7,8].

We report a case of acute postoperative focal macular ischemic injury followed by delayed formation and rapid enlargement of an FTMH after combined vitrectomy, scleral buckling, and silicone oil tamponade for rhegmatogenous retinal detachment.

Case presentation

A 53-year-old man with rhegmatogenous retinal detachment underwent combined pars plana vitrectomy, scleral buckling, and silicone oil tamponade. Preoperative fundus examination revealed an inferior retinal hole with inferior retinal detachment (Figure 1). Preoperative OCT demonstrated an inferior retinal detachment, with no macular hole, or macular edema (Figure 2).

The surgical procedure was completed without an apparent intraoperative complication. No indocyanine green or Brilliant Blue G was used during surgery, and the ILM was not peeled. On postoperative day 1, fundus examination revealed prominent central macular whitening with a relatively reddish foveal center (Figure 3). OCT demonstrated marked thickening and hyperreflectivity of the inner retinal layers in the macular region (Figure 4), findings consistent with acute retinal ischemic injury. The patient was managed conservatively with postoperative medical treatment, and the macular changes were monitored clinically and by OCT during the early postoperative period. Two weeks after surgery, the patient developed new-onset metamorphopsia. Fundus examination revealed a full-thickness macular defect (Figure 5). OCT confirmed an FTMH with a minimum diameter of 388 μm, accompanied by temporal ILM schisis (Figure 6). Serial OCT examinations during the following month demonstrated progressive enlargement of the macular hole (Figure 7). The temporal ILM schisis persisted, suggesting continuing structural instability of the foveal region. Because of progressive enlargement of the FTMH, silicone oil removal combined with macular hole repair was subsequently performed. Postoperatively the macular hole achieved complete anatomical closure (Figure8 and Figure 9). Best-corrected visual acuity improved to 20/200. At 6 months of follow-up, the macular hole remained closed without recurrence, and visual acuity remained stable at 20/200.

Discussion

Ischemic macular holes are increasingly recognized as a distinct entity from idiopathic tractional FTMHs. Previous reports have documented FTMH after CRAO[1], and Sen et al. emphasized irregular hole margins, inner retinal edema, and an intact posterior hyaloid, supporting an ischemic rather than vitreofoveal tractional mechanism[2]. Similar findings have been described in combined retinal vascular occlusion[3]. However, these reports primarily describe macular hole formation after spontaneously occurring retinal vascular occlusion. Our case differs in two important respects: the macula was documented to be normal before surgery, and the ischemic insult occurred in the immediate postoperative period after combined vitrectomy, scleral buckling, and silicone oil tamponade. This temporal sequence allowed us to

observe the evolution from acute macular ischemia to delayed FTMH formation. In addition, no indocyanine green or Brilliant Blue G was used, and the ILM was not peeled, making direct dye-related or ILM-peeling-related injury unlikely.

The structural basis for ischemia-related foveal dehiscence is supported by OCT studies of acute CRAO. Acute retinal ischemia typically produces inner retinal thickening and hyperreflectivity, followed by progressive retinal thinning and atrophy [4,5]. Venkatesh et al. reported ILM detachment in acute CRAO, particularly in eyes with severe inner retinal ischemic damage; notably, one case developed an FTMH accompanied by ILM detachment and retinal atrophy [8]. A larger multimodal study subsequently confirmed that ILM detachment in acute CRAO was associated with macular nonperfusion and later resolved with fragmentation, disruption, and retinal atrophy [7]. These observations suggest that ischemic injury may compromise the structural integrity of the fovea through both inner retinal damage and ILM abnormalities.

The Müller cell architecture may be particularly important in this process. The Müller cell cone has been proposed as a key structural component of the foveal center, and OCT studies indicate that Müller cells contribute to the stabilization and remodeling of foveal tissue [9]. In our patient, the temporal ILM schisis observed at the time of FTMH development may represent an intermediate stage of ischemia-associated structural weakening. Although a causal mechanism cannot be established from a single case, the sequence of acute ischemic injury, subsequent ILM abnormality, and delayed FTMH formation is consistent with a non-tractional pathway. Importantly, no FTMH was present on the first postoperative examination despite obvious acute macular ischemic changes; the hole appeared approximately two weeks later and then enlarged progressively. This delayed course suggests that ischemia may initiate a process of progressive foveal structural failure rather than causing an immediate full-thickness defect.

The precise cause of the acute postoperative ischemic event in our patient remains uncertain. The combined procedure included vitrectomy, scleral buckling, and silicone oil tamponade, each of which may alter the postoperative ocular and retinal environment. Scleral buckling is particularly relevant because experimental and clinical studies have demonstrated changes in ocular and retinal hemodynamics after encircling buckle placement. Regillo et al. reported an immediate postoperative reduction of up to 53% in central retinal artery blood-flow velocity after scleral buckling[10]. Another Doppler study showed reduced retrobulbar blood-flow parameters after scleral buckling, and previous case reports have described visual dysfunction associated with reduced ocular blood flow after encircling buckle placement [11]. These findings provide a plausible basis for considering altered retinal perfusion as one potential contributor in the present case.

Postoperative retinal vascular occlusion has also been reported after vitreoretinal surgery. Proposed contributing factors include periocular anesthesia, elevated intraocular pressure, systemic vascular risk factors, and drug-related vascular toxicity [12]. Silicone oil represents another possible factor. Toxic posterior segment syndrome with retinal vascular occlusion immediately after silicone oil injection has recently

been reported, with improvement following silicone oil removal [13]. Nevertheless, the clinical findings in our patient were not sufficient to establish silicone oil toxicity as the cause of the ischemic event. Thus, the postoperative macular infarction in this case was probably multifactorial, potentially involving changes in retinal perfusion associated with the combined surgical procedure.

This case suggests a potential sequence of acute postoperative macular ischemia followed by delayed FTMH formation and rapid enlargement. The initial ischemic changes preceded the macular hole by approximately two weeks, indicating that the structural consequences of acute ischemia may evolve after the initial clinical event. Early OCT and serial structural imaging may therefore be useful. Particular attention should be paid to the development of ILM abnormalities or progressive foveal architectural disruption. Further studies with serial multimodal imaging are needed to clarify the mechanisms linking acute macular ischemia to delayed FTMH formation after combined vitreoretinal surgery.

Conclusion

Acute postoperative focal macular ischemia may be followed by delayed FTMH formation and rapid enlargement. The combined vitreoretinal surgery may alter retinal perfusion through several potential perioperative mechanisms, although the precise cause of the ischemic event remains uncertain. Early postoperative OCT and continued structural surveillance may help identify delayed macular complications after vitreoretinal surgery.

Authors' contributions

HBL conceived the study, performed the surgical treatment, analyzed the clinical data, and drafted the manuscript. SXC and XHZ contributed to clinical evaluation, imaging interpretation, and literature review. All authors critically revised the manuscript and approved the final version.

Ethics approval and consent

Not applicable.

Consent for publication

Written informed consent was obtained from the patient for publication of the clinical details and ophthalmic images included in this report.

Competing interests

The authors declare that they have no competing interests.

Funding

Not applicable.

Data availability

All data generated or analyzed during this study are included in this published article.

Acknowledgements

Not applicable.

Figure legends

Figure 1. Preoperative fundus photograph demonstrates an inferior retinal break with associated inferior retinal detachment.

Figure 2. Preoperative OCT demonstrates inferior retinal detachment without evidence of macular hole or macular edema.

Figure 3. Fundus photograph on postoperative day 1 demonstrates prominent central macular whitening with a relatively reddish foveal center.

Figure 4. OCT obtained on postoperative day 1 demonstrates marked thickening and hyperreflectivity of the inner retinal layers in the macular region.

Figure 5. Fundus photograph on postoperative two weeks demonstrates newly developed full-thickness macular hole following the acute postoperative macular ischemic event.

Figure 6. OCT on postoperative two weeks demonstrates a full-thickness macular hole with a minimum diameter of 388 μm and associated temporal internal limiting membrane schisis.

Figure 7. OCT examinations during the subsequent month demonstrate progressive enlargement of the full-thickness macular hole, with persistent temporal internal limiting membrane schisis.

Figure 8. Postoperative photograph following silicone oil removal and macular hole repair demonstrates complete anatomical closure of the macular hole.

Figure 9. Postoperative OCT following silicone oil removal and macular hole confirms persistent anatomical closure of the macular hole after surgical repair.

References

1. Levison AL, Schachat AP. Macular hole from a central retinal artery occlusion. *JAMA Ophthalmol*. Dec 2014;132(12):1493. doi:10.1001/jamaophthalmol.2014.549
2. Sen P, Vaidya H, Dutta Majumder P, Bawankule PK, Narnaware SH. Ischemic macular hole in central retinal artery occlusion. *Indian J Ophthalmol*. Aug 2020;68(8):1670-1671. doi:10.4103/ijo.IJO_67_20
3. Keorochana N, Vongkulsiri S, Choontanom R. Combined central retinal vein, central retinal artery and cilioretinal artery occlusion with ischemic macular hole secondary to severe orbital cellulitis after black fly bite. *Int Med Case Rep J*. 2019;12:125-134. doi:10.2147/IMCRJ.S189082
4. Falkenberry SM, Ip MS, Blodi BA, Gunther JB. Optical coherence tomography findings in central retinal artery occlusion. *Ophthalmic Surg Lasers Imaging*. Nov-Dec 2006;37(6):502-5. doi:10.3928/15428877-20061101-12
5. Wang H, Wei H, Dong J, et al. Optical coherence tomography findings in acute central retinal artery occlusion and their association with visual outcomes. *Int J Retina Vitreous*. Dec 11 2025;12(1):10. doi:10.1186/s40942-025-00770-6

6. Yu S, Pang CE, Gong Y, et al. The spectrum of superficial and deep capillary ischemia in retinal artery occlusion. *Am J Ophthalmol*. Jan 2015;159(1):53-63 e1-2. doi:10.1016/j.ajo.2014.09.027
7. Jain M, Narayanan R, Barik B, Sahoo NK, Raval V, Reddy NG. Internal limiting membrane detachment in acute Central Retinal Artery Occlusion: clinical features, multimodal imaging, outcomes & prognostic biomarker. *Int J Retina Vitreous*. Dec 28 2022;8(1):86. doi:10.1186/s40942-022-00436-7
8. Venkatesh R, Jayadev C, Sridharan A, et al. Internal limiting membrane detachment in acute central retinal artery occlusion: a novel prognostic sign seen on OCT. *Int J Retina Vitreous*. Sep 3 2021;7(1):51. doi:10.1186/s40942-021-00323-7
9. Bringmann A, Unterlauft JD, Wiedemann R, Rehak M, Wiedemann P. Morphology of partial-thickness macular defects: presumed roles of Muller cells and tissue layer interfaces of low mechanical stability. *Int J Retina Vitreous*. 2020;6:28. doi:10.1186/s40942-020-00232-1
10. Regillo CD, Sergott RC, Brown GC. Successful scleral buckling procedures decrease central retinal artery blood flow velocity. *Ophthalmology*. Jul 1993;100(7):1044-9. doi:10.1016/s0161-6420(93)31541-1
11. Hanioglu-Kargi S, Yazar Z, Ziraman I, Gursel E. Effects of scleral buckling on the retrobulbar haemodynamic changes. *Eye (Lond)*. Apr 2000;14 (Pt 2):165-71. doi:10.1038/eye.2000.47
12. Murao F, Kinoshita T, Katome T, Sano H, Niki M, Mitamura Y. Suspected Gentamicin-Induced Retinal Vascular Occlusion after Vitrectomy. *Case Rep Ophthalmol*. May-Aug 2020;11(2):473-480. doi:10.1159/000509337
13. Kumoi M, Matsuda S, Matsumoto M, Tsujino C, Otori Y. Toxic posterior segment syndrome caused by silicone oil tamponade resulting in postsurgical retinal vascular occlusion: a case report. *Am J Ophthalmol Case Rep*. Sep 2025;39:102404. doi:10.1016/j.ajoc.2025.102404





2025-11-01, OS

IR&OCT 30° ART [HS] ART(26) Q: 27

HEIDELBERG ENGINEERING

OS



ZEISS CLARUS™


200 µm

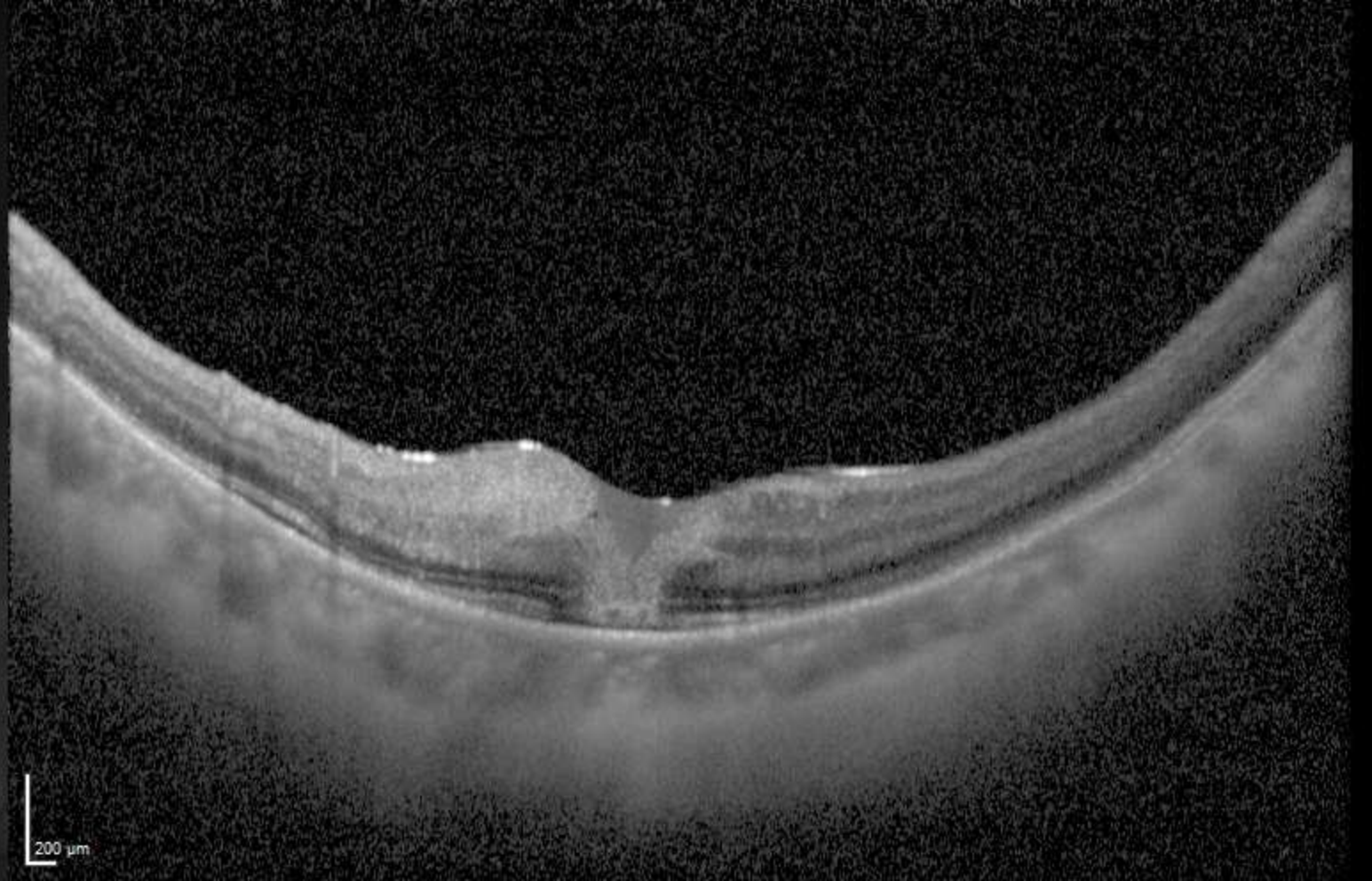
200 µm

OS

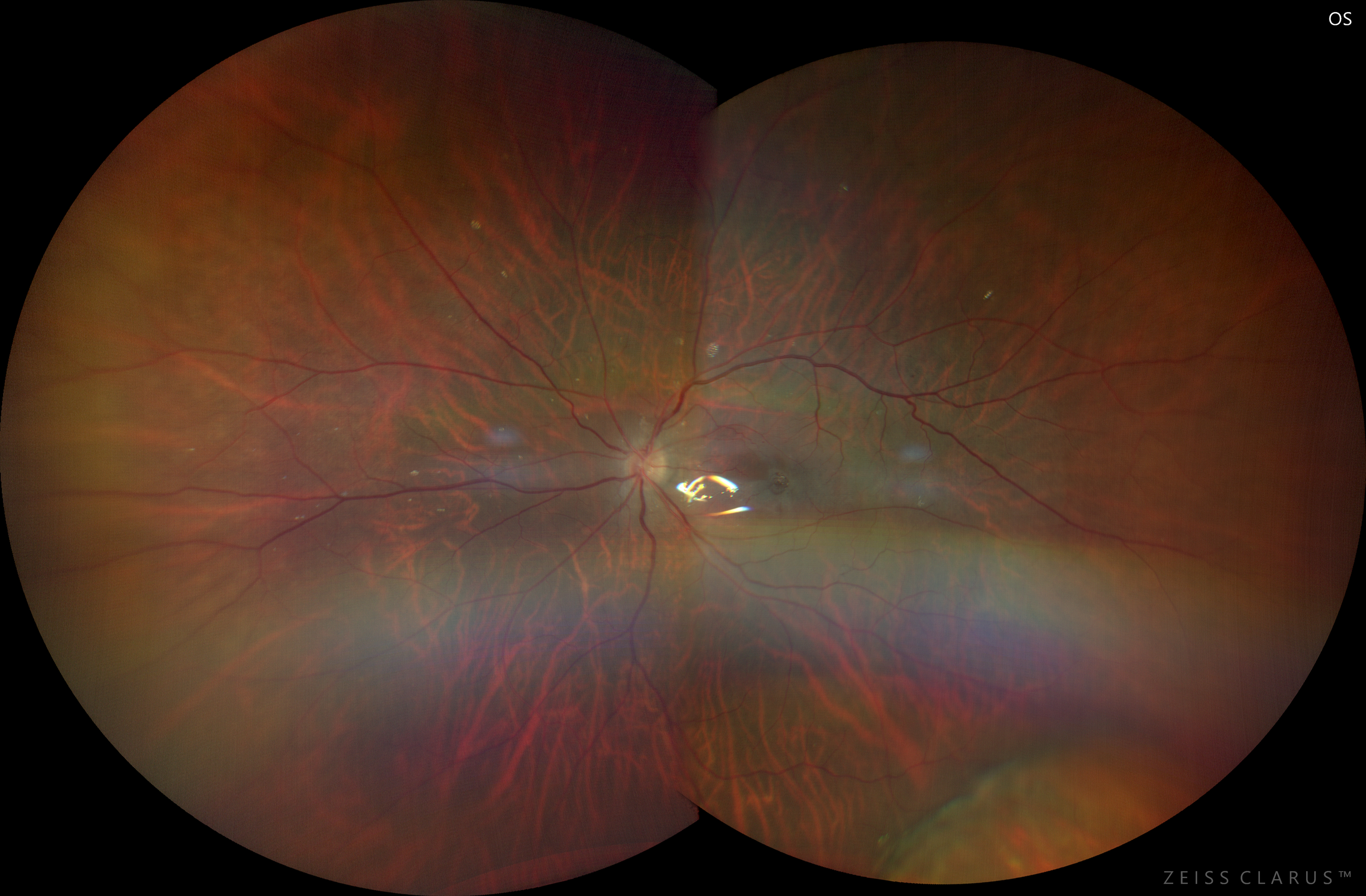

ZEISS CLARUS™

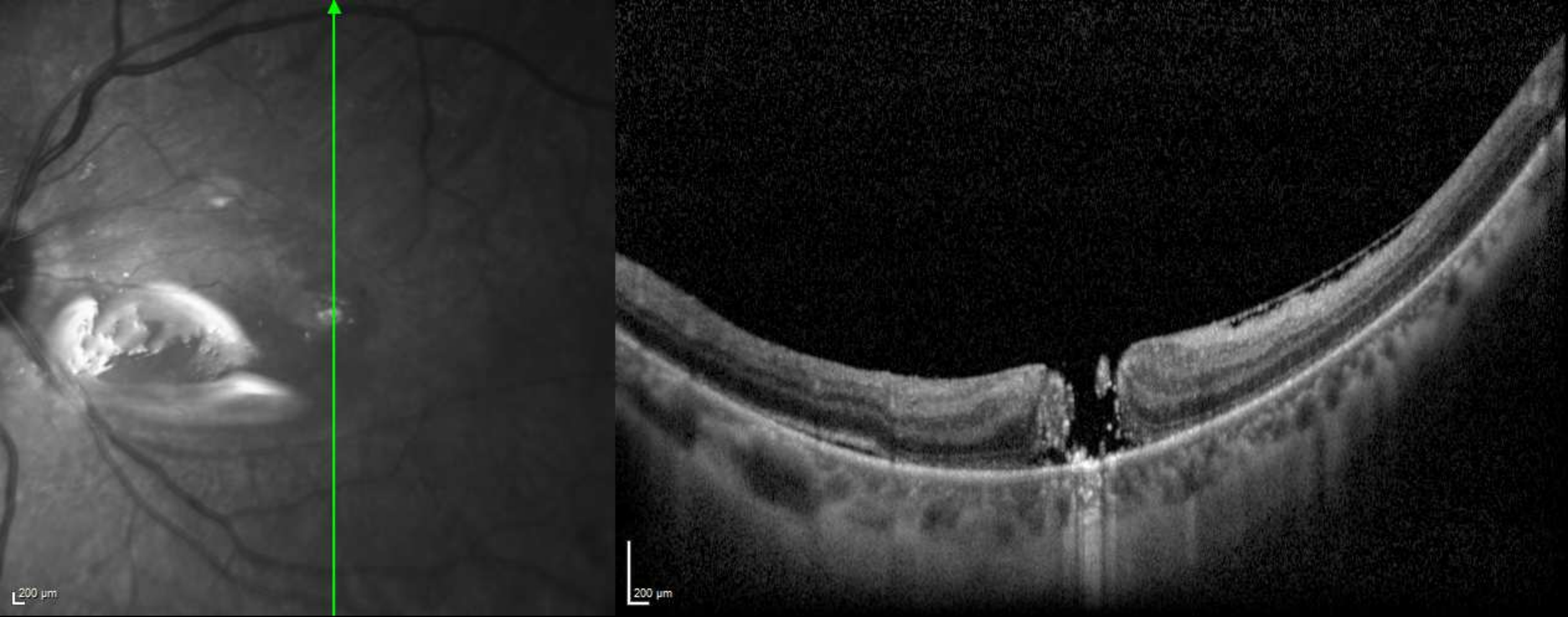
200 µm
200 µm

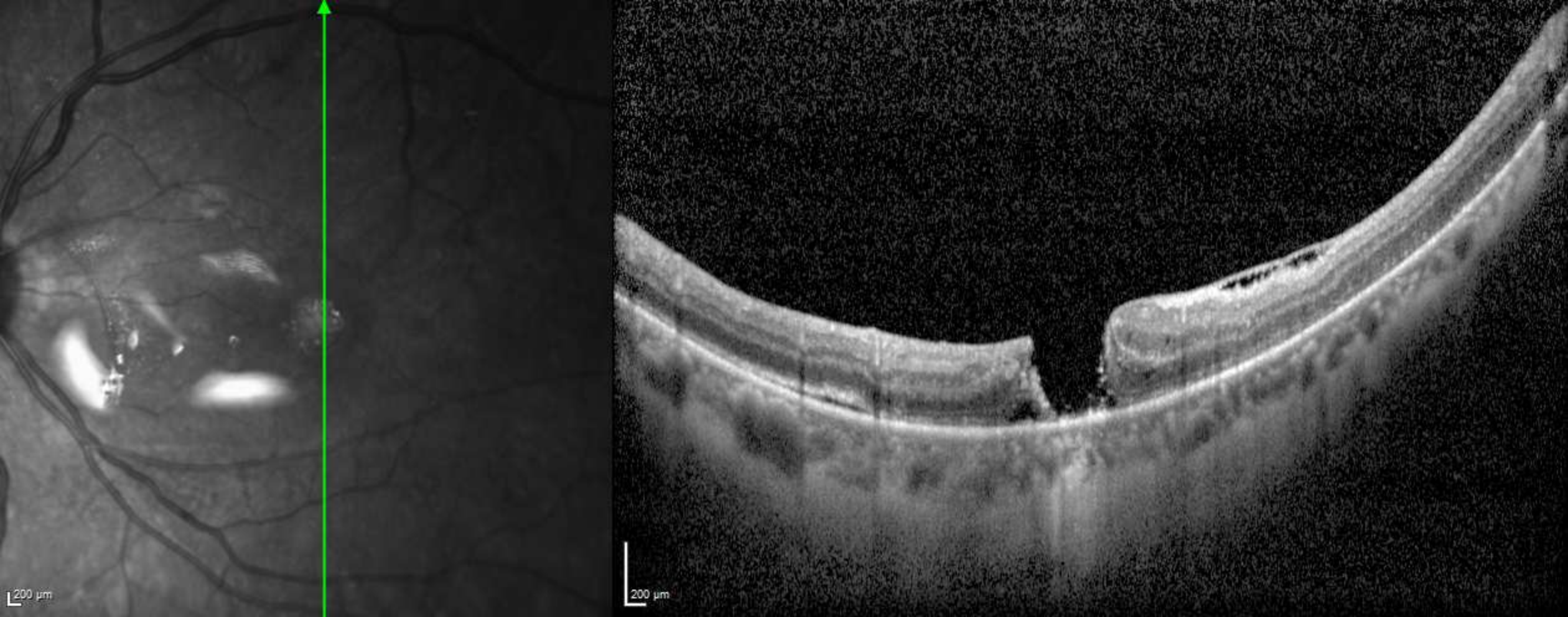
200 µm
200 µm

OS

ZEISS CLARUS™

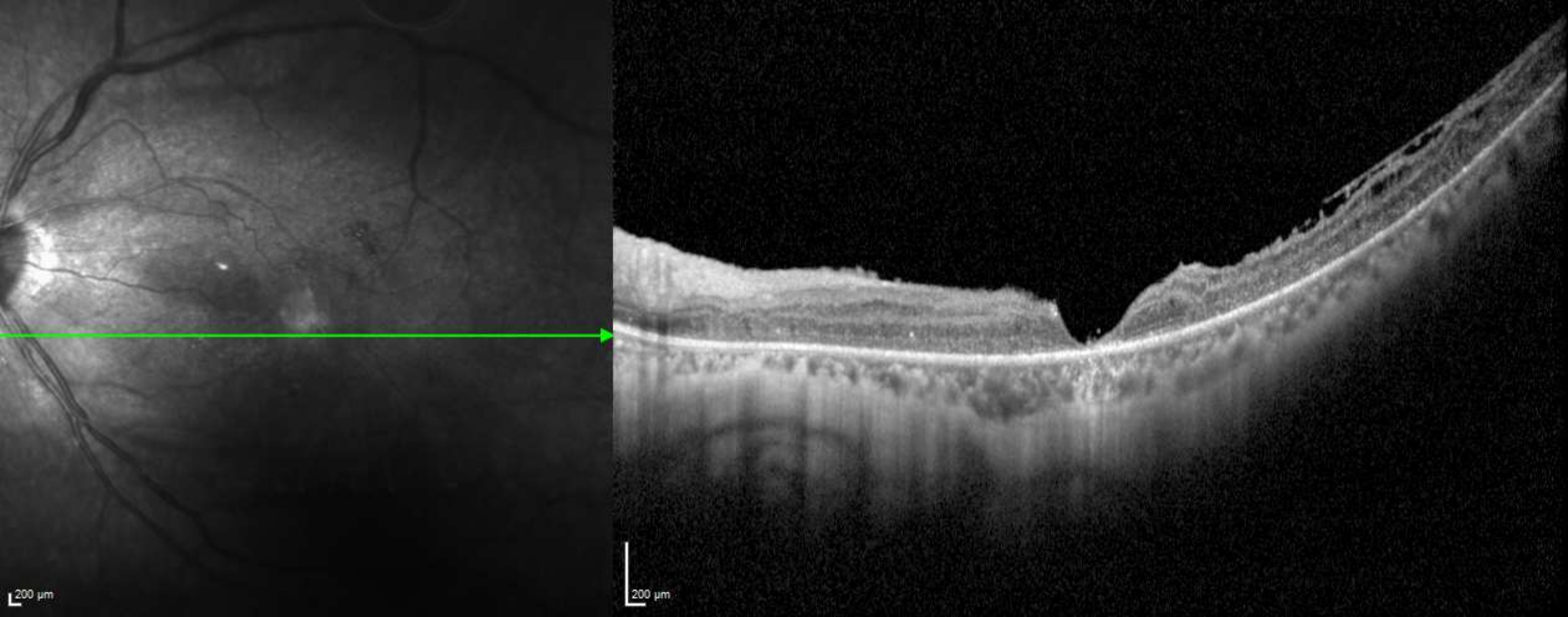
200 µm
200 µm