Research Square

Preprints are preliminary reports that have not undergone peer review.
They should not be considered conclusive, used to inform clinical practice,
or referenced by the media as validated information.

Life-threatening focal esophageal hemorrhage during EVAHEART left ventricular assist device support: a case report

Yue Zhu
Zhejiang University School of Medicine
Qiongli Zhou
Zhejiang University School of Medicine
Yelin Cao
Zhejiang University School of Medicine
Yangyang Jia
Zhejiang University School of Medicine
Wenqiao Yu
Zhejiang University School of Medicine
Guobin Wang
Zhejiang University School of Medicine
Hongliu Cai
Zhejiang University School of Medicine
Hua Zhou
hua__zhou@163.com

The Second Affiliated Hospital of Zhejiang University School of Medicine，Hangzhou

Case Report

Keywords: EVAHEART, left ventricular assist device, esophageal hemorrhage, gastrointestinal bleeding, VA-ECMO, anticoagulation

Posted Date: November 26th, 2026

DOI: https://doi.org/10.21203/rs.3.rs-11417866/v1

License: This work is licensed under a Creative Commons Attribution 4.0 International License.
Read Full License

Additional Declarations: No competing interests reported.

Abstract

Background

Gastrointestinal bleeding is a recognized complication of durable left ventricular assist device (LVAD) support. However, severe focal esophageal hemorrhage during EVAHEART support presents diagnostic and therapeutic challenges. We report a case of recurrent, life-threatening esophageal hemorrhage in a patient receiving EVAHEART after venoarterial extracorporeal membrane oxygenation (VA-ECMO) bridging.

Case presentation

A 40-year-old man with acute myocardial infarction complicated by cardiogenic shock underwent high-risk percutaneous coronary intervention under VA-ECMO support. Persistent severe cardiac dysfunction led to EVAHEART LVAD implantation on 14 January 2026, followed by VA-ECMO removal two days later. During a second hospitalization beginning on 20 April 2026, the patient developed recurrent upper gastrointestinal bleeding. Emergency endoscopy on 27 April revealed a raised esophageal lesion approximately 25 cm from the incisors, with a central depression and brisk pulsatile bleeding. Endoscopic clipping did not achieve reliable immediate hemostasis. Hemoglobin fell to 54 g/L, and the patient received 9 units of red blood cells and 870 mL of plasma on 27–28 April. Computed tomography angiography (CTA) did not identify a definite bleeding vessel or active contrast extravasation, and local artifact limited assessment of the affected region. Hematemesis recurred on 13 May. Repeat endoscopy demonstrated a visible vessel at the same esophageal site without active bleeding. CTA did not establish an aortoesophageal fistula. Antithrombotic therapy was interrupted during active bleeding and subsequently reintroduced in stages. No further clinically significant gastrointestinal bleeding was documented through 12 October 2026, during outpatient follow-up on warfarin.

Conclusions

Life-threatening focal esophageal hemorrhage can occur during EVAHEART support. In this case, repeat endoscopy provided the clearest localization of the bleeding site when CTA was nondiagnostic. The case highlights the importance of reassessing the bleeding source during recurrence and balancing hemorrhagic and thrombotic risks in patients receiving durable LVAD support.

Background

Durable left ventricular assist devices (LVADs) provide long-term mechanical circulatory support for patients with advanced heart failure. Despite improvements in device design and clinical management, bleeding and thrombotic events remain important hemocompatibility-related complications. Gastrointestinal bleeding is a major cause of morbidity in LVAD recipients, frequently requiring

transfusion, hospitalization, and interruption of antithrombotic therapy, which may in turn increase the risk of device-related thrombosis [1–8].

Temporary mechanical circulatory support, including VA-ECMO, may be required in refractory cardiogenic shock while myocardial recovery or transition to durable support is considered [9]. The pathophysiology of LVAD-associated gastrointestinal bleeding is multifactorial. Anticoagulant and antiplatelet therapy can aggravate hemorrhage, while continuous-flow support may alter primary hemostasis through acquired von Willebrand factor abnormalities and platelet dysfunction. Changes in vascular signaling and the development of gastrointestinal vascular lesions may also contribute to bleeding [1–7, 10]. These mechanisms may coexist, and the severity of hemorrhage cannot necessarily be explained by anticoagulation intensity alone.

EVAHEART is a centrifugal-flow LVAD designed to reduce shear-related blood trauma while maintaining pulsatility. Experimental comparisons have demonstrated less von Willebrand factor degradation with EVAHEART than with the axial-flow HeartMate II [11]. In a Japanese post-approval study involving 96 recipients, no gastrointestinal bleeding events were reported during the observation period [12]. However, these findings do not exclude the possibility of severe bleeding during EVAHEART support, particularly from a focal lesion with an underlying vascular abnormality.

We report a case of recurrent, life-threatening focal esophageal hemorrhage approximately three months after EVAHEART implantation in a patient initially supported with venoarterial extracorporeal membrane oxygenation (VA-ECMO) for refractory cardiogenic shock. The bleeding was characterized by brisk pulsatile hemorrhage from a localized esophageal lesion, whereas computed tomography angiography (CTA) failed to identify a definite arterial source. This case highlights the diagnostic challenges of recurrent focal esophageal bleeding during durable LVAD support and the need to balance hemorrhage control against the risk of thromboembolic complications.

Case presentation

Initial presentation and VA-ECMO-supported coronary intervention

A 40-year-old man with a 15-year history of recurrent chest pain was admitted to The First Affiliated Hospital, Zhejiang University School of Medicine, on 26 November 2025 with worsening chest pain. His initial heart rate was 111 beats/min, respiratory rate 25 breaths/min, oxygen saturation 86%, and blood pressure 93/53 mmHg. He was diagnosed with acute myocardial infarction complicated by cardiogenic shock.

Coronary angiography demonstrated complex multivessel coronary artery disease, including near-occlusion of the left anterior descending artery (LAD) ostium, distal left circumflex artery (LCx) occlusion, and severe stenosis of the first obtuse marginal branch. The LAD ostium partially enlarged

after intracoronary nitroglycerin, suggesting a vasospastic component in addition to fixed coronary disease. After coronary artery bypass grafting was discussed and declined by the family, high-risk percutaneous coronary intervention (PCI) was performed under venoarterial extracorporeal membrane oxygenation (VA-ECMO) support. Revascularization included intervention on the left main–LAD and LCx territories, with final angiography showing Thrombolysis in Myocardial Infarction (TIMI) grade 3 flow in the treated vessels.

Severe cardiac dysfunction persisted despite revascularization, and VA-ECMO could not be discontinued promptly. The ECMO course was complicated by several bleeding and vascular events. On 26 November 2025, a ruptured arterial branch in the right groin was identified during surgical exploration and ligated. On 4 December, angiography showed abnormal vascular staining in the left upper lung, and selective bronchial artery embolization reduced the abnormal staining and slowed flow. ECMO-access-related iliofemoral arterial thrombosis and intimal injury subsequently required thrombectomy, endarterectomy, and arterial reconstruction on 9 December.

Transition to durable LVAD support

Because of persistent circulatory failure and difficulty weaning from VA-ECMO, percutaneous atrial septostomy was performed under transesophageal echocardiographic guidance on 30 December 2025 for left-heart decompression. On 14 January 2026, the patient underwent implantation of an EVAHEART left ventricular assist device (LVAD) together with surgical closure of the atrial septal defect. The inflow cannula was positioned at the left ventricular apex, and the outflow graft was anastomosed to the ascending aorta. Intraoperative echocardiography showed satisfactory device function and no significant residual interatrial shunt.

On 15 January 2026, the documented pump speed was 1747 rpm and pump power was 2.7 W; a contemporaneous pump-flow value was not available. VA-ECMO was removed on 16 January, with femoral arterial thrombectomy and repair performed during decannulation. The patient continued on durable LVAD support.

Recurrent upper gastrointestinal bleeding and endoscopic localization

During a second hospitalization beginning on 20 April 2026, approximately three months after LVAD implantation, the patient presented with hematemesis, estimated at approximately 700 mL of bright-red blood. Hemoglobin was 81 g/L and the international normalized ratio (INR) was 2.01. Computed tomography (CT) showed blood within the stomach. Initial upper gastrointestinal endoscopy was limited by food residue and blood clot and did not identify a definite bleeding source. Warfarin and aspirin were withheld during active bleeding.

Repeat endoscopy on 21 April showed esophageal mucosal erosion and hematoma. A submucosal-appearing lesion along the lesser curvature of the gastric body had surface erosions and oozing and was treated with endoscopic clips and topical norepinephrine. No active bleeding was identified in the duodenal bulb or second portion. Bleeding temporarily stabilized after transfusion and supportive treatment.

Following recurrent hematemesis on 26 April, endoscopy under airway protection did not identify a definite active bleeding point. Emergency endoscopy on 27 April then revealed a raised, relatively firm esophageal lesion approximately 25 cm from the incisors, with a central depression and brisk pulsatile bleeding. Endoscopic clipping was attempted but did not provide reliable immediate hemostasis. The hemoglobin concentration fell to a nadir of 54 g/L. The patient received 9 units of red blood cells and 870 mL of plasma on 27–28 April.

The endoscopic appearance suggested a focal vascular source. An esophageal Dieulafoy-type lesion was considered because the mucosal abnormality was limited relative to the volume and pulsatile character of the bleeding; however, no histopathological confirmation was obtained. An aortoesophageal fistula was also considered. CTA showed a right-sided aortic arch and artifact around the affected region, but no definite active contrast extravasation or responsible vessel was identified. The findings did not establish an aortoesophageal fistula, although the examination did not definitively exclude one.

The gastric lesion identified on 21 April was a potential competing source during the initial evaluation. However, active pulsatile bleeding was directly observed from the esophageal lesion on 27 April, whereas repeat endoscopy did not demonstrate active bleeding from the treated gastric lesion or the duodenum. The recurrent brisk hemorrhage was therefore localized endoscopically to the esophagus, although the precise pathology of the lesion remained undetermined.

Coagulation tests varied during the bleeding episode. On 20 April, the prothrombin time (PT) was 22.3 s and the activated partial thromboplastin time (APTT) was 43.3 s. On 27 April, the INR was 1.17 at 10:00 and 1.59 at 13:52, with a PT of 18.6 s and an APTT of 42.5 s. By 30 April, the INR was 1.05, PT was 13.5 s, and APTT was 32.2 s. These results demonstrate temporal variation in coagulation tests but do not establish excessive warfarin effect as the sole cause of hemorrhage.

Recurrent bleeding, antithrombotic management, and follow-up

Management included transfusion, hemodynamic support, proton pump inhibitor therapy, somatostatin-based treatment, and nutritional support. Warfarin and aspirin were withheld during active bleeding. The available records do not fully document whether pharmacological reversal was administered or the precise timing of each interruption and resumption. Nadroparin 4100 IU once daily was documented from 5 May while warfarin remained withheld. On 5–6 May, the patient developed transient right-sided visual blurring or a visual-field disturbance. Embolic ischemia was considered, but no definite ocular vascular embolism was identified.

On 13 May, hematemesis recurred, with approximately 50 mL of fresh blood reported over 10 minutes, followed by profound hypotension (blood pressure 56/30 mmHg). Antithrombotic therapy was again withheld, and the patient was transferred to the intensive care unit. Endoscopy on 14 May showed a visible vessel at the previously identified esophageal site without active bleeding. At the treated gastric site, the clips remained in place; a small amount of blood beneath one clip stopped spontaneously after irrigation. No active bleeding was identified in the duodenum.

CTA of the thoracic and abdominal aorta showed postoperative changes and local artifact around the operative region. The artificial vascular graft was patent, with no reported contrast extravasation from the graft. Blood was present in the stomach, and a nodular enhancing focus adjacent to a gastric wall clip was reported; active bleeding at that site could not be excluded. CTA did not demonstrate a definite aortoesophageal fistula or identify a target vessel. After multidisciplinary review, conservative management was continued because no active hemorrhage was seen at repeat endoscopy and no target vessel had been identified for intervention.

The patient’s circulation stabilized, low-dose norepinephrine was discontinued, and the endotracheal tube was removed on 14 May. He was transferred out of the intensive care unit on 15 May. Hemoglobin was 77 g/L on 15 May and had increased to 106 g/L by 1 July. Nadroparin 5000 IU once daily was documented by 18 June as anticoagulation was gradually reintroduced. At discharge from the second hospitalization on 27 July 2026, warfarin 6 mg once daily and indobufen 100 mg twice daily were prescribed. Echocardiography on 21 July showed a left ventricular ejection fraction of 26%, without reported LVAD inflow or outflow obstruction.

Outpatient records documented warfarin at 1.75 tablets once daily from 8 September through 12 October 2026; the tablet strength was not specified. INR values during documented follow-up ranged from 1.66 to 2.32. The peripherally inserted central catheter was removed on 16 September. No further clinically significant gastrointestinal bleeding was documented through 12 October 2026. The clinical course and documented antithrombotic regimens are summarized in Table 1.

Table 1
Clinical timeline and antithrombotic management

Date	Clinical event	Key findings	Antithrombotic management and outcome
20 Apr 2026	Second hospitalization; initial presentation	Approximately 700 mL of bright-red hematemesis; hemoglobin (Hb) 81 g/L; international normalized ratio (INR) 2.01. CT showed blood within the stomach. Initial upper gastrointestinal endoscopy did not identify a definite bleeding source.	Warfarin and aspirin were withheld during active bleeding.
21 Apr 2026	Repeat endoscopy	Esophageal mucosal erosion and hematoma; a submucosal-appearing lesion along the lesser curvature of the stomach showed surface erosions and oozing. No active bleeding was identified in the duodenum.	Endoscopic clipping and topical norepinephrine were applied to the gastric lesion. Close monitoring and supportive treatment continued.
26–28 Apr 2026	Recurrent life-threatening hematemesis	Endoscopy on 27 April showed a raised esophageal lesion approximately 25 cm from the incisors, with a central depression and brisk pulsatile bleeding. Hb nadir 54 g/L; INR 1.17 at 10:00 and 1.59 at 13:52; lactate 3.4 mmol/L.	Repeat endoscopic clipping did not provide reliable immediate hemostasis. Vasopressor support and transfusion were required; 9 units of red blood cells and 870 mL of plasma were documented on 27–28 April.
5–6 May 2026	Thromboembolic concern during anticoagulation interruption	Transient right-sided visual blurring or visual-field disturbance prompted consideration of embolic ischemia. No definite ocular vascular embolism was identified.	Nadroparin 4,100 IU once daily was documented from 5 May while warfarin remained withheld.
13–14 May 2026	Recurrent hematemesis with hemodynamic instability	Approximately 50 mL of fresh hematemesis followed by hypotension (blood pressure 56/30 mmHg). CTA showed blood within the stomach and an enhancing focus adjacent to a gastric clip, without a definite arterial communication. Endoscopy on 14 May showed a visible vessel at the previously identified esophageal site without active bleeding and minor self-limited gastric oozing.	Antithrombotic therapy was again withheld. Intensive care support, transfusion, proton pump inhibitor therapy, and somatostatin were administered. Conservative management continued after multidisciplinary review.
15 May–1 Jul 2026	Clinical stabilization and staged reintroduction of anticoagulation	No further major hematemesis was documented. Hb was 77 g/L on 15 May and 106 g/L on 1 July.	Anticoagulation was gradually reintroduced. Nadroparin 5,000 IU once daily was documented by 18 June.

Date	Clinical event	Key findings	Antithrombotic management and outcome
27 Jul 2026	Discharge from the second hospitalization	Clinically stable. Echocardiography on 21 July showed a left ventricular ejection fraction of 26%, with no reported LVAD inflow or outflow obstruction.	Discharged on warfarin 6 mg once daily and indobufen 100 mg twice daily.
8 Sep–12 Oct 2026	Outpatient follow-up	No further clinically significant gastrointestinal bleeding was documented in the available records. The peripherally inserted central catheter was removed on 16 September. INR values ranged from 1.66 to 2.32 during documented follow-up.	Warfarin was documented as 1.75 tablets once daily. The tablet strength was not specified in the outpatient records.

Abbreviations: CTA, computed tomography angiography; CT, computed tomography; Hb, hemoglobin; ICU, intensive care unit; INR, international normalized ratio; LVAD, left ventricular assist device.

Note: Antithrombotic regimens and clinical events are reported as documented in the medical records. The outpatient warfarin tablet strength was not specified. Transient visual symptoms prompted consideration of embolic ischemia, but no definite ocular vascular embolism was documented. The esophageal lesion was not definitively characterized, and CTA did not establish an aortoesophageal fistula.

Discussion

This case illustrates the diagnostic and therapeutic challenges of recurrent, life-threatening focal esophageal hemorrhage during EVAHEART support. The most informative findings were direct visualization of brisk pulsatile bleeding from a localized esophageal lesion, recurrence of bleeding-related abnormalities at the same site, and failure of CTA to identify a definite responsible vessel. The case also highlights the difficulty of managing major hemorrhage when interruption of antithrombotic therapy may expose a patient with durable mechanical circulatory support to thrombotic complications.

Gastrointestinal bleeding during EVAHEART support

Gastrointestinal bleeding during durable LVAD support is multifactorial. Anticoagulant and antiplatelet therapy may increase the severity or duration of bleeding, while continuous-flow support has been associated with acquired von Willebrand factor abnormalities, platelet dysfunction, and vascular changes that may predispose patients to hemorrhage [1–8, 10]. These mechanisms are not mutually exclusive. The presence of anticoagulation does not, by itself, establish the cause of bleeding, and the severity of hemorrhage may depend on the characteristics of the underlying lesion as well as the patient's hemostatic state. In this patient, von Willebrand factor multimer analysis and platelet-function testing were unavailable; the contribution of these abnormalities therefore cannot be determined.

EVAHEART is a centrifugal-flow LVAD designed to reduce shear-related blood trauma while maintaining pulsatility. Experimental comparisons have reported less von Willebrand factor degradation with EVAHEART than with the axial-flow HeartMate II [11]. A Japanese post-approval study involving 96 recipients reported no gastrointestinal bleeding events during the observed support period [12]. These findings provide useful device-specific context, but a cohort of this size cannot exclude uncommon complications, and the absence of reported events in one study should not be interpreted as evidence that severe bleeding cannot occur. The present case establishes that a major focal esophageal hemorrhage occurred during EVAHEART support; it does not establish that the device caused the lesion or that the event resulted from a device-specific hemostatic mechanism.

The patient had experienced bronchial bleeding during the preceding VA-ECMO course. However, VA-ECMO and durable LVAD support represent different forms of mechanical circulatory support, and the available clinical information does not establish a causal link between the earlier bronchial event and the later esophageal hemorrhage. Nor can a persistent effect of ECMO be inferred. The most defensible interpretation is that antithrombotic treatment and the hemostatic environment associated with mechanical circulatory support may have amplified bleeding from a focal lesion of uncertain pathology. This remains a plausible explanation rather than a demonstrated mechanism.

Differential diagnosis of focal esophageal hemorrhage

The raised esophageal lesion, central depression, brisk pulsatile bleeding, and subsequent visualization of a vessel at the same site favored a focal vascular source. Esophageal Dieulafoy lesions have been reported, although this is an uncommon location [13–15]. The limited mucosal abnormality relative to the severity of hemorrhage is compatible with such a lesion, but this appearance is not specific. Without histopathological confirmation or definitive vascular characterization, a Dieulafoy-type lesion should remain a differential diagnosis rather than a confirmed diagnosis. Esophageal variceal hemorrhage has also been reported after continuous-flow LVAD implantation [16], illustrating that the presence of an LVAD does not narrow the differential to a single mechanism.

An aortoesophageal fistula was another important consideration because pulsatile esophageal hemorrhage can indicate communication with a major artery and may precede catastrophic rebleeding. CTA showed a right-sided aortic arch but did not demonstrate a definite fistulous tract, responsible vessel, or active contrast extravasation. The anatomical variant alone does not establish communication between the aorta and esophagus. Reports of delayed diagnosis with initially negative imaging [17] and arterioesophageal fistulas associated with aberrant left subclavian artery anatomy or right-sided aortic arch pathology [18–19] illustrate the potential seriousness of this differential diagnosis, but they cannot be used to infer a fistula in the present patient. The available imaging did not establish the relevant branch-vessel anatomy or a direct communication at the esophageal lesion. Local artifact and the intermittent nature of bleeding also limited the certainty with which a fistula could be excluded. The most defensible interpretation is therefore that an aortoesophageal fistula was considered but remained unconfirmed.

The gastric lesion identified during the initial evaluation was a genuine competing finding. It showed surface erosions and oozing and was treated endoscopically. During the subsequent episode, however, brisk pulsatile bleeding was directly observed from the esophageal lesion, whereas repeat endoscopy did not demonstrate active hemorrhage from the treated gastric site or the duodenum. The strongest evidence for the source of the 27 April event is therefore the direct endoscopic observation of active esophageal bleeding. The later episode was less definitive: a vessel remained visible at the same esophageal site, but active bleeding was not seen, and CTA described an enhancing focus adjacent to a gastric clip. Accordingly, the esophagus is the best-supported source of the documented massive hemorrhage, while the precise source of every subsequent episode cannot be established with equal certainty. This distinction avoids overstating what the investigations demonstrated.

Complementary roles of endoscopy and CTA

Endoscopy and CTA provided complementary rather than interchangeable information. Endoscopy directly demonstrated active pulsatile bleeding on 27 April and a visible vessel at the same location on 14 May after active hemorrhage had ceased. CTA did not identify a definite responsible vessel, but it contributed to assessment of the aorta, postoperative anatomy, and the possibility of a major vascular communication. Failure to demonstrate active contrast extravasation during image acquisition did not resolve the source of intermittent bleeding.

The diagnostic yield of CTA depends in part on whether bleeding is active during acquisition and whether the suspected region can be assessed without substantial artifact. In this case, local artifact limited evaluation, and no target vessel was identified for embolization. The findings therefore support describing CTA as nondiagnostic for the responsible bleeding source rather than as proof that an arterial lesion or fistula was absent. When a patient rebleeds after an initially inconclusive examination, repeat endoscopy can provide important new information, particularly when the earlier bleeding site can be directly compared with subsequent findings.

After the 13 May recurrence, no active hemorrhage was seen at endoscopy on 14 May, and imaging did not identify a target vessel for intervention. Conservative management was continued after multidisciplinary review. This decision should be interpreted in the context of the findings at that time, not as evidence that conservative treatment is generally adequate for severe pulsatile esophageal hemorrhage. Persistent or recurrent hemodynamically significant bleeding would warrant urgent reassessment and multidisciplinary consideration of definitive endoscopic, endovascular, or surgical treatment according to the suspected source, the patient's stability, and the feasibility of identifying a target.

Balancing hemorrhagic and thrombotic risks

The hemoglobin nadir of 54 g/L and the transfusion of 9 units of red blood cells demonstrate the severity of the April episode. The INR was 2.01 on 20 April and 1.59 at 13:52 on 27 April. These

measurements do not establish excessive warfarin effect as the sole explanation for the bleeding. Anticoagulation may have contributed to the clinical severity, but INR does not capture platelet dysfunction, acquired von Willebrand factor abnormalities, or the structural characteristics of a focal vascular lesion [1–4]. Conversely, these values alone cannot exclude a contribution from anticoagulation; interpretation requires the clinical context and the intended anticoagulation target for the individual device and patient.

Management of major bleeding in patients with durable LVADs requires simultaneous consideration of hemorrhage severity, source control, device function, and the competing risks of pump thrombosis and systemic thromboembolism [1, 2, 20]. In this case, warfarin and aspirin were withheld during active bleeding. Nadroparin was subsequently documented while warfarin remained withheld, and anticoagulation was later reintroduced in stages. A transient visual disturbance in early May prompted consideration of embolic ischemia, although no definite ocular vascular embolism was identified. The available records do not establish that the symptoms were thromboembolic or that they resulted from antithrombotic interruption. At discharge, the documented regimen comprised warfarin 6 mg once daily and indobufen 100 mg twice daily.

The ARIES-HM3 randomized trial found that aspirin avoidance with continued vitamin K antagonist therapy reduced nonsurgical bleeding without increasing thromboembolic events in recipients of the fully magnetically levitated HeartMate 3 device [21]. A secondary analysis reported similar findings among patients with atherosclerotic vascular disease [22]. These results are relevant to the broader balance between bleeding and thrombosis, but they should not be directly extrapolated to EVAHEART support. Device design, the patient's recent complex coronary intervention, and the incomplete antithrombotic chronology limit the conclusions that can be drawn for this case.

The sequence illustrates why neither prolonged interruption nor early reintroduction can be considered in isolation from the status of the bleeding source and the patient's thrombotic risk. However, the medical record does not provide a complete day-by-day account of antithrombotic interruptions, dose changes, reversal measures, or the rationale for each adjustment. It is therefore not possible to infer an optimal restart time or derive a specific anticoagulation protocol from this single case. No further clinically significant gastrointestinal bleeding was documented through 12 October 2026 during subsequent warfarin treatment. This follow-up is reassuring but does not establish that the lesion was definitively eradicated or that the discharge regimen is generally safe for other LVAD recipients.

Taken together, the clinically useful lessons are limited but practical: a focal lesion should be reassessed when bleeding recurs; nondiagnostic CTA should be interpreted in light of intermittent bleeding and technical limitations; and antithrombotic decisions should be individualized after considering the best available evidence of source control, device status, and thrombotic risk. The case does not establish a unique EVAHEART-associated bleeding mechanism or a universally applicable antithrombotic strategy.

Limitations

This report has several limitations. First, the esophageal lesion was not biopsied, and its precise pathological identity remains uncertain. Second, CTA did not identify a responsible vessel or establish an aortoesophageal fistula; local artifact and the intermittent nature of bleeding also limited definitive exclusion of a vascular communication. Third, von Willebrand factor multimer analysis, platelet-function testing, and a complete set of contemporaneous hemolysis markers were unavailable, precluding direct assessment of LVAD-associated hemostatic abnormalities. Fourth, the medical records did not provide a complete day-by-day account of antithrombotic interruptions, dose changes, or the rationale for each adjustment. Finally, although pump speed and power were documented on 15 January 2026, a contemporaneous pump-flow value was unavailable, and device-flow data were not available at the time of hemorrhage. A relationship between pump parameters and the bleeding episode therefore cannot be established.

Conclusions

Recurrent, life-threatening focal esophageal hemorrhage occurred during EVAHEART LVAD support. Endoscopy directly localized the bleeding to a focal esophageal lesion and subsequently demonstrated a visible vessel at the same site, whereas CTA did not identify a definite responsible vessel. The lesion's precise pathology remained undetermined, and an aortoesophageal fistula was not established. This case highlights the importance of repeat endoscopic assessment in recurrent bleeding and individualized management of antithrombotic therapy when hemorrhagic and thrombotic risks compete. Neither a nondiagnostic CTA nor an INR that is not markedly elevated should, in isolation, be taken to resolve the cause of severe gastrointestinal hemorrhage.

Abbreviations

APTT
activated partial thromboplastin time
CT
computed tomography
CTA
computed tomography angiography
Hb
hemoglobin
INR
international normalized ratio
LAD
left anterior descending artery
LCx
left circumflex artery
LVAD
left ventricular assist device

PCI
percutaneous coronary intervention
PT
prothrombin time
TIMI
Thrombolysis in Myocardial Infarction
VA-ECMO
venoarterial extracorporeal membrane oxygenation.

Declarations

Ethics approval and consent to participate

This retrospective single-case report was approved by the Ethics Committee of the First Affiliated Hospital, Zhejiang University School of Medicine (approval number [2026B] IIT Ethics Approval No. 0621). The report was prepared in accordance with institutional ethical requirements.

Consent for publication

Written informed consent for publication of this case report, including relevant clinical details and accompanying images, was obtained from the patient's wife in accordance with the institution's ethical requirements. All identifying information has been removed to protect patient confidentiality.

Availability of data and materials

The datasets used and analyzed during this report are not publicly available because they contain potentially identifiable clinical information. De-identified data may be available from the corresponding author on reasonable request and with institutional approval.

Competing interests

The authors declare that they have no competing interests.

Funding

This work was supported by the project "Application of Mixed Reality Technology in Early Limb Mobilization of ICU Patients" (grant No. 2023ZYHL33).

Authors' contributions

YZ and QZ contributed equally to this work. QZ was responsible for case data collection and verification. YC and YYJ collected and analyzed the clinical data. WY reviewed and interpreted the radiological findings. YZ, GBW, HLC, and WY participated in the patient's intensive care management. YZ drafted the manuscript. HZ provided overall academic supervision and critically revised the manuscript. All authors

critically revised the manuscript for important intellectual content, approved the final version, and agreed to be accountable for all aspects of the work.

Acknowledgements

Not applicable.

Use of AI-assisted tools in manuscript preparation

ChatGPT (OpenAI) was used to assist with language editing and manuscript restructuring. The authors reviewed and verified the clinical information, interpretation, and references and take full responsibility for the final manuscript.

Reporting guideline

This case report was prepared with reference to the CARE guidelines.

References

1. Saeed D, Feldman D, El-Banayosy A, et al. The 2023 International Society for Heart and Lung Transplantation guidelines for mechanical circulatory support: a 10-year update. J Heart Lung Transpl. 2023;42(7):e1–222. https://doi.org/10.1016/j.healun.2022.12.004.
2. Hollis IB, Jennings DL, Krim S, et al. An ISHLT consensus statement on strategies to prevent and manage hemocompatibility-related adverse events in patients with a durable, continuous-flow ventricular assist device. J Heart Lung Transpl. 2024;43(8):1199–234. https://doi.org/10.1016/j.healun.2024.04.065.
3. Guha A, Eshelbrenner CL, Richards DM, Monsour HP Jr. Gastrointestinal bleeding after continuous-flow left ventricular device implantation: review of pathophysiology and management. Methodist Debakey Cardiovasc J. 2015;11(1):24–7. https://doi.org/10.14797/mdcj-11-1-24.
4. Kushnir VM, Sharma S, Ewald GA, et al. Evaluation of GI bleeding after implantation of left ventricular assist device. Gastrointest Endosc. 2012;75(5):973–9. https://doi.org/10.1016/j.gie.2011.12.014.
5. Del Rio-Pertuz G, Nair N. Gastrointestinal bleeding in patients with continuous-flow left ventricular assist devices: a comprehensive review. Artif Organs. 2023;47(1):12–23. https://doi.org/10.1111/aor.14432.
6. Naveed A, Naveed B, Khan MA, Asif T. Gastrointestinal bleeding in recipients of left ventricular assist devices—a systematic review. Heart Fail Rev. 2023;28(5):1163–75. https://doi.org/10.1007/s10741-023-10313-6.
7. Hammer Y, Bitar A, Aaronson KD. Gastrointestinal bleeding on continuous-flow left ventricular assist device therapy. ESC Heart Fail. 2023;10(4):2214–24. https://doi.org/10.1002/ehf2.14433.
8. Gangwani MK, Aziz M, Nawras A, et al. Predictors of gastrointestinal bleeding in patients following left ventricular assist device implantation: a systematic review and meta-analysis. Future Cardiol.

2022;18(12):957–67. https://doi.org/10.2217/fca-2022-0054.

9. Bernhardt AM, Copeland H, Deswal A, et al. The International Society for Heart and Lung Transplantation/Heart Failure Society of America guideline on acute mechanical circulatory support. J Heart Lung Transpl. 2023;42(4):e1–64. https://doi.org/10.1016/j.healun.2022.10.028.
10. Patel SR, Vukelic S, Chinnadurai T, et al. Gastrointestinal angiodysplasia in heart failure and during CF LVAD support. J Heart Lung Transpl. 2022;41(2):129–32. https://doi.org/10.1016/j.healun.2021.11.009.
11. Bartoli CR, Kang J, Zhang D, et al. Left ventricular assist device design reduces von Willebrand factor degradation: a comparative study between the HeartMate II and the EVAHEART left ventricular assist system. Ann Thorac Surg. 2017;103(4):1239–44. https://doi.org/10.1016/j.athoracsur.2016.06.112.
12. Saito S, Yamazaki K, Nishinaka T, et al. Post-approval study of a highly pulsed, low-shear-rate, continuous-flow, left ventricular assist device, EVAHEART: a Japanese multicenter study using J-MACS. J Heart Lung Transpl. 2014;33(6):599–608. https://doi.org/10.1016/j.healun.2014.02.015.
13. Ertekin C, Barbaros U, Taviloglu K, Guloglu R, Kasoglu A. Dieulafoy's lesion of esophagus. Surg Endosc. 2002;16(1):219. https://doi.org/10.1007/s00464-001-4204-z.
14. Inayat F, Ullah W, Hussain Q, Hurairah A. Dieulafoy's lesion of the oesophagus: a case series and literature review. BMJ Case Rep. 2017;2017:bcr2016218100. https://doi.org/10.1136/bcr-2016-218100.
15. Bathobakae L, Russo J, Adalja D, et al. Dieulafoy's lesion in the esophagus causing gastrointestinal bleeding: a concise review. J Community Hosp Intern Med Perspect. 2024;14(6):82–8. https://doi.org/10.55729/2000-9666.1425.
16. Majmudar K, Northcutt M, Gordon R, Fimmel CJ. Rapid development of bleeding esophageal varices after placement of continuous-flow left ventricular assist device. Case Rep Hepatol. 2019;2019:8410420. https://doi.org/10.1155/2019/8410420.
17. Hakim S, Gjeorgjievski M, Garg L, Orosey M, Desai T. Atypical aortoesophageal fistula with atypical and delayed presentation and negative imaging studies. Case Rep Gastrointest Med. 2016;2016:7219034. https://doi.org/10.1155/2016/7219034.
18. Clements A, Touros K, Bearden G, Horst V. Survival after aberrant left subclavian artery-esophageal fistula hemorrhage: a case report and technique review. J Vasc Surg Cases Innov Tech. 2025;11(6):101940. 10.1016/j.jvscit.2025.101940.
19. Chen J, Shah V, King C, DiMuzio P. Management of right-sided aortic arch with type B aortic dissection and aortoesophageal fistula. Ann Thorac Surg Short Rep. 2024;2(1):15–7. https://doi.org/10.1016/j.atssr.2023.09.002.
20. Elshaer A, Abraham NS. Management of anticoagulant and antiplatelet agents in acute gastrointestinal bleeding and prevention of gastrointestinal bleeding. Gastrointest Endosc Clin N Am. 2024;34(2):205–16. https://doi.org/10.1016/j.giec.2023.09.002.

21. Mehra MR, Netuka I, Uriel N, et al. Aspirin and hemocompatibility events with a left ventricular assist device in advanced heart failure: the ARIES-HM3 randomized clinical trial. JAMA. 2023;330(22):2171–81. 10.1001/jama.2023.23204.
22. Gustafsson F, Uriel N, Netuka I, et al. Aspirin and hemocompatibility after LVAD implantation in patients with atherosclerotic vascular disease: a secondary analysis from the ARIES-HM3 randomized clinical trial. JAMA Cardiol. 2025;10(3):235–42. 10.1001/jamacardio.2024.4849.

Figures

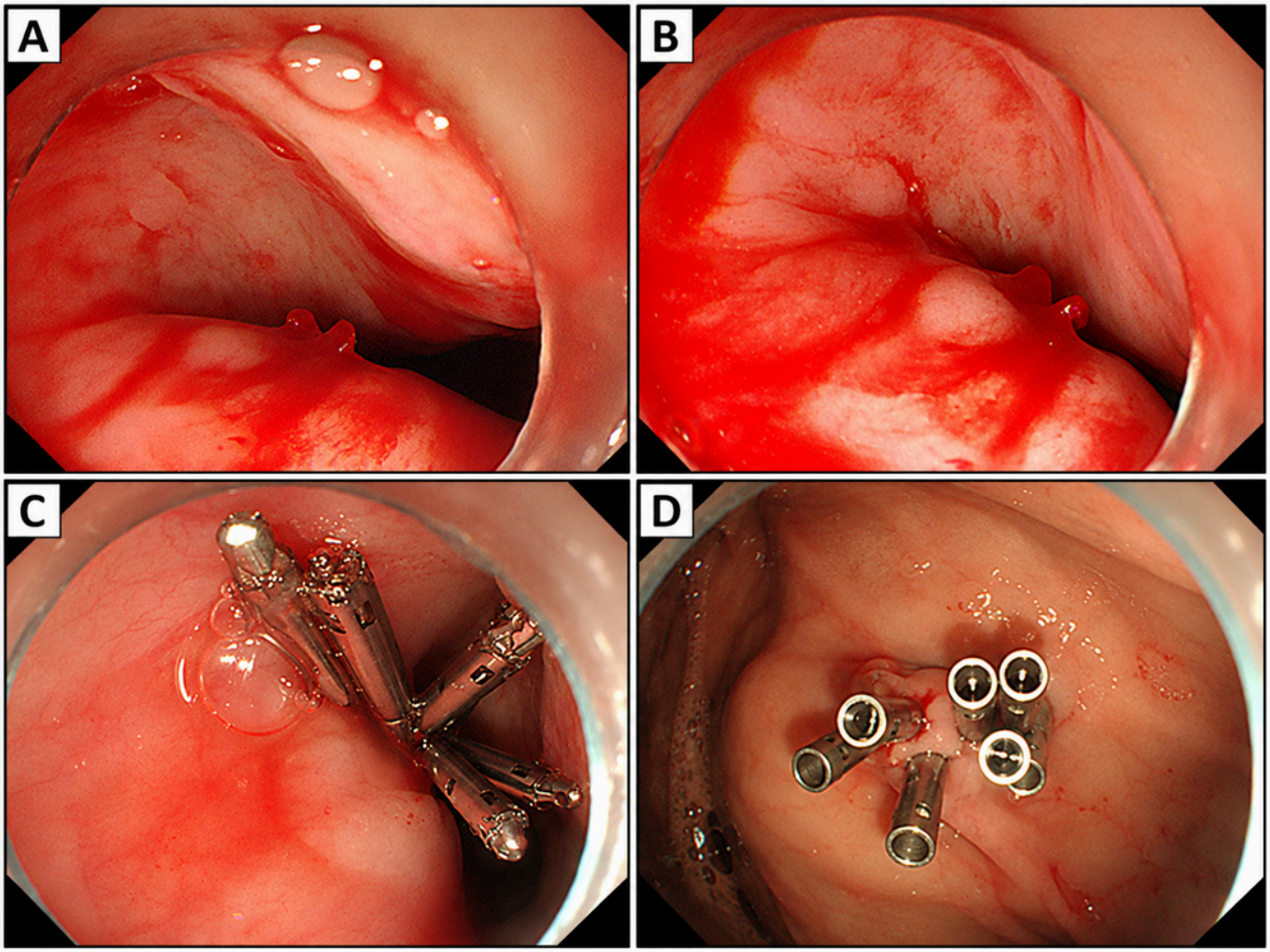

Figure 1

Endoscopic findings of recurrent focal esophageal hemorrhage.

(A) Upper gastrointestinal endoscopy on April 27, 2026, showing a raised focal esophageal lesion with a central depression, approximately 25 cm from the incisors. (B) Active pulsatile bleeding from the lesion. (C) Endoscopic clips applied to the bleeding site; immediate hemostasis was incomplete. (D) Repeat

endoscopy on May 14, 2026, showing previously placed clips and a visible vessel at the same esophageal site, without active bleeding at the time of examination.

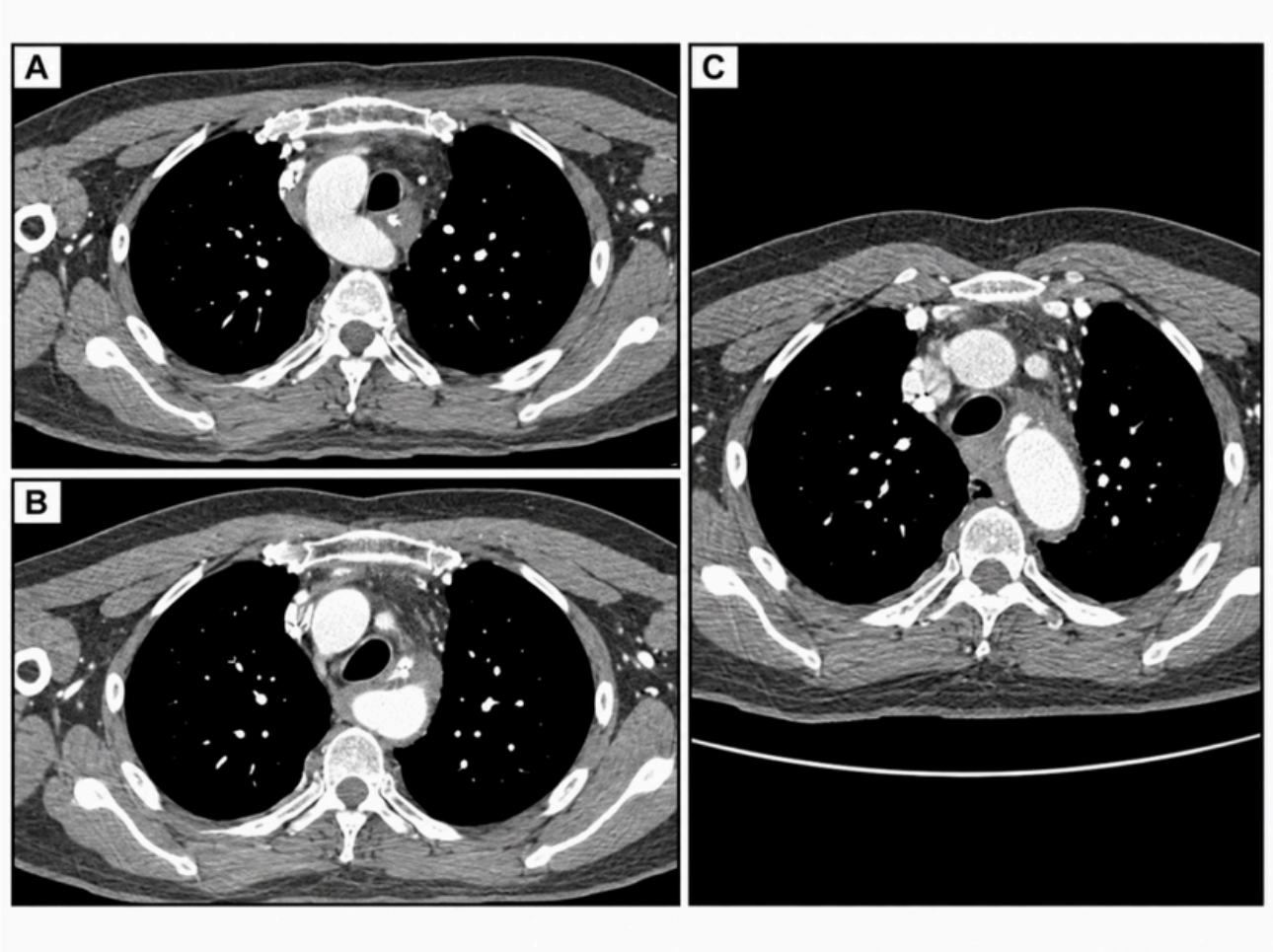

Figure 2

Contrast-enhanced computed tomography findings during recurrent upper gastrointestinal bleeding.

(A) Contrast-enhanced computed tomography on April 27, 2026, demonstrating a right-sided aortic arch. (B) The same examination showing the anatomical relationship between the esophagus and the adjacent aorta, without definite contrast extravasation. (C) Computed tomography angiography on May 13, 2026, showing no definite bleeding vessel or direct aortoesophageal communication. The imaging findings did not establish the source of hemorrhage or confirm an aortoesophageal fistula.