Research Square

Preprints are preliminary reports that have not undergone peer review.
They should not be considered conclusive, used to inform clinical practice,
or referenced by the media as validated information.

Organ-Preserving Carbon Ion Radiotherapy for Subglottic Adenoid Cystic Carcinoma: A Cross-Border Multidisciplinary Case

Hamdan Ahmed Pasha
Aga Khan University
Zehra Zonash
Aga Khan University
Reyan Hussain Shaikh
Aga Khan University
Syed Abbas Moazzam Kazmi
syed.abbas24@alumni.aku.edu

Aga Khan University

Case Report

Keywords: Adenoid cystic carcinoma, Subglottis, Laryngeal neoplasms, Carbon-ion radiotherapy, Particle therapy, Organ preservation, Voice preservation, Multidisciplinary care

Posted Date: November 22nd, 2026

DOI: https://doi.org/10.21203/rs.3.rs-11404296/v1

License: This work is licensed under a Creative Commons Attribution 4.0 International License.
Read Full License

Additional Declarations: No competing interests reported.

Abstract

Background

Laryngeal adenoid cystic carcinoma (ACC) is rare, particularly in the subglottis, and may be diagnosed late because of non-specific symptoms and submucosal growth. In low- and middle-income countries, limited access to advanced radiotherapy can restrict organ-preserving treatment. We report a case from Pakistan managed with carbon ion radiotherapy through international multidisciplinary collaboration.

Case Presentation

A non-smoking South Asian woman in her late 50s presented with progressive hoarseness for one year. Serial fiberoptic laryngoscopies showed edema without a visible lesion. CT and MRI revealed asymmetric left subglottic thickening measuring 13.7 × 8.2 mm, extending into the left true vocal fold without cartilage invasion or cervical lymphadenopathy. PET/CT showed localized FDG-avid disease without metastases.

Microlaryngoscopy identified a submucosal lesion. Permanent histopathology demonstrated a cribriform bilayered epithelial and myoepithelial neoplasm with AE1/AE3, C-Kit, p63, and CK5/6 expression, confirming ACC. No perineural invasion was identified. To avoid laryngectomy, the patient underwent definitive carbon ion radiotherapy abroad, receiving 22 sessions (44 Gy).

Post-treatment assessments showed improvement of hoarseness and cough, with normal laryngoscopy. MRI demonstrated progressive reduction in lesion size, and at six months showed only subglottic scar tissue without residual disease. At twelve months, the patient maintained a normal voice and airway.

Conclusion

International multidisciplinary collaboration enabled definitive carbon ion radiotherapy for rare subglottic ACC in a setting where this treatment was unavailable locally. Accurate imaging, expert pathology, shared decision-making, and cross-border access to advanced radiotherapy achieved early disease control while preserving laryngeal function.

BACKGROUND

Adenoid Cystic Carcinoma (ACC) is a malignancy of the secretory glands, constituting < 1% of head and neck cancers [1], and comprising 0.32% – 0.69% of all laryngeal malignancies[2]. Due to the rare nature of laryngeal ACC, no internationally accepted treatment guidelines exist for this condition. Propensity for recurrence and perineural invasion lead to radical surgical resections and adjunctive conventional radiotherapy remaining mainstays, but often compromise voice functionality and quality of life of the patient.

Particle Beam Therapy (PBT) is an upcoming cancer treatment modality employing carbon ions, protons, or neutrons along a particular distribution allowing high dose delivery to required targets while sparing surrounding tissues[3, 4]. This characteristic delivery helps in minimising morbidity, especially in radiosensitive areas such as the head and neck [5].

We present a case of subglottic ACC presenting as chronic hoarseness and sore throat with initially non-diagnostic flexible laryngoscopic examinations, managed with carbon ion radiotherapy (CIRT) and demonstrating sustained radiologic complete response on follow-up.

CASE PRESENTATION

A South Asian female in her late 50s presented to the ENT clinic with progressive hoarseness and cough for 9 months. Symptoms persisted despite voice rest, speech therapy, antihistamines, and anti-reflux therapy. Three repeated flexible fibreoptic direct laryngoscopies (FODL) over 7 months demonstrated glottic edema with bilaterally mobile vocal cords and no visible mucosal lesion. Due to worsening hoarseness, 9 months after her initial presentation, a fourth FODL demonstrated post-arytenoid and subglottic edema. This also prompted cross-sectional imaging and subsequent biopsy (see Investigations).

The patient works in a non-manual, office-based profession. She was a non-smoker and is postmenopausal, for which she had received hormone replacement therapy several years earlier. Her past medical history included chronic migraine, recurrent low back pain, and cervical spondylosis. Family history was notable for breast cancer in multiple maternal relatives, and Sjögren's syndrome in a sibling.

Investigations and Differential Diagnoses:

The patient presented with progressive hoarseness and cough and underwent three serial FODLs over seven months, each demonstrating glottic edema without a visible mucosal lesion. Videostroboscopy was not available at our institution or neighboring regions, and therefore could not be performed to further assess vocal fold vibration or characterize the persistent laryngeal findings after the non-diagnostic FODL examinations.

Given persistent hoarseness with early laryngoscopy showing edema without mucosal lesion, initial considerations included:

- Laryngopharyngeal reflux-related laryngitis
- Allergic/irritant laryngitis and chronic inflammatory oedema
- Functional dysphonia and voice overuse-related changes
- Benign submucosal lesions (e.g., cyst, granuloma)
- Primary laryngeal malignancy (including squamous cell carcinoma) and other salivary-type tumours (including ACC), particularly after imaging demonstrated a focal subglottic mass with diffusion

restriction

Worsening symptoms and subsequent subglottic edema on a fourth examination prompted cross-sectional imaging. CT, MRI, and FDG PET/CT demonstrated a localized left subglottic lesion without definite cartilage invasion, cervical nodal disease, or distant metastases. The diagnostic timeline is summarised in Fig. 1, while the MRI is shown in Fig. 2.

Microlaryngoscopy (9 months since presentation) demonstrated a submucosal subglottic lesion, more pronounced on the left; true vocal cords were grossly normal, and there was no mucosal lesion. Biopsy and subsequent histopathology revealed a neoplasm beneath focally overlying stratified squamous epithelium with cribriform pattern and bilayered tubules (epithelial and myoepithelial layers); lumina with myxoid ground substance. These features were consistent with ACC. Immunohistochemistry showed diffuse cytokeratin AE1/AE3 positivity; C-Kit (CD117) staining of inner epithelial cells; p63 and cytokeratin 5/6 staining of the peripheral myoepithelial layer. There was no perineural invasion. Histopathology is shown in Fig. 3.

Treatment:

The case was reviewed at a multidisciplinary tumour board. In the absence of radiological invasion of thyroid/cricoid cartilage and without nodal or distant metastasis, definitive non-surgical management was favoured. Preservation of her voice was particularly important given the nature of her occupation, and after counseling regarding the various treatment options, (including surgery versus particle therapy), the patient underwent 22 sessions of CIRT abroad (44 Gy), completed in two months since her diagnosis. Supportive measures during follow-up included hydration/steam/nebulisation and anti-reflux measures as required.

Outcome and Follow-Up:

Following completion of CIRT, the patient reported improvement of hoarseness and cough and interval laryngoscopic examinations demonstrated no visible subglottic lesion. Surveillance MRI three months after the completion of treatment showed objective radiological response with reduced lesion dimensions and markedly reduced diffusion restriction. She later developed fatigue and cough, with biochemical findings consistent with evolving hypothyroidism in the post-radiotherapy period, prompting endocrine referral. Her most recent MRI, 12 months after treatment demonstrated stable post-treatment subglottic scar tissue, no diffusion restriction, and no definite residual disease, reported as ongoing complete response/remission.

DISCUSSION

Adenoid cystic carcinoma (ACC) is uncommon among head and neck malignancies, and primary involvement of the larynx is particularly rare. It accounts for less than 1% of all nonsquamous malignant

laryngeal tumors. [6] In a prospective multicentre REFCOR study, Atallah et al. reported 470 patients with head and neck ACC, of whom 60% had tumors arising from minor salivary glands [7]. In contrast, a systematic review focused specifically on laryngeal ACC identified only 120 reported cases across 50 publications [8]. Of these, 56.7% arose in the subglottis, confirming the subglottis as the most frequently involved laryngeal subsite [8]. Population-based data similarly demonstrate a strong subglottic predilection: among 69 patients with laryngeal ACC identified in the Surveillance, Epidemiology, and End Results database, 44.9% had subglottic tumors [9]. The present case therefore represents an uncommon laryngeal manifestation of ACC but involves the subsite most consistently represented among published laryngeal cases.

The clinical findings in our patient also reflect the characteristic presentation of laryngeal ACC. In the systematic review by Marchiano et al., dyspnea was the most frequent presenting symptom, occurring in 48.8% of cases, followed by hoarseness in 43.9% [8]. Our patient presented with progressive hoarseness and cough, and serial fibreoptic examinations only demonstrated edema. Cross-sectional imaging was ultimately prompted by persistent symptoms and subsequent recognition of subglottic edema. This diagnostic delay is particularly relevant because laryngeal ACC typically grows beneath an intact mucosal surface, which can render early endoscopic examination non-diagnostic [8, 10].

Regional nodal disease appears to be uncommon at presentation in laryngeal ACC. Marchiano et al. reported regional disease in 13 of 89 patients with available nodal information (14.6%) [8], while the population-based series of 69 patients found that 87.9% presented with N0 disease and only 6.1% had distant metastases at diagnosis [9]. This pattern was reflected in our patient, in whom neither cervical lymphadenopathy nor distant metastatic disease was identified.

Published treatment of laryngeal ACC has historically been dominated by surgery. In the 120-case systematic review, surgery alone and surgery followed by radiotherapy each accounted for 43.3% of reported treatments, meaning that the large majority of published patients underwent surgical resection [8]. The extent of surgery, however, remains variable. Lionello et al. reported 17 surgically treated patients with laryngeal ACC, of whom 14 underwent partial laryngectomy and only three underwent total laryngectomy [2]. Five patients (29%) subsequently developed laryngeal recurrence after a mean disease-free interval of 66.6 months, while distant metastases occurred in 17%; the authors consequently advocated conservative rather than radical surgery whenever oncologically feasible [2]. These data are important in contextualizing the present case because they demonstrate that preservation of laryngeal function is a recognized treatment objective even within surgical series.

Evidence for definitive organ-preserving radiotherapy in laryngeal ACC is considerably smaller but directly relevant to our patient. Akbaba et al. reported 11 patients with primary laryngeal ACC, five treated with definitive radiotherapy and six with postoperative radiotherapy [11]. Eight patients were managed with a laryngeal-preservation approach, and the reported 5-year local-control rate was 100%. Only one of these eight ultimately required total laryngectomy because of a local recurrence occurring 11 years after treatment [11]. Misiukiewicz et al. separately reported two patients with laryngeal ACC who were offered

laryngectomy but instead underwent definitive chemoradiotherapy with carboplatin and paclitaxel. Both maintained locoregional control and a functional larynx at 60 + and 112 + months, although one subsequently developed pulmonary metastases [12]. Together, these small series suggest that non-surgical laryngeal preservation can achieve meaningful local control in selected patients, although the limited number of cases precludes comparison with surgical treatment.

Against this background, the present case is notable for the use of definitive CIRT without surgery or concurrent chemotherapy. Following multidisciplinary review, the absence of radiological cartilage invasion, cervical nodal disease and distant metastases, the patient was counseled on conservative surgery, which the patient declined, or radiotherapy. It was decided to then pursue a definitive non-surgical approach. Preservation of voice was also an important treatment priority for the patient. Particle therapy has been increasingly studied for head and neck ACC because of its capacity to deliver high biologically effective doses while limiting exposure to adjacent critical structures [3, 4, 13]. A 2024 systematic review and meta-analysis included 14 charged-particle studies comprising 1,297 patients with head and neck ACC and reported pooled 5-year local control of approximately 73% [4]. More recently, Rohit et al. reviewed 44 studies evaluating proton, carbon-ion and fast-neutron therapy for head and neck ACC and concluded that proton and carbon-ion approaches provide encouraging local control in both definitive and postoperative settings [13]. However, these particle-therapy datasets combine heterogeneous head and neck primary sites, and laryngeal tumors constitute only a very small proportion of the available evidence. Accordingly, their outcomes cannot be directly extrapolated to subglottic ACC.

The early outcome in our patient has been favorable, but the duration of follow-up remains short in the context of ACC. In the 120-case systematic review, distant metastases were reported in 30 patients during follow-up (33.3%) [8]. Moukarbel et al., in a 40-year institutional series of 15 patients with laryngeal ACC, reported local or regional recurrence in five patients (33.3%) and distant metastases in 66.7%, predominantly involving the lungs, after a median follow-up of 6.9 years [14]. Similarly, the recurrence requiring salvage laryngectomy in the Akbaba series occurred 11 years after initial treatment [11]. These observations emphasize that a radiological complete response at 12 months should be regarded as encouraging early disease control rather than evidence of cure. Prolonged surveillance for both local recurrence and distant metastasis remains essential.

This case contributes to the literature in two respects. First, it illustrates the diagnostic challenge of submucosal laryngeal ACC, in which persistent hoarseness may precede a visible mucosal lesion on laryngoscopy, underscoring the value of cross-sectional imaging when symptoms persist or progress. Second, it adds site-specific experience with definitive CIRT for subglottic ACC, an approach for which published evidence remains limited and is derived largely from heterogeneous head and neck ACC cohorts.

In summary, laryngeal ACC is rare, most commonly arises in the subglottis, and has traditionally been managed with surgery with or without postoperative radiotherapy. Limited larynx-specific series suggest

that definitive radiotherapy can preserve laryngeal function in selected patients. In the present case, definitive CIRT achieved an early complete radiological response with preservation of voice and laryngeal function without surgery or chemotherapy. However, the relatively short follow-up and the propensity of ACC for late local recurrence and distant metastasis preclude conclusions regarding durable disease control, and long-term surveillance remains essential.

CONCLUSION

This case supports the emerging role of PBT, particularly CIRT, as a viable, organ-preserving treatment option for selected patients with laryngeal ACC. In the absence of standardized treatment guidelines, individualized, multidisciplinary decision-making remains essential. PBT may offer a compelling balance between oncologic control and functional preservation in this rare and challenging malignancy.

ABBREVIATIONS

ACC
Adenoid cystic carcinoma
CIRT
Carbon-ion radiotherapy
CT
Computed tomography
ENT
Ear, nose and throat
FDG
Fluorodeoxyglucose
FODL
Fibreoptic direct laryngoscopy
FT4
Free thyroxine
Gy
Gray
GyE
Gray equivalent
MRI
Magnetic resonance imaging
PBT
Proton beam therapy
PET/CT
Positron emission tomography/computed tomography
SUVmax
Maximum standardized uptake value

T4
Thyroxine
TSH
Thyroid-stimulating hormone

LEARNING POINTS

- Persistent hoarseness with repeatedly “normal” mucosal findings on FODL should prompt consideration of submucosal laryngeal pathology and early cross-sectional imaging.
- ACC can present as a subglottic submucosal lesion and may be missed on initial examinations focused on mucosal abnormalities.
- Longitudinal surveillance should include both endoscopic evaluation and MRI with diffusion-weighted imaging, which may help distinguish residual/recurrent tumour from post-treatment change.

DECLARATIONS

Ethics approval and consent to participate

Ethical approval was not required for this single-patient case report in accordance with the Aga Khan University Ethics Review Committee’s institutional policy. Written informed consent was obtained from the patient for participation and use of the relevant clinical information.

Consent for publication

Written informed consent was obtained from the patient for publication of the clinical details and accompanying images. The institutional consent form was used.

Competing interests

The authors declare that they have no competing interests.

Authors’ information

Not applicable.

Funding

The authors received no funding for this work.

Author Contribution

H.A.P. contributed to case identification, conceptualization, clinical supervision, interpretation of clinical findings, treatment decision-making, and writing (review and editing). Z.Z. contributed to investigation, data curation, literature review, coordination of histopathological material, and writing (original draft, including the introduction and case presentation). R.H.S. contributed to literature review and writing (original draft, including the initial discussion). S.A.M.K. contributed to the data curation, coordination of radiological material, clinical interpretation, project administration, supervision of manuscript development, literature review, and writing (review and editing). All authors read and approved the final manuscript and agreed to be accountable for the work.

Acknowledgement

The authors acknowledge the carbon-ion radiotherapy team at the University of Heidelberg, Germany, for the patient's treatment and for providing the relevant treatment documentation. The authors also acknowledge Dr. Shahid Pervez for his contribution to the histopathological evaluation and diagnostic confirmation of the case. The authors also thank Dr Zafar Sajjad and Dr Fatima Mubarak for their assistance with radiological review and interpretation.

Availability of data and materials

Data sharing is not applicable to this article, as no datasets were generated or analysed during the current study. Relevant clinical information is included within the article.

REFERENCES

1. Ammad Ud Din M, Shaikh H. Adenoid Cystic Cancer. StatPearls [Internet]. Treasure Island (FL): StatPearls Publishing; 2026 [cited 2026 July 23]. http://www.ncbi.nlm.nih.gov/books/NBK557855/. Accessed 23 July 2026
2. Lionello M, Canal F, Presotto F, Palumbo R, Rizzotto G, Bertolin A. Laryngeal adenoid cystic carcinoma: Radical or conservative surgery? American Journal of Otolaryngology [Internet]. 2021 [cited 2026 July 23];42:102974. https://doi.org/10.1016/j.amjoto.2021.102974
3. Ebner DK, Malouff TD, Frank SJ, Koto M. The Role of Particle Therapy in Adenoid Cystic Carcinoma and Mucosal Melanoma of the Head and Neck. International Journal of Particle Therapy [Internet]. 2021 [cited 2026 July 23];8:273–84. https://doi.org/10.14338/IJPT-D-20-00076
4. Tan M, Chen Y, Du T, Wang Q, Wu X, Zhang Q, et al. Assessing the Impact of Charged Particle Radiation Therapy for Head and Neck Adenoid Cystic Carcinoma: A Systematic Review and Meta-Analysis. Technol Cancer Res Treat [Internet]. SAGE Publications Inc; 2024 [cited 2026 July 23];23:15330338241246653. https://doi.org/10.1177/15330338241246653

5. Bała K, Samovich Y, Dorobisz K. Proton Therapy in The Treatment of Head And Neck Cancers-Review. Curr Oncol Rep [Internet]. 2024 [cited 2026 July 23];26:1380–7. https://doi.org/10.1007/s11912-024-01592-9
6. Batsakis JG, Luna MA, El-Naggar AK. Pathology Consultation Nonsquamous Carcinomas of the Larynx. Ann Otol Rhinol Laryngol [Internet]. SAGE Publications Inc; 1992 [cited 2026 July 23];101:1024–6. https://doi.org/10.1177/000348949210101212
7. Atallah S, Casiraghi O, Fakhry N, Wassef M, Uro-Coste E, Espitalier F, et al. A prospective multicentre REFCOR study of 470 cases of head and neck Adenoid cystic carcinoma: epidemiology and prognostic factors. European Journal of Cancer [Internet]. Elsevier; 2020 [cited 2026 Sept 10];130:241–9. https://doi.org/10.1016/j.ejca.2020.01.023
8. Marchiano E, Chin OY, Fang CH, Park RC, Baredes S, Eloy JA. Laryngeal Adenoid Cystic Carcinoma. Otolaryngology–Head and Neck Surgery [Internet]. 2016 [cited 2026 July 23];154:433–9. https://doi.org/10.1177/0194599815621884
9. Dubal PM, Svider PF, Folbe AJ, Lin H-S, Park RC, Baredes S, et al. Laryngeal adenoid cystic carcinoma: A population-based perspective. The Laryngoscope [Internet]. 2015 [cited 2026 Sept 10];125:2485–90. https://doi.org/10.1002/lary.25448
10. Nielsen TK, Bjørndal K, Krogdahl A, Primdahl H, Kristensen CA, Andersen E, et al. Salivary gland carcinomas of the larynx: A national study in Denmark. Auris Nasus Larynx [Internet]. 2012 [cited 2026 July 23];39:611–4. https://doi.org/10.1016/j.anl.2012.02.003
11. Akbaba S, Lang K, Bulut OC, Held T, Rieken S, Plinkert P, et al. The role of organ- and function-preserving radiotherapy in the treatment of adenoid cystic carcinoma of the larynx. Head & Neck [Internet]. 2019 [cited 2026 July 26];41:2208–14. https://doi.org/10.1002/hed.25678
12. Misiukiewicz KJ, Camille N, Tishler R, Haddad R, Limaye S, Posner M. Organ Preservation for Adenoid Cystic Carcinoma of the Larynx. Oncologist [Internet]. 2013 [cited 2026 July 26];18:579–83. https://doi.org/10.1634/theoncologist.2012-0349
13. Rohit A, Bates JE, Frank SJ, Musha A, Ohno T, Holtzman A, et al. A systematic review of particle-based treatment modalities for adenoid cystic carcinomas of the head and neck. Radiotherapy and Oncology [Internet]. Elsevier; 2025 [cited 2026 July 23];212. https://doi.org/10.1016/j.radonc.2025.111115
14. Moukarbel RV, Goldstein DP, O'Sullivan B, Gullane PJ, Brown DH, Wang L, et al. Adenoid cystic carcinoma of the larynx: A 40-year experience. Head & Neck [Internet]. 2008 [cited 2026 Sept 10];30:919–24. https://doi.org/10.1002/hed.20802

Figures

PRESENTATION/EVENT	Initial presentation	FODL 1	FODL 2 due to persistent symptoms	FODL 3 due to persistent symptoms	FODL 4 due to worsening hoarseness	CT + MRI neck	FDG-PET/CT	Microlaryngoscopy + biopsy	Biopsy result	Final diagnosis
FINDINGS	Progressive hoarseness and cough	Glottic edema; mobile vocal cords; no visible mucosal lesion	Persistent glottic edema; no visible mucosal lesion	Persistent glottic edema; no visible mucosal lesion	Post-arytenoid and subglottic edema	CT: asymmetric left subglottic thickening; mild medialisation of left vocal cord; no cervical lymphadenopathy MRI: enhancing left subglottic lesion, 13.7 × 8.2 mm; extension into left vocal fold; no definite thyroid/cricoid cartilage invasion	FDG-avid lesion, 15 × 7 mm, SUVmax 5.3; no nodal or distant metastases	Submucosal subglottic lesion; no mucosal lesion	Cribriform and tubular ACC; AE1/AE3+, CD117+, p63+, CK5/6+; no perineural invasion	Subglottic ACC
MONTH	0		5	7	9					

Figure 1

Diagnostic timeline of subglottic ACC.

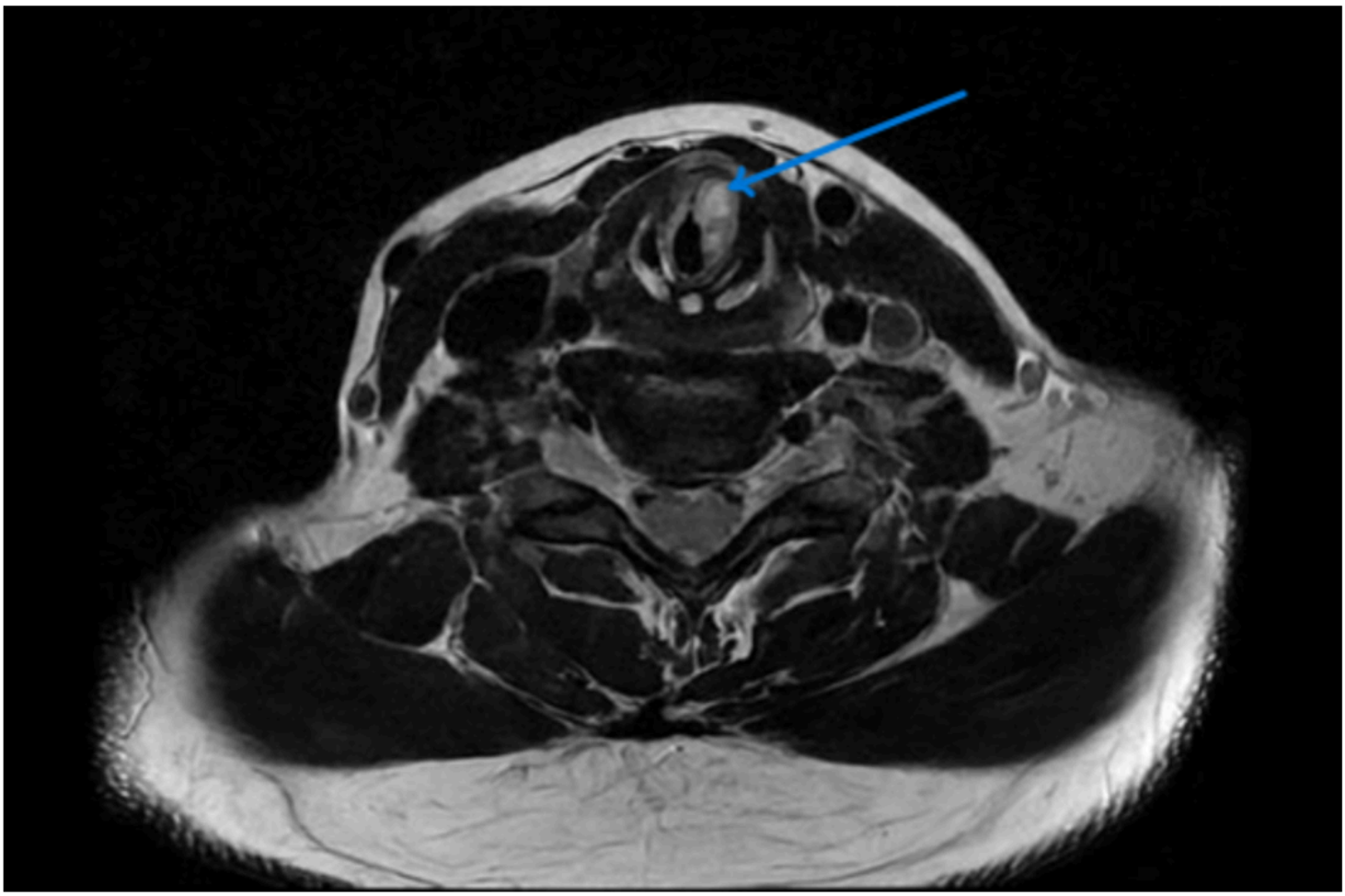

Figure 2

MRI of the neck showing a left subglottic enhancing lesion (blue arrow) abutting the adjacent cartilage with no definite invasion. Maximum thickness measures about 13.7 x 8.2 mm.

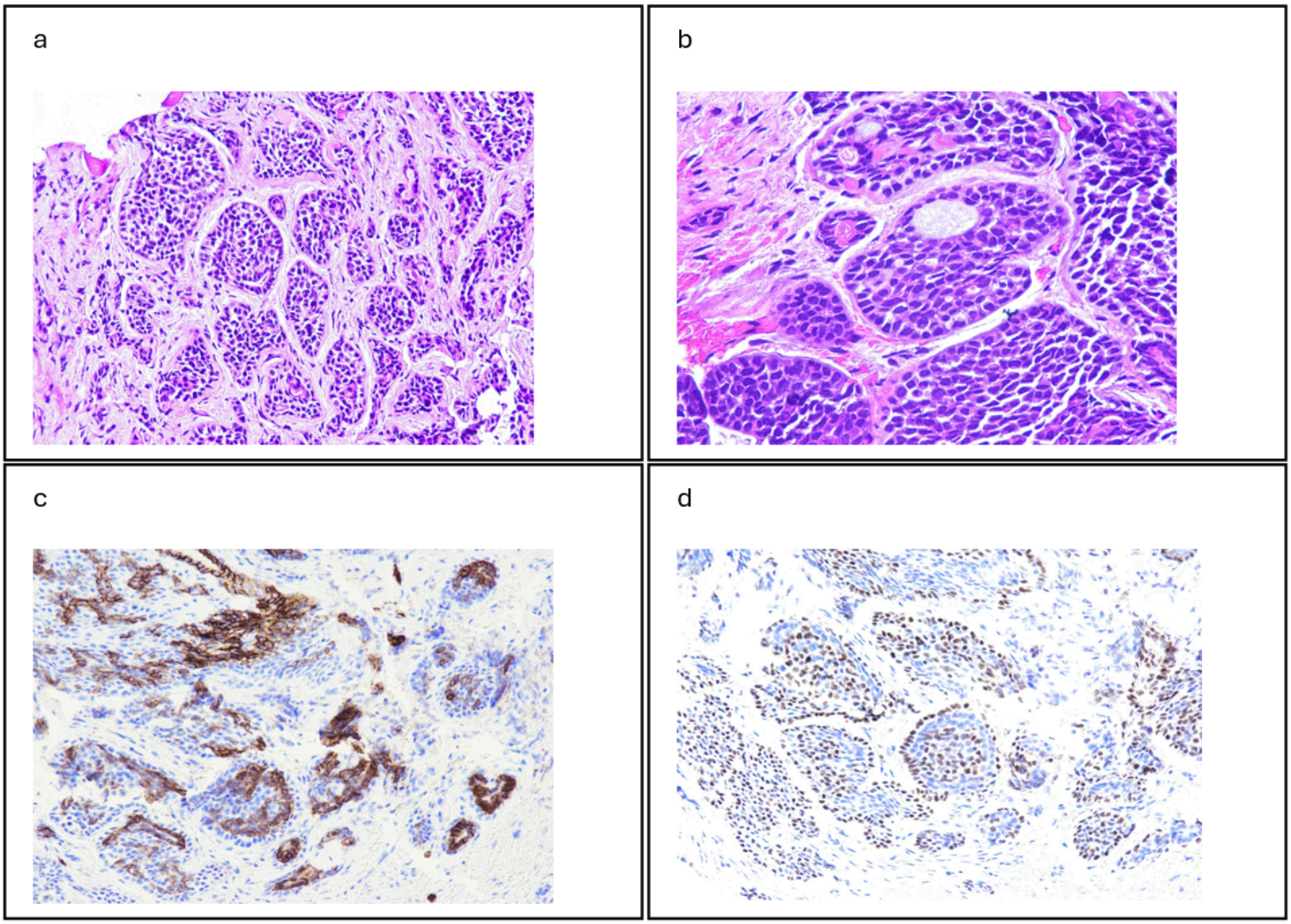

Figure 3

Histopathological features of subglottic adenoid cystic carcinoma. **a:** Permanent hematoxylin and eosin-stained section showing tumour arranged in cribriform and tubular structures within fibrous stroma. **b:** Higher-power view showing the characteristic biphasic cellular architecture and pseudoluminal spaces. **c:**Immunohistochemical staining for CD117 showing tumour-cell reactivity. **d:** Immunohistochemical staining for p63 showing nuclear reactivity in the tumour. The morphological and immunohistochemical findings supported the diagnosis of adenoid cystic carcinoma.