Research Square

Preprints are preliminary reports that have not undergone peer review. They should not be considered conclusive, used to inform clinical practice, or referenced by the media as validated information.

A Case of Misidentity: Rare Case of Hidradenocarcinoma of Ear

Dhanish Gopalakrishnan

p126405@siswa.ukm.edu.my

University Kebangsaan Malaysia Medical Centre https://orcid.org/0000-0001-6366-0119

Farah Dayana Zahedi

Department of Otorhinolaryngology-Head & Neck Surgery, Faculty of Medicine, Universiti Kebangsaan Malaysia

---

Case Report

Keywords: Hidradenocarcinoma, sweat gland carcinoma, cutaneous adnexal carcinoma, ear tumour, ear lobule, rare tumour

Posted Date: October 19th, 2026

DOI: https://doi.org/10.21203/rs.3.rs-11376068/v1

License: This work is licensed under a Creative Commons Attribution 4.0 International License. Read Full License

Additional Declarations: The authors declare no competing interests.

Abstract

Hidradenocarcinoma is an exceedingly rare and aggressive malignant tumour arising from sweat gland tissue, accounting for less than 0.001% of all tumours. It most commonly affects the head and neck region and typically presents in the fifth to seventh decades of life. We report a 75-year-old Chinese male with underlying diabetes mellitus, hypertension, infrarenal abdominal aortic aneurysm, and degenerative spine disease, who presented with a five-month history of a progressively enlarging, painless right ear lobule swelling associated with itching and minimal contact bleeding. Examination revealed a 3 × 3 cm broad-based, smooth, exophytic mass over the right ear lobule with surface crusting and bleeding on touch. Excision biopsy was performed under local anaesthesia. Histopathological examination demonstrated an intradermal malignant epithelial tumour composed of pleomorphic polygonal and clear cells with prominent nucleoli, frequent mitoses, tumour necrosis, and a Ki-67 proliferation index of 50–60%. Immunohistochemistry showed positivity for CK5/6 and epithelial membrane antigen (EMA), with negativity for CEA and BerEP4, consistent with hidradenocarcinoma. The patient declined further staging imaging and adjuvant treatment, opting instead for close clinical surveillance. He remains disease-free without evidence of local recurrence or distant metastasis at more than one year following excision. This case highlights the diagnostic challenge of hidradenocarcinoma, which may clinically mimic a benign cutaneous lesion, and underscores the importance of histopathological and immunohistochemical evaluation of unusual ear lesions. Given the lack of consensus guidelines, individualised management with complete surgical excision and long-term surveillance remains essential.

INTRODUCTION

Hidradenocarcinoma is a rare malignant tumour arising from the sweat glands and accounts for less than 0.001% of all tumours [1, 2, 3]. Hidradenocarcinoma is also synonymously known as clear cell eccrine carcinoma, malignant nodular hidradenoma, malignant clear cell acrospiroma, malignant clear cell hidradenoma, or primary mucoepidermoid cutaneous carcinoma [4]. This rare malignancy typically manifests in the head and neck region, with a particular emphasis on the face [5, 6]. The disease manifests predominantly between the fifth and seventh decades of life, and its incidence is comparable between men and women with no obvious racial prevalence. Typically, the tumour may appear as benign lesion [7]. Histological and immunohistochemical analysis are utilized to establish the diagnosis [8]. There is no consensus treatment for hidradenocarcinoma. The primary approach to treatment is surgery, which has been associated with a five-year postsurgical survival rate of less than 30% [9]. The rate of recurrence following surgery is 50% [10]. We report of an assuming benign looking growth over the ear lobule which was excised successfully.

CASE REPORT

Here we report a case of 75 years old Chinese Male with underlying Diabetes Melitus, hypertension, infrarenal abdominal aortic aneurysm and degenerative spine disease. He presented to ORL Hospital

Selayang August 2022, with chief complaint of right ear lobule swelling for 5 months (Fig. 1), gradually increasing in size, itching over swelling region and minimal contact bleed. Swelling was not associated with pain and pus discharge. He denied any trauma to the ear, fever, loss of appetite or loss of weight.

On examination of the right ear, the painless swelling measures 3cm x 3cm with a broad base with crusting over the tip of swelling. The surface was smooth with bleed on touch. The rest of pinna, external auditory canal and tympanic membrane was normal.

Operation: He underwent excision biopsy under local anaesthesia. Intraoperatively noted the mass ruptured upon manipulation discharging cheesy material. The skin was closed via primary closure and sutures was removed post operative day 7.

Upon subsequent review the right pinna wound healed well and no deformity to his ear. (Fig. 2).

Gross Appearance: received right pinna mass consist of one piece of brownish tissue measuring 30 x 30 x 26 mm with part of skin measuring 13 x 12 x 2mm. Cut section shows heterogenous yellowish brownish tissue.

Histology: Section shows intradermal tumour composed of solid sheets and trabeculae of neoplastic within collagenous stroma with connection with above epidermis. The neoplastic cells mainly composed of polygonal cells with vesicular nuclei and eosinophilic cytoplasm. The cells have pleomorphic nuclei and prominent nucleoli. Some of tumour cells are clear cells with eccentrically located nuclei with clear cytoplasm. Mitosis is easily seen with Ki67 index is 50–60%. Tumour necrosis noted.

Immunohistochemistry: The tumour cells are positive for CK5/6 and EMA. They are negative for CEA and BerEP4.

He was planned for CT staging, however patient and family request for conservative management and not keen for further management but agreed for close surveillance. He has since been tumour free during his 6 monthly follow up with his last visit to the ORL clinic in November 2023. (Fig. 3)

DISCUSSION

Due to the limited data available in the literature as well as the challenge in classifying sweat gland carcinomas, historically this have been difficult to study. There is no consensus has been established for the diagnosis histopathological features and treatment management for sweat gland carcinomas. Hidradenocarcinoma is a rare, aggressive, intradermal and skin adnexal malignant tumour of the sweat gland [11]. It accounts for around 6% of malignant eccrine tumours [10] and accounts for < 0.001% of all tumours [1, 2, 3]. Based on literature reviews, hidradenocarcinoma do not have prevalence towards either sex or race [12].

Diagnosis is based on histological and immunohistochemical analysis of biopsy material. Grossly, hidradenocarcinoma usually presents as well circumscribed nodule over superficial skin as how our

patient presented [11]. Hidradenocarcinoma is characterized by two different cell types: darker fusiform/spindle cells, which are deposited with eosinophilic cytoplasm, and larger clear cells that display atypical mitotic figures and nuclear pleomorphism [11]. Hidradenocarcinoma cells, like those of other eccrine tumours, exhibit the presence of cytokeratins, epithelial membrane antigen (EMA), carcinoembryonic antigen (CEA), and S100 protein [13]. Ko et al. concluded that Ki-67 and p53 staining may be useful histologic parameter [14]. Review back to the case we reported, sections showed pleomorphism with mitosis observed via Ki67 and tumour necrosis seen. The tumour concurrently was positive for CK5/6 and EMA.

Medical imaging techniques such as x-ray, ultrasonography, computed tomography scans, magnetic resonance imaging, and positron emission tomography scans are used to rule out local or distant spread of primary tumour [8]. However, in our patient, this was not done as patient was not keen for imaging and further management despite our advice.

Staging of hidradenocarcinoma can be done using the TNM Classification and staging system as per AJCC Cancer Staging Manual. Clinically we classified the patient as T2NxMx.

As hidradenocarcinoma is an extremely rare tumour, the is no consensus treatment to date [6]. The primary choice of treatment is surgery with wide local excision [4, 6, 11]. There would be a role of lymph node dissection if there is tumour metastasis to regional nodes [6, 11, 15]

Radiotherapy is often not recommended as the first treatment for cutaneous adnexal carcinomas [13]. Adjuvant radiation treatment is required in situations when surgery is not feasible, due to an unresectable tumour [13]. Radiotherapy has been used in several instances of hidradenocarcinoma, with inconsistent outcomes. Some studies have shown its efficacy, while others have reported radio-resistance [16].

The role of chemotherapy in sweat gland carcinoma remains unclear [17]. To date, there has been no evidence to support the efficacy of adjuvant chemotherapy, either alone or in combination with radiation therapy [11]. More research must be done in regard to management of hidradenocarcinoma with the roles of radiotherapy and chemotherapy.

Based on literature review, the five-year survival rate after surgery is 30% [9]. The risks of local recurrence after surgery vary between 10% and 50% [6].

CONCLUSION

The rarity of hidradenocarcinoma has led to a conundrum in the management of this condition. Contrary to the literatures, our patient is tumour free past 2 years with no signs of recurrence or metastasis. There is no clear guideline of frequency of surveillance visit, however we have continued monitoring him on regular basis of around 6 monthly. Much awareness needs to be instilled to the medical community

regarding this condition and further research is essential to come up with a proper treatment guideline for hidradenocarcinoma.

DECLARATIONS

Declaration of participant consent to publish: Written informed consent was obtained from the patient for participation in this case report and for the publication of their clinical details, investigations, images, and any potentially identifiable information. The patient was informed that the case report would be published and made publicly available.

REFERENCES

1. Santa Cruz DJ (1987) Sweet gland carcinomas a comprehensive review. Semin Diagn Pathol 4(1):38–74
2. Mehregan AH, Hashimoto K, Rahbari H (1983) Eccrine adenocarcinoma: a clinicopathologic study of 35 cases. Arch Dermatol 119(2):104–114. 10.1001/archderm.1983.01650260012008
3. Gouiaa N, Abbes K, Fakhfekh I et al (2008) Hidradénocarcinome développé sur un hidradénome préexistant. Ann de dermatologie et de vénéréologie 135:714–715. 10.1016/j.annder.2007.11.028
4. Obaidat NA, Alsaad KO, Ghazarian D (2007) Skin adnexal neoplasms—part 2: An approach to tumours of cutaneous sweat glands. J Clin Pathol 60(2):145–159. 10.1136/jcp.2006.041608
5. Yavel R et al (2009) Hidradenoma and hidradenocarcinoma of the scalp. Managed using Mohs micrographic surgery and a multidisciplinary surgery and a multidisciplinary approach: case reports and review of the literature. Dermatol Surg 35(2):273–281. 10.1111/j.1524-4725.2008.34424.x
6. Amel T et al (2009) Metastatic hidradenocarcinoma: Surgery and chemotherapy. N Am J Med Sci 1(7):372–374
7. Gauerke S, Driscoll JJ (2010) Hidradenocarcinomas: A Brief Review and Future Directions. Arch Pathol Lab Med 1 May 134(5):781–785. https://doi.org/10.5858/134.5.781
8. Toulemonde A, Croue A, Rodien P, Verret JL (2006) Nodular hidradenoma and multiple nodular malignant hidradenomas a patient hypogonadal. Ann Dermatol Venereol 133(12):1005–1008. 10.1016/S0151-9638(06)71088-2
9. Mirza I, Kloss R, Sieber SC (2002) Malignant eccrine spiradenoma. Arch Pathol Lab Med 126(5):591–594
10. Elder DE, Elensitas R, Johnson BL (2005) and G. F.Murphy. Histopathology of the skin, 9th edn. PALippincott Williams & Wilkins, Philadelphia
11. Gauerke S, Driscoll JJ (2010) Hidradenocarcinomas: a brief review and future directions. Arch Pathol Lab Med 134(5):781–785
12. Cooper PH (1987) Carcinoma of sweat glands. Pathol Annu 22(pt 1):83–124

13. Guillot B (2009) From unusual cutaneous malignancies: cutaneous adnexal tumors. In: Belkacemi Y, Mirimanoff R, Ozsahin M (eds) Management of rare adult tumors. Springer- Verlag France, Paris
14. Ko CJ, Cochran AJ (2006) W.Binder. Hidradenocarcinomas: a histological and immunochemical study.J Cutan Pathol. 33:726–730
15. Delgado R, Kraus D (2003) J.Busam. Sentinel lymph node analysis in patients with sweat gland carcinoma.Cancer. 97(9):2279–2284
16. Kyrgias G et al (2013) Hidradenocarcinoma of the temporal area successfully treated with concomitant electrochemotherapy and radiotherapy. Head Neck Oncol 5(2):14
17. Wang XX et al (2014) Primary cutaneous sweat gland carcinoma. J Can Res Ther 10:390–392. 10.4103/0973-1482.136667

Figures

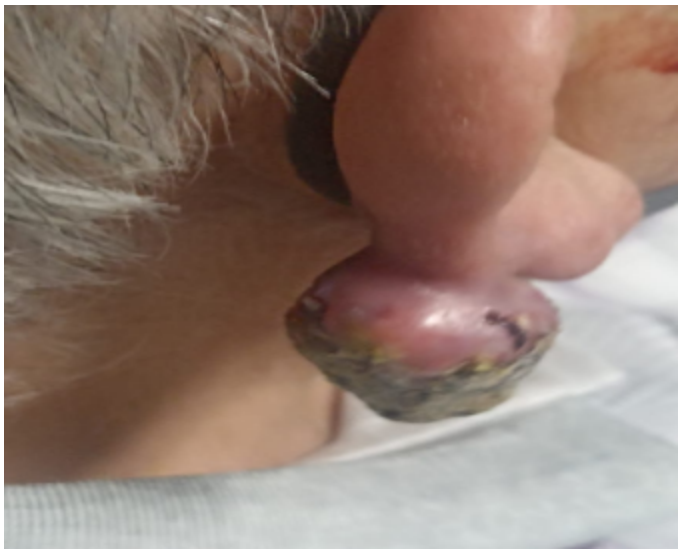

Figure 1

Initial presentation - right ear pinna swelling.

Figure 2

Post-operative month

Figure 3

Latest post-operative 2 years with no recurrence