Research Square

Preprints are preliminary reports that have not undergone peer review.
They should not be considered conclusive, used to inform clinical practice,
or referenced by the media as validated information.

A Randomized Controlled Clinical Trial Comparing Conventional and CAD/CAM- Fabricated Band-and-Loop Space Maintainers

Wenjuan Yan
Peking University School and Hospital of Stomatology
Yulan Ren
Peking University School and Hospital of Stomatology
Hongmei Zhang
Peking University School and Hospital of Stomatology
Yijiao Zhao
Peking University School and Hospital of Stomatology
Yong Wang
Peking University School and Hospital of Stomatology
Xiaoxian Chen
0464011926@bjmu.edu.cn

Peking University School and Hospital of Stomatology

Research Article

Keywords: Digital design, Chairside milling, Premature loss of primary teeth, Band-and-loop space maintainer

Posted Date: November 19th, 2026

DOI: https://doi.org/10.21203/rs.3.rs-11357094/v1

License: This work is licensed under a Creative Commons Attribution 4.0 International License. Read Full License

Additional Declarations: No competing interests reported.

Abstract

Background

Traditional space maintainers are fabricated manually and require a second follow-up visit, but digital technology is transforming this process. To compare the clinical outcomes of band-and-loop space maintainers fabricated using dedicated pediatric design software combined with chairside milling technology versus those fabricated conventionally with preformed bands.

Methods

Children with premature loss of primary molars requiring band-and-loop space maintainer therapy were prospectively enrolled and randomly allocated to either a computer-aided design/computer-aided manufacturing (CAD/CAM) group or a conventional fabrication group. Retention rates and periodontal health status were evaluated at 3, 6, and 12 months post-treatment.

Results

Fifty patients were enrolled, and 55 space maintainers were fabricated. One case was lost to follow-up, leaving 54 maintainers (26 conventional, 28 CAD/CAM) for analysis. Kaplan–Meier survival analysis revealed cumulative retention rates at 3, 6, and 12 months of 92.3%, 88.5%, and 80.8% in the conventional group, and 92.9%, 85.7%, and 75.0% in the CAD/CAM group, respectively (P = 0.6272).The CAD/CAM group significantly outperformed the conventional group with respect to band plaque area and gingival Bleeding Index (BI) (P < 0.05).

Conclusions

CAD/CAM-fabricated band-and-loop space maintainers achieve retention rates comparable to those of conventional maintainers while causing fewer adverse effects on periodontal health.

Clinical Trial Registration

: The study was prospectively registered with China Clinical Trial Registration Center on October 18, 2024 (ChiCTR2400091024). Trial registration was completed prior to patient enrollment.

Introduction

Dental caries is a highly prevalent chronic public health problem worldwide [1]. Untreated dental caries and its secondary periapical infections are the most common cause of pathological premature loss of primary teeth in children. Studies have confirmed that premature exfoliation of primary teeth is significantly associated with an increased prevalence of malocclusion in the permanent dentition, which manifests as increased overjet, dental crowding, disturbed molar relationships, or loss of arch space [2–4]. Approximately 40% of space loss occurs within the first three weeks after premature extraction of a primary molar [5, 6]. Timely and effective space management is therefore essential to prevent or minimize the development of malocclusion [7–9].

The band-and-loop space maintainer is the most widely used appliance for managing premature loss of a single primary molar [10]. However, its conventional fabrication has several inherent limitations: a relatively long manufacturing cycle necessitating a second appointment, limited marginal adaptation of prefabricated bands, and insufficient rigidity of the loop wire [11, 12]. These shortcomings frequently give rise to clinical complications, most notably plaque accumulation and compromised gingival health [13].

In recent years, CAD/CAM technology has been extensively integrated into various dental disciplines [14]. Existing evidence suggests that CAD/CAM-fabricated space maintainers deliver favorable clinical outcomes with high patient acceptance [15–18]. Nevertheless, their design has typically relied on general-purpose software lacking specialized modules for pediatric space maintainers, a factor that has hindered the broader global adoption of CAD/CAM technology in this field. To address this clinical need, our research team independently developed dedicated design software enabling individualized space maintainer design. A preliminary in vitro study demonstrated that maintainers produced with this software exhibit satisfactory fit and stability [19]. Building on this foundation, the present study aimed to evaluate the clinical performance of space maintainers fabricated with this software in combination with chairside milling equipment, in direct comparison with the conventional technique.

Materials and methods

Study Design and Ethical Approval

his prospective, randomized, controlled clinical trial compared CAD/CAM-fabricated band-and-loop space maintainers (digital group) with conventionally fabricated maintainers (conventional group). The trial was preregistered and reported in accordance with the CONSORT guidelines. Written informed consent was obtained from all participants and their legal guardians prior to enrollment.

Sample Size Calculation

The sample size was calculated based on a 9-month conventional retention rate of 51.6% in a previous study [20] and a retention rate of 9/10 for digital milling maintainers observed in our pilot study. Assuming a 1:1 allocation ratio, an anticipated dropout rate of 10%, a two-sided significance level (α) of 0.05, and a statistical power of 0.8, a minimum of 19 cases per group was required.

Participants

Children aged 4–10 years requiring fixed band-and-loop space maintainers for premature loss of primary molars were recruited.

Inclusion criteria: Unilateral or bilateral premature loss of primary molars without free-end defects; Presence of both mesial and distal abutment teeth without pathological mobility; Absence of caries, or presence of caries that had been successfully restored.

Exclusion criteria: Instability of the abutment teeth on either side of the edentulous space; Preformed metal crowns on abutment teeth; Intellectual disability; Systemic conditions contraindicating space maintainer therapy.

Eligible participants were randomly allocated to the conventional or digital group using the sealed envelope method.

Blinding

This study was designed as a single-blinded randomized controlled clinical trial. Parents and patients were not informed of the type of space maintainer and group allocation. Physicians and assessors were unblinded owing to the visible difference in the appearance of space maintainers between the two groups.

Clinical Procedures

Conventional group: Preformed metal bands were selected according to abutment tooth size and adjusted to optimize fit to the tooth morphology. Alginate impressions were taken, and plaster models were poured. A dental technician bent nickel–chromium alloy wire (0.9 mm in diameter) into loops, welded them to the bands, and polished the assembly. Cementation method was same with digital group.

Digital group: All digital designs were completed by one technician trained and certified by the software manufacturer, and clinical procedures were performed by four pediatric dentists who had received standardized training prior to trial initiation. The detailed workflow was as follows (Fig. 1):

(1) Digital model acquisition: An intraoral scanner (TRIOS; 3Shape, Denmark) was used to capture the dentition and occlusion on the affected side, and the data were exported in ".stl" format. When another molar was present distal to the abutment tooth, an elastic orthodontic separator was placed before scanning to separate the interproximal contact.

(2) Computer-aided design (CAD): An integrated band-and-loop space maintainer was designed using dedicated pediatric software (VisionMatrix Space Maintainer v1.0; VisionMatrix Medical Information Technology (Shandong) Co., Ltd., Jinan, China). The insertion path was determined, typically along the long axis of the abutment tooth, and undercuts were eliminated using the uniform concavity method.

1. Band design: The gingival and occlusal boundary lines were delineated on the abutment tooth, avoiding occlusal interferences. The margins were contoured according to tooth morphology and height, with a thickness of 0.5 mm, a width of ≥ 2 mm, and an adhesive gap of 0.05–0.10 mm between the band and the abutment. The "inner adhesive texture" function was applied to automatically generate a concavo-convex grid pattern on the intaglio surface to enhance bond retention.
2. Loop design: The loop was constructed using a point-to-line method, originating and terminating at the band, and formed a concave contour parallel to the alveolar ridge with a clearance of at least 1 mm from the gingiva. Its buccolingual width was slightly greater than that of the succedaneous permanent tooth. The free end of the loop encircled the mesial tooth in a C-shape, with the contact point positioned below the height of contour; the loop had a circular cross-section 1 mm in diameter.

The completed integrated design was exported in ".stl" format.

(3) Computer-aided manufacturing (CAM): A chairside five-axis milling unit (Ideal Mill M; Longyang Guoshu Technology Co., Ltd., Huizhou, China) was used to mill titanium discs (Adentatec GmbH, Germany) at a spindle speed of 28,000 r/min with a 1-mm-diameter milling burr for precise cutting.

(4) Cementation: The abutment teeth were etched with 37% phosphoric acid, and the space maintainers were bonded with a dual-cured resin cement (Multilink N; Ivoclar Vivadent, Liechtenstein), followed by occlusal adjustment as needed.

Outcome Measures

Immediately after cementation, the following parameters were assessed and recorded: ease of seating, marginal adaptation to the abutment, presence of tilting, and gingival compression. Follow-up examinations were performed at 3, 6, and 12 months post-treatment to evaluate clinical outcomes and to

inspect the condition of the maintainer and abutment. The edentulous space was assessed and measured by an independent examiner blinded to group allocation.

Primary outcome — retention rate: A maintainer was defined as "retained" in the absence of detachment, welding failure, or fracture; the occurrence of any of these events constituted "failure." Once failure occurred, all subsequent time points were counted as failures (cumulative failure rule). If the permanent successor erupted, the maintainer was removed and the case was recorded as "censored." Both "retained" and "censored" statuses were classified as clinical success.

Secondary outcomes:

1. Space maintenance efficiency: good (no change in interproximal space), fair (space reduction ≤ 1 mm), or poor (space reduction > 1 mm);
2. Plaque accumulation on the band: less (< 1/4 of the band area) or excessive (≥ 1/4 of the band area);
3. Gingivitis of the abutment tooth: none, mild (Bleeding Index [BI] = 1), or severe (marked gingival redness and swelling, BI > 1);
4. Caries of the abutment tooth attributable to the space maintainer: present or absent;
5. Loop subsidence: present or absent.

Statistical Analysis

Cumulative retention rates were estimated using the Kaplan–Meier method, and between-group differences were assessed with the log-rank test; retention at individual time points was compared using Fisher's exact test. Secondary outcomes were analyzed using the chi-square test or Fisher's exact test, as appropriate. All tests were two-tailed, with the significance level set at $\alpha = 0.05$.

Results

Participant Characteristics

A total of 50 patients (30 males, 19 females; mean age, 7.7 years) were enrolled, and 55 band-and-loop space maintainers were fabricated. One patient was lost to follow-up, leaving 54 maintainers in the final analysis: 26 in the conventional group and 28 in the digital group. The mean software design time was 10.2 ± 3.1 minutes per case.

Fabrication and Cementation Timeline

In the conventional group, impressions were sent to the laboratory after the initial visit, and the maintainers were cemented at a second appointment 1–2 weeks later. In the digital group, cementation was completed on the same day as, or the day after fabrication.

Notably, two patients in the digital group were treated under general anesthesia. In the first case, intraoral scanning and maintainer fabrication were performed preoperatively; the target tooth was then extracted and the maintainer placed during the same anesthetic session. In the second case, a severely carious first primary molar was extracted under general anesthesia, followed immediately by intraoral scanning, CAD/CAM fabrication, and cementation—all completed before the end of surger y (Fig. 2). The entire digital workflow, encompassing intraoral scanning, design, and fabrication, required 40–60 minutes.

Immediate Post-Cementation Assessment

In the conventional group, 2 of 26 maintainers encountered resistance during seating and could be placed only after adjustment of the loop angulation. The bands exhibited frictional retention against the abutments. Approximately 38% (10/26) of the maintainers exerted pressure on the distal and lingual gingiva of partially erupted abutments.

In contrast, all maintainers in the digital group were seated smoothly. Although the bands lacked frictional retention, they achieved intimate marginal adaptation without tilting or gingival compression.

Follow-Up Outcomes

The numbers of failures in the conventional group were 2, 1, and 2 at 3, 6, and 12 months, respectively, versus 2, 2, and 3 in the CAD/CAM group. Six maintainers in each group were censored after 6 months, leaving 20 and 22 maintainers under observation at 12 months in the conventional and CAD/CAM groups, respectively. Kaplan–Meier survival analysis revealed cumulative retention rates at 3, 6, and 12 months of 92.3%, 88.5%, and 80.8% in the conventional group, and 92.9%, 85.7%, and 75.0% in the CAD/CAM group, respectively; the log-rank test indicated no statistically significant difference in overall retention between the two groups over the 12-month period ($P = 0.6272$) (Fig. 3).

Both fabrication methods achieved comparable and clinically acceptable retention rates (Fig. 3). However, the digital group significantly outperformed the conventional group in plaque control and gingival health at all follow-up intervals At 12 months, the CAD/CAM group demonstrated significantly superior space maintenance efficiency ($P = 0.0012$) and a markedly lower incidence of loop subsidence ($P = 0.0001$) (Tables 1–3).

Table 1
Clinical performance of conventional and CAD/CAM fabricated band and loop space maintainers after 3 months [n (%)]

Group	Quantity	Cumulative retention rate	Space retention efficiency			Plaque area		Gingivitis			Abutment tooth caries	Subsidence of loops
			Good	Fair	Poor	Less	Excessive	None	Mild	Severe		
Conventional group	26	24(92)	26(100)	0	0	15(58)	11(42)	13(50)	13(50)	0	0	3(12)
CAD/CAM group	28	26(93)	28(100)	0	0	23(82)	5(18)	22(79)	6(21)	0	0	0
χ^2 value		-	/			3.87		4.83			/	-
P value		1.000	/			0.049		0.028			/	0.105
Note: BI stands for Bleeding Index; "-" denotes Fisher's exact test, with no statistical test value provided; "/"indicates constant, for which no statistical value has been calculated.												

Table 2
Clinical performance of conventional and CAD/CAM fabricated band and loop space maintainers after 6 months [n (%)]

Group	Quantity	Cumulative retention rate	Space retention efficiency			Plaque area		Gingivitis			Abutment tooth caries	Subsidence of loops
			Good	Fair	Poor	Less	Excessive	None	Mild	Severe		
Conventional group	26	23(88)	19(73)	7(27)	0	9(35)	17(65)	10(39)	14(54)	2(8)	1(4)	8(31)
CAD/CAM group	28	24(86)	26(93)	2(7)	0	27(96)	1(4)	26(93)	2(7)	0	0(0)	1(4)
χ^2 value		-	-			23.18			18.06		-	-
P value		1.000	0.072			< 0.001			< 0.001		0.481	0.100
Note: BI stands for Bleeding Index; "-" denotes Fisher's exact test, with no statistical test value provided												

Table 3
Clinical performance of conventional and CAD/CAM fabricated band and loop space maintainers after 12 months [n (%)]

Group	Quantity	Cumulative retention rate	Gap variation			Plaque area		Gingivitis			Abutment tooth caries	Subsidence of loops
			Good	Fair	Poor	Less	Excessive	None	Mild	Severe		
Conventional group	20	21(81)	12(56)	8(44)	0	14(70)	6(30)	13(65)	7(35)	0	2(10)	12(60)
CAD/CAM group	22	21(75)	22(100)	0	0	21(95)	1(5)	20(91)	2(9)	0	0(0)	0(0)
χ^2 value		-		-		-					-	-
P value		0.6653	0.0012			0.0408		0.0453			0.2207	0.0001
Note: BI stands for Bleeding Index; "-" denotes Fisher's exact test, with no statistical test value provided												

Discussion

This study evaluated the clinical application of dedicated pediatric CAD software, combined with chairside milling, for the fabrication of band-and-loop space maintainers. The system enables chairside design and same-day fabrication, and it achieved excellent clinical outcomes. Developed specifically for pediatric space maintainers, the software features a simple, efficient, and easily learned interface, requiring only approximately 10 minutes to complete a personalized design. Together with its favorable cost profile, these attributes make the platform well suited for widespread clinical adoption. The CAD/CAM maintainers were easy to seat, exerted minimal impact on periodontal tissues, and achieved retention rates statistically equivalent to those of conventionally fabricated maintainers, indicating promising prospects for clinical application.

This study identified several key advantages of the CAD/CAM approach. First, superior marginal fit. The precisely milled bands adapted intimately to the abutments, minimizing foreign body sensation, reducing chairside adjustment time, and lowering the risk of debonding and secondary abutment caries associated with cement dissolution. Second, expanded clinical versatility. The digital workflow overcomes several limitations of the conventional technique. For example, in cases of premature loss of the second primary molar with a partially erupted first permanent molar, a band can be designed on the first primary molar with an inverted loop extending onto the first permanent molar, exploiting the high strength of titanium to achieve robust space maintenance. Digital simulation of tooth extraction and gingival contouring permits immediate fabrication and placement of maintainers after removal of

non-restorable primary teeth. For children who cannot cooperate with routine outpatient care and require general anesthesia, this workflow obviates the need for a second sedation or anesthetic session—an advantage particularly valued by parents [21]. For incompletely erupted abutments, digital gingival simulation can enhance the retentive design; for primary teeth with insufficient crown height, occlusal partial-coverage or full-crown-and-loop maintainers can be designed (the software incorporates a primary tooth crown library), thereby increasing the bonding area and reducing the risk of debonding.Third, enhanced patient comfort, with reduced pain and dental fear [22–24]. Consistent with our findings, Nedeljkovic et al. evaluated an innovative approach using CAD/CAM-designed functional space maintainers and reported significant improvements in masticatory performance after placement, suggesting that CAD/CAM technology has the potential to set new standards in the fabrication of space maintainers in pediatric dentistry [25].

The retention outcomes of the two groups were comparable in the short term (3 months), with a low risk of early debonding. At 6 months, occasional new failures occurred in both groups, yet retention rates remained above 85%, without a significant intergroup difference. At 12 months, the retention rate in the digital group (75%) was slightly lower than that in the conventional group (81%), although the difference was not statistically significant. These findings are generally consistent with previous literature. Baroni et al. reported a stable 70% survival rate of fixed space maintainers [26], while Setia et al. reported a 9-month retention rate of 73.3% [27]. The different failure patterns between the two types of maintainers can be reasonably explained by their structural characteristics. The titanium digital space maintainer is designed without undercut structures and relies entirely on adhesive retention, making it prone to overall detachment under occlusal force and functional oral stress. In contrast, conventional band-and-loop maintainers mainly present progressive failure, including wire deformation, displacement, and solder fracture caused by long-term occlusal wear and mechanical fatigue.

The survival rate of space maintainers is affected by multiple confounding factors, including material properties, structural design, fabrication accuracy, bonding materials, and patient compliance [28]. Poor fabrication precision, marginal discrepancy, and inadequate morphological adaptation may lead to local stress concentration, further resulting in loosening, deformation, and detachment during long-term oral function. In this regard, individually customized appliances show better adaptation than standardized prefabricated products [28].Cengiz et al. demonstrated that 3D-printed space maintainers bonded with conventional glass ionomer cement presented a high 6-month failure rate of 66%, which was significantly higher than the 38% failure rate of the conventional band-and-loop group [29]. Kaur et al. further confirmed that resin cement provides significantly higher bonding strength than resin-modified glass ionomer cement and conventional glass ionomer cement, indicating that traditional glass ionomer cement is unsuitable for bonding CAD/CAM-fabricated space maintainers [30].

Current evidence indicates obvious heterogeneity in the failure modes of different fixed space maintainers. Due to the combined effects of multiple influencing factors, there is currently no optimal design or universal bonding protocol for clinical application [30].In the present study, high-strength resin cement was applied to improve bonding strength and interfacial stability for digital titanium maintainers, which was more compatible with CAD/CAM appliances. Furthermore, micro-retention structures were added based on standardized models to fit the fine anatomical morphology of abutment teeth, compensating for the lack of mechanical undercut retention, dispersing occlusal stress, and reducing the risk of overall detachment. Strict control of printing precision effectively avoided marginal inaccuracy and stress concentration, thereby reducing technical failure risks. Nevertheless, poor oral hygiene and low patient compliance can aggravate interfacial corrosion and appliance wear, significantly increasing the long-term failure rate. Therefore, regular clinical re-examination and professional maintenance are essential to improve the long-term survival of space maintainers.

The digital group demonstrated significantly superior plaque control and gingival health throughout follow-up, which can be attributed to several factors. The band margins in the digital group were positioned at or above the gingival margin, and precision milling ensured excellent marginal adaptation. Titanium exhibits excellent polishability, yielding a smoother surface less conducive to plaque accumulation, and its favorable biocompatibility and corrosion resistance reduce potential gingival irritation from metal ion release.

By contrast, the preformed bands used in the conventional group possess lower strength than milled titanium, and some of their margins extended subgingivally. Under repeated occlusal loading, these bands were prone to subsidence, resulting in gingival compression, erythema, and, in some patients, pain. Moreover, the nickel–chromium wire loops used conventionally lack sufficient rigidity—a key factor underlying loop subsidence, which became more pronounced with prolonged wear. Accordingly, at 12 months, the digital group demonstrated significantly better space maintenance efficacy and a markedly lower proportion of loop subsidence. Consistent with these observations, Cengiz et al. reported that both the gingival and plaque indices of abutment teeth increased at 6 months for both conventional and laser-printed maintainers relative to baseline, underscoring the importance of oral hygiene education prior to fixed space maintainer therapy [30].

This study has certain limitations, principally its modest sample size and relatively short observation period. Future studies with larger cohorts and extended follow-up are warranted to comprehensively evaluate the long-term effectiveness and durability of CAD/CAM-fabricated space maintainers.

Conclusions

CAD/CAM-fabricated band-and-loop space maintainers achieved effective space maintenance with retention rates comparable to those of the conventional method, and exerted less adverse impact on the periodontal tissues of the abutment teeth, indicating broad prospects for clinical application.

Abbreviations

CAD Computer-aided design

CAM Computer-aided manufacturing

BI Bleeding Index

Declarations

Ethics approval and consent to participate

Ethical approval for this study was granted by the Ethics Committee of the Peking University School and Hospital for Stomatology (PKUSSIRB-2024100097). The study protocol followed the Helsinki principles. Written informed consent was obtained from all participants and their legal guardians prior to enrollment after a detailed discussion regarding the clinical procedures, potential risks, and associated complications.

Consent for publication

Written informed consent for publication of their clinical images was obtained from the individual depicted in Fig. 1 and Fig. 3.

Funding

This study received the support provided by Program for New Clinical Techniques and Therapies of Peking University School and Hospital of Stomatology (PKUSSNCT-24A07).

Author Contribution

Chen Xiaoxian conceived the ideas; Yan Wenjuan, Ren Yulan and Zhang Hongmei collected the data; Zhao Yijiao, Wang Yong: software technical support; Xiaoxian Chen and Yan Wenjuan analysed the data and led the writing.

Acknowledgement

Not Applicable.

Data Availability

To comply with institutional privacy protocols, the primary datasets evaluated throughout this investigation are restricted from public repositories. However, anonymized data can be obtained directly from the corresponding author upon receiving a justified request.

References

1. GBD 2017 Disease and Injury Incidence and Prevalence Collaborators. Global, regional, and national incidence, prevalence, and years lived with disability for 354 diseases and injuries for 195 countries and territories, 1990–2017: a systematic analysis for the Global Burden of Disease Study 2017. Lancet. 2018;392(10159):1789–858. 10.1016/S0140-6736(18)32279-7PMC.
2. Brothwell DJ. Guidelines on the use of space maintainers following premature loss of primary teeth. J Can Dent Assoc. 1997;63(10):753–66.
3. Shakti P, Singh A, Purohit BM, et al. Effect of premature loss of primary teeth on prevalence of malocclusion in permanent dentition: A systematic review and meta-analysis. Int Orthod. 2023;21(4):100816. 10.1016/j.ortho.2023.100816Semantic.
4. Koaban A, Alotaibi SS, Abu Nakha KM, et al. Orthodontic Space Management in Pediatric Dentistry: A Clinical Review. Cureus. 2024;16(12):e76026. 10.7759/cureus.76026Cureus.
5. Bindayel NA. Clinical evaluation of short term space variation following premature loss of primary second molar, at early permanent dentition stage. Saudi Dent J. 2019;31(3):311–5. 10.1016/j.sdentj.2019.03.002PMC.
6. Macena MC, Tornisiello KC, Heimer MV, et al. Space changes after premature loss of deciduous molars among Brazilian children. Am J Orthod Dentofac Orthop. 2011;140(6):771–8. 10.1016/j.ajodo.2011.04.023PMC.
7. Space maintenance controversies. in pediatric dentistry—a scoping review. J Clin Pediatr Dent. 2025;49(6):1. 10.22514.... /jocpd.2025.121Journal of.
8. Casana-Ruiz M, Aura-Tormos JI, Marques-Martinez L, et al. Effectiveness of Space Maintainers in Pediatric Patients: A Systematic Review and Meta-Analysis. Dent J (Basel). 2025;13(1):32. 10.3390/dj13010032PMC.
9. Gandhi J, Gurunathan D. Short- and long-term dental arch spatial changes following premature loss of primary molars: A systematic review. J Indian Soc Pedod Prev Dent. 2022;40(3):239–45. 10.4103/jisppd.jisppd_230_22.
10. Chinese Society of Pediatric Dentistry. Expert consensus on the space maintainer in children. Zhonghua Kou Qiang Yi Xue Za Zhi. 2022;57(8):828–35.
11. Wang Q, Zhang Z, Zhong S, et al. Clinical application of a digital semi-rigid bridge space maintainer fabricated from polyetheretherketone for premature loss of primary molars. BMC Oral Health. 2023;23(1):944. doi:10.1186/s12903-023-03570-2BMC Oral H&#8230.
12. Sathyaprasad S, Krishnareddy MG, Vinod V, et al. Comparative Evaluation of Fixed Functional Cantilever Space Maintainer and Fixed Nonfunctional Space Maintainer: A Randomized Controlled Trial. Int J Clin Pediatr Dent. 2022;15(6):750–60. 10.5005/jp-journals-10005-2478PMC.
13. Tabatabai T, Kjellberg H. Effect of treatment with dental space maintainers after the early extraction of the second primary molar: a systematic review. Eur J Orthod. 2023;45(4):462–7. 10.1093/ejo/cjad006.

14. Balhaddad AA, Garcia IM, Mokeem L, et al. Three-dimensional (3D) printing in dental practice: Applications, areas of interest, and level of evidence. Clin Oral Investig. 2023;27(6):2465–81. 10.1007/s00784-023-04983-7PubMed.
15. Shakti P, Singh A, Purohit BM, et al. Effect of premature loss of primary teeth on prevalence of malocclusion in permanent dentition: A systematic review and meta-analysis. Int Orthod. 2023;21(4):100816. 10.1016/j.ortho.2023.100816PubMed.
16. Rodrigues LP, Dourado P, de Araujo C, et al. Digital workflow to produce esthetic space maintainers for growing patients. J Prosthet Dent. 2024;131(5):800–3. 10.1016/j.prosdent.2023.09.011.
17. Trivedi AV, Aduri R, Khan R, et al. Three-Dimensional Printed Lingual Arch Space Maintainer: A Game Changer in Pediatric Dentistry. Cureus. 2024;16(7):e63680. 10.7759/cureus.63680.
18. Khanna S, Rao D, Panwar S, et al. 3D Printed Band and Loop Space Maintainer: A Digital Game Changer in Preventive Orthodontics. J Clin Pediatr Dent. 2021;45(3):147–51. 10.22514/jocpd.2021.023.
19. Qin Q, Hu J, Chen X, et al. Chairside digital design and manufacturing method for children's band and loop space maintainers. Hua Xi Kou Qiang Yi Xue Za Zhi. 2024;42(2):234–41. 10.3724/SP.J.1008-2024.00234.
20. Thakur B, Bhardwaj A, Luke AM, et al. Effectiveness of traditional band and loop space maintainer vs 3D-printed space maintainer following the loss of primary teeth: a randomized clinical trial. Sci Rep. 2024;14(1):14081. 10.1038/s41598-024-64728-6.
21. Vij AA, Reddy A. Using digital impressions to fabricate space maintainers: A case report. Clin Case Rep. 2020;8(7):1274–6. 10.1002/ccr3.2934.
22. Tokuc M, Yilmaz H. Comparison of fit accuracy between conventional and CAD/CAM-fabricated band-loop space maintainers. Int J Paediatr Dent. 2022;32(5):764–71. 10.1111/ipd.12943.
23. Rathi N, Tirupathi S, Sawarkar S. Three-dimensional Printed Esthetic Innovative Space Maintainer for Children with ADHD: Short Communication. Int J Clin Pediatr Dent. 2023;16(6):908–10. 10.5005/jp-journals-10005-3730.
24. Dhanotra KG, Bhatia R. Digitainers-Digital Space Maintainers: A Review. Int J Clin Pediatr Dent. 2021;14(Suppl 1):S69–75. 10.5005/jp-journals-10005-1163.
25. Nedeljkovic A, Milosavljevic M, Mladenovic K, et al. Clinical outcomes of novel CAD/CAM-designed functional space maintainers produced via additive and subtractive methods: A randomized controlled trial. J Dent. 2025;155:105608. 10.1016/j.jdent.2025.105608.
26. Baroni C, Franchini A, Rimondini L. Survival of different types of space maintainers. Pediatr Dent. 1994;16(5):360–1.
27. Setia V, Kumar PI, Srivastava N, et al. Banded vs Bonded Space Maintainers: Finding Better Way Out. Int J Clin Pediatr Dent. 2014;7(2):97–104. 10.5005/jp-journals-10005-164.
28. Qudeimat MA, Sasa IS. Clinical success and longevity of band and loop compared to crown and loop space maintainers. Eur Arch Paediatr Dent. 2015;16(5):391–6. 10.1007/s40368-015-0194-8.
29. Cengiz A, Karayilmaz H. Comparative evaluation of the clinical success of 3D-printed space maintainers and band-loop space maintainers. Int J Paediatr Dent. 2024;34(5):584–92. 10.1111/ipd.13144.
30. Kaur J, Singh A, Sadana G, et al. Evaluation of Shear Peel Bond Strength of Different Adhesive Cements Used for Fixed Space Maintainer Cementation: An In Vitro Study. Int J Clin Pediatr Dent. 2021;14(2):97–104. 10.5005/jp-journals-10005-2017.

Figures

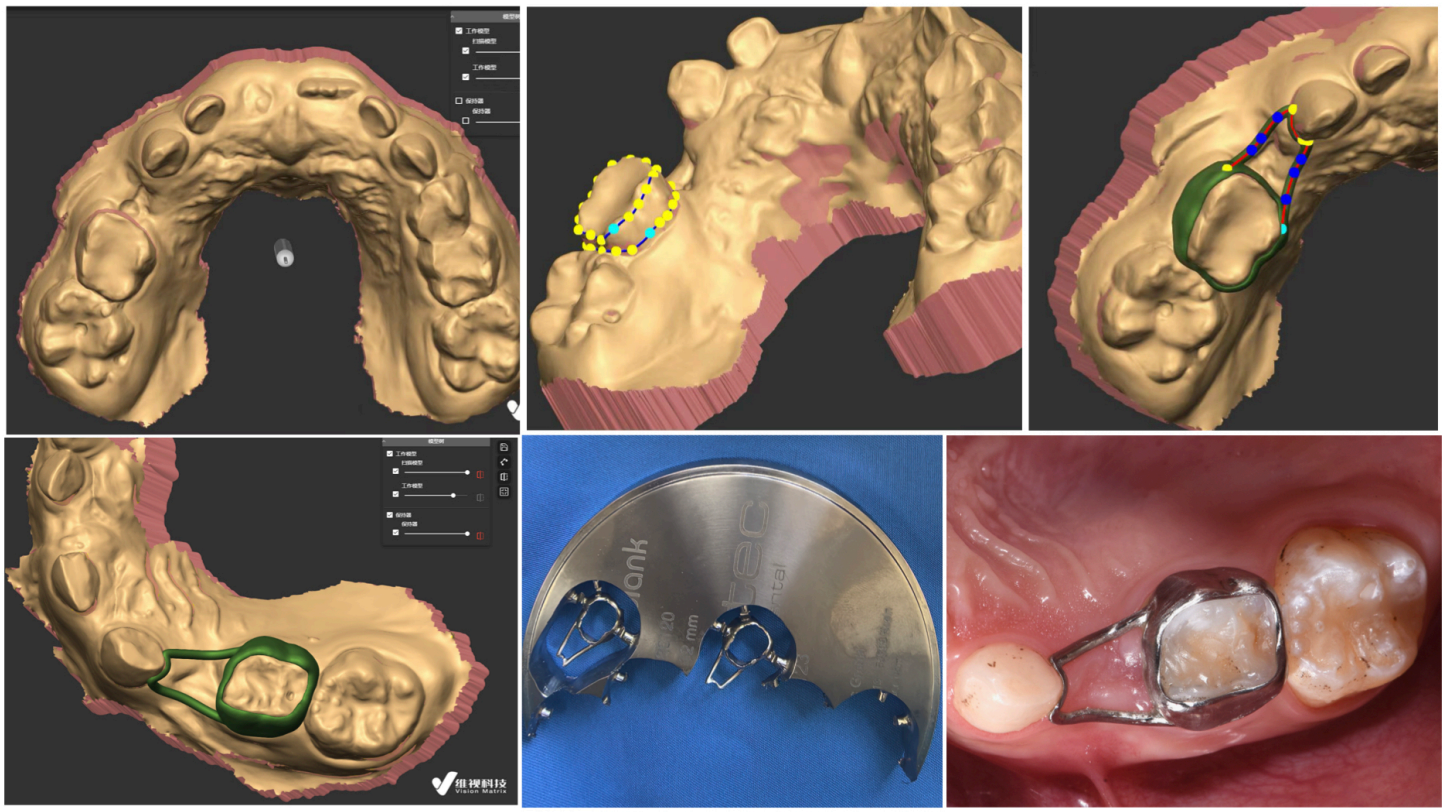

Figure 1

Workflow of CAD/CAM-fabricated space maintainers.



Figure 2

Clinical case of a CAD/CAM space maintainer placed under general anesthesia. A patient presented with severe early childhood caries. Under general anesthesia, tooth #54 was extracted. An intraoral scan was obtained, , and a CAD/CAM band-and-loop space maintainer was fabricated and cemented. At the 12-month follow-up, the maintainer remained well fixed, periodontal health was good, and no loop subsidence was observed.

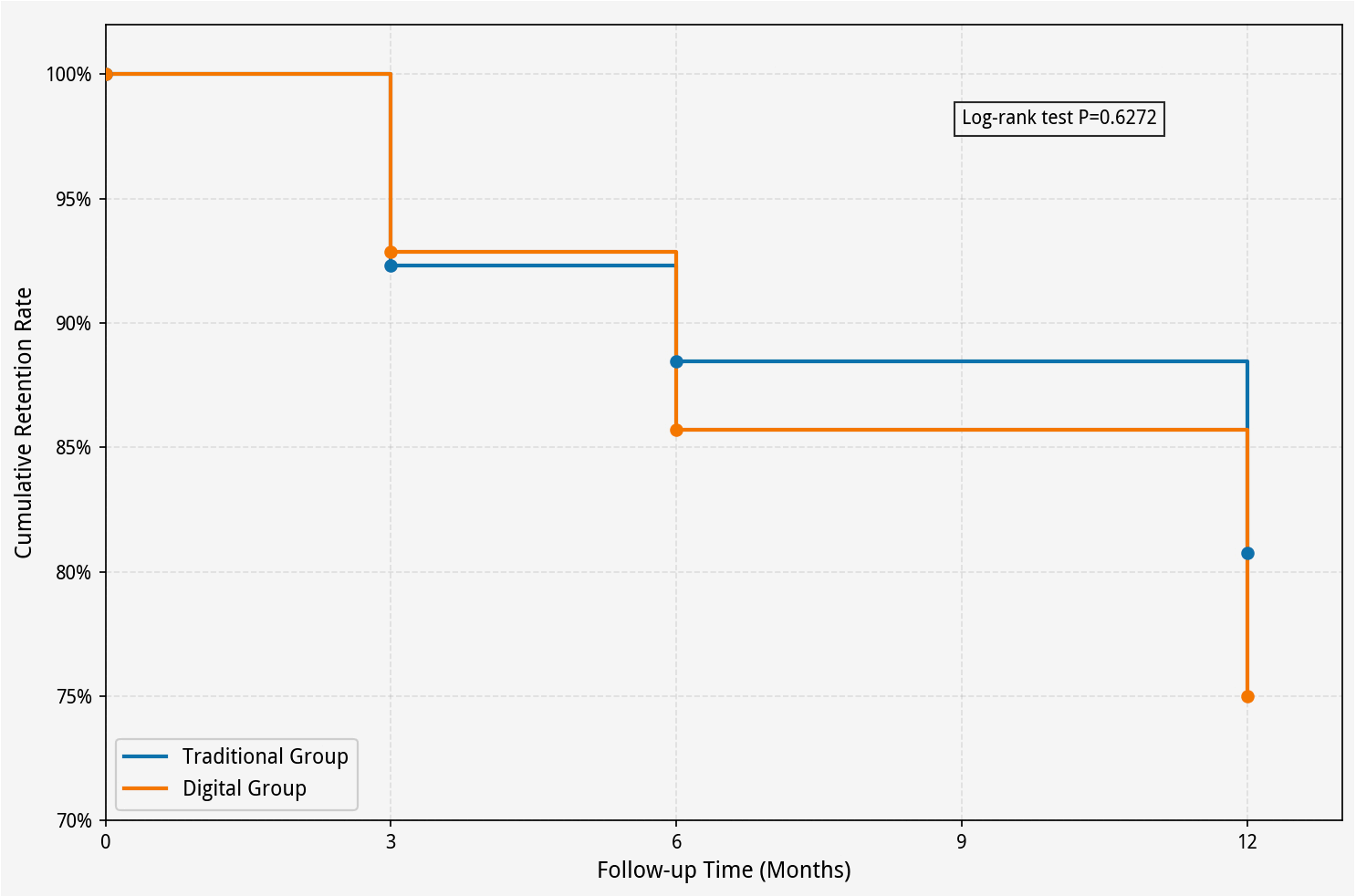

Figure 3

Kaplan–Meier survival curves of the space maintainers in the two groups.

Supplementary Files

This is a list of supplementary files associated with this preprint. Click to download.

- CONSORTchecklist.docx