Research Square

Preprints are preliminary reports that have not undergone peer review.
They should not be considered conclusive, used to inform clinical practice,
or referenced by the media as validated information.

Videolaryngoscopy failure without marked airway compression in a patient with coexisting rheumatoid cervical disease and diffuse idiopathic skeletal hyperostosis: a case report

Teruaki Kano

teruakika@jadecom.jp

Yokosuka General Medical Center

Hiroshi Sunagawa

Yokosuka General Medical Center

Masamitsu Sanui

Jichi Medical University Hospital

Case Report

Keywords: diffuse idiopathic skeletal hyperostosis, rheumatoid arthritis, difficult airway, videolaryngoscopy, supraglottic airway, bronchoscopic intubation

Posted Date: November 25th, 2026

DOI: https://doi.org/10.21203/rs.3.rs-11356068/v1

License: This work is licensed under a Creative Commons Attribution 4.0 International License.
Read Full License

Additional Declarations: No competing interests reported.

Videolaryngoscopy failure without marked airway compression in a patient with coexisting rheumatoid cervical disease and diffuse idiopathic skeletal hyperostosis: a case report

Teruaki Kano[1], Hiroshi Sunagawa[1], Masamitsu Sanui[2]

[1] Department of Anesthesiology, Yokosuka General Medical Center, 1-8 Shinmei-cho, Yokosuka, Kanagawa 239-8567, Japan

[2] Department of Anesthesiology and Intensive Care Medicine, Jichi Medical University, 3311-1 Yakushiji, Shimotsuke, Tochigi 329-0498, Japan

Corresponding author: Teruaki Kano, Department of Anesthesiology, Yokosuka General Medical Center, 1-8 Shinmei-cho, Yokosuka, Kanagawa 239-8567, Japan

E-mail: teruakika@jadecom.jp

Keywords: diffuse idiopathic skeletal hyperostosis; rheumatoid arthritis; difficult airway; videolaryngoscopy; supraglottic airway; bronchoscopic intubation

Abstract

Background: Diffuse idiopathic skeletal hyperostosis (DISH) can make airway management difficult through anterior cervical osteophytes and restriction of cervical motion. Rheumatoid arthritis (RA) may also cause difficult airway management through upper cervical disease. We report a patient with both disorders in whom videolaryngoscopy was severely difficult despite the absence of marked pharyngeal or laryngeal compression.

Case presentation: A 78-year-old woman with RA of more than 40 years' duration and cervical DISH had a nearly fixed flexed neck with markedly restricted extension. After being diagnosed with acute cholecystitis, endoscopic retrograde cholangiopancreatography (ERCP) was attempted, but the side-viewing endoscope could not be advanced across the pharyngoesophageal passage; open cholecystectomy and biliary reconstruction were therefore planned. Examination and computed tomography showed no evident structural abnormality of the pharyngeal or laryngeal soft tissues, marked upper-airway compression, tracheal stenosis, or deviation. Although difficult laryngoscopy was anticipated, facemask and supraglottic airway ventilation were judged likely to be feasible. After induction of general anesthesia, facemask ventilation was easy, but two videolaryngoscopes with different blade configurations showed only the posterior hypopharyngeal wall; neither the epiglottis nor the glottis could be identified. Further laryngoscopy was abandoned. A ProSeal laryngeal mask airway provided effective ventilation and a conduit for bronchoscopic tracheal access, followed by staged tube exchange. The same strategy was used successfully on postoperative day 5 during reoperation for biliary-enteric anastomotic leakage.

Conclusions: The combination of RA-associated upper cervical disease and DISH-related cervical fixation may cause severe laryngoscopic difficulty even when the upper-airway lumen

appears relatively preserved. Information from the failed ERCP, together with preoperative airway examination and CT, suggested difficult laryngoscopy but a relatively low risk of failed ventilation. In such patients, a cautious, staged airway strategy that preserves ventilation between steps may be a reasonable option while minimizing repeated airway manipulation and potential patient distress.

Background

Rheumatoid arthritis (RA) can complicate airway management through temporomandibular joint disease, cricoarytenoid involvement, and cervical spine abnormalities, including atlantoaxial pathology [1]. Diffuse idiopathic skeletal hyperostosis (DISH) is characterized by flowing ossification along the anterolateral spine, particularly the anterior longitudinal ligament. Cervical DISH can make tracheal intubation difficult in two main ways: anterior osteophytes may narrow or distort the pharyngeal and laryngeal airway, and progressive ossification can restrict cervical flexion-extension and limit the head and neck positioning required for laryngoscopy [2,3]. RA and DISH can coexist [4], but in the literature reviewed for this report we did not identify an airway-management case focused on a patient with both disorders.

Awake tracheal intubation is an important option when difficult intubation is anticipated [5,6]. Conversely, when intubation is attempted after induction, current difficult-airway guidance emphasizes limiting repeated attempts, maintaining oxygenation, and moving promptly to an alternative technique when the primary approach fails [5,7]. Supraglottic airway-guided bronchoscopic intubation is an established rescue technique, and similar rescue sequences have been reported in both DISH and RA [8-10]. The rescue technique used in the present case is therefore not proposed as novel; closely related published cases are summarized in Table 1.

We report a patient with long-standing RA-associated upper cervical disease and cervical DISH. Preoperative examination and CT showed severe restriction of cervical motion but no major abnormality of the pharyngeal or laryngeal soft tissues and no marked upper-airway compression. Difficult laryngoscopy was therefore anticipated, whereas facemask and supraglottic airway ventilation were judged likely to be feasible. In addition, a side-viewing endoscope used for ERCP had previously failed to cross the pharyngoesophageal passage. Because prolonged or repeated awake instrumentation might cause substantial discomfort and pharyngeal mucosal trauma, we planned a staged post-induction strategy in which ventilation could be secured before each subsequent step. This strategy was also used successfully during reoperation five days later.

Case presentation

A 78-year-old woman (height 138 cm; weight 28 kg; body mass index 14.7 kg/m^2) had RA of more than 40 years' duration. ERCP was attempted before definitive biliary surgery, but the side-viewing endoscope encountered marked resistance at the pharyngoesophageal passage and could not be advanced; the procedure was abandoned. The precise reason for the failed passage was not established. Open cholecystectomy and biliary reconstruction were subsequently planned.

Airway examination showed a mouth opening of approximately two fingerbreadths, modified Mallampati class IV, and upper lip bite test class II. The neck was nearly fixed in the patient's habitual flexed posture, with markedly restricted extension. Preoperative CT showed erosive changes around the atlantoaxial region attributed to RA, together with flowing ossification of the anterior longitudinal ligament, loss of cervical lordosis, and flexed cervical alignment consistent with cervical DISH (Fig. 1). The C2-C7 Cobb angle was -23° when lordosis was defined as positive. No anterior atlantoaxial subluxation was identified on the static CT obtained in the habitual flexed position. Flexion-extension cervical radiographs were not obtained. No evident

structural abnormality of the pharyngeal or laryngeal soft tissues, marked pharyngeal or laryngeal compression by anterior osteophytes, tracheal stenosis, or tracheal deviation was identified.

Difficult tracheal intubation was anticipated because of the fixed flexed neck, marked restriction of extension, and modified Mallampati class IV. In contrast, difficult facemask or supraglottic airway ventilation was judged less likely because there was no obesity, short neck, micrognathia, major dental defect, or facial abnormality expected to interfere with mask seal, no symptoms suggestive of obstructive sleep apnea or resting upper-airway obstruction, and no major pharyngeal or laryngeal soft-tissue abnormality on CT. The previous failed endoscope passage was considered separately as evidence that passage of a relatively rigid instrument across the pharyngoesophageal region could be difficult. Flexible bronchoscopy, videolaryngoscopes, supraglottic airway devices, and equipment for emergency front-of-neck airway access were prepared before induction. Awake tracheal intubation was considered a reasonable option, but a post-induction strategy was selected after balancing the anticipated difficulty of laryngoscopy against the expected feasibility of rescue ventilation.

After preoxygenation, general anesthesia was induced with fentanyl 200 μg, remimazolam 12 mg/kg/h, and rocuronium 25 mg. Two-handed facemask ventilation was easy.

Videolaryngoscopy was attempted once with a McGRATH MAC videolaryngoscope and once with an Airway Scope using a thin blade. With both devices, the blade appeared to reach the vicinity of the tongue base, but only the posterior hypopharyngeal wall was visible; neither the epiglottis nor the glottis could be identified. Because the same non-diagnostic view was obtained with two different blade configurations, and because repeated manipulation could cause mucosal trauma, bleeding, or edema that might compromise subsequent rescue, further laryngoscopy was abandoned.

A size 2.5 ProSeal laryngeal mask airway was inserted and effective ventilation was established.

A 3.1-mm outer-diameter flexible bronchoscope preloaded with a 4.5-mm internal-diameter

cuffed tracheal tube was advanced through the supraglottic airway into the trachea. After the tracheal rings and carina were identified, the 4.5-mm tube was advanced and the bronchoscope was withdrawn. A 5-Fr tracheal tube guide, with a 10-Fr suction catheter preloaded concentrically over it, was then advanced through the 4.5-mm tube without bronchoscopic visualization. The distal ends were advanced approximately 2 cm beyond the tip of the 4.5-mm tube. The 4.5-mm tube and the ProSeal laryngeal mask airway were removed while the guide-catheter assembly was retained. A 6.0-mm internal-diameter tracheal tube was advanced over the retained assembly. The guide and suction catheter were removed, and final tube position was confirmed by waveform capnography and bronchoscopy. Peripheral oxygen saturation remained 100% throughout airway management (Fig. 2).

The intraoperative course was stable. Neuromuscular blockade was reversed with sugammadex, and the trachea was extubated after the patient was awake, following commands, and had adequate spontaneous ventilation and oxygenation. No upper-airway obstruction, stridor, hoarseness, dysphagia, hypoxemia, or other airway-related complication was observed postoperatively.

On postoperative day 5, reoperation was required for leakage at the biliary-enteric anastomosis. The airway record from the first operation was reviewed, and the same patient-specific staged strategy was used. Tracheal intubation was again completed without hypoxemia or airway-related complications.

Discussion and Conclusions

Three findings were central to airway planning in this patient. First, long-standing RA-associated cervical disease and cervical DISH produced a nearly fixed flexed neck with markedly restricted extension, whereas preoperative examination and CT showed no major structural abnormality of the pharyngeal or laryngeal soft tissues and no marked airway compression. Second, the previous ERCP had been abandoned because a side-viewing endoscope could not cross the

pharyngoesophageal passage. Although the reason was not established, this was direct patient-specific evidence that passage of a relatively rigid instrument through this region could be difficult. Third, difficult laryngoscopy was anticipated while facemask and supraglottic airway ventilation were judged likely to remain feasible. These findings led us to prepare a staged post-induction airway strategy in which ventilation could be re-established before proceeding to bronchoscopic tracheal intubation.

The closest published reports are summarized in Table 1. Thompson et al. described failed videolaryngoscopy followed by successful laryngeal mask airway and fiberoptic bronchoscope rescue in a patient with DISH, but the airway was markedly distorted and displaced by prominent anterior cervical osteophytes [8]. Zhang et al. likewise reported videolaryngoscopy in which the epiglottis and vocal cords could not be identified; subsequent assessment showed that eccentric osteophytes occupied a large part of the laryngopharyngeal space [11]. In contrast, our patient had no marked pharyngeal or laryngeal compression. Matsuyama et al. reported severe direct-laryngoscopy difficulty caused by an immobilized craniocervical junction in RA, but the Airway Scope fully visualized the glottis [12]. Laryngeal mask airway-guided bronchoscopic intubation and subsequent tube exchange have also been reported in RA [9], and the rescue concept is established [10]. Thus, neither videolaryngoscopy failure nor supraglottic airway-guided bronchoscopic intubation is unique to the present case.

RA and DISH may alter cervical anatomy in different ways. RA may cause erosive change and instability, whereas DISH produces ligamentous ossification and may markedly reduce cervical mobility [1-4]. In our patient, atlantoaxial erosive changes coexisted with extensive anterior longitudinal ligament ossification and a nearly fixed flexed posture. Static CT did not show anterior atlantoaxial subluxation; however, flexion-extension radiographs were not obtained, so dynamic instability cannot be excluded. Resnick et al. described bone proliferation around erosions and bony ankylosis in patients with both RA and DISH [4]. Their findings support coexistence of erosive and bone-forming changes, but the present case cannot determine how

much each disease contributed to the fixed posture or whether DISH modified RA-related instability.

The mechanism of videolaryngoscopy failure in this patient remains uncertain. Preoperative CT showed no marked pharyngeal or laryngeal compression, tracheal narrowing, or major abnormality of the upper-airway soft tissues. Nevertheless, two videolaryngoscopes with different blade configurations showed only the posterior hypopharyngeal wall, and neither the epiglottis nor the glottis could be identified. The nearly fixed flexed neck and markedly restricted cervical extension associated with RA and DISH may have limited the head and neck positional adjustments required during laryngoscopy. The C2-C7 Cobb angle was included only to describe the abnormal cervical sagittal alignment and was not used as a predictor of videolaryngoscopy difficulty. Because blade position, viewing direction, and dynamic soft-tissue displacement were not measured, a specific anatomical mechanism cannot be established from this case. Insertion depth, limited lifting, and dynamic soft-tissue obstruction also remain possible explanations.

The failed ERCP provided a different type of information. The side-viewing endoscope had been unable to cross the pharyngoesophageal passage, although the reason for this difficulty was not established. This event is not a validated predictor of difficult tracheal intubation, and the endoscope differs substantially from airway devices in size, rigidity, and intended trajectory. We therefore do not interpret it as evidence of generalized difficulty with oral airway devices; indeed, supraglottic airway insertion was subsequently easy. Nevertheless, it documented previous difficulty passing a relatively rigid instrument through the pharyngoesophageal region in this particular patient and was therefore taken into account when planning airway management. Previous procedural information may complement conventional airway examination and static imaging when planning subsequent airway management.

Awake tracheal intubation with a flexible bronchoscope was a reasonable alternative. In this patient, however, preoperative examination and CT suggested that laryngoscopy would be

difficult while facemask and supraglottic airway ventilation were likely to remain feasible. The previous failed endoscope passage also raised concern that prolonged or repeated awake manipulation at the pharyngeal level could be uncomfortable and could cause mucosal injury, bleeding, or secretion accumulation, potentially degrading the bronchoscopic view. These concerns did not make awake intubation inappropriate, and failure of a side-viewing endoscope did not imply that a smaller flexible bronchoscope would fail. After preparing flexible bronchoscopy, videolaryngoscopes, supraglottic airway devices, and emergency front-of-neck airway equipment, we therefore chose a post-induction approach that allowed ventilation to be reassessed and restored between steps. This report does not show that post-induction intubation was safer than awake intubation. Rather, it supports making the decision after separately evaluating the expected difficulty of laryngoscopy, ventilation, and rescue in the individual patient.

After videolaryngoscopy failed, the ProSeal laryngeal mask airway first restored ventilation and then served as a conduit for bronchoscopic tracheal access. This is an established difficult-airway technique [9,10]. Because a size 2.5 device was used and the intended final tracheal tube could not be passed directly through it, a smaller tube was placed first and tracheal access was maintained during exchange using a guide and suction catheter. Tracheal tube advancement over a bronchoscope can fail because of impingement on laryngeal structures [14], but we did not measure whether the guide-catheter sequence prevented impingement in this case. The staged sequence should therefore be regarded as a patient-specific adaptation to anatomic and device-size constraints, not as a new or superior technique. Its practical advantage in this patient was that ventilation could be secured before further steps were undertaken and the procedure could be advanced in stages rather than by repeated laryngoscopy.

The same strategy was used successfully during reoperation for biliary-enteric anastomotic leakage on postoperative day 5. This does not establish general reproducibility or safety. It does

show the value of recording the actual laryngoscopic view, the device that restored ventilation, tube sizes, and the sequence that ultimately achieved tracheal intubation.

This report has several limitations. We could not directly determine why the ERCP endoscope failed to cross the pharyngoesophageal passage. Static CT and clinical examination cannot establish the mechanism of videolaryngoscopy failure. Flexion-extension cervical radiographs were not obtained, so dynamic atlantoaxial instability cannot be excluded. The individual contributions of RA, DISH, fixed flexion, small body size, and other airway factors cannot be separated. Awake oral or nasal bronchoscopic intubation was not attempted. Changes in pharyngeal dimensions after supraglottic airway insertion were not measured. Finally, two successful procedures in a single patient cannot establish the safety or efficacy of the staged exchange sequence.

In conclusion, this patient with coexisting RA-associated cervical disease and cervical DISH had severe videolaryngoscopic difficulty despite no marked upper-airway compression or major pharyngeal-laryngeal soft-tissue abnormality on CT. Marked restriction of cervical motion may have limited the positional adjustments required for laryngoscopy, but the mechanism could not be determined from static imaging. The airway strategy was based on the combination of a fixed abnormal cervical configuration, previous failure of a side-viewing endoscope to cross the pharyngoesophageal passage, and an expectation that rescue ventilation would remain feasible. When post-induction intubation is chosen in a patient with this pattern, a staged strategy that preserves ventilation between steps may be considered; awake intubation remains a reasonable alternative.

References

1. Kim HR, Kim SH. Perioperative and anesthetic management of patients with rheumatoid arthritis. Korean J Intern Med. 2022;37:732-9. doi:10.3904/kjim.2021.555.

2. Gosavi K, Dey P, Swami S. Airway management in case of diffuse idiopathic skeletal hyperostosis. Asian J Neurosurg. 2018;13:1260-3. doi:10.4103/ajns.AJNS_235_17.

3. Xu M, Liu Y, Yang J, Liu H, Ding C. Ossification of the cervical anterior longitudinal ligament is an underdiagnosed cause of difficult airway: a case report and review of the literature. BMC Anesthesiol. 2020;20:161. doi:10.1186/s12871-020-01077-9.

4. Resnick D, Curd J, Shapiro RF, Wiesner KB. Radiographic abnormalities of rheumatoid arthritis in patients with diffuse idiopathic skeletal hyperostosis. Arthritis Rheum. 1978;21:1-5. doi:10.1002/art.1780210101.

5. Apfelbaum JL, Hagberg CA, Connis RT, et al. 2022 American Society of Anesthesiologists Practice Guidelines for Management of the Difficult Airway. Anesthesiology. 2022;136:31-81. doi:10.1097/ALN.0000000000004002.

6. Ahmad I, El-Boghdadly K, Bhagrath R, et al. Difficult Airway Society guidelines for awake tracheal intubation (ATI) in adults. Anaesthesia. 2020;75:509-28. doi:10.1111/anae.14904.

7. Ahmad I, El-Boghdadly K, Iliff H, et al. Difficult Airway Society 2025 guidelines for management of unanticipated difficult tracheal intubation in adults. Br J Anaesth. 2026;136:283-307. doi:10.1016/j.bja.2025.10.006.

8. Thompson C, Moga R, Crosby ET. Failed videolaryngoscope intubation in a patient with diffuse idiopathic skeletal hyperostosis and spinal cord injury. Can J Anaesth. 2010;57:679-82. doi:10.1007/s12630-010-9313-5.

9. Mashio H, Kojima T, Goda Y, Kawahigashi H, Ito Y, Kato M. Intubation of a patient with rheumatoid arthritis with a 7.5-mm-ID armored endotracheal tube using a laryngeal mask airway. Masui. 1997;46:1639-43.

10. Berkow LC, Schwartz JM, Kan K, Corridore M, Heitmiller ES. Use of the Laryngeal Mask Airway-Aintree Intubating Catheter-fiberoptic bronchoscope technique for difficult intubation. J Clin Anesth. 2011;23:534-9. doi:10.1016/j.jclinane.2011.02.005.

11. Zhang X, Wang J, Liu Y, Li Z, Han B. A rare case of an unexpected difficult airway management in a diffuse idiopathic skeletal hyperostosis patient and post-operative airway evaluation with 3D printing technique. Ann Transl Med. 2021;9:75. doi:10.21037/atm-20-5992.

12. Matsuyama H, Hara M, Seto A, Hiraki T. Predictive underestimation of difficult direct laryngoscopy in a patient with rheumatoid arthritis-associated immobilized craniocervical junction. JA Clin Rep. 2023;9:85. doi:10.1186/s40981-023-00679-9.

13. Nakao K, Komasawa N, Kusunoki T, et al. Successful fiberoptic tracheal intubation guided by Airwayscope with a thin Intlock blade in a patient with severe rheumatoid arthritis. Masui. 2014;63:804-6.

14. Jackson AH, Orr B, Yeo C, Parker C, Craven R, Greenberg SL. Multiple sites of impingement of a tracheal tube as it is advanced over a fibreoptic bronchoscope or tracheal tube introducer in anaesthetized, paralysed patients. Anaesth Intensive Care. 2006;34:444-449. doi:10.1177/0310057X0603400409.

Figure legend

Figure 1. Clinical neck posture and preoperative cervical imaging. (A) Preoperative clinical photograph showing the patient's habitual fixed flexed cervical posture. (B) Preoperative midsagittal CT obtained in the habitual flexed position. Flowing ossification along the anterior longitudinal ligament and abnormal cervical sagittal alignment are shown. The black arrow indicates ossification of the anterior longitudinal ligament, consistent with cervical DISH. The C2-C7 Cobb angle was -23° when lordosis was defined as positive. No marked pharyngeal or laryngeal compression by anterior cervical osteophytes was identified. No anterior atlantoaxial subluxation was identified on this static image. (C) Preoperative coronal CT showing flowing anterolateral ossification consistent with DISH and erosive changes around the atlantoaxial region attributed to long-standing RA. The white arrow indicates the atlantoaxial erosive change, and the black arrows indicate flowing ossification.

Figure 2. Staged tracheal tube exchange after supraglottic airway-guided bronchoscopic intubation.

① A size 2.5 ProSeal laryngeal mask airway was inserted and effective ventilation was established.

② A 3.1-mm outer-diameter bronchoscope preloaded with a 4.5-mm internal-diameter cuffed endotracheal tube was advanced through the supraglottic airway into the trachea. After confirmation of the tracheal rings and carina, the 4.5-mm tube was advanced and the bronchoscope was withdrawn.

③ A 5-Fr tracheal tube guide, with a 10-Fr suction catheter preloaded concentrically over it, was advanced through the 4.5-mm tube without bronchoscopic visualization. The distal ends were advanced approximately 2 cm beyond the tip of the 4.5-mm tube.

④ The 4.5-mm endotracheal tube and ProSeal laryngeal mask airway were removed while the guide-catheter assembly was retained as an exchange rail.

⑤ A 6.0-mm internal-diameter endotracheal tube was advanced over the retained assembly. The guide and suction catheter were removed, and final tube position was confirmed by waveform capnography and bronchoscopy.

Declarations

Ethics approval and consent to participate

This case report was approved by the Ethics Committee of Yokosuka General Medical Center (approval number: 20260011). Written informed consent to participate was obtained from the patient.

Clinical trial number: not applicable.

Consent for publication

Written informed consent for publication of this case report, including the accompanying clinical information and images, was obtained from the patient.

Availability of data and materials

No research dataset was generated or analysed. The clinical information necessary to understand the case is contained in this article; additional patient-level data are not publicly available to protect patient confidentiality.

Competing interests

The authors declare that they have no competing interests.

Funding

The authors received no specific funding for this work.

Authors' contributions

TK conceived the report, participated in the anesthetic management, collected and interpreted the perioperative data, and drafted the manuscript. HS participated in the anesthetic management and critically revised the manuscript for important intellectual content. MS contributed to interpretation of the airway-management findings and critically revised the manuscript for important intellectual content. All authors read and approved the final manuscript and agree to be accountable for all aspects of the work.

Acknowledgements

Not applicable.

Authors' information

MS is Professor in the Department of Anesthesiology and Intensive Care Medicine, Jichi Medical University, with clinical and academic expertise in airway management and perioperative critical care.

Use of generative artificial intelligence

OpenAI ChatGPT was used to assist with manuscript organization, English translation, language editing, and comparison of author-identified literature. The authors reviewed and verified all clinical statements, references, and AI-assisted text against the source records and publications and take full responsibility for the final manuscript.

Figure 1. Clinical and radiological features of the cervical airway

(A) Preoperative clinical photograph showing the patient's habitual fixed flexed cervical posture.

(B) Preoperative midsagittal computed tomography obtained with the neck in the habitual flexed position. Flowing ossification along the anterior longitudinal ligament and abnormal cervical sagittal alignment are shown. The black arrow indicates ossification of the anterior longitudinal ligament, consistent with cervical diffuse idiopathic skeletal hyperostosis. The C2-C7 Cobb angle was −23° when lordosis was defined as positive. No marked pharyngeal or laryngeal compression by anterior cervical osteophytes was present. No anterior atlantoaxial subluxation was identified on this static image.

(C) Preoperative coronal computed tomography showing flowing anterolateral ossification consistent with diffuse idiopathic skeletal hyperostosis and erosive changes around the atlantoaxial region attributed to long-standing rheumatoid arthritis. The white arrow indicates the atlantoaxial erosive change, and the black arrows indicate flowing ossification.

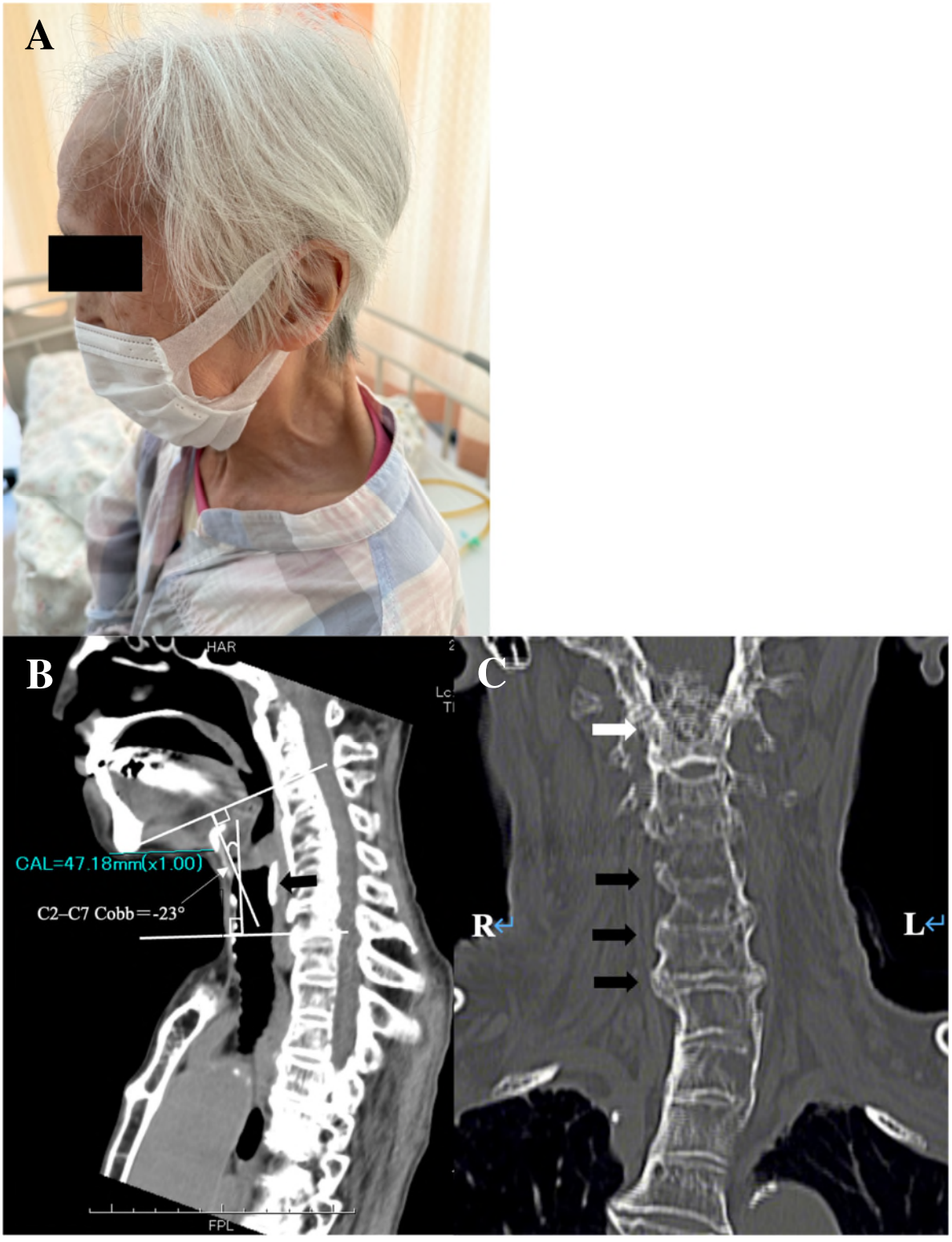
A
B
HAR
CAL=47.18mm(x1.00)
C2–C7 Cobb＝-23°
FPL
C
R
L

Figure 2. Staged tracheal tube exchange after supraglottic airway-guided bronchoscopic intubation.

① A size 2.5 ProSeal laryngeal mask airway was inserted and effective ventilation was established.

② A 3.1-mm outer-diameter bronchoscope preloaded with a 4.5-mm internal-diameter cuffed endotracheal tube was advanced through the supraglottic airway into the trachea. After confirmation of the tracheal rings and carina, the 4.5-mm tube was advanced and the bronchoscope was withdrawn.

③ A 5-Fr tracheal tube guide, with a 10-Fr suction catheter preloaded concentrically over it, was advanced through the 4.5-mm tube without bronchoscopic visualization. The distal ends were advanced approximately 2 cm beyond the tip of the 4.5-mm tube.

④ The 4.5-mm endotracheal tube and ProSeal laryngeal mask airway were removed while the guide-catheter assembly was retained as an exchange rail.

⑤ A 6.0-mm internal-diameter endotracheal tube was advanced over the retained assembly. The guide and suction catheter were removed, and final tube position was confirmed by waveform capnography and bronchoscopy.

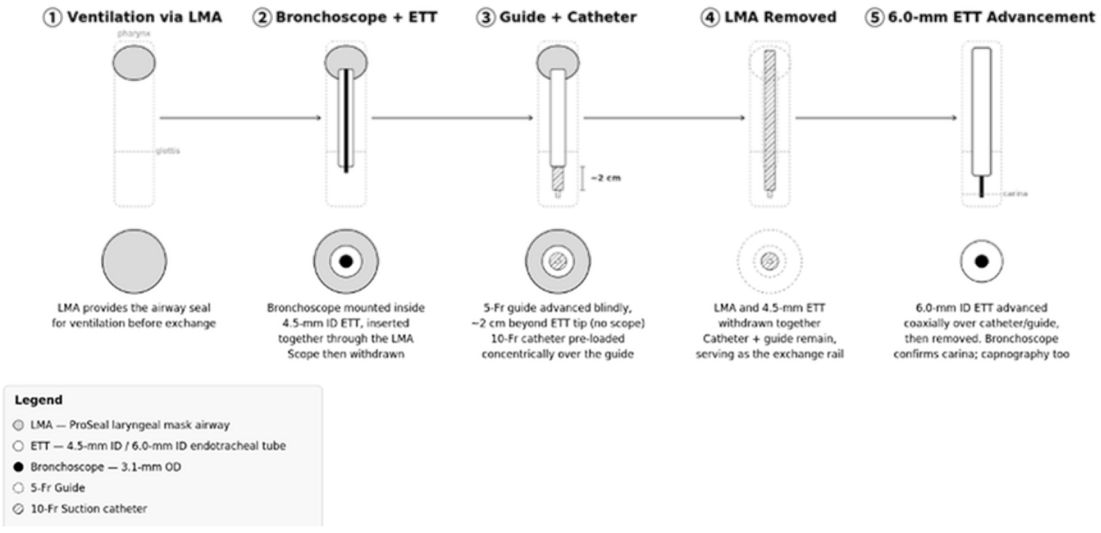

Figure 2. Comparison with closely related published difficult-airway cases

Report	Disease/anatomy	Airway difficulty	Management/outcome	Relation to present case
Mashio et al., 1997 [9]	RA; limited cervical movement; atrophic mandible	Predicted difficult intubation	LMA + fiberscope + tube changer	Shows that LMA-guided bronchoscopic intubation with tube exchange in RA is established
Thompson et al., 2010 [8]	DISH; prominent anterior osteophytes; severe airway distortion	Videolaryngoscope failed	LMA + fiberoptic bronchoscope; tube exchange	Very similar rescue sequence, but severe airway distortion/anterior displacement was present
Nakao et al., 2014 [13]	Severe RA	GlideScope and nasal intubation failed; AWS alone did not reveal glottis	AWS-guided fiberoptic intubation	Severe RA-related instrumentation difficulty; no DISH
Zhang et al., 2021 [11]	DISH; eccentric osteophytes occupying laryngopharyngeal space	Videolaryngoscopy failed; epiglottis/vocal cords not identified	LMA failed; nasal fiberoptic intubation succeeded	Imaging initially underestimated compromise, but substantial pharyngeal encroachment was demonstrated
Matsuyama et al., 2023 [12]	RA; occiput-atlas-axis bony integration	Direct laryngoscopy Cormack-Lehane grade IV	Airway Scope fully visualized glottis	Upper cervical fixation caused difficult direct laryngoscopy, but videolaryngoscopy succeeded
Present case	RA-associated atlantoaxial erosive disease + cervical DISH; fixed flexed alignment; no marked airway compression	Two differently configured videolaryngoscopes failed to identify epiglottis/glottis	ProSeal LMA + bronchoscopic access + staged tube exchange; same strategy successful at reoperation	Focus is the dissociation between relatively preserved lumen and restricted instrumentation pathway

CT: computed tomography; DISH: diffuse idiopathic skeletal hyperostosis; ERCP: endoscopic retrograde cholangiopancreatography; LMA: laryngeal mask airway; RA: rheumatoid arthritis.