Research Square

Preprints are preliminary reports that have not undergone peer review.
They should not be considered conclusive, used to inform clinical practice,
or referenced by the media as validated information.

Scleral Calcification Masquerading as an Ulcer 20 Years After Bare-Sclera Pterygium Excision: A Case Report

Shuyu Han
Shenzhen Huaxia Eye Hospital
Qi Fang
Shenzhen Huaxia Eye Hospital
Shu Zhou
Chengdu Aidi Eye Hospital
Yuan Tian
Chengdu Aidi Eye Hospital
Xiaoming Yao
xmyeye@163.com
Chengdu Aidi Eye Hospital
Yukun Yang
Chengdu Aidi Eye Hospital

Case Report

Keywords: Scleral calcification, Scleral ulcer, Pterygium, Phosphate buffer, Ocular surface reconstruction

Posted Date: November 23rd, 2026

DOI: https://doi.org/10.21203/rs.3.rs-11355984/v1

License: This work is licensed under a Creative Commons Attribution 4.0 International License.
Read Full License

Additional Declarations: No competing interests reported.

Scleral Calcification Masquerading as an Ulcer 20 Years After Bare-Sclera Pterygium Excision: A Case Report

Shuyu Han, M.Med[1], Qi Fang, M.B.B.S[1], Shu Zhou, M.Med[2], Yuan Tian, M.D.[2], Xiaoming Yao, M.D., PhD[2*]， Yukun Yang, M.Med[2*]

[1] Department of Cataract & Refractive Surgery, Shenzhen Huaxia Eye Hospital, Shenzhen, China

[2] Department of Ocular Surface & Corneal Diseases, Chengdu Aidi Eye Hospital, Chengdu, China

*Correspondence: Xiaoming Yao, M.D., PhD (E-mail: xmyeye@163.com) and Yukun Yang, M.Med (E-mail: yk_yang966@126.com)

Abstract

Purpose: To report a case of late-onset scleral calcification clinically mimicking scleral ulceration after bare-sclera pterygium excision, and to discuss possible contributing factors and surgical management.

Methods: A 71-year-old woman presented with a progressively enlarging nasal scleral lesion in her right eye. Clinical management—including comprehensive history taking, slit-lamp biomicroscopy, surgical excision, homologous scleral grafting, autologous conjunctival transplantation, histopathological evaluation, and a 9-month postoperative follow-up—was retrospectively reviewed.

Results: The patient had undergone bare-sclera pterygium excision in 2006 and subsequently used polyvinyl alcohol, prednisolone acetate, and olopatadine eye drops for approximately eight years postoperatively. Histopathological examination of the excised tissue revealed dense calcium salt deposits within fragmented scleral collagen,eatablishing the diagnosis of scleral calcification. Following excision, homologous scleral patch grafting and autologous

conjunctival transplantation achieved stable ocular-surface reconstruction. At nine months, the graft remained well healed and the visual acuity was 20/25. **Conclusions:** Late scleral calcification should be considered in the differential diagnosis of a painless, progressive calcific lesion arising at a previous bare-sclera pterygium excision site. Histopathology can be valuable when the clinical diagnosis is uncertain.In this case, combined homologous scleral patch grafting and autologous conjunctival transplantation provided a satisfactory method for ocular-surface reconstruction. The possible contribution of prolonged topical medication exposure, including phosphate-containing formulations, remains biologically plausible but cannot be established from a single case.

Keywords: Scleral calcification; Scleral ulcer; Pterygium; Phosphate buffer; Ocular surface reconstruction

1. Introduction

Scleral calcification is characterized by the deposition of calcium salts within the collagen matrix of the sclera, and clinically presents with a slowly progressive, asymptomatic, yellowish-white plaque in older adults [1,2]. When associated with marked scleral thinning and choroidal show-through, however, its appearance may overlap with necrotizing scleritis, scleral ulceration, infection, or other causes of scleral thinning, for which management differs substantially [3].The reported etiologies include age-related alterations in scleral proteoglycans, systemic metabolic dysregulation (e.g., hyperparathyroidism, chronic renal failure), and iatrogenic insults such as adjunctive beta-irradiation or mitomycin C application during pterygium surgery [4–6]. Topical phosphate exposure has also been implicated in ocular-surface calcification, although evidence specifically linking chronic phosphate-containing eye drops to calcification of a bare scleral bed is limited [7,8]. Herein, we report a late-onset case after bare-sclera pterygium excision and discuss the differential diagnosis, possible contributing factors, and reconstructive management.

2. Case Report

2.1. Patient Information and History

A 71-year-old Chinese female presented on December 30, 2025, complaining of a 1-year history of an elevated whitish nasal scleral lesion in her right eye that had recently enlarged. She denied ocular pain, photophobia, or significant visual loss.

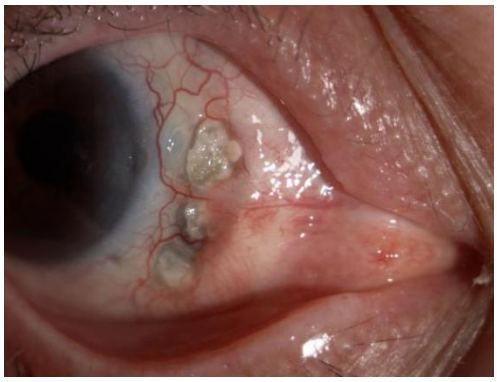

Fig. 1 Slit-lamp photograph of the right eye demonstrating nasal scleral calcification.

Her ocular history was notable for a bare-sclera pterygium excision in her right eye in 2006. Postoperatively, she reported intermittent-to-regular use of polyvinyl alcohol eye drops (Shijiazhuang No. 4 Pharmaceutical Co., Ltd., China), prednisolone acetate ophthalmic suspension (Pred Forte®, AbbVie Inc., North Chicago, IL, USA), and olopatadine hydrochloride ophthalmic solution (Patanol®, Alcon Laboratories, Inc., Fort Worth, TX, USA) for approximately eight years . The buffer composition and cumulative exposure of the specific formulations used over this period could not be independently verified from the clinical record. She reported no history of ocular trauma, autoimmune disease, or systemic metabolic disorders (renal failure or hyperparathyroidism). Serum calcium, phosphate, alkaline phosphatase, and renal function parameters were all within normal reference ranges.

2.2. Clinical Examination

Slit-lamp biomicroscopy of the right eye revealed a well-demarcated, elevated, chalky-white nodular lesion measuring approximately 5.0mm×15.0 mm in the nasal paralimbal sclera (Figure 1). Mild localized conjunctival hyperemia, irregular crystalline deposits, scleral thinning and subtle dark-blue choroidal show-through were present (Figure 2). The adjacent cornea was clear, and the anterior chamber was quiet without flare or cells. Uncorrected visual acuity (UCVA) was 20/40 in the right eye and 20/30 in the left eye. Intraocular pressure (IOP) measured by Goldmann applanation tonometry was 15 mmHg in both eyes. Dilated fundus examination was unremarkable bilaterally.

2.3. Surgical Technique and Histopathology

Given the progressive enlargement of the lesion, with risk of impending globe perforation, and uncertainty regarding malignancy or infection, surgical intervention was performed under local anesthesia. After dissection of the overlying conjunctiva, the calcified plaque infiltrating the anterior sclera was completely excised (Figure 2) and submitted for histopathological examination. The residual deep scleral defect (5.0mm×15.0mm) was repaired with a preserved homologous donor scleral graft secured with interrupted 10-0 nylon sutures. An autologous conjunctival limbal graft harvested from the superior bulbar conjunctiva was placed on the scleral graft and secured with 10-0 vicryl sutures (Figure 2). Hematoxylin and eosin (H&E) staining demonstrated dense, acellular, basophilic calcium deposits embedded within fragmented collagen bundles, confirming the diagnosis of scleral calcification, with no active inflammatory infiltrate or malignant tissue identified in the submitted specimen (Figure 3).

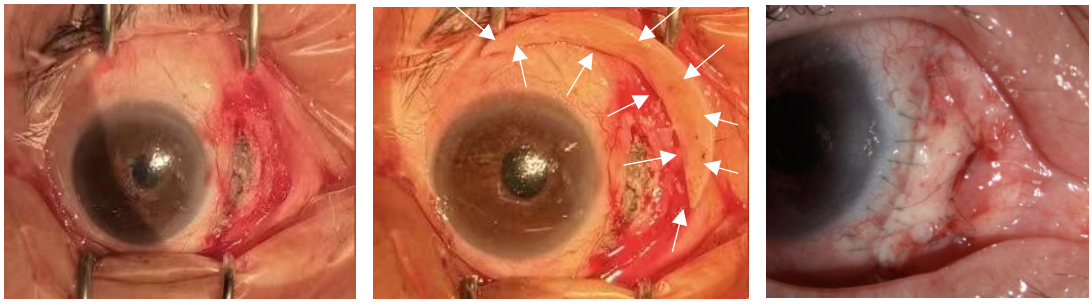

Fig. 2 Surgical procedures. Preparing the scleral bed: excising the calcified scleral plaque to expose the choroid (left). Preparing the allogeneic scleral graft: the allogeneic scleral patch before trimming (white arrows) (middle). Allogeneic scleral grafting combined with free autologous conjunctival transplantation completed (right).

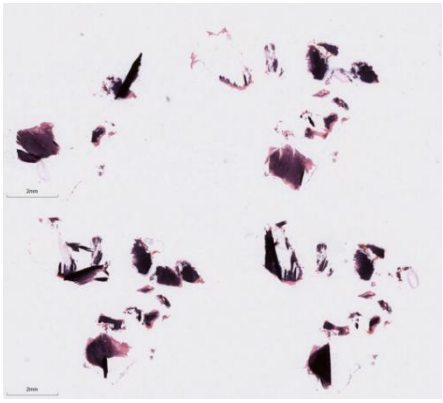

Fig. 3 H&E staining shows dense, acellular, basophilic calcium deposits in fragmented collagen bundles, confirming scleral calcification.

2.4. Postoperative Course

Postoperatively, the patient received topical tobramycin-dexamethasone and preservative-free artificial tears. Conjunctival sutures were removed at one week. At two months, the conjunctivalized scleral graft was well-integrated and vascularized, without clinical evidence of graft rejection, infection, recurrence of calcification, or elevated IOP. Visual acuity was 20/40. At nine months, the sclera and conjunctiva grafts remained well healed and visual acuity was 20/25 (Figure 4).

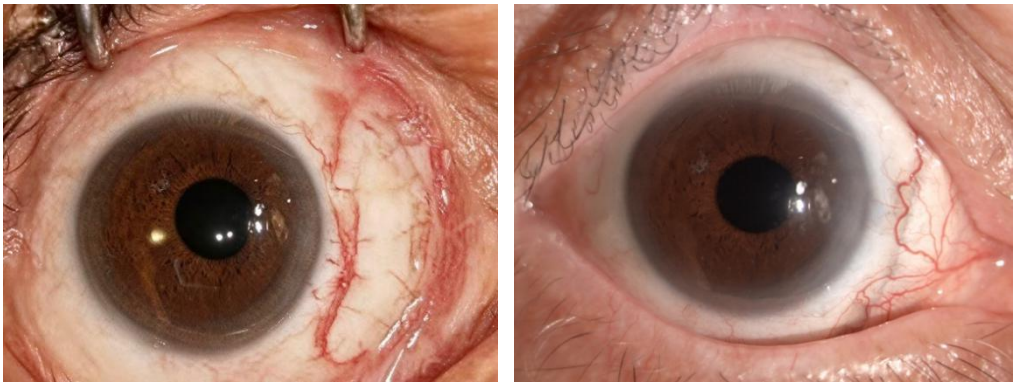

Fig. 4. The slit-lamp photographs show at two months (left) and nine months (right) after the combined scleral patching and conjunctival autografting

3 Discussion

This case illustrates a diagnostically challenging late scleral lesion arising at a previous bare-sclera pterygium excision site. The painless, chalky appearance favored calcification, whereas the associated thinning and choroidal show-through raised concern for ulcerative or necrotizing scleral disease. Histopathology was therefore important in establishing the diagnosis and guiding management [1–3].

3.1. The Pathogenic Triad: Bare Sclera, Phosphate Buffers, and Tear Calcium

The pathogenesis in this patient cannot be established definitively. Three factors may contribute: a chronically altered ocular surface after bare-sclera excision, the prolonged exposure to the phosphate-buffered eye drops, and the calcium present in the tear fluid.

Human tear fluid contains calcium (Ca^{2+}), with concentrations of approximately 2.60-7.60mg/dL (mean 4.4mg/dL, equivalent to1.1 mM) [9].

Calcium-phosphate precipitation is biologically plausible in the presence of sufficient phosphate and a favorable local physicochemical environment. However, tear-film ion concentrations and local phosphate levels were not measured in this patient. Therefore, the mechanisms described below should be regarded as hypotheses regarding the potential pathogenesis rather than causal processes demonstrated in this case.

3.1.1 The Anatomical "Tear Pond" and Evaporative Concentration: Bare-sclera excision (BSE) creates a concave, de-epithelialized scleral defect with disrupted vascular supply and impaired conjunctival re-epithelialization [4,5]. This anatomical contour acts as a stagnant "tear pond." Prolonged tear retention within this region, further exacerbated by concurrent meibomian gland dysfunction (MGD), promotes progressive solute concentration via evaporation.

3.1.2 Exogenous Phosphate Loading: The patient used three topical formulations—polyvinyl alcohol, prednisolone acetate, and olopatadine—for eight years. Phosphate-buffered ophthalmic preparations have been associated with ocular-surface calcium-phosphate deposition [7]. Nevertheless, the exact formulations, phosphate concentrations, dosing frequency, and cumulative exposure in this patient were not available for verification; therefore, a direct drug-induced mechanism cannot be concluded.

3.1.3 Collagen Nucleation and Matrix Binding:

If local calcium and phosphate concentrations exceeded the solubility threshold, precipitation on exposed or damaged scleral collagen could theoretically occur.. Furthermore, age-related reductions in negatively charged scleral proteoglycans may also influence mineral deposition [10-12].

Notably, while this mechanism shares a final common pathway with β-irradiation-induced calcification (where local hyperphosphatemia arises from radiation-induced tissue necrosis [5]), A potential drug-associated mechanism may develop over a prolonged period.

3.2. Clinical Mimicry and Differential Diagnosis

Both scleral calcification and active scleral ulceration can present as a whitish, thinned scleral lesion with dark-blue choroidal show-through. Nevertheless, critical clinical distinctions exist: calcification typically presents as a painless, granular, slow-growing plaque, whereas ulceration is characteristically painful, featuring punched-out margins, positive fluorescein pooling, and frequent associations with systemic autoimmune diseases.

In our patient, the absence of pain and the nodular, crystalline appearance served as diagnostic clues. However, because calcified plaques can induce secondary surface breakdown and focal fluorescein staining, the two conditions can clinically overlap, creating diagnostic uncertainty. Relying solely on slit-lamp biomicroscopy is therefore insufficient. Histopathological verification remains decisive; in this case, it prevented the inappropriate administration of systemic immunosuppressive therapy and guided the patient toward definitive surgical management. We recommend that any patient with a history of bare-sclera pterygium surgery, prolonged topical medication use, and a suspicious thinned scleral lesion undergo excisional biopsy for histopathological confirmation prior to initiating immunosuppressive regimens.

3.3. Surgical Reconstruction and Preventive Strategies

Following complete lesion resection, the residual bare choroid was exposed. Leaving such an extensive defect unmanaged carries a high risk of scleral ectasia or spontaneous globe rupture [13]. To achieve robust structural and biological restoration, we executed a two-layer reconstruction strategy combining a homologous donor scleral graft with an autologous conjunctival limbal graft. The homologous sclera provides a sturdy structural framework that promotes host fibroblast infiltration and restores scleral wall thickness. The overlying vascularized autologous conjunctival graft re-establishes an intact epithelial barrier, supplies crucial graft nutrition, protects against

immunological melting, and prevents recurrent calcification by restoring normal tear kinetics.

From a preventive perspective, primary pterygium surgery should strictly avoid leaving an exposed bare-sclera bed; conjunctival limbal autografting (CAG) remains the gold standard to ensure rapid epithelialization and ocular surface integrity [14]. Furthermore, ophthalmologists must exercise vigilance regarding the buffer composition of long-term topical ophthalmic formulations, preferentially prescribing phosphate-free or preservative-free medications to patients with persistent ocular surface defects.

This report has several limitations. It is a single retrospective case, the composition and phosphate concentration of the historical eye-drop formulations were not independently verified, exposure was based on patient history, local tear calcium/phosphate concentrations were not measured, and no calcium-specific histochemical stain or compositional analysis of the deposits was reported. Accordingly, the association between topical medication exposure and scleral calcification should be interpreted as hypothesis-generating rather than causal.

Declarations

Consent for publication:Written informed consent was obtained from the patient for publication of the clinical information and accompanying images.

Availability of data and materials:The clinical data supporting the findings of this case report are available from the corresponding author upon reasonable request, subject to patient confidentiality requirements.

Conflicts of Interest :None.

Funding: Supported by Major Science and Technology Special Project of the Shenzhen Municipal Science, Technology and Innovation Bureau (Grant No. KJZD20240903103305008) and Chengdu Municipal Medical Research Project (Grant No. 2025601)

Authors' contributions: SH: Writing- original draft, Investigation, Data curation. QF: Data curation. SZ: Data curation. YT: Data curation, YY:

Writing- review & editing, Methodology, XY: Methodology, Investigation, Writing- review & editing, funding acquisition.

Acknowledgements: None.

References

[1] Watson PG, Young RD. Scleral structure, organisation and disease. A review. Exp Eye Res. 2004;78(3):609-623.

[2] Gündüz AK, Tetik D. Diagnosis and Management Strategies in Sclerochoroidal Calcification: A Systematic Review. Clin Ophthalmol. 2023 Sep 11;17:2665-2686.

[3] Dunn JP, Seamone CD, Ostler HB, Nickel BL, Beallo A. Development of scleral ulceration and calcification after pterygium excision and mitomycin therapy. Am J Ophthalmol. 1991 Sep 15;112(3):343-4.

[4] Safianik B, Ben-Zion I, Garzozi HJ. Serious corneoscleral complications after pterygium excision with mitomycin C. Br J Ophthalmol. 2002 Mar;86(3):357-8.

[5] Höllhumer R. Dystrophic calcification of the sclera following pterygium surgery with adjunctive beta-irradiation: Case report of the surgical management. Afr Vision Eye Health. 2020;79(1):e1-e4.

[6] Rubinfeld RS, Pfister RR, Stein RM, et al. Serious complications of topical mitomycin-C after pterygium surgery. Ophthalmology. 1992;99(11):1647-1654.

[7] Bernauer W, Thiel MA, Kurrer M, et al. Corneal calcification following intensified treatment with sodium hyaluronate artificial tears. Br J Ophthalmol. 2006;90:285-288.

[8] Kivelä TT. (2019). Sclerochoroidal calcification. In: Rojanaporn, D. (eds) Ocular Oncology. Retina Atlas. Springer, Singapore. https://doi.org/10.1007/978-981-13-2336-2_17

[9] Caldeira JAF, Luthold WW, Sabbaga E. Tear calcium levels in normal subjects. Ophthalmologica. 2010,114-119.

[10] Rada JA, Achen VR, Penugonda S, et al. Proteoglycan composition in the human sclera during growth and aging. Invest Ophthalmol Vis Sci. 2000;41:1639–1648.

[11] Rantamäki AH, Seppänen-Laakso T, Oresic M, et al. Human tear fluid lipidome: from composition to function. PLoS One. 2011;6(5):e19543.

[12] Boote C, Dennis S, Newton RH, et al. Collagen fibrils appear more closely packed in the prepupillary cornea: optical and biomechanical implications. Invest Ophthalmol Vis Sci. 2003;44(7):2941-2948.

[13] Gozawa M, et al. Spontaneous eyeball rupture in an elderly patient with calcific scleral plaque. Case Rep Ophthalmol. 2020;11(2):412-417.

[14] Hirst LW. Recurrence and complications after 1,000 surgeries using pterygium extended removal followed by extended conjunctival transplant. Ophthalmology. 2012;119(11):2205-2210.