Research Square

Preprints are preliminary reports that have not undergone peer review.
They should not be considered conclusive, used to inform clinical practice,
or referenced by the media as validated information.

# Cutaneous histoplasmosis co-existing with tuberculosis in advanced HIV disease – a dermatological diagnostic challenge in resource-limited settings. A Case Report

**Medard Mlenda**

drmedardm@gmail.com

Muhimbili University of Health and Allied Sciences (MUHAS)

**Regina Charles**

Muhimbili University of Health and Allied Sciences (MUHAS)

**Eleneus Elias**

Muhimbili University of Health and Allied Sciences (MUHAS)

**Kwandu Nginilla**

Muhimbili University of Health and Allied Sciences (MUHAS)

**Elizabeth Swai**

Muhimbili University of Health and Allied Sciences (MUHAS)

**Violeth Willbard**

Muhimbili University of Health and Allied Sciences (MUHAS)

**Fabian Ntigga**

Muhimbili University of Health and Allied Sciences (MUHAS)

**Victor Njunwa**

Muhimbili University of Health and Allied Sciences (MUHAS)

**Dammy Shimbo[3]**

Muhimbili National Hospital

**Elizabeth Msangi[1]**

Muhimbili University of Health and Allied Sciences (MUHAS)

**Andrew Foi[1]**

Muhimbili National Hospital

**Eliaichiroma Minja[2]**

Muhimbili National Hospital

**Muhammad Bakari[1]**

Muhimbili University of Health and Allied Sciences (MUHAS)

**Case Report**

**Keywords:** Histoplasmosis, HIV/AIDS, Cutaneous tuberculosis, Opportunistic infection, Resource-limited settings, Sub-Saharan Africa

**Posted Date:** November 24th, 2026

**DOI:** https://doi.org/10.21203/rs.3.rs-11352161/v1

**License:** This work is licensed under a Creative Commons Attribution 4.0 International License. Read Full License

**Additional Declarations:** No competing interests reported.

## Abstract

# Background

Histoplasmosis is an AIDS-defining opportunistic infection caused by the dimorphic fungus *Histoplasma capsulatum*. Cutaneous involvement is uncommon, but may be the presenting or most conspicuous manifestation of disseminated disease, as non-specific papules, nodules, plaques, or ulcers that closely mimic other infectious and malignant conditions. In Tuberculosis-endemic settings, such lesions may be misattributed to cutaneous tuberculosis, which leads to delays in institution of definitive antifungal therapy.

# Case Presentation:

A 32-year-old woman with a 17-year history of HIV infection and recent antiretroviral non-adherence following a period of good adherence during pregnancy, presented with a history of seven months of fever; four months of progressive ulcerating skin lesions involving the perineum, upper limbs, nose and left ear; three months of odynophagia, and one month of symmetrical polyarthritis. She had been diagnosed with tuberculosis one month before presentation to the general clinic, based on a positive urine lateral-flow lipoarabinomannan (LF-LAM) assay and the cutaneous lesions. She was thus commenced on antituberculosis therapy. However, the cutaneous lesions progressed. Her $CD4^+$ T-lymphocyte count was below 200 cells/μL. An eventual skin biopsy showed circumscribed dermal necrosis with aggregates of round-to-oval yeast forms, each surrounded by a clear halo, within histiocytes, positive on periodic acid–Schiff staining, consistent with *Histoplasma capsulatum and* establishing a diagnosis of disseminated cutaneous histoplasmosis with institution of antifungal therapy and partial resolution of lesions.

# Discussion

This case illustrates the challenge of dermatological diagnosis of cutaneous lesions in the settings of TB endemicity and constrained diagnostic capabilities.

# Conclusion

Clinicians in tuberculosis-endemic, resource-limited settings should maintain a high index of suspicion for disseminated histoplasmosis in patients with advanced HIV disease having chronic, progressive, cutaneous lesions. A tissue biopsy should be undertaken early, rather than relying on clinical morphology.

## INTRODUCTION

Histoplasmosis is caused by the dimorphic fungus *Histoplasma capsulatum*, which exists in a mycelial form in the environment and converts to a yeast form at body temperature in mammals. Disseminated disease occurs almost exclusively in the setting of significant immunosuppression, most notably among people living with HIV who have CD4 counts below 200 cells/μL (1). Cutaneous involvement, although uncommon, may be the presenting or most prominent manifestation of disseminated disease and typically produces non-specific papules, nodules, plaques, or ulcers that closely mimic other infectious and malignant conditions (1, 2).

Progressive disseminated histoplasmosis occurs in approximately 1 in 2000 cases among immunocompetent adults, but affects 4–27% of infected children, older individuals and immunosuppressed persons (3). In tuberculosis-endemic regions, cutaneous lesions of disseminated histoplasmosis are frequently attributed to cutaneous tuberculosis, reflecting the considerable clinical overlap between the two conditions. This can delay recognition of histoplasmosis and initiation of appropriate antifungal therapy (3–5).

This case is presented to highlight the diagnostic challenge between cutaneous histoplasmosis and cutaneous tuberculosis in advanced HIV disease, and to underscore the essential role of histopathological confirmation in guiding management. This is of importance since treatment modalities for the two conditions are different.

# CASE PRESENTATION

A 32-year-old woman with a 17-year history of human immunodeficiency virus (HIV) infection presented at the skin clinic in Muhimbili National Hospital (MNH) in Dar es Salaam, Tanzania, with recurrent fever for 7 months, progressive skin lesions for 4 months, odynophagia for 3 months, and symmetrical polyarthritis for 1 month.

She was diagnosed with HIV infection during adolescence and initially received cotrimoxazole prophylaxis, when the baseline CD4 lymphocyte count was above 350 cells/μL. Antiretroviral therapy (ART) with tenofovir, lamivudine, and efavirenz was initiated four years later, in 2013, but adherence was poor because of HIV-related stigma. She was transitioned to tenofovir, lamivudine, and dolutegravir (TLD) in 2022 during pregnancy, with good adherence maintained throughout pregnancy. However, she discontinued therapy after delivery and was re-initiated on TLD four months before this presentation, when her most recent $CD4^+$ T-lymphocyte count was below 200 cells/μL, with HIV viral load of 114,739 copies/mL. One month before presentation, at a peripheral facility, she was diagnosed with tuberculosis based on a positive urine lateral-flow lipoarabinomannan (LF-LAM) assay and the presence of cutaneous lesions. She was therefore started on rifampicin, isoniazid, pyrazinamide, and ethambutol, to which she was adhering well.

Her presentation started with a low-grade fever. The fever was gradual in onset, intermittent, and predominantly occurred in the evening, with partial relief following paracetamol. It was associated with

chills, generalized weakness, and an unintentional 8 kg weight loss over 6 months. She subsequently developed multiple painful skin nodules, initially involving the genital area and then the upper limbs, nose, and left ear over subsequent weeks. The nodules progressively enlarged and ulcerated, with some discharging clear fluid, and did not improve with topical mupirocin.

She also developed progressively worsening odynophagia with both solid and liquid foods. The pain was burning in character, rated 6/10 in severity, exacerbated by hot meals, and associated with dysphagia; antacids provided no relief. There was no associated oral ulceration, heartburn, regurgitation, or choking.

She subsequently developed severe, continuous pain and swelling involving multiple joints, including the elbows, knees, wrists, and the small joints of the hands and feet symmetrically. The pain reached 8/10 in severity, worsened with movement, and was partially relieved by rest and paracetamol, resulting in difficulty using the affected limbs. There was no history of joint deformity, prolonged morning stiffness, or sensory symptoms.

She had undergone one caesarean section and had one living, HIV-negative child. There was no significant family history of hypertension, diabetes mellitus, or sudden cardiac death.

# Physical Examination

On examination, she was markedly cachexic and pale, with a weight of 40 kg and height of 1.63 m, giving a body mass index of 15.1 kg/m². She was afebrile, with a blood pressure of 118/65 mmHg, pulse rate of 76 beats/min, respiratory rate of 16 breaths/min, and oxygen saturation of 96% on room air. The random blood glucose was 5.9 mmol/L. Bilateral submandibular and submental lymphadenopathy was present, with four discrete lymph nodes, the largest measuring approximately 2 × 3 cm, that were firm, non-tender, and non-matted.

Dermatological examination revealed multiple papulonodular and ulcerative lesions involving the perineum, upper limbs, nose, and left ear. In the perineum, the lesions were multiple, well-defined oval ulcers measuring 0.5–2 cm, with erythematous to pink granulating bases. The margins were slightly raised and indurated, and had surrounding post-inflammatory hyperpigmentation. Figure 1A.

**Figure 1A**

Perineal region showing multiple well-defined oval ulcers with granulating bases and surrounding post-inflammatory hyperpigmentation.

As shown in Fig. 1B, on the left forearm, there was an approximately 4 cm oval ulcer with raised hyperpigmented margins and a granulating base, and a retained suture at the site of a previous biopsy. A 1.5 cm dome-shaped, hyperpigmented, crusted nodule was present over the left supraclavicular region.

The left ear showed multiple coalescing nodules and ulcerated plaques with yellow crusting and irregular margins, resulting in partial distortion of the auricular architecture. A crusted plaque involving the nasal

tip was associated with distortion of the nasal contour. Figure 1C-D.

Musculoskeletal examination demonstrated symmetrical swelling and tenderness of the metacarpophalangeal, interphalangeal and metatarsophalangeal joints, with pain on movement and functional limitation but no established joint deformities. The remainder of the systemic examination was unremarkable.

## DIFFERENTIAL DIAGNOSES

A number of differential diagnoses were considered in this case. Based on the presentation with chronic and progressive ulcerating cutaneous nodules in the setting of advanced HIV disease, and endemicity of tuberculosis, cutaneous tuberculosis was considered as a differential diagnosis. However, this was unlikely since the lesions had not improved despite one month of anti-TB therapy. Other differential diagnoses considered included Kaposi sarcoma, given the background of advanced HIV disease, but the lesions lacked the characteristic violaceous, non-ulcerating plaques typical of this condition, furthermore, there was no buccal cavity involvement, a common site for KS-associated lesions. Cutaneous cryptococcosis and cutaneous lymphoma were also considered, given their recognized propensity to produce diverse cutaneous manifestations in immunosuppressed patients.

## INVESTIGATIONS

A complete blood count revealed anaemia with a haemoglobin level of 7.5 g/dL, which was microcytic and hypochromic. Inflammatory markers were markedly elevated, with an erythrocyte sedimentation rate (ESR) of 140 $mm/hr^{-1}$ and C-reactive protein of 181.3 mg/L. Liver function tests and liver enzymes were within normal limits, as were renal function tests and serum electrolytes. Serological testing for hepatitis B surface antigen and hepatitis C antibodies were negative, and the Venereal Disease Research Laboratory (VDRL) test performed to exclude syphilis was non-reactive.

Chest radiography was normal. Pulmonary features consistent with histoplasmosis, including diffuse or patchy pulmonary infiltrates and hilar or mediastinal lymphadenopathy were absent.

Urine Histoplasma antigen testing, which could have demonstrated budding yeast forms within macrophages, was not available at the centre. Fungal culture is important for confirmation of the diagnosis, although it may take several weeks to yield a positive result.

Tissue diagnosis through a punch biopsy of a representative skin nodule was therefore pursued as the easily accessible and rapid means of confirmation, since histopathological examination offered same-week results, whereas fungal culture would have taken several weeks. The sections showed circumscribed necrotic foci within the dermis, with occasional histiocytes at the periphery. Low-power examination showed a dense, diffuse inflammatory infiltrate occupying the full thickness of the dermis (Fig. 2A), which at higher magnification was composed predominantly of histiocytes admixed with

lymphocytes and plasma cells (Fig. 2B). Haematoxylin and eosin staining demonstrated numerous rounded, yeast-like organisms within the cytoplasm of these histiocytes, each surrounded by a clear halo, morphologically consistent with *Histoplasma capsulatum* (Fig. 2C). Periodic Acid–Schiff staining confirmed that the yeast forms were PAS-positive, establishing the diagnosis of cutaneous histoplasmosis.

## TREATMENT

The patient was maintained on antituberculosis treatment for a total of six months for her concurrently diagnosed tuberculosis. She was started on itraconazole 200 mg orally three times daily for 3 days, followed by 200 mg twice daily for a planned duration of one year. She also continued her existing antiretroviral therapy, with an additional 50 mg dose of dolutegravir given 12 hours after the standard tenofovir/lamivudine/dolutegravir dose to offset the rifampicin-induced reduction in dolutegravir levels, with enhanced adherence counselling. Adequate hydration and nutrition were encouraged, and complications were managed as they arose.

## FOLLOW-UP AND OUTCOME

FOLLOW-UP AND OUTCOME
Follow-up was scheduled at 2 weeks after treatment initiation, and monthly thereafter. During the first follow-up encounter, the patient showed partial clinical improvement of the skin lesions after initiation of itraconazole therapy. However, she died at home, a week later. Although the immediate cause of death could not be established due to lack of further clinical information, it most likely was due to the advanced nature of the HIV disease, and the presence of multiple co-morbidities.

# Ethical Considerations

A written informed consent was obtained from the patient for the publication of this case report and accompanying clinical images.

## DISCUSSION

This case demonstrates a dermatological diagnostic challenge of cutaneous lesions in the setting of advanced HIV disease and limited diagnostic capabilities, as well as the complexity of managing HIV disease presenting with multiple comorbidities.

Histoplasmosis is caused by a dimorphic fungus that remains in a mycelial form at ambient temperatures and grows as yeast at body temperature in mammals. The risk of symptomatic and disseminated disease increases with severe immunosuppression, particularly at CD4 counts below 200 cells/μL (1). Although cutaneous involvement is uncommon, it may occur as a manifestation of disseminated histoplasmosis and can present with diverse, nonspecific lesions, including papules,

nodules, plaques, and ulcers (1, 2). Progressive disseminated histoplasmosis occurs in approximately 1 per 2000 cases among immunocompetent adults, but in 4–27% of infected children, older individuals, and immunosuppressed persons (3).

Our patient was a 32-year-old woman living with HIV and advanced immunosuppression (CD4 < 200 cells/μL) who presented with multiple progressive cutaneous lesions. The initial clinical diagnosis was cutaneous tuberculosis, based on a high prevalence of tuberculosis in the local setting. This diagnostic challenge has been described in other reports, particularly in tuberculosis-endemic regions where atypical cutaneous lesions are often initially attributed to tuberculosis (3–5).

Cutaneous histoplasmosis is an important diagnostic mimic and may resemble cutaneous tuberculosis, leishmaniasis, cryptococcosis, Kaposi sarcoma, and other infectious or malignant conditions (4, 5). The nonspecific morphology of the lesions makes clinical diagnosis alone unreliable. In our patient, the diagnosis was ultimately established by a punch biopsy of a representative skin lesion. This highlights the importance of obtaining tissue for histopathological and microbiological evaluation when cutaneous lesions in patients with advanced HIV lack a definitive clinical diagnosis (3).

This case emphasizes the need to maintain a broad differential diagnosis for multifocal cutaneous lesions in patients with advanced HIV, even in settings where tuberculosis is highly prevalent. Although cutaneous tuberculosis should remain an important consideration, histoplasmosis should also be considered, particularly in patients with advanced immunosuppression and progressive or atypical lesions, but especially so in those already receiving antituberculosis therapy whose cutaneous lesions fail to improve. Early tissue diagnosis is essential because treatment differs substantially: cutaneous tuberculosis requires antituberculosis therapy, whereas disseminated histoplasmosis requires systemic antifungal treatment, typically liposomal amphotericin B for severe disease followed by itraconazole (1, 2). Delayed recognition and treatment of disseminated histoplasmosis may result in significant morbidity and mortality, as illustrated in our patient, who died three weeks after starting appropriate antifungal therapy, although she had an initial partial clinical response.

# CONCLUSION

This case underscores the importance of considering cutaneous histoplasmosis an important, treatable mimic of cutaneous tuberculosis in patients with advanced HIV disease, and that a confirmed diagnosis of tuberculosis should not preclude further investigation of skin lesions that fail to respond as expected. Strengthening access to histopathological and microbiological diagnostics in tuberculosis-endemic, resource-limited settings is essential to reduce diagnostic delay and improve outcomes in advanced HIV disease.

# Declarations

**Ethics approval and consent to participate**

Ethical approval was not required for this single case report. Written informed consent was obtained from the patient (see Consent for publication).

**Consent for publication**

Written informed consent was obtained from the patient for the publication of this case report and accompanying clinical images.

**Availability of data and materials**

All data generated or analysed during this study are included in this published article.

**Competing interests**

The authors declare that they have no competing interests.

**Funding**

This case report did not receive any specific funding.

**Authors' contributions**

MM drafted the manuscript and is the corresponding author. DS performed the histopathological examination. EM performed the dermatological assessment. All authors were involved in the clinical care of the patient and/or the preparation of the manuscript, critically revised the manuscript, and read and approved the final manuscript.

**Acknowledgements**

Not applicable.

**Authors' information (optional)**

Not applicable.

# References

1. WHO guidelines on the management of advanced HIV disease. World Health Organization; 2025.
2. Panel on Opportunistic Infections in Adults and Adolescents with HIV. Guidelines for the Prevention and Treatment of Opportunistic Infections in Adults and Adolescents With HIV: Histoplasmosis.
3. Sood A, Raman DK, Sinha A, Vasudevan B. Cutaneous manifestations leading to a diagnosis of a case of severe disseminated histoplasmosis in a human immunodeficiency virus-positive child. Indian J Sex Transm Dis AIDS. 2022;43(2):185–8. doi: 10.4103/ijstd.ijstd_59_22

4. Oladele RO, Ayanlowo OO, Richardson MD, Denning DW. Histoplasmosis in Africa: An emerging or a neglected disease? PLoS Negl Trop Dis. 2018. doi: 10.1371/journal.pntd.0006046
5. Couppé P, Herceg K, Bourne-Watrin M, Thomas V, Blanchet D, Alsibai KD, et al. The broad clinical spectrum of disseminated histoplasmosis in HIV-infected patients: A 30 years' experience in French Guiana. J Fungi. 2019. doi:10.3390/jof5040115

# Figures



**Figure 1**

**Figure 1A:** Perineal region showing multiple well-defined oval ulcers with granulating bases and surrounding post-inflammatory hyperpigmentation.



**Figure 2**

**Figure 1B:** Left forearm ulcer with raised hyperpigmented margins, a granulating base, and a retained suture from a prior biopsy site.

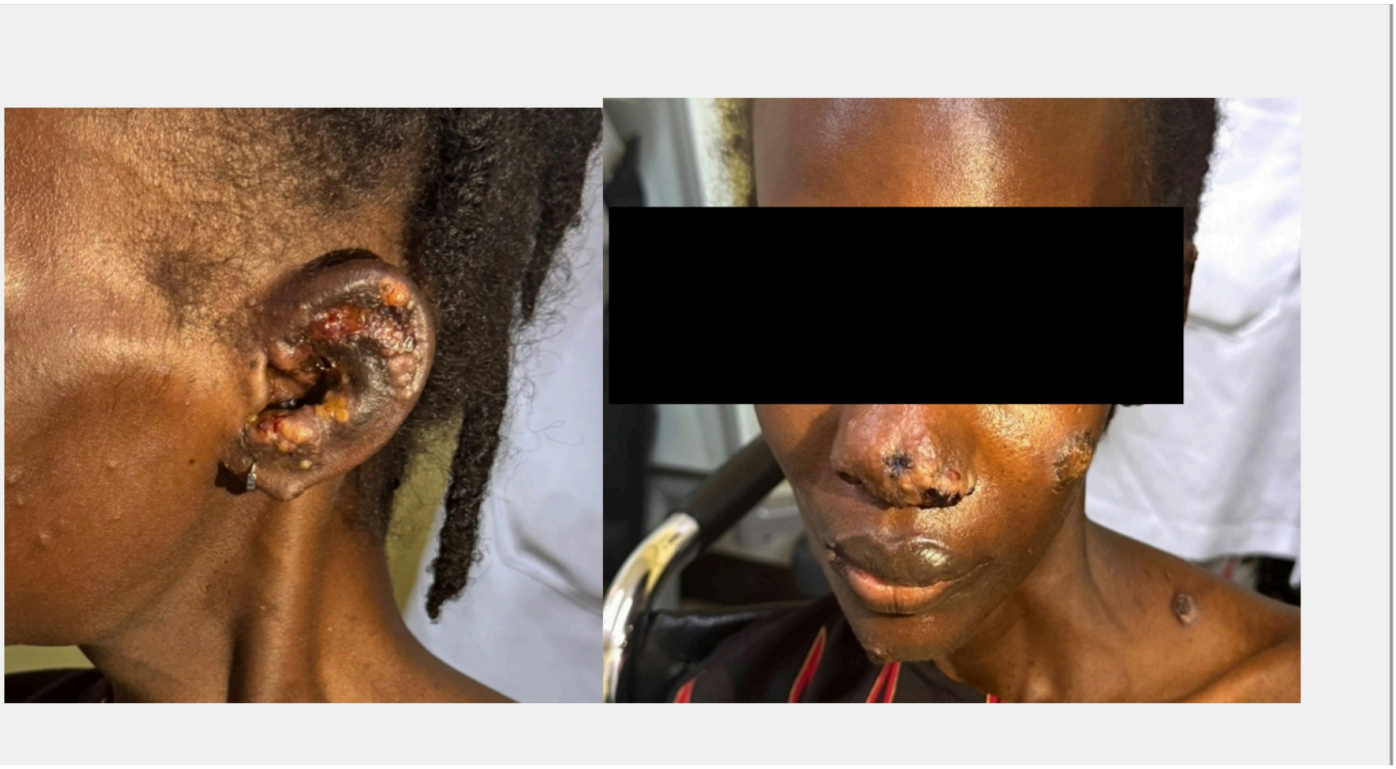

**Figure 3**

**Figure 1C–D:** (C) Left ear showing coalescing nodules and ulcerated plaques with yellow crusting and distortion of the auricular architecture. (D) Nasal tip crusted plaque with associated contour distortion.

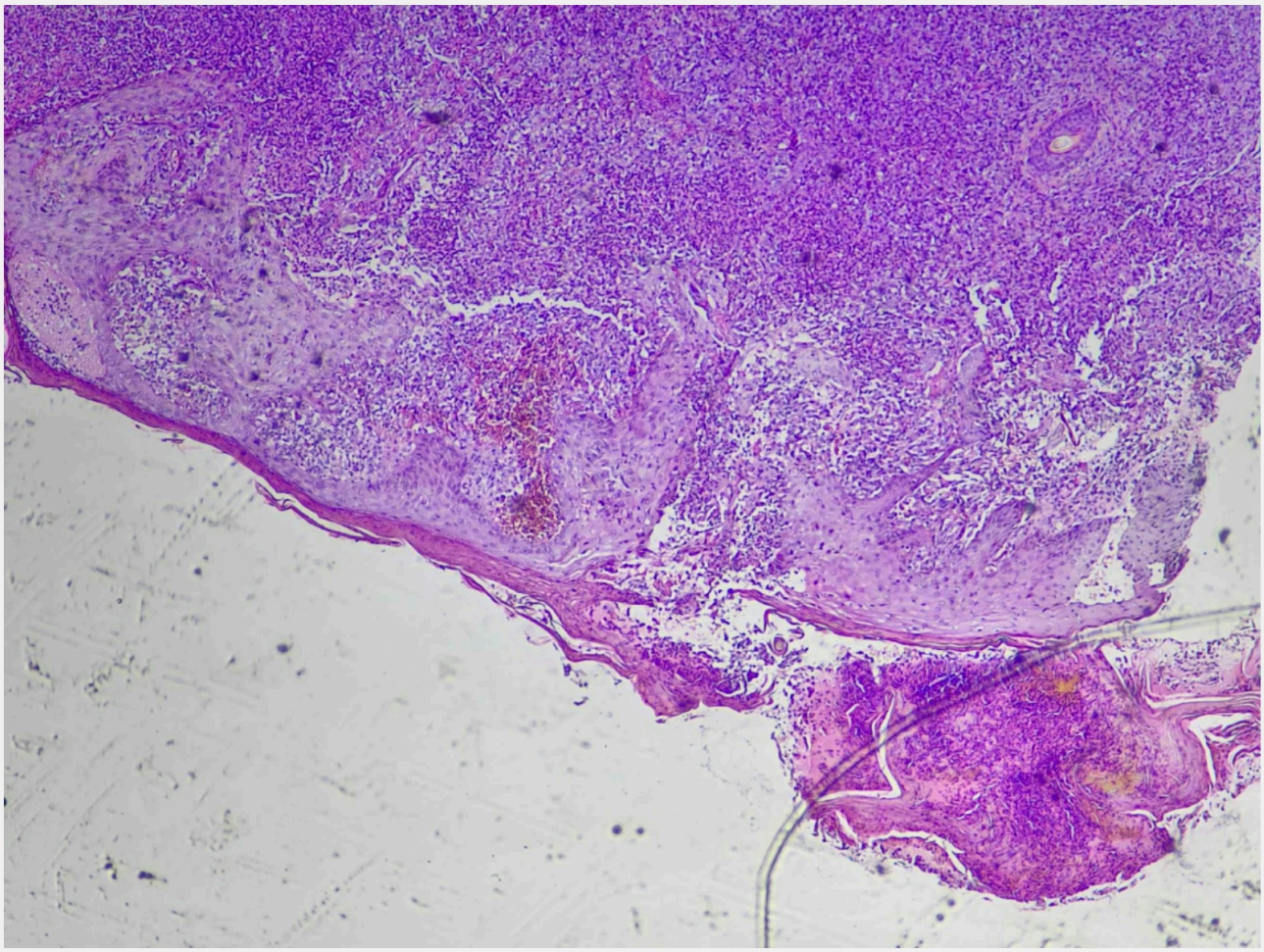

**Figure 4**

**Figure 2A.** Low-power view of the skin biopsy showing a focally attenuated epidermis overlying a dense, diffuse inflammatory infiltrate that fills the papillary and reticular dermis.

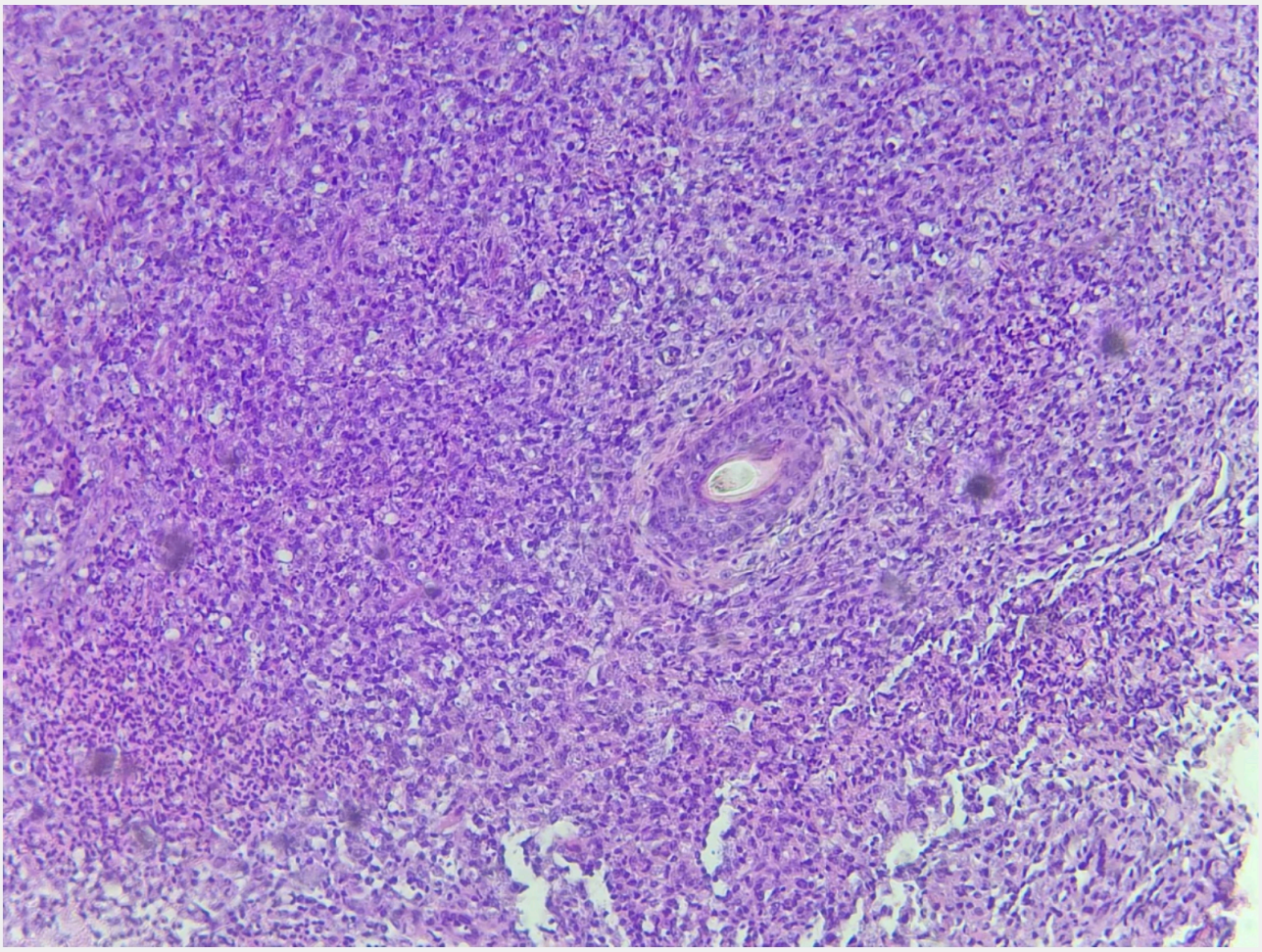

**Figure 5**

**Figure 2B.** Intermediate-power view showing the dermal infiltrate composed predominantly of sheets of histiocytes admixed with lymphocytes and plasma cells, surrounding and effacing adnexal structures, with ill-defined foci of necrosis.

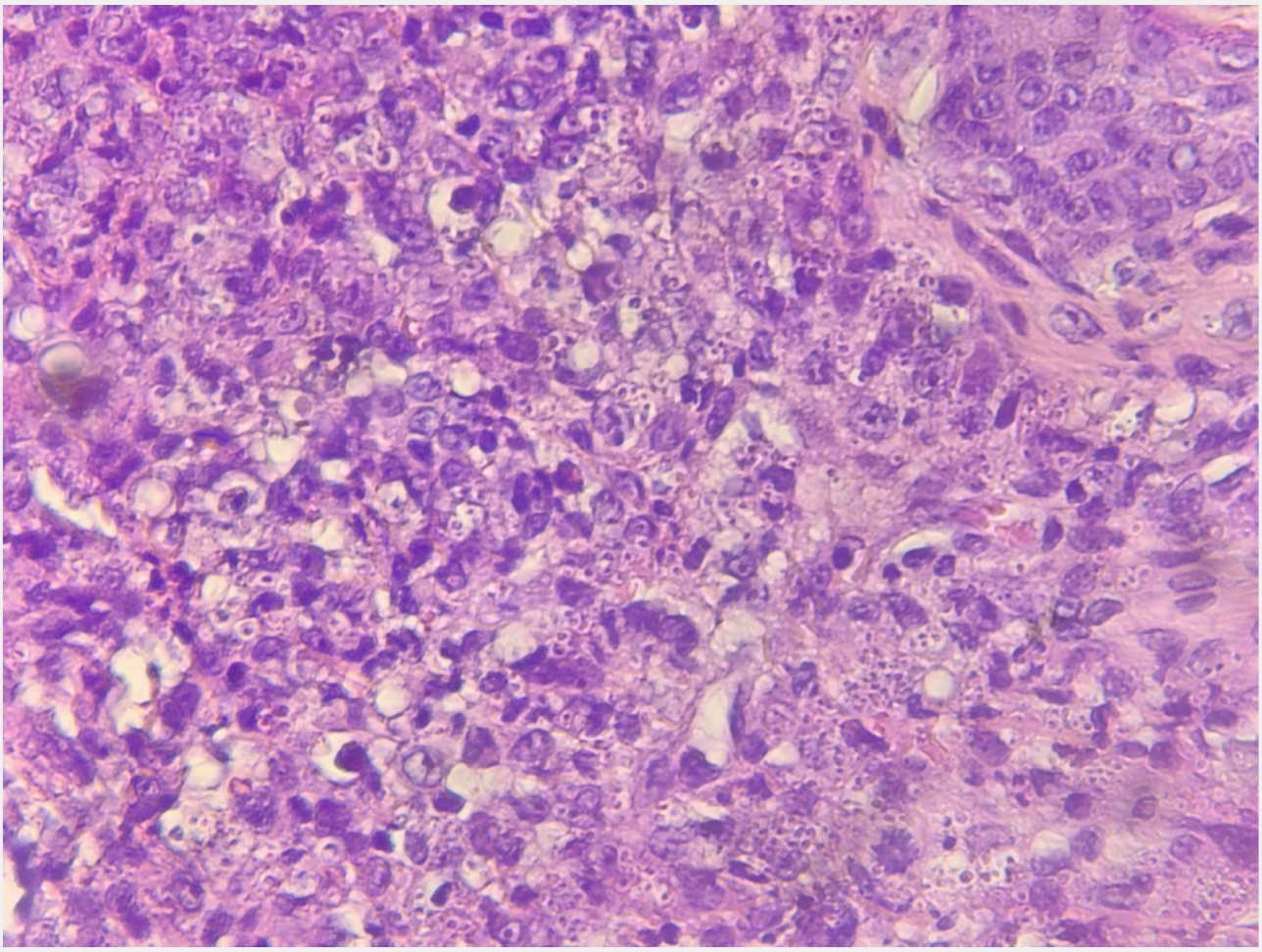

**Figure 6**

**Figure 2C.** High-power view showing numerous small, round-to-oval yeast-like organisms within the cytoplasm of histiocytes, each surrounded by a characteristic clear halo, morphologically consistent with *Histoplasma capsulatum*.

## Supplementary Files

This is a list of supplementary files associated with this preprint. Click to download.

- CutaneoushistoplasmosisCAREChecklist.docx