Research Square

Preprints are preliminary reports that have not undergone peer review.
They should not be considered conclusive, used to inform clinical practice,
or referenced by the media as validated information.

Long-Term Outcomes and Postoperative Management After Endoscopic Resection of Non-Ampullary Duodenal Lesions: A Retrospective Single-Center Cohort Study

Xue Jia
Peking University Cancer Hospital (Inner Mongolia Campus) & Affffliated Cancer Hospital of Inner Mongolia Medical University

Xiaoyan Qi
Peking University Cancer Hospital (Inner Mongolia Campus) & Affffliated Cancer Hospital of Inner Mongolia Medical University

Bowen Ha
Peking University Cancer Hospital (Inner Mongolia Campus) & Affffliated Cancer Hospital of Inner Mongolia Medical University

Zhiguang Hu
Peking University Cancer Hospital (Inner Mongolia Campus) & Affffliated Cancer Hospital of Inner Mongolia Medical University

Guanlan Liu
Peking University Cancer Hospital (Inner Mongolia Campus) & Affffliated Cancer Hospital of Inner Mongolia Medical University

Xiaozhi Hu
Peking University Cancer Hospital (Inner Mongolia Campus) & Affffliated Cancer Hospital of Inner Mongolia Medical University

Hai qing Hu
huhaiqingnm@163.com

Peking University Cancer Hospital (Inner Mongolia Campus) & Affffliated Cancer Hospital of Inner Mongolia Medical University

---

Research Article

Keywords:

Posted Date: November 22nd, 2026

DOI: https://doi.org/10.21203/rs.3.rs-11324592/v1

License: This work is licensed under a Creative Commons Attribution 4.0 International License.
Read Full License

Additional Declarations: No competing interests reported.

Abstract

Objective: To describe the procedural and long-term outcomes of endoscopic resection for non-ampullary duodenal lesions (NADLs) and explore postoperative management strategies.

Methods: This retrospective, single-center cohort study reviewed 36 consecutive patients with 41 NADLs who underwent endoscopic mucosal resection (EMR), endoscopic submucosal dissection (ESD), or endoscopic full-thickness resection (EFTR) between January 2022 and April 2025. Clinical, procedural, pathological, and follow-up data were obtained from institutional records and analyzed retrospectively.

Results: Among 41 lesions, 11 (27%) were treated with EMR, 24 (59%) with ESD, and 6 (15%) with EFTR. En bloc resection was achieved in 95% of lesions, and the R0 resection rate was 93%. One patient (2.4%) developed delayed perforation after ESD, which resolved with conservative management and endoscopic drainage. Following the implementation of a three-lumen feeding tube combined with an irrigation protocol in subsequent patients, no further delayed perforations were observed. All patients remained free of delayed bleeding, surgical rescue interventions, or perioperative death. During a median follow-up of 43 months (range 12–51), 34 patients completing long-term follow-up showed no local recurrence.

Conclusion: Endoscopic resection was feasible and achieved favorable observed resection and long-term outcomes in selected patients with NADLs. Triple-lumen tube-assisted irrigation and decompression may be a feasible adjunct to postoperative management, but its effect on delayed adverse events requires evaluation in larger controlled studies. Given the technical complexity, procedures should be performed by experienced endoscopists with careful selection of appropriate candidates.

Introduction

Non-ampullary duodenal lesions (NADLs) are rare and pathologically heterogeneous lesions of the duodenum. With the widespread adoption of advanced endoscopic techniques, the detection rate of NADLs has steadily increased [1]. Compared with conventional surgical resection, endoscopic approaches offer the advantages of minimal invasiveness, shorter recovery times, and organ preservation. However, several anatomical and technical challenges limit their widespread application: the duodenum’s deep retroperitoneal location, narrow lumen, proximity to major vessels and adjacent organs, thin wall, and rich vascularization restrict endoscopic maneuverability and contribute to higher rates of perioperative complications [2, 3].

Endoscopic mucosal resection (EMR) and endoscopic submucosal dissection (ESD) have emerged as widely adopted minimally invasive methods for resecting duodenal lesions [2, 4]. More recently, endoscopic full-thickness resection (EFTR) has been increasingly explored, enabling en bloc removal of lesions involving the entire duodenal wall, facilitating histological assessment, and potentially achieving curative outcomes [2, 5]. Despite these advances, data on the safety, efficacy, and long-term outcomes of endoscopic resection for NADLs remain limited.

In this retrospective cohort study, we aimed to describe the clinical and long-term outcomes of endoscopic resection for NADLs and to summarize our preliminary experience with an adjunctive lavage-based postoperative management strategy.

Materials and Methods

1.1 Study Population

This retrospective, single-center cohort study reviewed consecutive patients who underwent endoscopic resection of NADLs at the Endoscopy Center of the Inner Mongolia Hospital, Peking University Cancer Hospital (Inner Mongolia Medical University Affiliated Cancer Hospital) between January 2022 and April 2025. This study was reviewed and approved by the Ethics Committee of the Affiliated Tumor Hospital of Inner Mongolia Medical University (Approval Nos. YL202002 and YL202013).

Eligibility criteria applied during retrospective record review were as follows: (1) age ≥ 18 years and able to tolerate endoscopic procedures under general anesthesia with endotracheal intubation; (2) endoscopically confirmed NADLs; (3) preoperative imaging, including abdominal CT, showing no evidence of distant metastasis; (4) preoperative endoscopic ultrasound assessment of lesion depth; and (5) provision of written informed consent.

Patients were excluded if they met any of the following criteria: (1) lesions representing advanced or secondary malignancy; (2) significant coagulopathy or ongoing anticoagulant/antiplatelet therapy that could not be discontinued; (3) severe cardiopulmonary comorbidities or other systemic conditions precluding safe endoscopic intervention; and (4) refusal to provide informed consent.

1.2 Endoscopic Procedures

All procedures were performed using a gastroscope (GIF-H260 or GIF-H290, Olympus, Japan) with the patient in the left lateral position under general anesthesia with endotracheal intubation by Professor Haiqing Hu, an experienced endoscopist.

1.2.1 Endoscopic Mucosal Resection (EMR)

Lesion margins were marked 5 mm beyond the lesion perimeter using the tip of the Dual Knife (KD-650L, Olympus, Japan). A mixture of methylene blue and epinephrine was injected into the submucosa at multiple sites using an endoscopic injection needle (VDK-IN-23-230-2504-A, Jiangsu VDK Medical Technology Co., China) to achieve adequate lesion lifting. Suitable snares (MTN-PFS-E-24/23, Micro-Tech Medical, Nanjing, China) were then used to capture the elevated lesion and perform electrocautery resection. Larger lesions were resected piecemeal.

1.2.2 Hot Snare Polypectomy

For lesions with thick pedicles or rich vascularity, the lesion base was pre-ligated using metallic clips (ROCC-D-2-195, Micro-Tech Medical, Nanjing, China) or a combination of clips with nylon loops (2300 mm × 2.6 mm × 30 mm, Olympus, Japan) to prevent bleeding. A snare of appropriate size was positioned from the distal side of the lesion and gradually tightened toward the base. Electrocautery resection was then performed while carefully controlling the cutting speed to avoid bleeding or perforation. In this study, hot snare polypectomy was included in the EMR group.

1.2.3 Endoscopic Submucosal Dissection (ESD)

Marking and submucosal injection were performed as in EMR. Mucosal pre-incision was made around the marked perimeter, followed by stepwise submucosal dissection under direct visualization using an IT Knife (KD-612U, Olympus, Japan) or Dual Knife. A transparent cap was used to optimize visualization, and repeated submucosal injections were applied to maintain adequate lifting. Electrocautery was used for hemostasis as needed, and the endoscope position was adjusted to ensure safe and complete dissection(Fig. 1).

If submucosal dissection could not be safely completed or en bloc resection required, conversion to endoscopic full-thickness resection (EFTR) was performed at the discretion of the endoscopist based on intraoperative findings. Cases converted from ESD to EFTR were analyzed in the EFTR group.

Modified ESD Technique: After circumferential mucosal incision with the Dual Knife, additional submucosal injections were performed to fully lift the lesion. The lesion was then completely captured with a snare, and electrocautery was applied to achieve full resection.

1.2.4 Endoscopic Full-Thickness Resection (EFTR)

Marking and submucosal injection were performed as described for EMR. Mucosal pre-incision was made along the marked perimeter. Full-thickness resection was achieved by stepwise dissection of the submucosa and muscularis propria using an IT Knife or Dual Knife under direct visualization, extending to the serosal layer to completely remove the lesion. Electrocautery was applied as needed for hemostasis. In cases of intraoperative pneumoperitoneum, increased abdominal tension, or elevated airway pressure, percutaneous decompression was performed at a safe site approximately two fingerbreadths below the right costal margin(Fig. 2).

1.2.5 Defect Management

Depending on the clinical circumstances, exposed vessels in the resection defect were coagulated using argon plasma coagulation (APC300, ERBE, Germany) or hot biopsy forceps (HBF-23/2000, Micro-Tech Medical, Nanjing, China). The defect was then closed with metallic clips or a combination of metallic clips and a nylon loop. Under direct endoscopic visualization, a nasogastric decompression tube (PUR-CH14, Beijing Maikang Medical Devices Co., China) combined with a jejunal feeding tube (PUR-CH10, Beijing Maikang Medical Devices Co., China), or triple-lumen feeding tube (CH16/9, Fresenius Kabi,

Germany) was placed.. Tube positioning was confirmed by abdominal radiography and a contrast study on postoperative day 1.

1.2.6 Postoperative Care and Follow-Up

Patients were maintained in a supine or semi-recumbent position postoperatively. Postoperative care included gastrointestinal decompression and jejunal nutritional support using either tube configuration. Following a case of delayed perforation, experience gained during its treatment led to the introduction of local defect irrigation into subsequent postoperative care. Under this protocol, 30 mL of normal saline was administered every 30 minutes through the nasogastric decompression tube or the gastric channel of the triple-lumen feeding tube, with intervals extended to 1 hour at night as appropriate. The irrigation side ports were positioned adjacent to the resection defect to facilitate lavage and drainage (Fig. 3).

Enteral nutrition was initiated through the separate jejunal feeding tube or the feeding lumen of the triple-lumen system according to the patient's clinical condition and confirmation of appropriate tube positioning. The day of surgery was defined as postoperative day 0. The actual day of enteral nutrition initiation and tube-related adverse events, including nasal mucosal pressure injury, were obtained from the medical records. All patients received acid suppression therapy, prophylactic antibiotics, and fluid support. Vital signs were closely monitored for delayed bleeding, perforation, or intra-abdominal infection.

For large or deep defects, or lesions located near the major duodenal papilla, endoscopic reassessment was performed on postoperative day 5, and feeding tubes were removed once healing was confirmed. After discharge, patients were prescribed proton pump inhibitors and gastric mucosal protectants for at least 1 month. Surveillance endoscopy was performed at 3, 6, and 12 months postoperatively, then annually based on mucosal healing and pathological results. Additional abdominal CT scans were performed if clinically indicated. Follow-up data were collected through April 30, 2026. Follow-up duration was calculated from the date of endoscopic resection to the last surveillance endoscopy or documented clinical contact.

1.3 Statistical Analysis

All statistical analyses were performed using SPSS version 26.0 (IBM, Armonk, NY, USA). Continuous variables with a normal distribution are presented as mean ± standard deviation (SD), while non-normally distributed continuous variables are expressed as median (range). Categorical variables are reported as counts and percentages. Comparisons of continuous variables between two groups were conducted using the Mann–Whitney U test, and multi-group comparisons were performed using the Kruskal–Wallis test. Categorical variables were compared using Pearson's chi-square test, with Fisher's exact test applied when expected counts were less than 5. All statistical tests were two-sided, and a P-value < 0.05 was considered statistically significant.

Results

2.1 Patient Characteristics

The retrospective review identified 36 consecutive patients with 41 non-ampullary duodenal lesions (NADLs). The cohort comprised 17 males and 19 females, with a mean age of 58.18 ± 10.92 years. Lesion distribution was as follows: duodenal bulb, 13 lesions (32%); descending portion, 26 lesions (63%); horizontal portion, 1 lesion (2%); bulb-descending junction, 1 lesion (2%). According to the Paris classification, 16 lesions (39%) were type 0-I, 22 lesions (54%) were type 0-IIa, and 3 lesions (7%) were type 0-IIa + IIc (Table 1).

Table 1
Patient characteristics.

Variable	n
Patients	
Number	36
Age, mean ± SD, years	58.18 ± 10.92
Sex, n (%)	
Male	17(47)
Female	19(53)
Familial adenomatous polyposis, n (%)	0(0)
Lesions	
Number	41
Location in duodenum, n (%)	
First part	13(32)
Second part	26(63)
Third part	1(2)
First-Second part junction	1(2)
Macroscopic type (Paris classification), n (%)	
0-Ip	2(5)
0-Is	8(20)
0-Isp	6(15)
0-IIa	22(54)
0-IIa + IIc	3(7)
Layer, n (%)	
Mucosa	14(34)
Submucosa	23(56)
Muscularis propria	4(10)

2.2 Endoscopic Treatment and Adverse events

All procedures were successfully completed. Endoscopic treatment included 11 lesions treated with EMR, 24 with ESD, and 6 with EFTR. En bloc resection was achieved in 39 lesions (95%), while 2 lesions

(5%) were resected piecemeal; one lesion (2%) required more than three pieces for complete removal. Post-resection hemostasis with hot biopsy or argon plasma coagulation (APC) was applied in 27 lesions (66%) to reduce the risk of delayed bleeding and residual tumor. All 41 defects (100%) were successfully closed (Fig. 4, Table 2). Closure was attempted in all cases; the technical success rate of complete closure was 100%.

Table 2
Endoscopic treatment methods and resection outcomes in 41 lesions

Variable	n (%)
Treatment methods	
EMR	11(27)[a]
ESD	24(59)[b]
EFTR	6(15)[c]
Procedural techniques	
Clip-assisted snare traction	21(51)
Post-procedural management[d]	
Nasogastric tube / Jejunal feeding tube	26(72)
Triple-lumen feeding tube	10(28)
Resection outcomes	
En bloc	39(95)
Piecemeal	2(5)
Number of piecemeal specimen fragments	
2	1(50)
≥ 3	1(50)
Discontinuation of treatment	**0(0)**
Additional coagulation	27(66)[e]
Prophylactic clipping	34(83)[f]
Purse-string suture	7(17)[g]
Complication	
Delayed perforation	
First part	0/13(0)
Second part	1/26(4)
Third part	0/1(0)
First-Second part junction	0/1(0)
Delayed bleeding	0(0)

Variable	n (%)
Additional surgery	**0(0)**

EMR, endoscopic mucosal resection;ESD, endoscopic submucosal dissection；EFTR, endoscopic full-thickness resection.

[a] Including 3 cases of hot snare polypectomy.

[b] Including 5 cases of snaring with circumferential incision (modified ESD).

[c] Including 2 cases converted intraoperatively from ESD to EFTR.

[d] Post-procedural management data are reported as patient numbers; percentages are based on the total number of patients.

[e] including 10 hot biopsies and 17 argon plasma coagulation.

[f] Prophylactic clipping includes 2 lesions treated with snaring after pedicle pre-ligation with metallic clips, and 1 lesion treated with snaring after pedicle pre-ligation using metallic clips combined with a nylon loop.

[g] Purse-string suture includes 7 lesions closed with the clip-and-loop method.

One patient developed delayed perforation following ESD. The lesion was located on the papillary side of the descending duodenum, measuring approximately 2.5 × 2.0 cm, Paris classification type IIa. Endoscopic ultrasound prior to the procedure suggested the lesion was confined to the mucosal layer. ESD was performed on July 10, 2024, with the defect closed using metallic clips and placement of a nasogastric tube and jejunal feeding tube under endoscopic guidance. The nasogastric and jejunal tubes were removed on postoperative days 6 and 9, respectively. On postoperative day 11, delayed perforation occurred. The patient was managed with fasting, gastrointestinal decompression, antibiotics, acid suppression, somatostatin, and nutritional support, and underwent endoscopic-guided placement of a peritoneal drainage tube and jejunal feeding tube with metallic clip reinforcement of the defect. Irrigation was performed hourly with 1000 mL normal saline containing 160,000 U gentamicin (160 U/mL) via the gastrointestinal and peritoneal drainage tubes. The patient gradually improved and transitioned to enteral nutrition via the feeding tube. Follow-up endoscopy on October 17, 2024, showed good defect healing with surrounding nodular hyperplasia. The drainage tube was removed, and the patient was discharged in good condition.

No other serious procedure-related adverse events occurred.

2.3 Histopathological Results

The median tumor size determined by histopathology was 15 mm (range, 5–60 mm). The pathological diagnoses were as follows: 1 inflammatory hyperplastic polyp, 12 adenomas/low-grade intraepithelial neoplasia (LGIN), 6 intramucosal adenocarcinomas/high-grade intraepithelial neoplasia (HGI), 6

neuroendocrine tumors (NET, G1), 2 leiomyomas, 3 gastrointestinal stromal tumors (GIST, G1), 1 hamartoma, 1 Brunner’s gland adenoma, 6 lipomas, 1 heterotopic pancreas, and 2 Composite Gangliocytoma/Neuroma and Neuroendocrine Tumor(CoGNET) (Table 3).

Table 3
Histopathological results

Clinicopathological characteristics	**n**
Lesion size, median (range), mm	15(5–60)
Histological diagnosis, n (%)	
Inflammatory Hyperplastic Polyp	1(2)
Adenoma/ LGIN	12(29)
Intramucosal adenocarcinoma /HGIN	6(15)
NET(G1)	6(15)
Leiomyom	2(5)
Gastrointestinal stromal tumo(G1)	3(7)
Hamartoma	1(2)
Brunner’s gland adenoma	1(2)
Lipoma	6(15)
Heterotopic pancreas	1(2)
CoGNET	2(5)
Ductal involvements n (%)	
Negative(-)	41(100)
Positive(+)	0(0)
Horizontal margin n (%)	
Negative	39(95)[a]
Positive	1(2)
Inconclusive	1(2)
Vertical margin n (%)	
Negative	40(98)
Positive	1(2)
Inconclusive	0(0)
LGIN, low grade intraepithelial neoplasia.; HGIN, high grade intraepithelial neoplasia.	
[a] Including 2 with negative horizontal margin histopathologically with piecemeal resection.	

Horizontal margins were negative in 39 lesions (95%), positive in 1 lesion (2%), and inconclusive in 1 lesion (2%). Vertical margins were negative in 40 lesions (98%) and positive in 1 lesion (2%). No lymphatic or venous invasion was observed in any of the lesions.

2.4 Lesion Characteristics and Treatment Outcomes by Endoscopic Method

Lesions treated with EMR, ESD, and EFTR were mainly located in the descending duodenum (73%, 58%, and 67%, respectively). Resection depth differed significantly ($P < 0.05$): EMR was used for mucosal lesions (82%), ESD for submucosal lesions (79%), and EFTR for muscularis propria lesions (67%). En bloc resection rates were 91%, 96%, and 100%, and R0 resection rates were 100%, 88%, and 100% for EMR, ESD, and EFTR, respectively. For lesions ≥ 20 mm, en bloc resection rates were 75%, 91%, and 100%. One delayed perforation occurred in the ESD group (4%), with no delayed bleeding in any group. Histopathology showed EMR-treated lesions were mainly adenomas/low-grade intraepithelial neoplasia (45%). In the ESD group, adenomas/low-grade intraepithelial neoplasia accounted for 25%, while neuroendocrine tumors (G1) and intramucosal adenocarcinoma/high-grade intraepithelial neoplasia each accounted for 21%, and EFTR-treated lesions were primarily gastrointestinal stromal tumors (G1, 33%) (Table 4).

Table 4
Lesion characteristics and outcomes by resection method

Variable	EMR (n = 11)	ESD (n = 24)	EFTR (n = 6)	H/χ^2	*P*
Tumor size, median (range), mm[a]	10(6–60)	16(5–40)	18(15–35)	1.3	0.52
Location, n (%)[b]				1.51	0.96
First part	3(27)	8(33)	2(33)		
Second part	8(73)	14(58)	4(67)		
Third part	0(0)	1(5)	0(0)		
First-Second part junction	0(0)	1(5)	0(0)		
Layer, n (%)[b]				39.60	<0.05
Mucosa	9(82)	5(21)	0(0)		
Submucosa	2(18)	19(79)	2(33)		
Muscularis propria	0(0)	0(0)	4(67)		
Complications, n (%)[c]				-	0.58
Delayed perforation	0(0)	1(4)	0(0)		
Delayed bleeding	0(0)	0(0)	0(0)		
Results of resection, n (%)[c]					
En bloc	10(91)	23(96)	6(100)	-	0.62
< 20mm	7(64)	13(54)	3 (50)		
≥ 20mm	4(36)	11(46)	3(50)		
R0	11(100)	21(88)	6(100)	-	0.18
Histological diagnosis, n (%)[c]				-	0.20
Inflammatory Hyperplastic Polyp	1(9)	0(0)	0(0)		

R0: Curative resection with negative margins confirmed by histopathology, i.e., no residual tumor cells at the resection margin under microscopic examination.

[a] Kruskal–Wallis test

[b] Chi-square test

[c] Fisher's exact test

Variable	EMR (n = 11)	ESD (n = 24)	EFTR (n = 6)	H/χ^2	P
Adenoma/ LGIN	5(45)	6(25)	1(17)		
Intramucosal adenocarcinoma /HGIN	1(9)	5(21)	0(0)		
NET(G1)	0(0)	5(21)	1(17)		
Leiomyoma	0(0)	2(8)	0(0)		
Gastrointestinal stromal tumor(G1)	0(0)	1(4)	2(33)		
Hamartoma	0(0)	0(0)	1(17)		
Brunner's gland adenoma	0(0)	1(4)	0(0)		
Lipoma	3(27)	2(8)	1(17)		
Heterotopic pancreas	0(0)	1(4)	0(0)		
CoGNET	1(9)	1(4)	0(0)		
R0: Curative resection with negative margins confirmed by histopathology, i.e., no residual tumor cells at the resection margin under microscopic examination.					
[a] Kruskal–Wallis test					
[b] Chi-square test					
[c] Fisher's exact test					

2.5 Postoperative Management Strategies

Postoperative management included a nasogastric decompression tube combined with a jejunal feeding tube in 26 patients and a triple-lumen feeding tube in 10 patients. The triple-lumen system was introduced later in the study period. Experience gained from managing one case of delayed perforation led to the subsequent introduction of local defect irrigation. Irrigation could be performed through either the nasogastric tube or the gastric channel of the triple-lumen system, with the side ports positioned adjacent to the resection defect. Irrigation use therefore depended on the postoperative protocol in place at the time, rather than tube configuration alone.

Age, sex, and lesion size did not differ significantly between the two groups (all $P > 0.05$), whereas lesion location and layer distribution differed ($P < 0.05$). One delayed perforation occurred in the double-tube group (1/26, 3.8%); no delayed bleeding occurred in either group. The median time to initiation of enteral nutrition was 3 days (range, 2–5) in the double-tube group and 2 days (range, 2–3) in the triple-lumen group ($P > 0.05$). Nasal mucosal pressure injury occurred in 19 patients (73.1%) in the double-tube group

and 3 patients (30.0%) in the triple-lumen group ($P < 0.05$) (Table 5). Given the nonrandomized selection of tube configuration and changes in postoperative care over time, these findings do not establish whether irrigation or either tube configuration reduced delayed adverse events.

Table 5
Comparison of Postoperative Management Strategies

Variable	Double-tube group[a]	Triple-lumen tube group[b]	U/χ^2	*P*
Patients				
Number	26	10		
Age, mean ± SD, years[c]	57.52 ± 12.49	59.89 ± 5.06	106.5	0.36
Sex, n (%)[d]			0.15	0.70
Male	11(42)	6(60)		
Female	15(58)	4(40)		
Delayed perforation[4]	1(4)	0(0)	-	1.00
Delayed bleeding	0(0)	0(0)	-	-
Lesions				
Number	29	12		
Tumor size, median (range), mm[c]	15(5–60)	20(5–40)	152.5	0.52
Location in duodenum, n (%)[e]			-	<0.05
First part	13(45)	0 (0)		
Second part	15 (52)	11 (92)		
Third part	0 (0)	1 (8)		
First-Second part junction	1 (3)	0(0)		
Layer, n (%)[e]			-	<0.05
Mucosa	8 (28)	6 (50)		
Submucosa	20(69)	3 (25)		

[a] Nasogastric tube and jejunal feeding tube

[b] Triple-lumen feeding tube

[c] Mann–Whitney U test

[d] Chi-square test

[e] Fisher's exact test

Variable	Double-tube group[a]	Triple-lumen tube group[b]	U/χ^2	*P*
Muscularis propria	1(3)	3(25)		
Postoperative day of first enteral nutrition, median (range)[c]	3(2–5)	2(2–3)	98	0.22
Nasal mucosal pressure injury,n(%)[e]	19 (73.1)	3(30)	-	<0.05
[a] Nasogastric tube and jejunal feeding tube				
[b] Triple-lumen feeding tube				
[c] Mann–Whitney U test				
[d] Chi-square test				
[e] Fisher's exact test				

2.6 Follow-Up

Of 36 patients, two were lost within the first year but showed no evidence of local tumor recurrence on early endoscopic reassessment. Among the remaining 34, no local tumor recurrence occurred among patients with neoplastic lesions over a median follow-up of 43 months (range, 12–51).

Discussion

In this retrospective, single-center cohort study, 36 patients with 41 non-ampullary duodenal lesions (NADLs) underwent endoscopic resection. En bloc and R0 resection were achieved in 95% and 93% of cases, respectively. After a median follow-up of 43 months, no local recurrence was observed among patients who completed long-term follow-up. One patient (2.4%) developed delayed perforation following ESD, which resolved with conservative management and endoscopic drainage. No delayed bleeding, surgical intervention, or perioperative mortality occurred. These findings describe favorable observed outcomes in carefully selected patients but do not establish comparative safety or efficacy [6–8].

Endoscopic resection may offer advantages over major surgery, including less operative trauma and organ preservation. However, direct comparisons of hospital stay and complication rates are limited, and the present study was not designed to compare endoscopic and surgical treatment. Pancreaticoduodenectomy carries a high risk of serious adverse events (30–60%), including pancreatic fistula, delayed gastric emptying, and infections, even in high-volume centers [9, 10]. EFTR has further expanded the limits of endoscopic therapy, enabling resection of selected lesions originating from the muscularis propria [13].

Despite achieving a 93% R0 resection rate (1 case with positive horizontal margin, 1 with positive vertical margin, and 1 with uncertain margin), no recurrences were observed. This suggests that histological margin status may not always reflect biological residual disease. Bhatt et al. [14] reported that R1 margins were independently associated with higher recurrence risk in duodenal neuroendocrine tumors, with most recurrences occurring within 3 years, highlighting the prognostic importance of R0 resection. However, Hwang et al. [15] found that some R1 or uncertain-margin cases remained recurrence-free in long-term follow-up. Factors such as cautery artifacts, specimen contraction, and tissue orientation may underestimate margins [16, 17]. Thus, while R0 remains a primary therapeutic target, it should not be interpreted as the sole predictor of long-term outcome.

Previous studies have consistently identified the resection technique as a key determinant of R0 resection. The 2022 ESGE guideline emphasizes that, although endoscopic submucosal dissection (ESD) is technically more demanding, it provides superior en bloc and R0 resection rates compared with alternative endoscopic resection modalities[18]. In duodenal lesions, a recent systematic review demonstrated an R0 resection rate of 80.9% with ESD, significantly higher than that of EMR (54.2%)[19]. Esaki et al. [20] further confirmed that duodenal ESD achieves improved histological completeness and R0 resection, albeit with an increased risk of adverse events, particularly perforation. Meta-analytic evidence similarly supports the superiority of ESD over EMR in achieving curative resection, while also highlighting its higher technical complexity and perioperative risk profile[21].

Mechanistically, these differences are primarily attributable to the ability of ESD to achieve controlled, en bloc excision along the submucosal plane, thereby preserving specimen integrity. In contrast, piecemeal resection disrupts histological continuity, resulting in tissue fragmentation and reduced reliability of margin assessment, which inherently compromises the accuracy of R0 evaluation[22–24].

In the present study, the low rate of piecemeal resection, combined with systematic use of traction-assisted techniques, likely played a synergistic role in optimizing procedural conditions. Traction facilitates stable exposure of the submucosal dissection plane, improves visualization of lateral and deep margins, and enables more precise and controlled dissection. Collectively, these factors may have contributed to accurate margin delineation and, consequently, the high R0 resection rate observed in this cohort[25].

EMR was predominantly used for mucosal lesions (82%), ESD for submucosal lesions (79%), and EFTR for muscularis propria lesions (67%), with significant differences in resection depth among groups ($P < 0.05$). These findings align with ESGE and ASGE guidance that technique selection should be based on lesion invasion depth rather than size. Bourke et al. emphasized submucosal invasion depth as the key determinant for ESD suitability [26]. For EFTR, multicenter prospective studies have demonstrated high R0 rates even in lesions involving the muscularis propria or with deep fibrosis [27]. Accordingly, the observed differences primarily reflect lesion-based treatment selection and should not be interpreted as evidence of comparative superiority among EMR, ESD, and EFTR.

The pathological spectrum of NADLs in the present study included adenomas, early adenocarcinomas, neuroendocrine tumors, GISTs, and other mesenchymal lesions, highlighting the marked histopathological and biological heterogeneity of these lesions. As such, NADLs may be better regarded as a location-based disease category rather than a single biological entity[28]. Lesion origin and invasion depth guided technique selection, highlighting the importance of preoperative EUS assessment and individualized planning

Complications remain a limiting factor for duodenal endoscopic resection. Adverse event rates of 10–35% have been reported for duodenal ESD, with delayed bleeding and perforation being the most frequent risks [29, 30]. In this study, only one delayed perforation occurred, with no delayed bleeding. All defects were closed individually based on lesion size, location, morphology, and depth. Complete defect closure reduces delayed adverse events: Shigeta et al. reported delayed bleeding in 4.5% of cases with complete closure versus 18.8% without ($P < 0.05$) [31], and Kawamura et al. identified incomplete closure as a significant risk factor for post-ESD complications [32]. Whenever feasible, complete closure is recommended, particularly for high-risk lesions or locations.

Bile and pancreatic secretions may expose the defect to ongoing chemical irritation after duodenal resection [33]. Following a delayed perforation case, our center optimized postoperative management by implementing a single three-lumen feeding tube system, providing simultaneous gastrointestinal decompression, jejunal nutrition, and targeted local irrigation as an adjunctive strategy. Accurate placement of the gastric side port is critical to ensure effective defect irrigation and drainage. Postoperative imaging on day 1 confirmed correct tube positioning. No further delayed perforations or bleeding events were observed after this strategy was introduced; however, its independent effect cannot be determined because all defects were closed and there was no randomized control group. In centers without triple-lumen feeding tubes, irrigation can also be performed as long as the side hole of the gastric tube is correctly aligned with the wound surface.Multicenter prospective studies are needed to validate this approach.

This study has several limitations. Its retrospective, single-center design, small and pathologically heterogeneous cohort, and reliance on a single experienced endoscopist may limit generalizability. In addition, postoperative management was nonrandomized and changed over time; therefore, findings regarding triple-lumen tube-assisted irrigation should be considered exploratory rather than causal. Although the median follow-up was 43 months, longer follow-up is needed for indolent tumors. Larger multicenter studies are warranted to validate these findings.

In conclusion, endoscopic resection achieved high en bloc and R0 resection rates with favorable long-term outcomes in selected patients with NADLs. Technique selection and complete defect closure remain central to management. Local irrigation, decompression, and jejunal feeding were incorporated into postoperative care following experience with delayed perforation. Both tube configurations supported these measures. The triple-lumen system may simplify nursing care by combining these functions in a single tube and was associated with less nasal mucosal pressure injury. The timing of

enteral nutrition did not differ significantly between groups. Larger controlled studies are needed to determine whether these postoperative measures improve healing or reduce delayed adverse events.

Declarations

Disclosures

Xue Jia, Xiaoyan Qi, Bowen Ha, Xiaozhi Hu, Guanlan Liu, Zhiguang Hu, and Haiqing Hu have no conflicts of interest or financial ties to disclose.

Funding:

National Natural Science Foundation of China Regional Science Foundation Project (82460118); General Project of Natural Science Foundation of Inner Mongolia Autonomous Region (2024MS08002); Major Project for High Level Clinical Specialty Construction of Peking University Cancer Hospital Inner Mongolia Hospital (2024YNZD002); Research Joint Fund Project of Public Hospitals of Inner Mongolia Academy of Medical Sciences (2024GLLH0390); Natural Science Foundation Project of Inner Mongolia Autonomous Region (2025QN0811); Special Project for Enhancing the Research Capacity of the Clinical Medicine Discipline at the Affiliated Hospital of Inner Mongolia Medical University (NYFY2025LCYXXK014).

Author Contribution

X.J. contributed to patient management, data analysis, and manuscript drafting and revision. X.Q. and B.H. contributed to patient management, preoperative assessment, and follow-up. Z.H., G.L., and X.H. assisted with endoscopic procedures and collected and organized the data. H.H. performed the endoscopic procedures, provided technical support, acquired funding, supervised the study, and critically revised the manuscript. All authors reviewed and approved the final manuscript.

Data Availability

The datasets generated and/or analysed during the current study are available from the corresponding author on reasonable request.

References

1. Pimentel–Nunes P, Libânio D, Bastiaansen BAJ, et al. Endoscopic submucosal dissection for superficial gastrointestinal lesions: European Society of Gastrointestinal Endoscopy (ESGE) Guideline-Update 2022. Endoscopy. 2022;54(6):591–622.

2. Yahagi N, Kato M, Ochiai Y, et al. Outcomes of endoscopic resection for superficial duodenal epithelial neoplasia. Gastrointest Endosc. 2018;88(4):676–82.
3. Oh GM, Je HS, Jung K, et al. Low recurrence rate after endoscopic resection in non-ampullary duodenal lesions: a 16-year single-center retrospective study. Med (Baltim). 2021;100:e26267.
4. Yahagi N, Takatori Y, Sasaki M, et al. Feasibility of endoscopic submucosal dissection including papilla (ESDIP) (with video). Dig Endosc. 2025;37(4):402–10.
5. Andrisani G, Di Matteo FM. Endoscopic full-thickness resection of duodenal lesions (with video). Surg Endosc. 2020;34(4):1876–81.
6. Jeon HK, Kim GH. Endoscopic Resection for Superficial Non-Ampullary Duodenal Epithelial Tumors. Gut Liver. 2025;19(1):19–30.
7. Li W, Liu Y, Dou L, et al. Treatment outcomes of endoscopic resection for nonampullary duodenal neuroendocrine tumors. J Gastrointest Onco. 2024;15(3):1255–64.
8. Hoibian S, Ratone JP, Gonzalez JM, et al. Endoscopic mucosal resection of sporadic nonampullary duodenal adenoma: outcomes of 130 patients with a long–term follow up in two tertiary French centers. Ann Gastroenterol. 2021;34(2):169–76.
9. Kokkinakis S, Kritsotakis EI, Maliotis N, et al. Complications of modern pancreaticoduodenectomy: A systematic review and meta-analysis. Hepatobiliary Pancreat Dis Int. 2022;21(6):527–37.
10. Dominguez OH, Grigorian A, Wolf RF, et al. Delayed gastric emptying is associated with increased risk of mortality in patients undergoing pancreaticoduodenectomy for pancreatic adenocarcinoma. Updates Surg. 2023;75(3):523–30.
11. Pérez-Cuadrado-Robles E, et al. ESD versus EMR in non-ampullary superficial duodenal tumors: a systematic review and meta-analysis. Endosc Int Open. 2018;6:E998–1007.
12. Rimondi A, Dell'Unto E, Morais R, et al. Outcomes and safety of duodenal endoscopic submucosal dissection for nonampullary lesions: systematic review and meta-analysis. Gastrointest Endos. 2025;102(4):514–e5249.
13. Bauder M, Schmidt A, Caca K. Endoscopic full-thickness resection of duodenal lesions—a retrospective analysis of 20 FTRD cases. United Eur Gastroenterol J. 2018;6(7):1015–21.
14. Bhatt A, Abe S, Kumaravel A, et al. Impact of margin status on outcomes after endoscopic resection of well-differentiated duodenal neuroendocrine tumors. Gastrointest Endosc. 2021;94(3):580–e5881.
15. Hwang KL, Kim GH, Lee BE, et al. Long-term outcomes of endoscopic resection for non-ampullary duodenal epithelial tumors: a single-center experience. Turk J Gastroenterol. 2020;31(1):49–57.
16. Kumarasinghe MP, Bourke MJ, Brown I, et al. Pathological assessment of endoscopic resections of the gastrointestinal tract: a comprehensive clinicopathologic review. Mod Pathol. 2020;33(2):193–202.
17. Gotoda T, Kondo H, Ono H, et al. Endoscopic mucosal resection and submucosal dissection for early gastrointestinal cancers: complications and pathological assessment. Gastrointest Endosc.

2005;62(5):696–701.

18. Vanbiervliet G, Moss A, Arvanitakis M, et al. Endoscopic management of superficial nonampullary duodenal tumors: European Society of Gastrointestinal Endoscopy (ESGE) Guideline. Endoscopy. 2021;53(5):522–34.
19. Yamasaki Y, Iwagami H, Matsueda K, et al. What is the optimal endoscopic resection method for intermediate-sized (10–20 mm) superficial non-ampullary duodenal epithelial tumors? A systematic review. Digestion; 2026.
20. Esaki M, Haraguchi K, Akahoshi K, et al. Endoscopic mucosal resection vs endoscopic submucosal dissection for superficial non-ampullary duodenal tumors. World J Gastroenterol. 2020;26(8):918–30.
21. Amoyel M, Belle A, Dhooge M, et al. Endoscopic management of non-ampullary duodenal adenomas. Endosc Int Open. 2022;10(01):E96–108.
22. Bahin FF, Heitman SJ, Rasouli KN, et al. Piecemeal endoscopic resection and risk of recurrence in colorectal lesions: a systematic review and meta-analysis. Gastrointest Endosc. 2016;84(4):625–e6355.
23. Ferlitsch M, Hassan C, Bisschops R, et al. Colorectal polypectomy and endoscopic mucosal resection: European Society of Gastrointestinal Endoscopy (ESGE) Guideline—Update 2024. Endoscopy. 2024;56(7):516–45.
24. Lopimpisuth C, Simons M, Akshintala VS, et al. Traction-assisted endoscopic submucosal dissection reduces procedure time and risk of serious adverse events: a systematic review and meta-analysis. Surg Endosc. 2022;36(3):1775–88.
25. Oyama T. Counter traction makes endoscopic submucosal dissection easier. Clin Endosc. 2012;45(4):375–8. 10.5946/ce.2012.45.4.375.
26. Bourke MJ, Neuhaus H, Bergman JJ. Endoscopic submucosal dissection: indications and application in western endoscopy practice. Gastroenterology. 2018;154(7):1887–900. e5.
27. Schmidt A, Beyna T, Schumacher B, et al. Colonoscopic full-thickness resection using an over-the-scope device: a prospective multicentre study in various indications. Gut. 2018;67(7):1280–9.
28. Seicean A, Tantau M. Endoscopic ultrasound assessment of the duodenal wall lesions. In: Stoian M, editor. Echoendoscopy. London: IntechOpen; 2021.
29. Akahoshi K, Kubokawa M, Inamura K, et al. Current challenge: endoscopic submucosal dissection of superficial non-ampullary duodenal epithelial tumors. Curr Treat Options Oncol. 2020;21(12):98.
30. Kuroki K, Sanomura Y, Oka S, et al. Clinical outcomes of endoscopic resection for superficial non-ampullary duodenal tumors. Endosc Int Open. 2020;8(03):E354–9.
31. Shigeta K, Yoshida M, Yamamoto Y, et al. Risk factors for delayed bleeding after endoscopic resection of non-ampullary duodenal epithelial tumors and the effectiveness of complete mucosal closure in high-risk patients. Surg Endosc. 2025;39(2):1025–35.

32. Kawamura T, Hirose T, Kakushima N, et al. Factors related to delayed adverse events of endoscopic submucosal dissection in the duodenum. Dig Dis. 2023;41(1):80–8.
33. Fujihara S, Mori H, Kobara H, et al. Management of a large mucosal defect after duodenal endoscopic resection. World J Gastroenterol. 2016;22(29):6595–609.

Figures

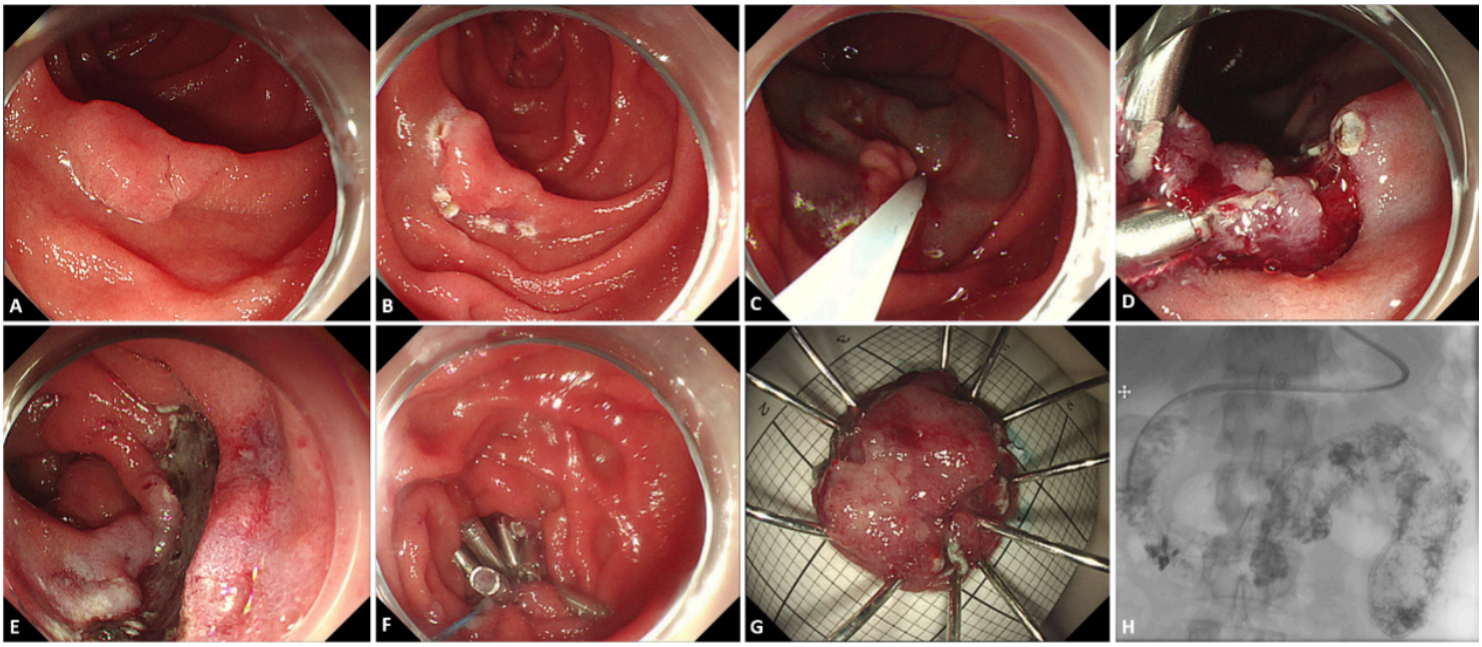

Figure 1

Endoscopic submucosal dissection (ESD) of a non-ampullary duodenal lesion.

(A) Lesion located in the descending duodenum; (B) Circumferential marking outside the lesion margin; (C) Submucosal injection; (D) Intraoperative clip-assisted snare traction; (E) Post-resection mucosal defect; (F) Defect closure using metallic clips and a nylon loop; (G) Resected specimen; (H) Postoperative radiographic contrast study demonstrating correct placement of the triple-lumen feeding tube.

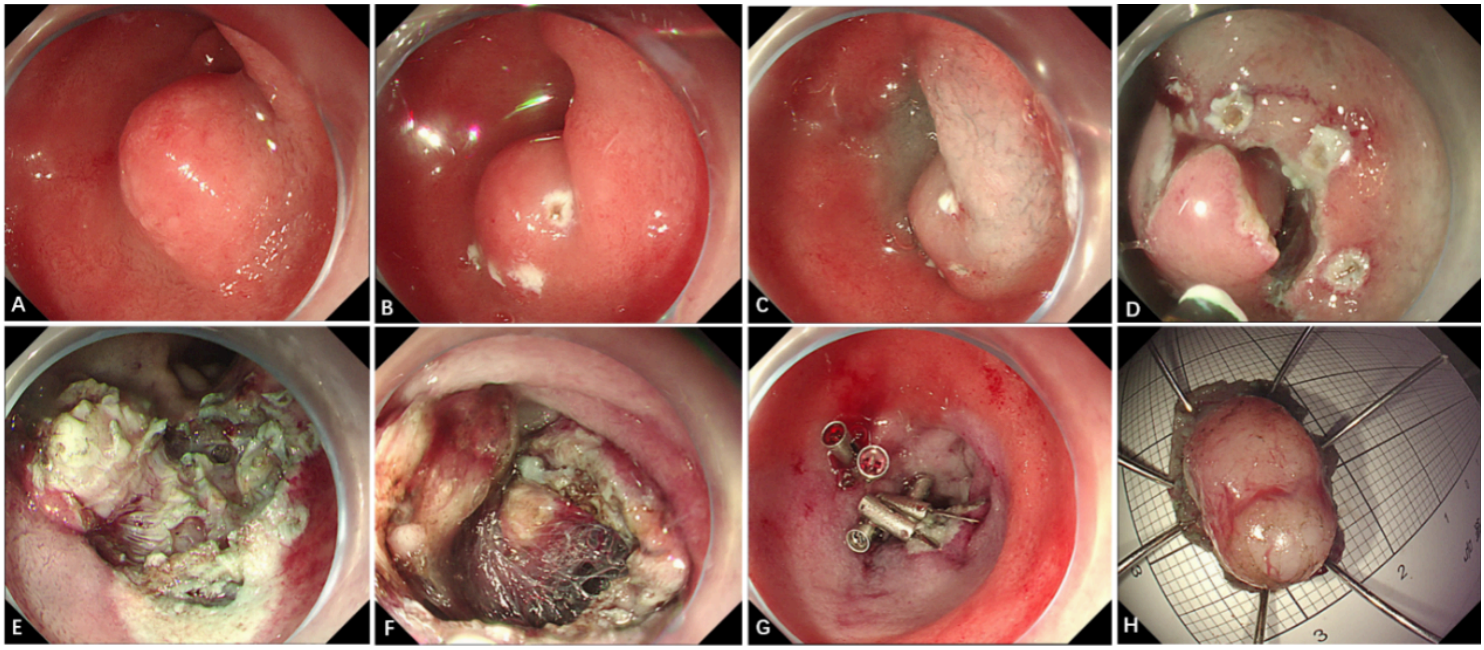

Figure 2

Endoscopic full-thickness resection (EFTR) of a non-ampullary duodenal lesion.

(A) Lesion located in the duodenal bulb; (B) circumferential marking around the lesion margin; (C) submucosal injection; (D) incision along the markings; (E) full-thickness resection; (F) post-resection defect; (G) closure of the defect with endoscopic clips; (H) resected specimen

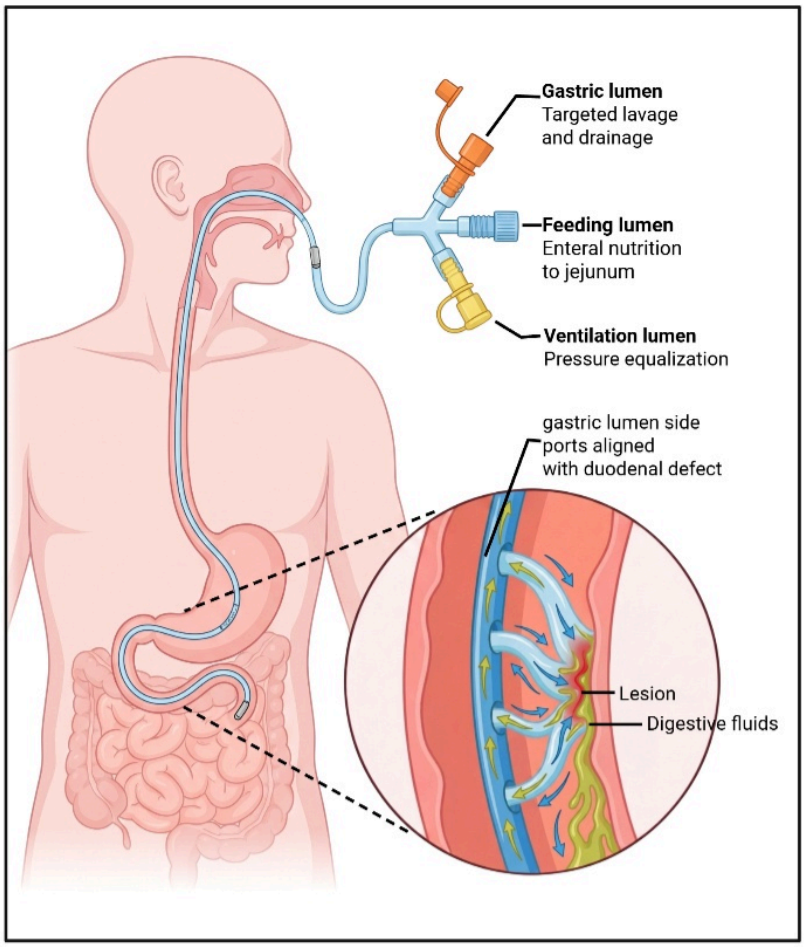

Figure 3

Schematic illustration of triple-lumen tube-assisted irrigation, decompression, and jejunal feeding after duodenal endoscopic resection.

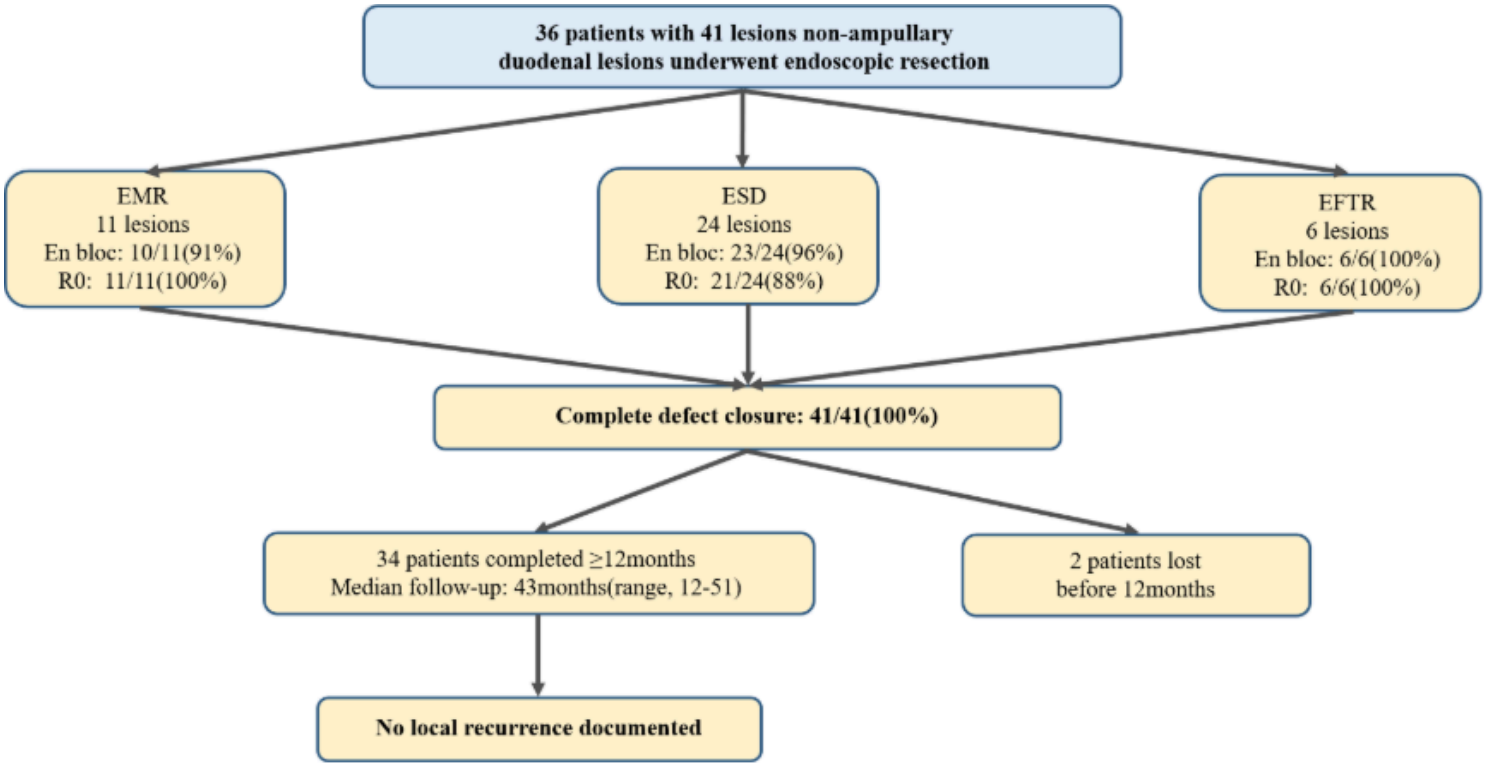

Figure 4

Study Flowchart of Endoscopic Resection for Non-Ampullary Duodenal Lesions (NADLs)