Research Square

Preprints are preliminary reports that have not undergone peer review.
They should not be considered conclusive, used to inform clinical practice,
or referenced by the media as validated information.

Three-Dimensional Evaluation of Maxillary Sinus Dimensions and Volume in Patients With Unilateral Maxillary Impacted Canines, Using Cone Beam Computed Tomography

Fatih KAHRAMAN
Mücahid Faik ŞAHİN
mucahid.sahin@bilecik.edu.tr

Bilecik Şeyh Edebali Üniversitesi
Mehmet UĞURLU
Necmettin Erbakan University
Rıdvan OKŞAYAN
Bilecik Şeyh Edebali Üniversitesi
İbrahim Sevki BAYRAKDAR
Eskisehir Osmangazi University

Research Article

Keywords: Maxillary impacted canines, Maxillary sinus, Cone-beam computed tomography

Posted Date: November 23rd, 2026

DOI: https://doi.org/10.21203/rs.3.rs-11280167/v1

License: This work is licensed under a Creative Commons Attribution 4.0 International License.
Read Full License

Additional Declarations: No competing interests reported.

Abstract

Objective: To investigate the relationship between maxillary sinus size and volume in patients with unilateral impacted canine, using cone beam computed tomography (CBCT).

Material and methods: CBCT images of 26 patients (7 men, 19 women; mean age: 19.40+/– 4.73 years), each with a unilateral maxillary impacted canine, were evaluated. All three-dimensional images had been obtained in a standing position by using CBCT. The following maxillary sinus related parameters were evaluated with CBCT images: right and left maxillary sinus volume, length, width, and height.

Results: There was no statistically significant difference in maxillary sinus volume measurements between the impaction and non-impaction sides ($p<0.05$). Additionally, the results showed no significant differences in maxillary sinus length, width, and height parameters between the unilateral impaction side and the normally erupted side ($p<0.05$).

Conclusions: Maxillary canine impaction did not have a significant impact on maxillary sinus volume or dimensions (length, width, and height). CBCT seems to be very helpful in evaluating the relationship between maxillary impacted canine and maxillary sinus morphology.

Clinical relevance: The results of the our study may be useful in maxillary impacted canine eruption with fixed orthodontic appliances and mini-screw insertions in the upper jaw.

SUMMARY

The aim of this study was to investigate the relationship between maxillary sinus size and volume in patients with unilateral impacted canine, using cone beam computed tomography (CBCT). CBCT images of 26 patients (7 men, 19 women; mean age: 19.40+/– 4.73 years), each with a unilateral maxillary impacted canine, were evaluated. All three-dimensional images had been obtained in a standing position by using CBCT. The following maxillary sinus related parameters were evaluated with CBCT images: right and left maxillary sinus volume, length, width, and height. There was no statistically significant difference in maxillary sinus volume measurements between the impaction and non-impaction sides ($p<0.05$). Additionally, the results showed no significant differences in maxillary sinus length, width, and height parameters between the unilateral impaction side and the normally erupted side ($p<0.05$). Maxillary canine impaction did not have a significant impact on maxillary sinus volume or dimensions (length, width, and height). CBCT seems to be very helpful in evaluating the relationship between maxillary impacted canine and maxillary sinus morphology.

INTRODUCTION

The maxillary sinus is the largest of all the paranasal sinuses, and it is located bilaterally in the mid-facial skeleton; additionally, itis the first paranasal sinus to develop in the structures of the viscerocranium, in

the third month of fetal growth [1, 2]. The base of the maxillary sinus is located in the lateral nasal wall and extends up to the zygomatic process of the maxilla [3]. The maxillary sinus achieves adult size between 12 and 15 years of age, similar to the growth period of the maxilla [4].

Many studies on maxillary sinus volume and dimensions relate to the relationships among cleft lip and palate, oral breathing, and skeletal malocclusions [2, 5, 6] Tikku et al. conclude that mouth-breathers have a smaller maxillary sinus volume than normal breathers [7]. Erdur et al. state that maxillary sinus volumes are impaired in unilateral cleft-lip and palate patients, compared to a healthy control group [6]. Endo et al. found no statistically significant association between sinus size and sagittal jaw relationship in 12–16-year-old patients [12]. Another study investigated the relationship between vertical face-growth patterns and maxillary sinus dimensions, and it found that vertical face dimensions had no effects on maxillary sinus volumes [4]. We found only one study regarding the relationship between maxillary impacted canine and maxillary sinus volume: Oz et al. studied the maxillary sinus volumes in unilaterally impacted canine patients by using CBCT [8].

Maxillary sinus size and shape measurement protocols have improved with recent advances in dento-facial imaging. Two-dimensional radiographs offer limited information with regards to evaluations of the morphology and volume of three-dimensional structures. In undertaking both maxillary sinus and maxillary impacted canine 3D assessments, CBCT offers many advantages (e.g., decreased distortion, reliable, cost-effective, and lower radiation dose) [9].

Three-dimensional and volumetric assessments of the maxillary sinus are needed to determineoptimal orthodontic treatment options. Darsey et al. studied the effects of hyrax expansion therapy on maxillary sinus volume, and they foundit had no significant impact on maxillary sinus volume. Furthermore, maxillary sinus dimensions are important in fixed orthodontic treatments with posterior teeth extraction, as in such cases teeth move distally or mesially and there is a risk of sinus perforation. When teeth are crowded and not properly aligned, maxillary impacted canines come into very close contact with the maxillary sinuses [10]. Some studies found that the intrusion and bodily movement of teeth across the sinus floor can cause tipping and root resorption [11, 12]. Song et al. found that maxillary sinus shape and size might play an important role in facial contour formation [13]. Another condition that requires consideration in orthodontic treatment planning is the proximity of maxillary impacted canines to adjacent structures, such as the maxillary sinus and the roots of the laterals and premolars.

To date, the evaluation of both sinus dimensions (i.e., length, width, and height) and volume in patients with maxillary impacted canines has not been undertaken through the use of CBCT. Therefore, the aim of this dimensional study is to assess with CBCT the relationship between maxillary sinus size and volume in patients with unilateral impacted canines.

MATERIAL AND METHODS

In this retrospective study, we examined the three-dimensional CBCT records of 26 patients (7 men, 19 women; mean ages 19.40+/−4.73 years), each of whom had a unilateral maxillary impacted canine.

Eleven of the maxillary impacted canines were located on the right side; the other 15 were located on the left side. The subjects had been referred to the orthodontic department for consultation, with the chief complaint of maxillary impacted canine.

The exclusion criteria include the presence of sinus pathologies (e.g., sinusitis, retention cysts, etc.), diagnosed craniofacial syndrome, oral breathers, presence of cleft lip or palate, systemic bone diseases related to the mid-facial region, previous orthognathic surgery, any history of orthodontic treatment, and those patients under the age of 15 years. The study protocols were approved by the Clinical Ethical Committee of Eskişehir Osmangazi University(09.05.2016-29).

The same CBCT device (Promax 3D. Mid; Planmeca, Helsinki, Finland) was used for all patients, and they were in a standing position during the CBCT imagining period. The technical specifications of that CBCT device are as follows: tube voltage of 94 kVp, X-ray tube current of 14 mA, scanning in 360-degree rotation, and a scanning time of 27 s. All CBCT scans were evaluated by the same operator (F.K.), to preclude inter observer differences. Data obtained from the CBCT images were recorded at a computer workstation. Simplant O&O (Materialise, Leuven, Belgium) dental software was used to assess the dimensional maxillary sinus measurements of both the impacted canine side and the other side, the maxillary sinus length (i.e., the perpendicular distance between the most anterior point andthe most posterior point of the sinus in the sagittal plane of the three-dimensional image), the width (i.e., the widest part of the sinus in the axial plane of the three-dimensional image), and height (i.e., the perpendicular distance between the most superior point and the most inferior point of the sinus in the sagittal plane of the three-dimensional image) [13]. Volumetric maxillary sinus measurements were performed using the Dolphin tracing software program (v11.9) (Dolphin Imaging and Management Solutions, Chatsworth, CA, USA),on both the impacted canine side and the other side. Any relationships with other airway areas were eliminated; cropping was done to obtain the widest measurement in all three planes, and the sinus volumes of both sides were measured in constructed three-dimensional images [14] (Fig. 1). All sinus volumes were measured in cubic millimeters (mm^3).

Statistical analyses were performed with MedCalc Software for Windows (v17.5) (Broekstraat, Mariakerke, Belgium). Means and standard deviations were calculated for each of the maxillary sinus variables. To assess intra-examiner reliability, 10 randomly selected tomographs were remeasured by the same investigator (F.K.) after a two-week interval. The Kolmogorov–Smirnov test was used for normality evaluation, and the student's *t*-test for independent samples was used to analyze correlation among variables. Statistical significance was set at 5%.

RESULTS

This retrospective study analyzes the CBCT records of 26 unilateral maxillary impacted canine patients. Descriptive statistics (i.e., subject number, mean age, gender, and impaction side) appear in Table I.

The results of maxillary sinus volume measurements and their statistical analyses are presented in Table II. The mean maxillary sinus volumes of the unilateral canine impaction side and the normally erupted canine side were 12131.42 +/– 2832.40 mm^3 and 12416.69 +/– 2905.73 mm^3, respectively; no statistically significant differences were found between the two groups ($p < 0.05$).

The maxillary sinus dimension measurements are shown in Table III. The mean maxillary sinus lengths of the unilateral canine impaction side and the normally erupted canine side were 37.14 +/– 2.79 mm and 36.85 +/– 2.69 mm, respectively. The mean maxillary sinus widths of the impaction side and normally erupted side were 29.96 +/– 4.36 mm and 29.63 +/– 4.49 mm, respectively. The mean maxillary sinus heights of the unilateral canine impaction side and the normally erupted canine side were 35.97 +/– 5.71 mm and 36.70 +/– 4.67 mm, respectively. Statistical analyses showed no significant differences in the maxillary sinus length, width, and height parameters between the unilateral impaction side and the normally erupted side ($p < 0.05$).

DISCUSSION

Within the literature, various studies have focused on maxillary sinus dimensions and volume in the orthodontic area (e.g., cleft lip and palate, malocclusion, and mouth-breathers); the number of studies that focus on CBCT examinations of the maxillary sinus inimpacted canine patients, however, is small [8]. In addition, we have not yet encountered any CBCT study that evaluates both the volume and dimensions of the maxillary sinus in unilateral maxillary canine impaction. Additionally, it is essential to undertake dimensional evaluations of the maxillary sinus with CBCT, to address adverse situations such as root resorption, sinus perforation, and tipping in the posterior teeth[15, 16]. Lana et al. found an association between the dimensions and shape of the maxillary sinus and the proximity of the tooth roots [17]. In addition, Song et al. report that the maxillary sinus relates to the middle-face shape, and they suggest that the maxillary sinus might play an important role in facial contours [13]. In the current study, we compare CBCT evaluations of maxillary sinus dimensions and volume in unilateral maxillary impaction, and our results confirm that there is no statistically significant relationship between maxillary canine impaction and maxillary sinus volume and dimensions.

Upon comparing the mean volumes, we found there to be no significant difference between the impaction side (12131.42 +/– 2832.40 mm^3) and the non-impaction side (12416.69 +/– 2905.73 mm^3). However, the non-impaction sides did tend to have a larger maxillary sinus volume than the impaction side. This tendency may be explained by the maxillary impacted canines’effect on inferior maxillary sinus development. Oz et al. found the right maxillary sinus volume to be statistically smaller than the left one when the canine was impacted on the right side, prior to orthodontic treatment; they also found that if the impacted canines erupted to the occlusion maxillary sinus, volume enhancement may occur [8]. However, other congenital deformities like cleft lip and palate were found to have a negative impact on maxillary sinus volume [6]. Contrary to our sinus volume findings, Agacayak et al. found that the volume of the maxillary sinus in oral breathers was significantly lower than that in nasal breathers [5]. This may be explained by inadequate nasal breathing activity, as oral breathers showed transversal maxillary

dimensional deficiency, which may in turn reduce maxillary sinus volume. Muszynska et al. found that at the end of the 16th year, the maximum sinus sizes (in all dimensions) and volume of the maxillary sinus are reached [1]. Dissimilarities among the findings of various sinus volume studies can be attributed to patient age:the current study includesonly patients over the age of 15, in order to exclude patients still in maxillary sinus development. Additionally, Shahidi et al. conclude that variations in maxillary sinus anatomyare common in CBCT images [18].

Our results indicate that there are no significant differences in maxillary sinus dimensions (i.e., the maxillary sinus length, height, and width) between the impaction side and normally erupted side. In this respect, our findings are similar to those in the literature: Endo et al., for example, found no statistically significant association between maxillary sinus sizes (length and height) and the ANB angle (i.e., thus addressing the sagittal skeletal jaw relationship) in 12–16-year-old subjects [2]. In their computed tomography study, Ariji et al. report that the height of the sinus floor changed along with changes to sinus volume, but that it was not clearly influenced by dental status [19]. The current study is superior to these within the literature, in that it features a three-dimensional maxillary sinus evaluation by way of CBCT, as well as sinus width parameter measurements.

The maxillary sinus enlarges the forward direction to the first premolar and canine section [2]. The impaction of the maxillary impacted canine due to the inferior growth of the maxillary sinus may affect the fixed orthodontic treatment process in patients with malocclusion. Therefore, knowledge of the maxillary sinus dimensions and volume may be very important in making assessments and undertaking the orthodontic treatment of malocclusions. Additionally, the dimensional findings of the current study may be useful in undertaking orthodontic mini-screw insertions in the upper jaw of impacted canine cases. Furthermore, three-dimensional studies are needed to evaluate within a larger study sample maxillary sinus dimensions and volume according to maxillary impacted canine angulation and the localization features.

The following conclusions can be drawn from the results of this study.

- While the normally erupted side showed larger maxillary sinus volume, statistically, maxillary sinus volume findings seemed not to relate directly to maxillary canine impaction.
- There were no significant differences in maxillary sinus dimensions (i.e., length, height, and width) between the unilateral impaction side and the normally erupted side.
- Three-dimensional imaging, especially CBCT, seems to be very helpful in determining the relationship between maxillary impacted canines and maxillary sinus morphology.
- Knowledge of the dimensions and location of the maxillary sinus in impaction cases will be useful in undertaking fixed orthodontic treatments for maxillary impacted teeth.

Declarations

Conflict of Interest:

The authors declare that they have no conflict of interest.

Clinical relevance

The results of the our study may be useful in maxillary impacted canine eruption with fixed orthodontic appliances and mini-screw insertions in the upper jaw.

Funding:

There is no funding to report for this manuscript.

Author Contribution

F.K. (designed material method and traced the 3D images)M.F.S. (wrote the manuscript)M.U. (made the statistical analyses)R.O. (prepared the figures and tables)İ.S.B. (edited the manuscript and helped the methodology)

Data Availability

The datasets used and/or analysed during the current study are available from the corresponding author on reasonable request.

References

1. Lorkiewicz-Muszynska D, Kociemba W, Rewekant A, Sroka A, Jonczyk-Potoczna K, Patelska-Banaszewska M, et al. Development of the maxillary sinus from birth to age 18. Postnatal growth pattern. Int J Pediatr Otorhinolaryngol. 2015;79:1393–400.
2. Endo T, Abe R, Kuroki H, Kojima K, Oka K, Shimooka S. Cephalometric evaluation of maxillary sinus sizes in different malocclusion classes. Odontology. 2010;98:65–72.
3. Orhan K, Kusakci Seker B, Aksoy S, Bayindir H, Berberoglu A, Seker E. Cone beam CT evaluation of maxillary sinus septa prevalence, height, location and morphology in children and an adult population. Med Princ Pract. 2013;22:47–53.
4. Oksayan R, Sokucu O, Yesildal S. Evaluation of maxillary sinus volume and dimensions in different vertical face growth patterns: a study of cone-beam computed tomography. Acta Odontol Scand. 2017;75:345–9.
5. Agacayak KS, Gulsun B, Koparal M, Atalay Y, Aksoy O, Adiguzel O. Alterations in maxillary sinus volume among oral and nasal breathers. Med Sci Monit. 2015;21:18–26.

6. Erdur O, Ucar FI, Sekerci AE, Celikoglu M, Buyuk SK. Maxillary sinus volumes of patients with unilateral cleft lip and palate. Int J Pediatr Otorhinolaryngol. 2015;79:1741–4.
7. Tikku T, Khanna R, Sachan K, Srivastava K, Munjal N. Dimensional changes in maxillary sinus of mouth breathers. J Oral Biol Craniofac Res. 2013;3:9–14.
8. Oz AZ, Oz AA, El H, Palomo JM. Maxillary sinus volume in patients with impacted canines. Angle Orthod. 2017;87:25–32.
9. da Silva Santos LM, Bastos LC, Oliveira-Santos C, da Silva SJ, Neves FS, Campos PS. Cone-beam computed tomography findings of impacted upper canines. Imaging Sci Dent. 2014;44:287–92.
10. Kwak HH, Park HD, Yoon HR, Kang MK, Koh KS, Kim HJ. Topographic anatomy of the inferior wall of the maxillary sinus in Koreans. Int J Oral Maxillofac Surg. 2004;33:382–8.
11. Wehrbein H, Bauer W, Schneider B, Diedrich P. [Experimental bodily tooth movement through the bony floor of the nose–a pilot study]. Fortschr Kieferorthop. 1990;51:271–6.
12. Wehrbein H, Bauer W, Wessing G, Diedrich P. [The effect of the maxillary sinus floor on orthodontic tooth movement]. Fortschr Kieferorthop. 1990;51:345–51.
13. Song SY, Hong JW, Roh TS, Kim YO, Kim DW, Park BY. Volume and distances of the maxillary sinus in craniofacial deformities with midfacial hypoplasia. Otolaryngol Head Neck Surg. 2009;141:614–20.
14. Panou E, Motro M, Ates M, Acar A, Erverdi N. Dimensional changes of maxillary sinuses and pharyngeal airway in Class III patients undergoing bimaxillary orthognathic surgery. Angle Orthod. 2013;83:824–31.
15. Livas C, Halazonetis DJ, Booij JW, Pandis N, Tu YK, Katsaros C. Maxillary sinus floor extension and posterior tooth inclination in adolescent patients with Class II Division 1 malocclusion treated with maxillary first molar extractions. Am J Orthod Dentofac Orthop. 2013;143:479–85.
16. Jun BC, Song SW, Park CS, Lee DH, Cho KJ, Cho JH. The analysis of maxillary sinus aeration according to aging process; volume assessment by 3-dimensional reconstruction by high-resolutional CT scanning. Otolaryngol Head Neck Surg. 2005;132:429–34.
17. Lana JP, Carneiro PM, Machado Vde C, de Souza PE, Manzi FR, Horta MC. Anatomic variations and lesions of the maxillary sinus detected in cone beam computed tomography for dental implants. Clin Oral Implants Res. 2012;23:1398–403.
18. Shahidi S, Zamiri B, Momeni Danaei S, Salehi S, Hamedani S. Evaluation of Anatomic Variations in Maxillary Sinus with the Aid of Cone Beam Computed Tomography (CBCT) in a Population in South of Iran. J Dent (Shiraz). 2016;17:7–15.
19. Ariji Y, Ariji E, Yoshiura K, Kanda S. Computed tomographic indices for maxillary sinus size in comparison with the sinus volume. Dentomaxillofac Radiol. 1996;25:19–24.
20. Legend. of the figures.

Figures

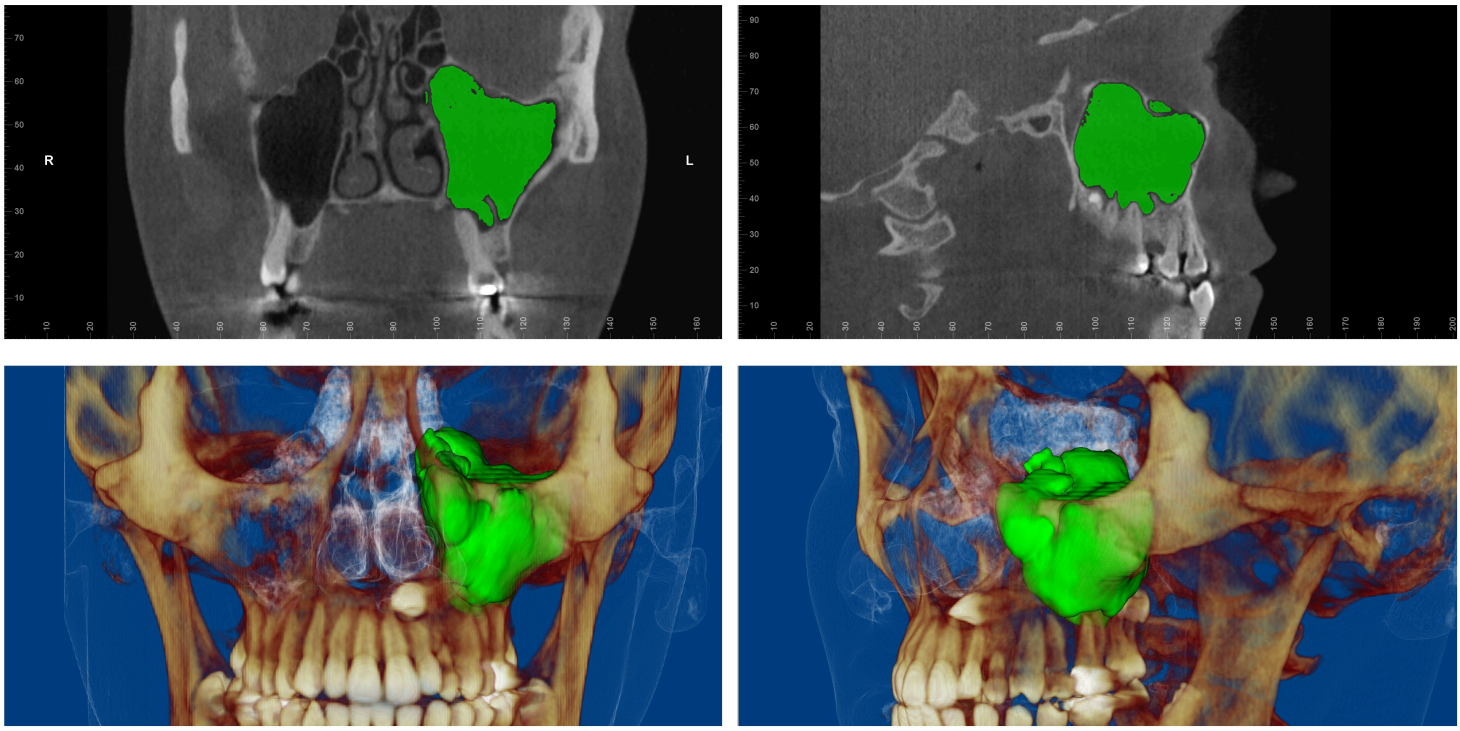

Figure 1

The volumetric measurements of maxillary sinus using the Dolphin software program

Supplementary Files

This is a list of supplementary files associated with this preprint. Click to download.

- TableI.doc
- TableII.doc
- TableIII.doc