Research Square

Preprints are preliminary reports that have not undergone peer review.
They should not be considered conclusive, used to inform clinical practice,
or referenced by the media as validated information.

Spontaneous diaphragmatic hernia in a child: A case report and review of the literature

Xiaoxue Feng
Gansu Provincial Hospital
Yinqi Zhao
Wenzhou Medical University
Ya Guo
Gansu Provincial Hospital
Chaoyi Wang
Wenzhou Central Hospital
Ting Li
Gansu Provincial Hospital
Lei Wu
Ningbo First Hospital
Yingjie Hua
Second Affiliated Hospital & Yuying Children's Hospital of Wenzhou Medical University
Qifeng Han
Gansu Provincial Hospital
Dongqing Ren
rdqing30@126.com

Gansu Provincial Hospital

Case Report

Keywords: Diaphragmatic Hernia, Adolescent, Shock, Hemodynamic Monitoring, Rapid Sequence Induction

Posted Date: November 25th, 2026

DOI: https://doi.org/10.21203/rs.3.rs-11276688/v1

License: This work is licensed under a Creative Commons Attribution 4.0 International License.
Read Full License

Additional Declarations: No competing interests reported.

Abstract

Background

Spontaneous diaphragmatic hernia in children is rare and may occur without a clear history of trauma. When it presents acutely, respiratory and circulatory compromise can develop rapidly, making anesthetic management particularly difficult. We report an emergency pediatric case and describe the perioperative anesthetic strategies used according to the patient’s clinical condition.

1. Background

Diaphragmatic hernia refers to a condition in which abdominal organs enter the thoracic cavity through a defect or weakened area of the diaphragm. Diaphragmatic hernias are mainly classified as congenital or acquired. The main types of acquired diaphragmatic hernia include traumatic diaphragmatic hernia, non-traumatic acquired diaphragmatic hernia (spontaneous diaphragmatic hernia), iatrogenic diaphragmatic hernia, and acquired hiatal hernia. Spontaneous diaphragmatic hernia refers to the rupture of a congenital or acquired weak point in the diaphragm due to a sudden increase in intra-abdominal pressure in the absence of trauma(1, 2). This condition is extremely rare, occurs more frequently in adults, and is seldom reported in children(3–5).It often presents as an acute strangulated diaphragmatic hernia, progresses rapidly, and has a poor prognosis. Currently, the etiology, precipitating factors, and clinical characteristics of pediatric spontaneous diaphragmatic hernia are not yet fully understood(4, 6). In this paper, we report a case of a 14-year-old male patient who experienced a sudden increase in intra-abdominal pressure induced by vigorous physical activity, leading to the rupture of a latent congenital weak point in the diaphragm(7).Previous pediatric reports have described spontaneous diaphragmatic rupture associated with congenital diaphragmatic eventration, further supporting the possibility of an underlying structural weakness in the diaphragm(8). The particularity of this case lies in its rare occurrence during childhood, the clear precipitating factor of physical activity, and the absence of a weak point on preoperative imaging, indicating diagnostic difficulties.This case analysis may serve as a reference for clinical diagnosis and treatment(9).

2. Case Report

A 14-year-old male pediatric patient, height 170 cm, weight 60 kg, was admitted for 'sudden onset of upper abdominal pain for 12 hours after intense physical activity.'The patient reported severe, intolerable upper abdominal pain accompanied by nausea and vomiting of gastric contents, as well as palpitations and shortness of breath. There was no diarrhea, hematochezia, or melena. Upon presentation to the Emergency Department, abdominal computed tomography showed herniation of abdominal organs into the left thoracic cavity, accompanied by mesenteric edema and exudation, thickening of the inferior mesenteric and portal veins, Glisson's capsule effusion, incomplete expansion of the left lung, and rightward displacement of the mediastinum (Fig. 1). The patient was diagnosed with strangulated diaphragmatic hernia with intestinal obstruction and underwent emergency laparoscopic repair.

Figure 1. Computed tomography findings of strangulated diaphragmatic hernia.

Upon admission, vital signs monitoring showed blood pressure (BP) of 60/40 mmHg and heart rate of 165–170 beats/min. Large-bore peripheral venous access was obtained in both upper limbs. Following local anesthesia, left radial artery puncture and catheterization were performed, and an arterial pressure monitoring line was connected for invasive blood pressure monitoring. Gastrointestinal decompression was also carried out. Arterial blood gas analysis revealed: pH 7.228, SaO_2 85.4%, PaO_2 32.5 mmHg, and $PaCO_2$ 56.2 mmHg. Following continuous infusion of norepinephrine through a micro-infusion pump, emergency anesthesia induction was initiated. The patient was placed in the head-up and foot-down position and fully preoxygenated via face mask at 8 L/min for 5 minutes. After careful airway assessment, rapid sequence induction was chosen for intubation anesthesia, avoiding positive pressure ventilation with a face mask. Midazolam 1 mg, etomidate 10 mg, rocuronium bromide 60 mg, and sufentanil 25 μg were administered. Cricoid pressure was applied to prevent regurgitation and aspiration. Under video laryngoscopy, a 6.5-mm reinforced endotracheal tube was smoothly inserted orally and fixed at 17 cm from the incisors. Auscultation revealed no breath sounds in the left lung and diminished breath sounds on the right. The ventilator was connected for mechanical ventilation. Mechanical ventilation was set to volume control mode. The parameters included a tidal volume of 360 mL, a respiratory rate of 12 breaths/min, airway pressure of 25 cmH_2O, and an oxygen flow rate of 2 L/min. The FiO_2 was set at 45% and adjusted as needed according to the clinical situation. Respiratory parameters were modified based on $EtCO_2$ levels.

After the surgery began, we established pneumoperitoneum for laparoscopic exploration, maintaining a low pneumoperitoneum pressure of 8 mmHg. At this time, the patient developed tachycardia with a heart rate of 180 beats/min, while blood pressure suddenly dropped to 70/40 mmHg and oxygen saturation decreased to 94%. The ventilator indicated high airway pressure (55 cmH_2O) and $EtCO_2$ of 59 mmHg. We immediately administered 8 μg of norepinephrine intravenously to raise blood pressure and adjusted the respiratory parameters. We switched to pressure control ventilation, changed the inspiratory-to-expiratory ratio from 1:2 to 1:1.5, increased the FiO_2 from 45% to 55%, and raised the respiratory rate from 12 to 16 breaths/min. Positive end-expiratory pressure (PEEP) was maintained between 2–5 cmH_2O, and airway pressure decreased to 47 cmH_2O. Intermittent lung expansion was performed to maintain oxygen saturation at 92%–96%, with $EtCO_2$ maintained at 47–57 mmHg. Norepinephrine was administered intravenously at 0.03–0.05 μg/kg/min to maintain blood pressure, along with appropriate fluid resuscitation. Blood pressure rose to 90/60 mmHg and heart rate decreased to 130 beats/min, but oxygen saturation and airway pressure did not improve, and $EtCO_2$ continued to increase. It was considered that herniated contents were compressing lung tissue and major cardiac vessels in the thoracic cavity, necessitating urgent surgery to relieve the obstruction. After consultation with the surgeons, the procedure was converted to laparotomy.

The surgeon smoothly freed the diaphragm, revealing a diaphragmatic defect measuring about 12 × 10 cm. The gastric fundus, pancreatic tail, and spleen were found twisted and herniated into the thoracic cavity, together with the ileocecal region and the entire small intestine. The splenic flexure and part of

the transverse colon were also herniated into the thoracic cavity, with some herniated contents being gently pulled back toward the abdominal cavity. The pediatric patient's spleen measured approximately 15 cm. After routine entry into the abdominal cavity, the spleen could not be repositioned, so a partial incision of the diaphragm was made to reduce the spleen and gastric fundus. The thoracic surgeon placed a closed thoracic drainage tube on the left side. The pediatric patient's airway pressure improved markedly, decreasing to 33 cmH_2O. After completion of diaphragm patch repair and adequate lung expansion, oxygen saturation gradually increased, and heart rate and blood pressure progressively returned to normal. Ventilator parameters were then adjusted, norepinephrine dose was titrated down, and vasoactive agents were discontinued. After cessation of pneumoperitoneum, arterial blood gas analysis showed a $PaCO_2$ of 43 mmHg, PaO_2 of 150 mmHg, and SaO_2 of 97%.

Postoperatively, the patient was transferred to the ICU for observation and follow-up, with a favorable outcome. Tracheal extubation was performed within 4 hours after surgery, and follow-up at 12 and 24 hours showed stable vital signs with no reported discomfort. Routine anti-inflammatory, acid-suppressive, and analgesic therapy was administered postoperatively. The child recovered well and was discharged after 7 days. At one-month telephone follow-up, the general condition was good, with no other symptoms.

Clinical trial number: not applicable.

3. Discussion

3.1 Case summary and clinical significance

Spontaneous diaphragmatic hernia is rare in children and may present acutely with strangulation and severe cardiopulmonary compromise (1, 4, 8). We report a 14-year-old boy who developed sudden abdominal pain, vomiting, palpitations, and dyspnea after intense physical activity. Imaging demonstrated extensive herniation of abdominal viscera into the left thoracic cavity, with mesenteric edema, incomplete expansion of the left lung, and rightward displacement of the mediastinum. Emergency surgical intervention was required.

The acute onset after intense physical activity and the absence of an obvious diaphragmatic defect or structural weak point on preoperative imaging made the diagnosis challenging (6, 7). Previous pediatric reports have described spontaneous diaphragmatic rupture associated with congenital diaphragmatic eventration, suggesting that an underlying structural abnormality may contribute to spontaneous diaphragmatic hernia (8, 9). In our patient, extensive herniation and intestinal strangulation were accompanied by severe hypoxemia and hemodynamic instability, making anesthetic management particularly challenging. Pneumoperitoneum was poorly tolerated, whereas airway pressure and gas exchange improved rapidly after conversion to laparotomy and reduction of the herniated viscera. This clinical course suggests that mechanical compression from the herniated viscera contributed to the intraoperative respiratory deterioration.

3.2 Anesthetic Induction and Airway Management

Anesthetic induction was challenging because the patient presented with severe hypoxemia, hemodynamic instability, and a high risk of regurgitation and aspiration. Although preservation of spontaneous ventilation may be considered in patients with compromised respiratory function, the clinical condition of our patient made this approach difficult. Severe hypoxemia required reliable control of oxygenation and ventilation, while the risk of aspiration favored prompt airway control. Therefore, rapid sequence induction (RSI) was selected in this case.

Preoxygenation was performed with a face mask at 8 L/min for 5 min in a head-up/feet-down position, while positive-pressure ventilation before intubation was avoided. Tracheal intubation was then performed promptly to limit apnea time and further oxygen desaturation. Cricoid pressure was applied during intubation. A 6.5-mm reinforced endotracheal tube was inserted under video laryngoscopy and fixed at 17 cm from the incisors.

The choice of anesthetic agents should also be individualized according to the underlying condition, hemodynamic status, and respiratory reserve. Previous reports of spontaneous diaphragmatic hernia associated with severe coughing or physical activity have described the use of intravenous anesthesia (6, 14). In contrast, sevoflurane was used in a neonate with Ehlers–Danlos syndrome and a COL1A1 mutation, with careful airway and vascular management because of tissue fragility (13). These reports illustrate that anesthetic selection may vary with the underlying pathology and the patient's physiological status.

3.3 Anesthetic induction and airway management

The choice of induction technique is particularly important in patients with diaphragmatic hernia (10, 11). Preservation of spontaneous ventilation may be considered in patients with severe respiratory compromise, because positive-pressure ventilation may further impair venous return and lung expansion (10, 11). However, in patients with intestinal obstruction and a high risk of aspiration, rapid-sequence induction (RSI) may be preferred to facilitate prompt airway control (12). In our patient, severe hypoxemia, marked hemodynamic instability, and the need for urgent surgery favored RSI.

Preoxygenation was performed with a face mask at 8 L/min for 5 minutes in a head-up/feet-down position, while positive-pressure ventilation before intubation was avoided. Tracheal intubation was then performed promptly to limit apnea time and further oxygen desaturation. Cricoid pressure was applied during intubation as part of the aspiration-risk management strategy. A 6.5-mm reinforced endotracheal tube was inserted under video laryngoscopy and fixed at 17 cm from the incisors.

The choice of anesthetic agents should also be individualized according to the underlying condition, hemodynamic status, and respiratory reserve. Reported cases of spontaneous diaphragmatic hernia associated with severe coughing or physical activity have used intravenous anesthesia (6, 13). In contrast, in a neonate with Ehlers–Danlos syndrome and a COL1A1 mutation, sevoflurane was used, with

careful handling during airway and vascular procedures because of tissue fragility (14). Thus, anesthetic technique should be selected according to the underlying disease and the patient's real-time physiological state.

3.4 Intraoperative Deterioration and Its Management

Ventilation after intubation should be adjusted according to respiratory mechanics, oxygenation, and hemodynamic status (10, 11). In patients with markedly reduced lung compliance, pressure-controlled ventilation may help limit airway pressure, while PEEP may need to be adjusted cautiously (11). However, when respiratory dysfunction is mainly caused by mechanical compression from herniated abdominal contents, increasing ventilatory support alone may be insufficient to correct the respiratory abnormalities (10, 11).

In our patient, mechanical ventilation was initially performed in volume-control mode. After pneumoperitoneum was established, the patient developed tachycardia, hypotension, oxygen desaturation, increased airway pressure, and rising $EtCO_2$. Ventilation was switched to pressure-control mode, the inspiratory-to-expiratory ratio was adjusted from 1:2 to 1:1.5, FiO_2 was increased from 45% to 55%, and the respiratory rate was increased from 12 to 16 breaths/min, with PEEP maintained at 2–5 cmH_2O. Norepinephrine was administered at 0.03–0.05 μg/kg/min, together with fluid resuscitation, to maintain circulatory stability.

Despite these adjustments, the respiratory parameters did not improve substantially, and $EtCO_2$ continued to rise. The procedure was therefore converted to laparotomy. After reduction of the herniated viscera, diaphragmatic repair, and lung re-expansion, airway pressure decreased from 55 to 33 cmH_2O, accompanied by improvement in respiratory and hemodynamic status. After cessation of pneumoperitoneum, arterial blood gas analysis showed a $PaCO_2$ of 43 mmHg, PaO_2 of 150 mmHg, and SO_2 of 97%. The rapid improvement after reduction of the herniated viscera suggested that relief of mechanical compression was an important factor in restoring respiratory and circulatory function.

Hemodynamic monitoring should be adjusted according to the severity of circulatory compromise (10). In patients with shock or marked respiratory instability, invasive arterial monitoring allows continuous blood pressure monitoring and repeated arterial blood gas analysis (10). Adequate peripheral venous access is also important for the rapid administration of fluids and vasoactive drugs. Fluid therapy should be guided by the clinical condition, particularly in patients with bowel obstruction, third-space fluid loss, or impaired venous return, rather than by a fixed-volume strategy. Vasoactive support may be required when hypotension persists despite appropriate fluid resuscitation (10, 11).

Central venous catheterization may not be necessary in every pediatric patient with diaphragmatic hernia (10). It may be considered in patients with preoperative shock, anticipated prolonged vasoactive support, major bleeding risk, difficult peripheral venous access, or a need for central venous pressure monitoring (10, 15). When adequate peripheral access can be obtained and prolonged hemodynamic support is not anticipated, peripheral venous access combined with invasive arterial monitoring may be sufficient (10,

15). The choice of vascular access and hemodynamic monitoring should depend on circulatory status and surgical requirements (10, 15) (Table 1).

3.5 Tolerance to Pneumoperitoneum and Choice of Surgical Approach

Laparoscopic repair offers the advantages of less surgical trauma, faster recovery, and a clear operative field, but is more suitable for patients who are hemodynamically stable and without significant intestinal necrosis or perforation (16). In patients with severe hypoxemia, hypercapnia, or circulatory instability, pneumoperitoneum may further increase intra-abdominal pressure, elevate the diaphragm, reduce lung compliance, and impair venous return (10, 16). In such circumstances, open surgery may be more appropriate (10, 11, 16).

In our patient, even an insufflation pressure of 8 mmHg was poorly tolerated in the setting of severe cardiopulmonary compromise. Despite maintaining pneumoperitoneum at 8 mmHg, the patient developed marked increases in airway pressure and $EtCO_2$, accompanied by further hemodynamic deterioration. Respiratory abnormalities persisted despite adjustments in ventilatory and circulatory support, whereas airway pressure decreased rapidly after reduction of the herniated viscera. This finding suggests that mechanical compression from the herniated abdominal contents was an important contributor to the intraoperative respiratory deterioration. Therefore, in patients with severe pre-existing cardiopulmonary compromise, the physiological response may be more informative than insufflation pressure alone when assessing tolerance to pneumoperitoneum.

Thus, absolute insufflation pressure alone may not adequately reflect tolerance to pneumoperitoneum in patients with severe cardiopulmonary compromise. The choice of surgical approach should take into account changes in airway pressure, oxygenation, $EtCO_2$, and hemodynamic status rather than relying solely on a predefined pressure range. When deterioration persists despite appropriate anesthetic and circulatory support, conversion to laparotomy may be warranted to relieve mechanical compression and facilitate reduction of the herniated viscera (10, 16).

3.6 Postoperative management and complications

Because of the prolonged lung compression and bowel strangulation, postoperative surveillance should focus on pulmonary re-expansion, bowel viability, abdominal pressure, and recurrence (17, 18). Rapid re-expansion of a chronically compressed lung may be associated with re-expansion pulmonary edema, while reduction of a large volume of herniated viscera may increase intra-abdominal pressure (19). The viability of previously strangulated bowel should also be reassessed after reduction, as ischemic injury may persist despite restoration of bowel position (20). These considerations are particularly relevant in patients with extensive herniation and prolonged compression.

In our patient, extubation was performed within 4 hours after surgery, followed by observation in the intensive care unit. The postoperative course was uneventful, and the patient was discharged 7 days

after surgery. At 1-month follow-up, the patient remained well without evidence of recurrence or other significant complications.

3.7 Comparison with published cases and age-specific considerations

Published pediatric cases of spontaneous diaphragmatic hernia are scarce (4, 6, 8, 13). Reported triggers include severe coughing, intense physical activity, and underlying connective tissue disorders such as Ehlers–Danlos syndrome (6, 7, 14). In a neonate with COL1A1-associated classical Ehlers–Danlos syndrome, sevoflurane was used, with particular attention to tissue fragility during airway and vascular procedures (14). In contrast, intravenous anesthesia has been described in spontaneous diaphragmatic rupture after coughing or exertion (6, 13). The anesthetic approach may therefore vary with the underlying disease and the patient's respiratory and hemodynamic condition.

For traumatic diaphragmatic hernia in infants and young children, associated injuries such as hepatic or splenic rupture and pericardial compression may contribute to hemorrhagic shock and circulatory instability (15, 21). Induction agents should be selected according to the circulatory condition, while invasive monitoring and vascular access should be tailored to the severity of associated injuries (21). In these patients, associated trauma and limited physiological reserve may have a greater influence on anesthetic risk than the diaphragmatic defect itself (21).

In adolescents without major associated injuries, physiological reserve may be relatively preserved compared with younger patients with severe trauma (22). However, extensive herniation can still cause marked lung compression, mediastinal displacement, and impaired venous return (10, 22). Ventilation, fluid therapy, and vasoactive support should be adjusted according to the patient's respiratory and hemodynamic response, with careful assessment of tolerance to pneumoperitoneum (10, 11, 22) (Table 2). Our patient was 14 years old and had no known major underlying disease, but developed severe hypoxemia and hemodynamic instability because of extensive herniation and intestinal strangulation. Rapid sequence induction, invasive arterial monitoring, and vasoactive support were therefore required.

Adult and elderly patients more often have coexisting conditions such as hypertension or coronary heart disease and may have less physiological reserve (3). Anesthetic induction and fluid management consequently require greater caution, and invasive monitoring or postoperative ventilatory support may be considered according to the clinical condition (3). Younger patients generally have fewer comorbidities and greater physiological reserve, although severe hypoxemia and acute mechanical compression may still lead to rapid deterioration (3, 22). In our patient, the major anesthetic challenge was not an underlying cardiopulmonary disorder but the severe mechanical compression caused by the herniated abdominal contents.

Several aspects of perioperative management can be considered across age groups, particularly the assessment of pneumoperitoneum tolerance, invasive monitoring, and postoperative respiratory

support. Their application, however, should be adapted to the patient's physiological reserve and underlying disease. Flexibly integrating anesthetic principles from both age groups may help improve the safety of emergency surgery for spontaneous diaphragmatic hernia (Table 3).

Notably, even pneumoperitoneum at 8 mmHg was poorly tolerated in our patient, with marked increases in airway pressure and $EtCO_2$ accompanied by further hemodynamic deterioration. After conversion to laparotomy and reduction of the herniated viscera, respiratory and circulatory status improved rapidly. This temporal relationship supports a major contribution of mechanical compression to the intraoperative deterioration. In patients with extensive herniation and severe cardiopulmonary compromise, these real-time physiological changes may be more informative than age alone when deciding whether to continue pneumoperitoneum or convert to laparotomy.

3.8 Limitations

This report has several limitations. First, this was a single case, and the anesthetic strategy was individualized according to real-time physiological changes; the observations should therefore be interpreted as case-specific rather than general recommendations. Second, blood gases were not obtained at all clinically relevant time points, particularly after pneumoperitoneum and reduction of the herniated viscera, limiting assessment of dynamic changes in ventilation and metabolism. Third, vasoactive support was initiated after hemodynamic deterioration rather than before induction, so the potential benefit of pre-induction low-dose norepinephrine could not be determined. Finally, follow-up was limited to one month, so longer-term pulmonary function, recurrence, and late complications could not be assessed.

3.9 Conclusion

In this case of pediatric spontaneous diaphragmatic hernia with severe respiratory and hemodynamic compromise, anesthetic management was guided by real-time physiological changes. Rapid-sequence induction, careful ventilation, invasive hemodynamic monitoring, and cautious fluid and vasoactive management were used during emergency surgery. When respiratory and hemodynamic deterioration persisted despite appropriate anesthetic management and low-pressure pneumoperitoneum, the surgical approach was reassessed and converted to laparotomy, followed by rapid improvement. This experience suggests that persistent deterioration in a severely compressed patient may not be reversible by further adjustment of anesthetic parameters alone. Timely recognition of the mechanical component and relief of the underlying compression may therefore be important when determining whether to continue minimally invasive surgery or proceed to open repair.

Abbreviations

RSI
rapid sequence induction
PCV
pressure-controlled ventilation

$EtCO_2$
end-tidal carbon dioxide
PEEP
positive end-expiratory pressure
FiO_2
fraction of inspired oxygen
ICU
intensive care unit
CDH
congenital diaphragmatic hernia
CVP
central venous pressure
SIMV
synchronized intermittent mandatory ventilation.

Declarations

Ethics approval and consent to participate

This is a retrospective single case report. Formal ethics committee approval was not required by our institutional guidelines for de-identified case reports. Written informed consent was obtained from the patient's legal guardians.

Consent for publication

Written informed consent for publication of the clinical details and relevant clinical images was obtained from the patient's legal guardians.

Competing interests

The authors declare that they have no competing interests.

Funding

Lanzhou City Science and Technology Planning Project (2022-ZD-51); Research Fund Project within Gansu Provincial Hospital (21GSSYC-32); Science and Technology Project of Gansu Province (25 JRRA885).

Author Contribution

XX.Feng: Case collection, research design, funding acquisition; YQ.Zhao: Manuscript drafting; Y.Guo: Surgical participation, patient follow-up; CY.Wang: Assisted manuscript writing, figure and table production; T.Li., L.Wu., YJ.Hua: Manuscript critical revision; QF.Han: Surgical procedure participation; DQ.Ren: Corresponding author, overall supervision and final manuscript approval. All authors read and approved the final manuscript.

Acknowledgements

We gratefully acknowledge the support of Geenmedical, and the Home 424 for Researchers website for their valuable contributions to this work.

Data Availability

The data supporting the findings of this case report are contained within the article and its supplementary materials, where applicable. Any additional patient-level information should be handled in accordance with privacy and institutional requirements.

References

1. Darocki MD, Medak AJ. Spontaneous Diaphragmatic Hernia. Clin Pract Cases Emerg Med. 2018;2(3):244–6.
2. Bisgaard C, Rodenberg JC, Lundgaard J. Spontaneous rupture of the diaphragm. Scand J Thorac Cardiovasc Surg. 1985;19(2):177–80.
3. Lamture Y, Dubhashi SP, Shetty D. Spontaneous Acquired Diaphragmatic Hernia: Case Series and Review of Literature. J Emerg Trauma Shock. 2024;17(4):241–4.
4. Akbar A, Parikh DH, Alton H, Clarke JR, Weller PH, Green SH. Spontaneous rupture of the diaphragm. Arch Dis Child. 1999;81(4):341–2.
5. Kumar MS, Shaw SC, Devgan A. Non-traumatic rupture of eventration of diaphragm in a child. Med J Armed Forces India. 2018;74(3):290–3.
6. Fenner H, Memeti E, Taha S, Fornaro J, Scheiwiller A, Metzger J, et al. Spontaneous Diaphragmatic Rupture after Coughing: Report of a Case and Review of the Literature. Case Rep Surg. 2019;2019:1270195.
7. Yang YM, Yang HB, Park JS, Kim H, Lee SW, Kim JH. Spontaneous diaphragmatic rupture complicated with perforation of the stomach during Pilates. Am J Emerg Med. 2010;28(2):e2591–3.
8. Saha S, Bal HS, Sen S. Spontaneous rupture of a congenital diaphragmatic eventration in an infant. BMJ Case Rep. 2015;2015:bcr2015208634.

9. Gün F, Günendi T, Erginel B, Güler N, Celik A. Rupture of a congenital diaphragmatic eventration in a child: report of a case. Surg Today. 2011;41(12):1630–2.
10. Ito M, Terui K, Nagata K, Yamoto M, Shiraishi M, Okuyama H, et al. Clinical guidelines for the treatment of congenital diaphragmatic hernia. Pediatr Int. 2021;63(4):371–90.
11. Kunisaki SM, Desiraju S, Yang MJ, Lakshminrusimha S, Yoder BA. Ventilator strategies in congenital diaphragmatic hernia. Semin Pediatr Surg. 2024;33(4):151439.
12. Weiss M, Gerber AC. Rapid sequence induction in children -- it's not a matter of time! Paediatr Anaesth. 2008;18(2):97–9.
13. Zhu DY, Gao Q. Non-traumatic diaphragmatic rupture in children: A case report. Asian J Surg. 2024;47(11):4828–9.
14. Anand L, Munro MJ, Shetty A, Dean J, Pagan J, Campbell J. Diaphragmatic Hernia in a Newborn With COL1A1-Associated Classical Ehlers-Danlos Syndrome. Case Rep Genet. 2025;2025:5233998.
15. Kassie MT, Ayana MG, Abebe RB, Abebe BM. Case Report: Surgical challenges and insights in a child with a blunt left diaphragmatic and pericardial rupture and heart subluxation. Front Surg. 2024;11:1369255.
16. Eva I, Rosario V, Guglielmo R, Clarissa V, Federica LP, Emma C, et al. Laparoscopic surgery: A randomised controlled trial comparing intraoperative hemodynamic parameters and arterial-blood gas changes at two different pneumoperitoneal pressure values. Volume 81. Annals of Medicine & Surgery; 2022.
17. Mahfood S, Hix WR, Aaron BL, Blaes P, Watson DC. Reexpansion pulmonary edema. Ann Thorac Surg. 1988;45(3):340–5.
18. Macchini F, Raffaeli G, Amodeo I, Ichino M, Encinas JL, Martinez L, et al. Recurrence of Congenital Diaphragmatic Hernia: Risk Factors, Management, and Future Perspectives. Front Pediatr. 2022;10:823180.
19. Dalencourt G, Katlic MR. Abdominal compartment syndrome after late repair of bochdalek hernia. Ann Thorac Surg. 2006;82(2):721–2.
20. Bryski MG, Frenzel Sulyok LG, Kaplan L, Singhal S, Keating JJ. Techniques for intraoperative evaluation of bowel viability in mesenteric ischemia: A review. Am J Surg. 2020;220(2):309–15.
21. Ramos CT, Koplewitz BZ, Babyn PS, Manson PS, Ein SH. What have we learned about traumatic diaphragmatic hernias in children? J Pediatr Surg. 2000;35(4):601–4.
22. Winstead RC, Kumar V. A 15-Year-Old Female Presenting With Traumatic Diaphragmatic Hernia One Year After a Car Accident. Cureus. 2022;14(4):e24141.

Tables

Tables 1 to 3 are available in the Supplementary Files section.

Figures

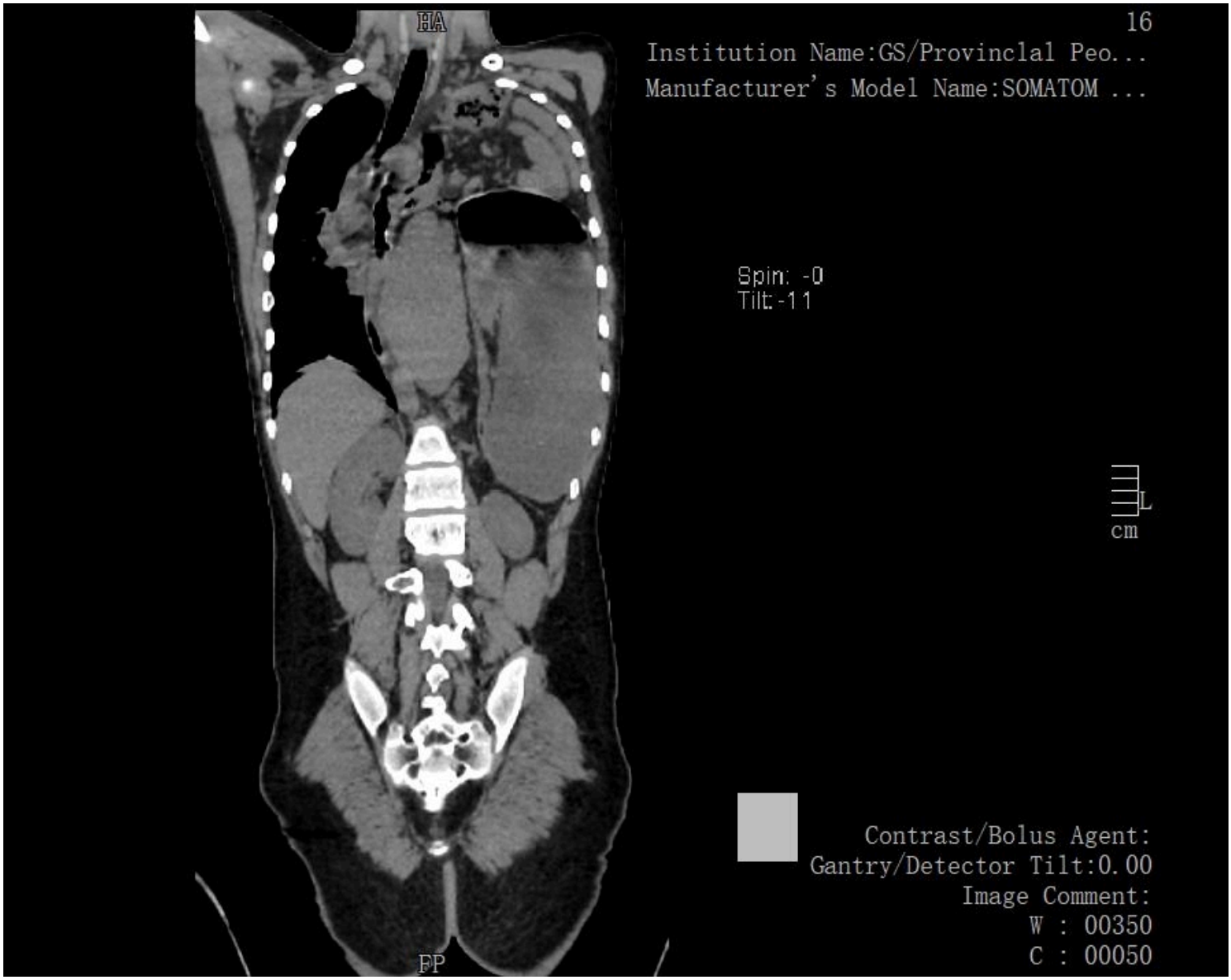

Figure 1

Computed tomography findings of strangulated diaphragmatic hernia.

Supplementary Files

This is a list of supplementary files associated with this preprint. Click to download.

- floatimage2.png
- floatimage3.png
- floatimage4.png
- floatimage5.png