Research Square

Preprints are preliminary reports that have not undergone peer review.
They should not be considered conclusive, used to inform clinical practice,
or referenced by the media as validated information.

Multi-Planar Reconstruction and 3D Volume Rendering as Tools of Anatomical Dissection and Morphometry on the Example of Cadaveric Study of Inferior Medial Genicular Artery

Julia Szopa
Medical University of Warsaw
Laura Fortuna
Medical University of Warsaw
Paweł Gębski
Medical University of Warsaw
Filip Lipiński
Medical University of Warsaw
Bogdan Ciszek
Medical University of Warsaw
Beata Ciszkowska-Łysoń
Life Institute
Robert Śmigielski
robert.smigielski@interia.com

Medical University of Warsaw

Research Article

Keywords: Computer Dissection, Genicular Anastomosis, Dissection Technique, Inferior Genicular Arteries

Posted Date: October 21st, 2026

DOI: https://doi.org/10.21203/rs.3.rs-11272002/v1

License: This work is licensed under a Creative Commons Attribution 4.0 International License.
Read Full License

Additional Declarations: No competing interests reported.

Version of Record: A version of this preprint was published at Surgical and Radiologic Anatomy on November 11th, 2026. See the published version at https://doi.org/10.1007/s00276-026-04046-y.

Abstract

Cadaveric dissection is a traditional method used to reveal deep-seated anatomical structures; however, it is inherently time-consuming and irreversible, preventing the correction of procedural errors. To address these limitations, this study presents a novel computer-assisted dissection framework designed to accelerate workflow, allow error mitigation, and enable repeatable analysis of a single specimen.

Four independent investigators performed virtual dissections of the inferior medial genicular artery across two DICOM viewing platforms: RadiANT DICOM Viewer 2025.2 (64-bit) and Horos v4.0.0 RC5. Morphometric measurements were recorded at predefined reference points corresponding to arterial branching sites. Inter-observer variability was evaluated, and the resulting dataset was validated against multiplanar reconstruction (MPR) metrics—the standard radiological benchmark for vascular assessment.

Statistical analysis revealed no significant difference between three-dimensional volume rendering (3D VR) and MPR in assessing vessel dimensions for structures with a diameter exceeding $0.950\,\mathrm{mm}$ ($d_{\mathrm{MPR}} = 0.950\,\mathrm{mm}$). For vessels > 0.95 mm, 3-D VR and MPR yielded no statistically significant difference (p = 0.086), a strong Pearson correlation (r = 0.971), and a Bland-Altman mean bias of − 0.03 mm (95% LoA: − 0.14 to + 0.07 mm). Furthermore, morphological consistency was maintained regardless of vessel caliber.

The findings demonstrate that the integration of 3D VR and MPR modalities offers a highly reproducible, non-invasive tool for both educational and research applications in vascular analysis. Moreover, these measurements exhibit strong stability across different software platforms and operators, showing an absence of systematic bias with only minor variations attributable to human error or minor misalignment.

Aim of study

Establishing the credibility of 3D VR as a tool for anatomical assay creates a possibility of using simpler, more available, efficient and reusable techniques for education, research and clinical practice.

1. Introduction

Cadaveric dissection constitutes the fundamental method of identifying anatomical structures, having allowed for significant progress in understanding what is beyond the surface. However, with development of new technologies, a fresh approach should be applied to exploring the human body to overcome limitations that come with already established methods such as the irreversibility of alterations, scarce visibility of some structures, postmortem autolysis or limited availability of cadavers. The following paper proposes the validation of a digital dissection based on 3D volumetric computed tomography images as a reliable method of identifying vascular structures. The specimen used for this exploration is a postmortem scan of a knee which was analyzed in a double-blind trial. Morphology of

inferior medial genicular artery was analysed and correlated with the dissected fresh-frozen specimen. Morphometric measurements completed in 3D Volume Rendering (3D VR) were compared to Multi-Planar Reconstruction (MPR) which is a golden standard in radiology [9], [13] and was therefore treated as a reference for the acquired results. Establishing the credibility of 3D VR as a tool for anatomical assay creates a possibility of using simpler, more available, efficient and reusable techniques for education, research and clinical practice. The inferior medial genicular artery (*a. inferior medialis genus*) is a branch of the popliteal artery that commonly descends from the level below the articular line. It runs along the inferior part of medial tibial condyle underneath the tibial collateral ligament providing arterial supply to areas such as interior of tibia, posterior wall of joint capsule or medial meniscus, emptying into the genicular anastomosis (*rete articulare genus*). It also extends to the popliteus muscle and tendons of sartorius, gracilis and semitendinosus muscles [1].

2. Methods

2.1 Specimen

One fresh frozen cadaver was used, the donor was a Caucasian female. The cause of death was Hypertensive Heart Disease with Heart Failure. The donor also had Type II Diabetes and smoked cigarettes for 25 years.

2.2 Specimen Preparation

The frozen specimen was thawed in a warm freezer then at room temperature. Once the cadaveric specimen was thawed, the superficial femoral artery was cannulated using an appropriately sized angiocatheter. The arterial system of the lower extremity was slowly flushed with room-temperature normal saline using a manual syringe until venous outflow was observed and returned clear. Next, a solution containing: red acrylic paint, 150 ml latex, 350 ml Barium-based contrast per 500 ml mixture was prepared and injected into the cannulated superficial femoral artery using a manual syringe under slow, constant manual pressure to allow for the best perforation of small arteriole beds. Specimen filling was continued until there was visible reddening of the skin, indicating that smaller arteriole branches were perfused. Once adequately perfused, the specimen was sent to computed tomography.

2.3 Computed Tomography

The perfused specimen was then prepared to undergo computed tomography (CT). It was laid down in full extension on a diagnostic table and secured with duct tape. The specimen underwent scout imaging Siemens Healthineers SOMATOM ON TOP 64 [width of slice – 0.60mm] and 128 slice to obtain an overview of the major vessels and was frozen after the scan. Digital Imaging and Communications in Medicine images from each CT scan were imported into an image processing application RadiANT DICOM Viewer 2025.2(64.bit)(running on Windows) and Horos v4.0.0 RC5 DICOM viewer (running on MacOS) to produce a 3-dimensional (3D) model of bone and vascular anatomy.

2.4 3D “Dissection” and Measurement

This stage was performed by two independent teams of two people, producing separate results, unaware of the others' results. The first team used RadiANT DICOM Viewer 2025.2(64.bit) and the second Horos v4.0.0 RC5 DICOM viewer. The vascularization of the genicular area was visualized using 3D VR, the above-mentioned softwares were used to remove superficial tissue layers and expose the inferior medial genicular artery and its branches. Nineteen (19) points were arbitrarily selected in the branching of the artery and measured in 3D VR and MPR. The points were selected on the digital programme and on the specimen. The angle at which the results were measured has been established in order to avoid inter-observer error. Each researcher performed the measurements independently of each point, then the average of each measurement was taken. Equally on the 3D VR and MPR the points were measured by digital calipers. Measurements of each branch were performed at maximum magnification to minimize the potential for error and pixel loss.

2.5 Anatomical Dissection Technique

After thawing the specimen at room temperature, a sharp dissection of skin, subcutaneous tissue, fascia, and the gastrocnemius-soleus muscle complex was performed to isolate the popliteal artery. At this point, the popliteal artery and vein were divided by incising their common sheath. Once the popliteal artery was isolated, careful blunt dissection in the distal direction was performed to isolate and expose all the main branches of the popliteal artery, whilst the focus was on inferior medial genicular artery, from which all the branches were dissected. Once the genicular arteries were isolated, careful dissection was carried out toward the medial joint line either proximally or distally, dependent on the best visual planes for appropriate dissection. The focus was on isolating all branches of the inferior medial genicular artery which were dissected down to the genicular anastomosis. The specimen was dissected by an experienced orthopedic surgeon and anatomist.

2.6 Statistics and Analysis

All variables were quantitative. A preliminary analysis of the results was performed using descriptive statistics. The normality of the distributions was assessed using the Shapiro-Wilk test. All variables analyzed followed a normal distribution ($p > \alpha$); therefore, parametric tests were used for further analysis. Measurements of corresponding points obtained using the two software packages were compared. Differences between measurements obtained using the two systems were assessed using a paired-samples t-test, taking into account the test’s assumptions (normal distribution of differences). To achieve the main objective, the results obtained using the two measurement methods (3D-VR and MPR) were compared using a paired-samples t-test.

The agreement between the two methods was assessed based on: the extent of bias, the 95% limits of agreement, outliers, and the proportional bias using Bland-Altman analysis. All analyses were performed using the Statistica 13.3 statistical software package at a significance level of $\alpha = 0.05$.

3. Results

Average diameters based on four independent measurements (two in Horos, two in RadiAnt) were calculated for every point of measurement (separately for 3D VR and MPR) Percentage error ($\%err\ [\%] = \frac{|d_{3D-VR} - d_{MPR}|}{d_{MPR}} \times 100\%$) was calculated with MPR used as a reference and plotted against average diameter measured in MPR, as shown in Fig. 4. The level of 10% percentage error was set as an acceptable maximum. Based on this limit, the accuracy threshold was established at diameter d_{MPR}=0.950 mm. This threshold represents the apparent technological limitations of the methodology, namely the insufficient resolution of the CT scan for measurement of structures of this size, which is further explained in the discussion section. Therefore, the points below the accuracy threshold were excluded from later analysis (9 points).

Comparisons of the mean results obtained for the two evaluation software packages (RadiAnt and Horos), performed using a test for a paired-samples t-test showed no statistically significant differences between these software packages for samples acquired using both the 3D-VR and MPR methods. In both analyses, the p-value was p = 0.1110 for 3D-VR and p = 0.4018 for MPR (Table 1).

Table 1. Paired-samples comparisons and Pearson correlations of 3D-VR and MPR measurements obtained using RadiAnt (Rad) and Horos (Hor).

	Mean [mm]	SD [mm]	Difference [mm]	t	p	-0,95Cl	+0,95Cl	Correlation r
3D-VR_mean	1,284	0,163						0,971
MPR_mean	1,251	0,197	0,034	1,929	0,0857	-0,006	0,073	
MPR(Rad)	1,268	0,192						0,842
MPR(Hor)	1,235	0,217	0,033	0,879	0,4018	-0,051	0,117	
3D-VR(Rad)	1,322	0,194						0,727
3D-VR(Hor)	1,247	0,157	0,075	1,767	0,111	-0,021	0,171	

As part of the assessment of the agreement between the 3D-VR and MPR methods, a comparison of the mean measurement values obtained using both methods was performed using a paired-samples t-test. No statistically significant difference was found between the means of the two methods (p = 0.0857) (Table 1). Furthermore, Pearson's linear correlation coefficient showed a strong positive correlation between the variables (r = 0.971) (Table 1).

To assess the agreement between the two methods, a Bland–Altman analysis was performed. Bias, which is a mean difference between MPR and 3D-VR, Lower LoA (Lower Limit of Agreement), and Upper LoA were calculated.

The Bland–Altman analysis showed a mean bias between the MPR and 3D-VR measurements, amounting to approximately − 0.03 mm. The lower and upper 95% limits of agreement were approximately − 0.14 mm and 0.07 mm, respectively. All observations fell within the 95% limits of agreement (Fig. 4).

4. Discussion

Methodology described in this paper is supported by previously done studies. In a 2020 study [7] fresh-frozen cadavers of lower extremities were determined as viable specimen for vascular research, while in another paper [4] the postmortem CT angiography was ruled as useful for anatomical analysis with a 2016 study determining barium-based contrast as preferred for vascular examination [8]. The color injection method was also previously successfully used on lower extremities for the purpose of mapping inferior medial genicular arteries [5]. Regarding the goal of the study, past attempts revolved around introducing computed tomography as a valuable tool for education. Previous studies describing the morphology of genicular blood supply have also employed this technique using both fresh frozen dissection as well as 3D VR obtained in computed tomography [14]. However, in this research paper MPR is additionally used to evaluate the vascularization with a high precision.

The key finding of the presented paper is that 3D Volume Rendering (VR) is a reliable method of visualisation of the vascular architecture of fresh-frozen cadavers. The measurements extracted from 3D VR are further supported by the MPR image recognised in medical practice as a credible reference. All three techniques (fresh frozen dissection, MPR, 3D VR) proved to be consistent in showing the morphology and morphometry of the vascularization of the knee. 3D volume rendering is assessed mostly as a significant tool in visual depiction of the vessel morphology due to its high consistency with the cadaver photography. 3D VR was morphometrically consistent with MPR at larger vessel diameters (> 0.950 mm). Using these tools allows for a very precise anatomical dissection which is easy to learn, convenient, cheap and, most importantly, reversible - a single specimen can be dissected in a number of ways allowing for visualisation of different structures without the permanent destruction of tissues.

The cadaveric specimen and computed tomography exhibit significant similarities in the appearance of the inferior medial genicular artery. The popliteal artery is removed on the cadaver therefore only the medial view of the inferior medial genicular artery was analyzed. In both images the vessel is identified on the similar level. It curves into a soft “W” with the branch to the medial meniscus in the middle, then descends and bifurcates into two parallel arteries. All major branches overlap in both images including even microarteries diverging from the branch to the medial meniscus, although not all of them appear entirely on the 3D due to the increasingly narrower diameter. Eventual distortions between two images may be related to the fisheye effect on the photo of the cadaver, which would account for the divergence on the sides but not in the middle. The difference in the position of superior portion of the largest branch of the inferior medial genicular artery could be explained by the fact that it lays on the medial meniscus which is a mobile tissue due to which the vessels can be repositioned when moved unlike those fixed to the tibia. However, it is important to note that there are no prominent arteries in the 3D volumetric image

which are not reflected on the cadaver, implying that eventual disparities stem from the inefficiency of the processing system rather than actual discrepancy between pictures of the specimen. The continuous similitude of the physically dissected inferior medial genicular artery with its computed tomography scan supports the claim that 3D volumetric image can be used as a viable tool for anatomical exploration.

Both 3D VR and MPR modalities allow for measurements of the visible structures. This study revealed that 3D VR can match MPR in terms of effectiveness and precision up to a limit of d_{MPR}=0.950 mm (measured in MPR). Below this threshold, significant divergence between these methods was observed (%err > 10%). As the diameter values approached 0.600 mm (measured in MPR), the percentage error values climbed exponentially, reaching as much as 60%. Thus, a cut-off threshold for accurate measurement was set at d_{MPR}=0.950 mm diameter measured in MPR. Only the measurement points with diameter of d_{MPR}=0.950 mm or wider (10 points) were labeled as relevant and included in the statistical analysis. The comparison between 3D VR and MPR measurements revealed that, apart from the percentage error being below 10%, the differences between these modalities are not statistically significant ($p > 0.05$, Student's T-test). Additionally, the values obtained in 3D VR and MPR showed a Pearson's Linear Correlation Coefficient $r = 0.971$, suggesting a very strong correlation between them. Hence, it can be concluded that above the set accuracy threshold of 0.950mm object size, 3D VR is a precise tool for morphometric measurement, comparable to MPR.

The inaccuracies below the set accuracy threshold can be explained by the partial volume effect - at such a small vessel size, particular voxels contain the surrounding tissues, apart from the contrasted vessels, causing the signal from these voxels to be distorted [18]. This could have led to inaccuracies in the 3D Volume Rendering, as well as "spill-out" effect or "blooming artifact" in MPR, where nearby voxels were contaminated by the strong signal from the small vessel [11]. Therefore, in MPR it was impossible to accurately establish the true boundary of the vessel, greatly increasing the risk of under- or overestimation of the diameter. In future studies, ultra-high resolution CT could be utilized (such as 0.3mm slice width) to allow for accurate measurements of vessels below d_{MPR}=0.950 mm diameter in both 3D VR and MPR. Moreover, mathematical techniques of minimizing the significance of "blooming artifact" could be used, such as those proposed by Mololi S et al., 2018. Employing them would help decrease the risk of inaccurate measurement in MPR.

The dimensions of the vessels were also consistent between both DICOM viewers (Horos and RadiAnt). The difference between the values obtained in Horos and RadiAnt in 3D VR and MPR modality were insignificant statistically ($p > 0.05$ Student's T-test). Occasional discrepancies could be attributed to human error, such as faulty angle of measurement. Therefore, it can be concluded that both of these accessible DICOM viewers can be used for visualisation and morphometric measurement of vessels with a high degree of precision above the mentioned accuracy threshold of d_{MPR}=0.950 mm.

Using MPR as a reference method rather than the actual specimen, ensured that the size of the structures was not altered due to repeated freeze - thaw cycles that the specimen underwent and the following shrinkage and destruction. The CT was done before the repeated freezing, thus the tissues

including the investigated vessels were more preserved and intact in 3D VR and MPR images [19]. Another potential problem that was avoided could have been the desiccation of tissues. During the dissection, material was exposed to air for prolonged periods of time, often multiple hours over the course of a few days, leading to the alternation of the cadaver tissue due to inevitable loss of moisture [16].

5. Conclusions

Three-dimensional visualization via 3D volume rendering represents an accurate and reliable imaging modality for assessing the vascular anatomy of the knee, demonstrating a high degree of correspondence with post-mortem photographic specimens. For vessels exceeding d_{MPR}=0.950 mm in diameter, spatial measurements obtained through 3D VR closely align with multi-planar reconstruction (MPR) - the established clinical standard. Below this d_{MPR}=0.950 mm threshold, however, significant measurement discrepancies emerge. These inaccuracies are primarily attributable to the physical resolution limits of the computed tomography (CT) scanner and the occurrence of the blooming artifact. The integration of CT and DICOM processing tools facilitates repeatable, precise, and cost-effective anatomical evaluations. Notably, digital tools permit non-destructive, virtual "dissections" of a single specimen without compromising tissue integrity. In contrast, physical cadaveric preparation - including air-drying and repeated freeze-thaw cycles - induces structural deformations in the tissue. Furthermore, optical distortions such as the "fisheye" effect can introduce discrepancies along the periphery of photographic frames. Finally, measurements derived from 3D VR display high inter-operator and cross-platform stability across diverse DICOM viewing applications, showing an absence of systematic bias and only minor variance secondary to human alignment error.

Declarations

Ethics statement

All procedures involving human donor material were performed in compliance with relevant laws and institutional guidelines. While alive, the body donors had given their informed and written consent to the post-mortem donation of their tissues for research and training. The privacy rights of the donors were observed throughout.

Author Contribution

Julia Szopa: Writing – review & editing, Writing – original draft, Visualization, Investigation, Conceptualization. Laura Fortuna: Writing – review & editing, Writing – original draft, Visualization, Investigation, Conceptualization. Paweł Gębski: Writing – review & editing, Writing – original draft, Visualization, Investigation, Conceptualization. Filip Lipiński: Writing – review & editing, Writing – original draft, Visualization, Investigation, Conceptualization. Robert Śmigielski: Writing – editing, Supervision,

Funding acquisition. Bogdan Ciszek: Writing - editing, Supervision.Beata Ciszkowska-Łysoń - Radiological Consultation.

Acknowledgement

The authors wish to sincerely thank those who donated their bodies to science so that anatomical research could be performed. Results from such research can potentially improve patient care and increase mankind's overall knowledge. Therefore, these donors and their families deserve our highest gratitude. The authors would also like to thank Piotr Wójcik, who is the author of the photographs used in this paper.

Data Availability

All data supporting the findings of this study are available within the paper and from the corresponding author upon request.

References

1. Bochenek A, Reicher M (2022) Anatomia człowieka. Tom 3. Warszawa, PZWL
2. Callese T, Cusumano L, Redwood K, Genshaft S, Plotnik A, Stewart, Jessica, Padia, Siddharth (2023) Classification of Genicular Artery Anatomic Variants Using Intraoperative Cone-Beam Computed Tomography. Cardiovasc Interventional Radiol 46. 10.1007/
3. Doomernik DE, Kruse RR, Reijnen J, Kozicz MP, T. L., Kooloos M, J. G (2016) A comparative study of vascular injection fluids in fresh-frozen and embalmed human cadaver forearms. J Anat 229(4):582. https://doi.org/10.1111/joa.12504
4. Grabherr S, Djonov V, Yen K, Thali MJ, Dirnhofer R (2007) Postmortem angiography: Review of former and current methods. Am J Roentgenol 188(3):832–838. https://doi.org/10.2214/AJR.06.0787
5. Hirtler L, Ederer M, Faber M, Weninger P (2016) The inferior medial genicular artery and its vascularization of the pes anserinus superficialis: A cadaveric study. Indian J Orthop 50(6):677. https://doi.org/10.4103/0019-5413.193476
6. Iacoponi N, Giacomelli S, Turillazzi E, Paolo MD (2026) The Shrinking Blind Spot: How Freeze–Thaw Obscures Microscopic Evidence of Ante-Mortem Ecchymosis. Diagnostics 16(3):419. https://doi.org/10.3390/diagnostics16030419
7. Jansen MM, Hazenberg B, E. V., Bleys W, L. A (2020) Feasibility of fresh frozen human cadavers as a research and training model for endovascular image guided interventions. PLoS ONE 15(11):e0242596. https://doi.org/10.1371/journal.pone.0242596

8. Kingston MJ, Perriman DM, Neeman T, Smith PN, Webb AL (2016) Contrast agent comparison for three-dimensional micro-CT angiography: A cadaveric study. Contrast Media Mol Imaging 11(4):319–324. https://doi.org/10.1002/cmmi.1695
9. Leach JR, Zhu C, Mitsouras D, Saloner D, Hope MD (2021) Abdominal aortic aneurysm measurement at CT/MRI: potential clinical ramifications of non-standardized measurement technique and importance of multiplanar reformation. Quant Imaging Med Surg 11(2):823–830. 10.21037/qims-20-888
10. Molloi S, Johnson T, Lipinski J, Ding H, Hubbard L (2018) A phantom based evaluation of vessel lumen area quantification for coronary CT angiography. Int J Cardiovasc Imaging 35(3):551. https://doi.org/10.1007/s10554-018-1452-8
11. Pack JD, Xu M, Wang G, Baskaran L, Min J, Man BD (2022) Cardiac CT blooming artifacts: Clinical significance, root causes and potential solutions. Visual Comput Ind Biomed Art 5:29. https://doi.org/10.1186/s42492-022-00125-0
12. Park D, Park EA, Jeong B, Lee YS, Lee W (2024) Quantitative analysis of blooming artifact caused by calcification based on X-ray energy difference using computed tomography. Sci Rep 14(1):11539. https://doi.org/10.1038/s41598-024-61187-z
13. Siepmann T, Barlinn K, Floegel T, Barlinn J, Pallesen LP, Puetz V, Kitzler HH (2021) CT Angiography Manual Multiplanar Vessel Diameter Measurement vs. Semiautomated Perpendicular Area Minimal Caliber Computation of Internal Carotid Artery Stenosis. Front Cardiovasc Med 8:740237. 10.3389/fcvm.2021.740237
14. Śmigielski R, Azua E, Gursoy S, Khan ZA, Mameri ES, Ciszkowska-Łysoń B, Ciszek B, Hevesi M, Piękoś J, Zielińska A, Zarins B, Chahla J (2024) A Novel Description of Medial Meniscus Vascularization: A Multicenter Study Introducing the Medial Meniscal Artery. Am J Sports Med. 2024;52(14):3551–3560. 10.1177/03635465241291802
15. Tohka J (2014) Partial volume effect modeling for segmentation and tissue classification of brain magnetic resonance images: A review. World J Radiol 6(11):855. https://doi.org/10.4329/wjr.v6.i11.855
16. Travers B, Hite A, Kalthoff R, Ray O, Gould D (2020) Techniki konserwacji zwłok ludzkich podczas długotrwałej sekcji na stołach z opadającym strumieniem powietrza w laboratorium anatomii makroskopowej. Czasopismo FASEB 34:1–1. https://doi.org/10.1096/fasebj.2020.34.s1.03077
17. Zimmerman SL (2015) Overestimation of coronary artery stenosis due to calcified plaque. In S. L. Zimmerman & E. K. Fishman (Eds.), Pearls and Pitfalls in Cardiovascular Imaging: Pseudolesions, Artifacts, and Other Difficult Diagnoses (pp. 93–95). chapter, Cambridge: Cambridge University Press
18. Erlandsson K, Buvat I, Pretorius P, Thomas B, Hutton B (2012) A review of partial volume correction techniques for emission tomography and their applications in neurology, cardiology and oncology. Physics in medicine and biology. 57. R119-59. 10.1088/0031-9155/57/21/R119

19. Giovannini E, Bonasoni P, Bardaro M, Russello G, Carretto E, Zerbini A, Gargano G, Pelotti S (2023) Postmortem histological freeze–thaw artifacts: a case report of a frozen infant and literature review. Forensic Sci Med Pathol 20:1412–1419. 10.1007/s12024-023-00752-w

Figures

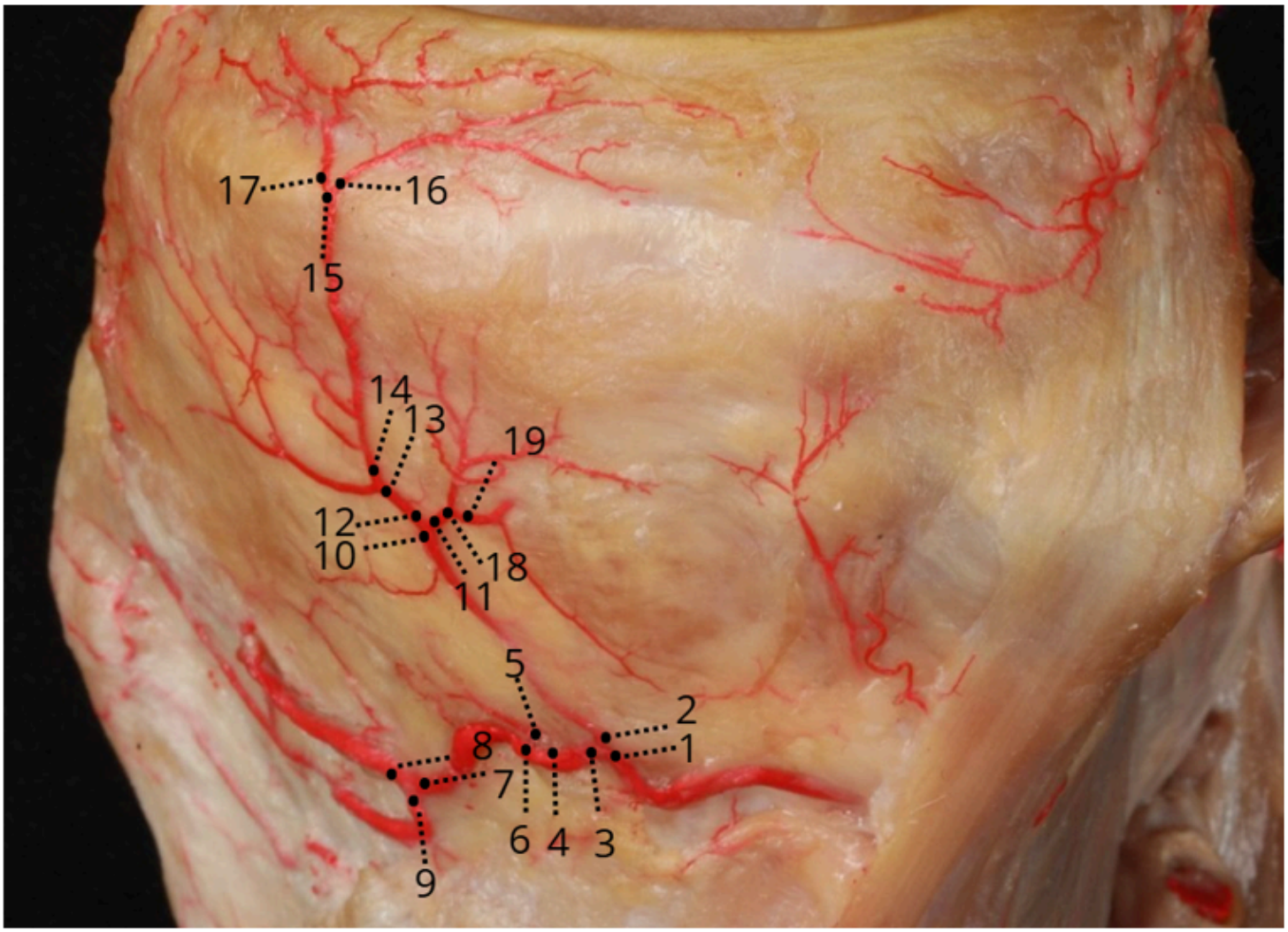

Figure 1

Dissected inferior medial genicular artery on a cadaveric specimen, annotated with points of measurement.

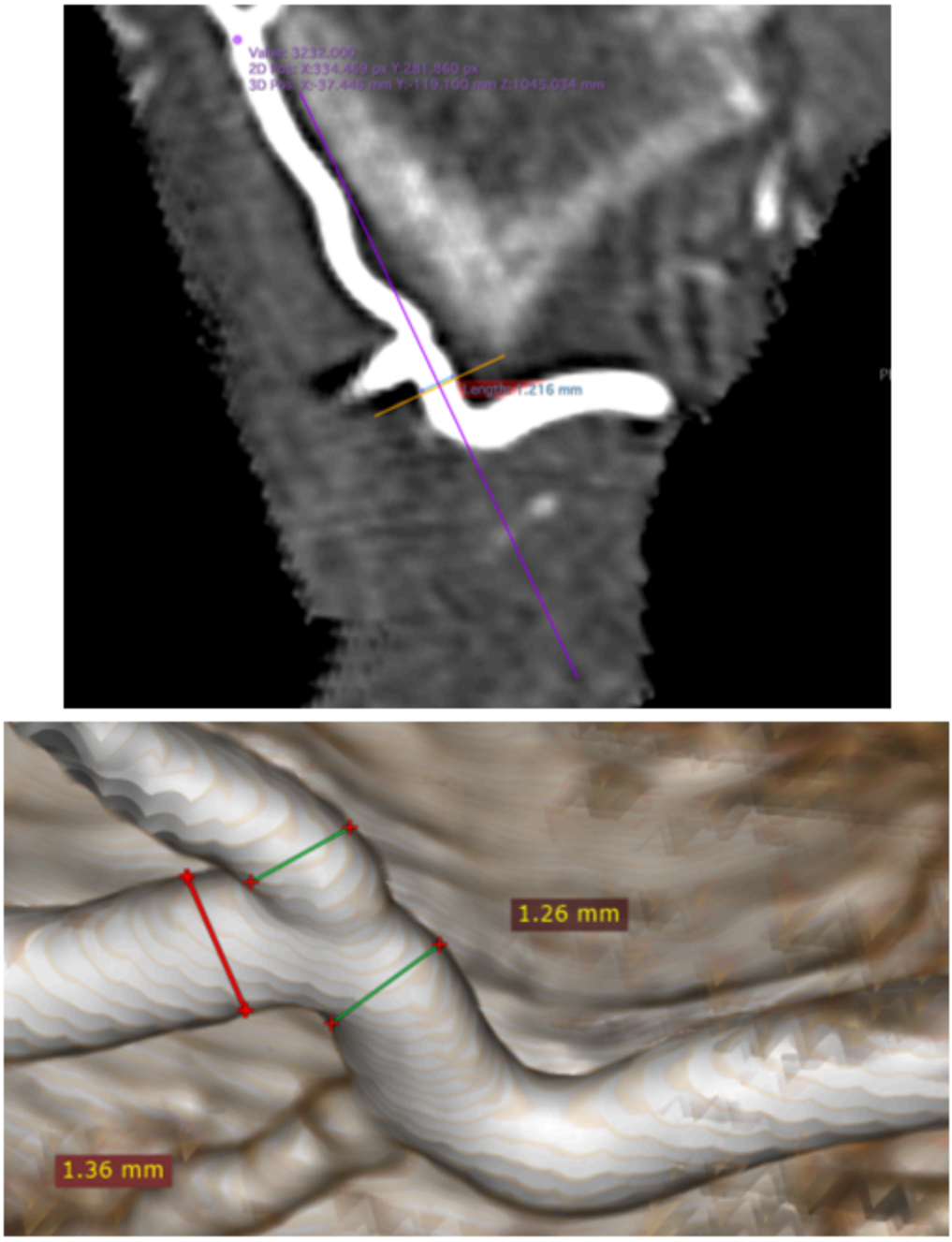

Figure 2

(a). Measurement on MPR image, visualised in Horos. Figure 2(b) Measurement on 3D volumetric image, visualised in RadiANT.

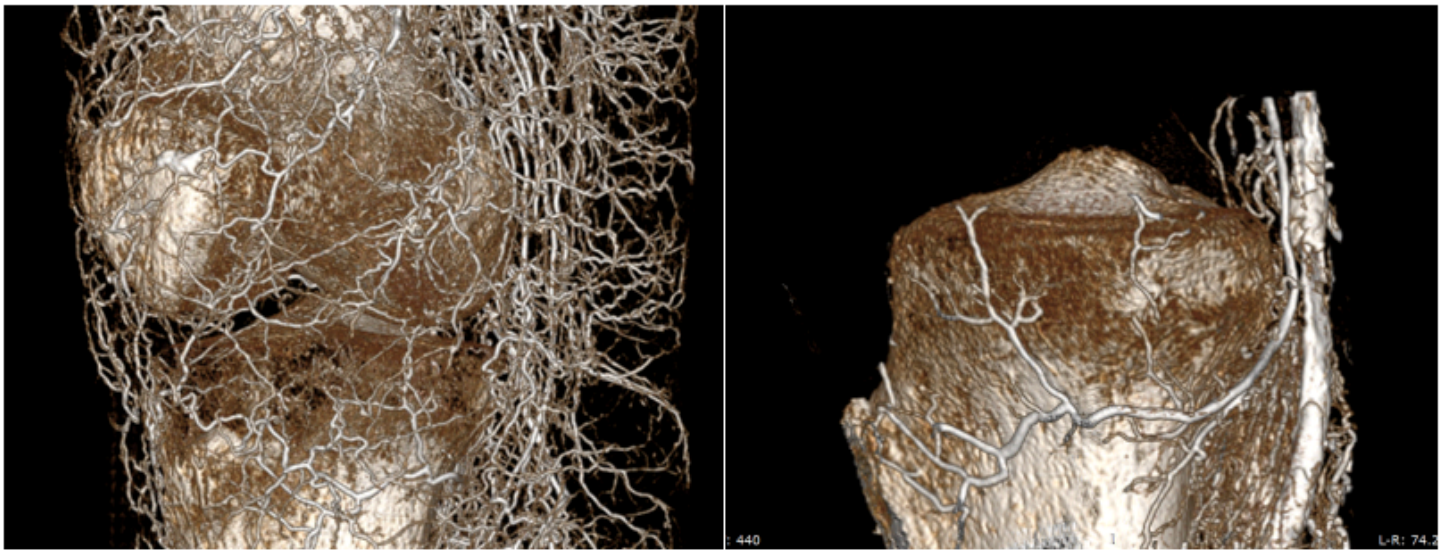

Figure 3

(a). (left) Screenshot before digital dissection of inferior medial genicular artery on a 3D volumetric CT, visualised in RadiANT. Figure 3(b). (right) Screenshot after digital dissection of inferior medial genicular artery on a 3D volumetric CT, subcutaneous tissue and superficial blood vessels were removed, the femur was also removed, the same specimen as figure 2, visualised in RadiANT.

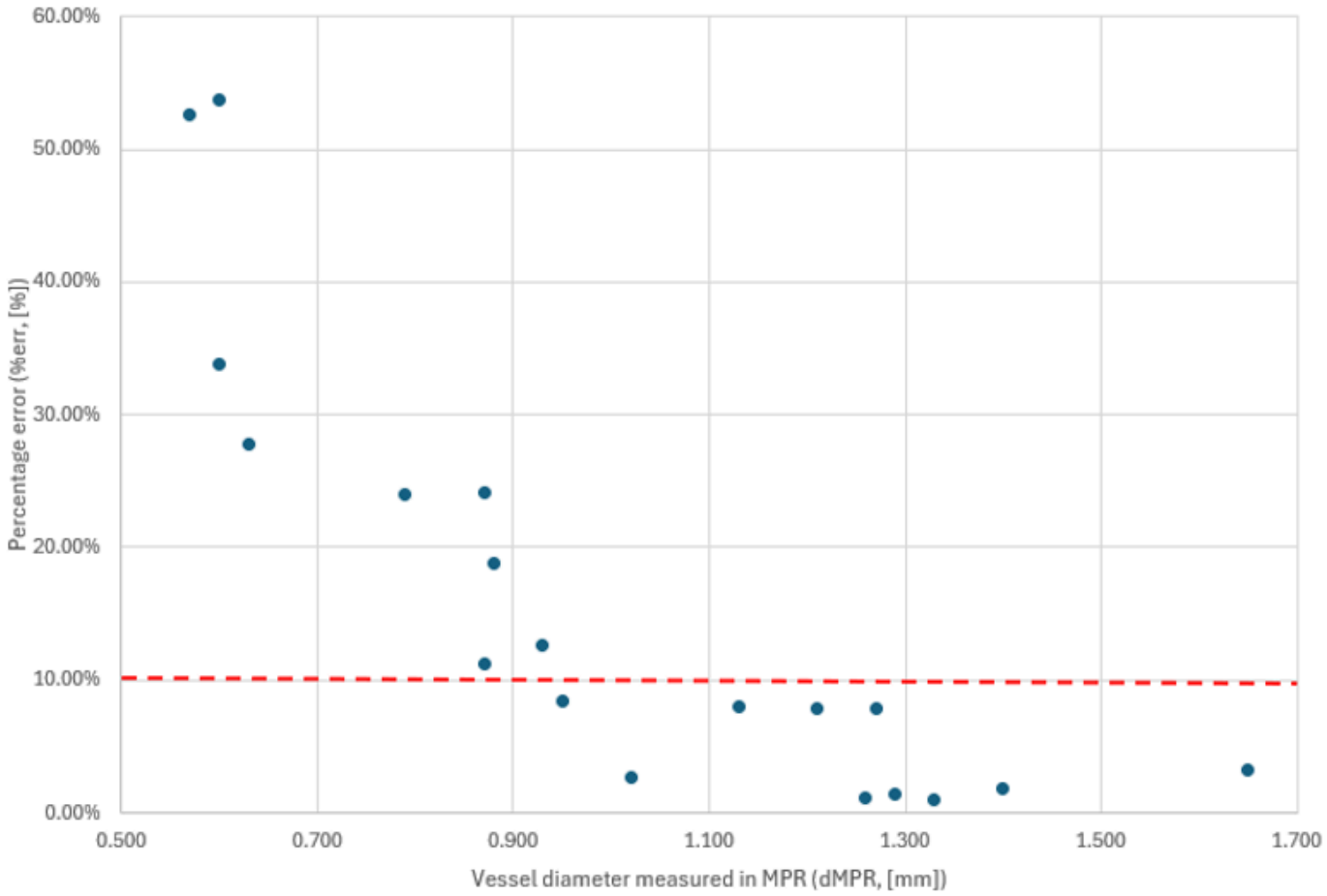

Figure 4

Scatter diagram showing the dependence of percentage error between 3D VR and MPR measurement (%err, [%]) on the vessel diameter measured in MPR (dMPR, [mm]). The red horizontal line indicates a percentage error level of %err = 10.00%.

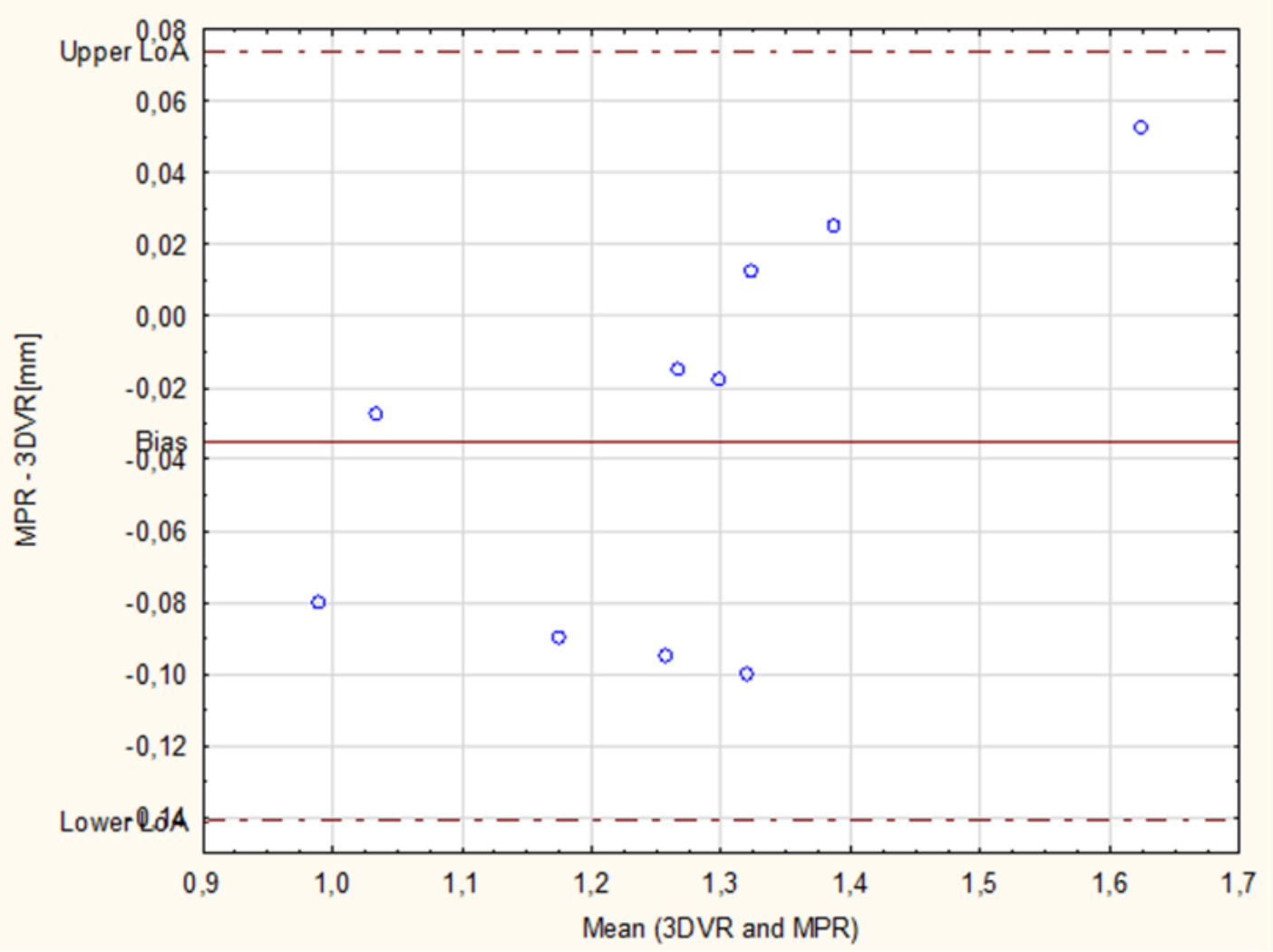

Figure 5

Bland–Altman plot showing agreement between three-dimensional volume-rendering (3D-VR) and multiplanar reconstruction (MPR) measurements. Differences were calculated as MPR minus 3D-VR. The solid line represents the mean bias, and the dashed lines represent the lower and upper 95% limits of agreement.

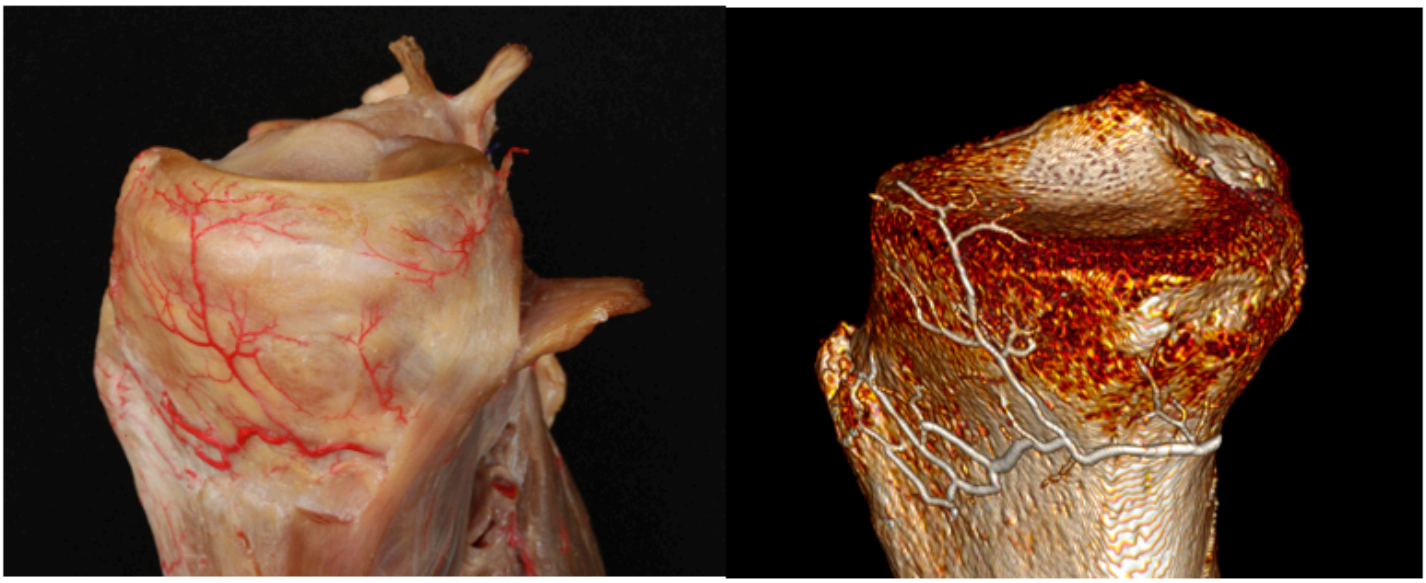

Figure 6

(a). (left) Photography of the dissected cadaver showing the inferior medial genicular artery. Photo by Piotr Wójcik, used with permission. Figure 6(b). (right) Screenshot of a digitally dissected inferior medial genicular artery on a 3D volumetric CT image of the same specimen (fibula was removed) visualised in Horos.