Research Square

Preprints are preliminary reports that have not undergone peer review.
They should not be considered conclusive, used to inform clinical practice,
or referenced by the media as validated information.

TMJ function and skeletal stability in skeletal Class II patients after orthognathic surgery: a retrospective cohort study

Xinyi Deng
Sichuan University
Zizhou Ye
Sichuan University
Jialu Li
Sichuan University
Xinyu Chen
Sichuan University
Haozhe Chen
Sichuan University
Ruicheng Liu
Chengdu Tianqi Additive Manufacturing Co., Ltd.
Liping Wu
Chengdu Tianqi Additive Manufacturing Co., Ltd.
Nan Jiang
Sichuan University
Songsong Zhu
Sichuan University
Pinyin Cao
Sichuan University
Rong Ren
dr_renrong@163.com
Sichuan University

Research Article

Keywords: Orthognathic surgery, skeletal Class II patients, skeletal instability, temporomandibular joint dysfunction, condylar morphology

Posted Date: November 24th, 2026

DOI: https://doi.org/10.21203/rs.3.rs-11249449/v1

License: This work is licensed under a Creative Commons Attribution 4.0 International License.
Read Full License

Additional Declarations: No competing interests reported.

TMJ function and skeletal stability in skeletal Class II patients after orthognathic surgery: a retrospective cohort study

Xinyi Deng, BDS,[a] Zizhou Ye, BDS,[a] Jialu Li, BDS,[a] Xinyu Chen, BDS,[a] Haozhe Chen, PhD,[a] Ruicheng Liu, PhD,[b] Liping Wu, PhD,[b] Nan Jiang, MD, PhD,[a] Songsong Zhu, MD, PhD,[a] Pinyin Cao, PhD,[a]* Rong Ren, MD, PhD,[a]*

Affiliation:

a. State Key Laboratory of Oral Diseases and National Clinical Research Center for Oral Diseases, West China Hospital of Stomatology, Sichuan University, No. 14, Section 3 of Renmin Nan Road, Chengdu 610041, Sichuan, China

b. Department of Oral and Maxillofacial Surgery, West China Hospital of Stomatology, Sichuan University, No. 14, Section 3 of Renmin Nan Road, Chengdu 610041, Sichuan, China

c. Chengdu Tianqi Additive Manufacturing Co., Ltd. No. 5, Building 5, South Section 3 of Tianfu Avenue, Jiancha Subdistrict, Tianfu New Area, Chengdu City, Sichuan Province, 610213, China

***Corresponding authors:**

Rong Ren, Attending, PhD

State Key Laboratory of Oral Diseases and National Clinical Research Center for Oral Diseases; Department of Oral and Maxillofacial Surgery, West China Hospital of Stomatology, Sichuan University, No. 14, Section 3 of Renmin Nan Road, Chengdu 610041, Sichuan, China

Email: dr_renrong@163.com

Pinyin Cao, Attending, PhD

State Key Laboratory of Oral Diseases and National Clinical Research Center for

Oral Diseases; Department of Oral and Maxillofacial Surgery, West China Hospital of Stomatology, Sichuan University, No. 14, Section 3 of Renmin Nan Road, Chengdu 610041, Sichuan, China

Email: woshicin@126.com

Acknowledgments:

This study was supported by grants from the National Natural Science Foundation of China (No. 82571123, 82501190, 82301112), Sichuan Province 'Achievement Finds Market' Reveal-the-List-and-Hire-the-Leader Project (25JBZSC0002), West China Hospital of Stomatology, Sichuan University (No. LCYJ-ZD202302).

Abstract

Statement of problem: Skeletal instability and temporomandibular joint (TMJ) dysfunction remain challenging complications following orthognathic surgery in skeletal Class II patients, and a reliable preoperative method to identify high-risk patients is lacking.

Purpose: This study investigates whether preoperative condylar morphology classification can identify high-risk patients for these complications.

Methods: This retrospective cohort study enrolled 170 skeletal Class II patients undergone orthognathic surgery. Patients were divided into three groups based on preoperative condylar morphology: Normal (n =35), Erosion (n = 78), or Stump (n = 57). Skeletal stability was assessed by three-dimensional CT superimposition, with relapse defined as postoperative Pogonion displacement ≥2 mm from immediately after surgery to final follow-up. Condylar remodeling (height, width, length, volume) and TMJ function (Helkimo index) were evaluated. No significant intergroup differences existed in demographics, deformity severity, or surgical magnitude ($p > 0.05$). One-way ANOVA analysis, Wilcoxon signed rank test, Chi-square test, or Fisher exact test were used for inter-group statistical analysis.

Results: After a minimum 24-month follow-up, the Erosion group had the highest relapse rate (22.5%), significantly greater than the Normal (2.2%) and Stump (7.6%) groups ($p = 0.0031$). This group also demonstrated the greatest condylar remodeling, with reductions in height (-2.64 ± 0.32mm), length (-1.71 ± 0.24mm), width (-1.26 ± 0.08mm), and volume (-344.70 ± 28.1mm^3) ($p < 0.0001$). Preoperative TMJ function was similar across groups, but the Erosion group showed marked postoperative deterioration, with 12.4% in Di III and 27.5% in Ai II developing severe clinical dysfunction ($p = 0.0026$, $p < 0.0001$).

Conclusion: Preoperative condylar morphology classification effectively stratifies risk for postoperative skeletal relapse and TMJ dysfunction in skeletal Class II patients. Identifying the Erosion subtype enables individualized surgical planning to improve outcomes.

Key words: Orthognathic surgery; skeletal Class II patients; skeletal instability; temporomandibular joint dysfunction; condylar morphology

Clinical Implications: Preoperative condylar morphology classification identifies skeletal Class II patients at high risk for postoperative relapse and TMJ dysfunction (especially the Erosion subtype), enabling personalized surgical planning to improve outcomes.

INTRODUCTION

Skeletal Class II patients typically present with a receding mandible, a high mandibular plane angle, and anterior open bite[1, 2]. These characteristics significantly compromise both facial aesthetics and occlusal function, which often requires orthognathic surgery to achieve functional occlusion and facial harmony[3, 4]. However, skeletal instability causing relapse still remains a major challenge, occurring in a considerable proportion of patients despite refined surgical techniques and rigid internal fixation[5]. Relapse frequently manifests as anterior open bite and recurrence of mandibular retrognathism, which may compromise both aesthetic outcomes and masticatory function[6-8]. One of the key mechanisms underlying relapse is temporomandibular joint (TMJ) pathological condylar remodelling (PCR) after orthognathic surgery, which can lead to decreased ramus height, backward rotation of the mandible, and subsequent occlusal instability[9-12].

In addition to skeletal relapse, TMJ dysfunctions (TMDs) are also a frequent concern in skeletal Class II patients after orthognathic surgery[13-16]. TMDs symptoms such as pain, clicking, and limited mouth opening may develop postoperatively, further affecting patients' quality of life[14]. The relationship between TMDs after orthognathic surgery and skeletal relapse is complex and bidirectional[13, 17, 18]. The status of the condyle may serve as a key factor linking these two concerns[13]. Pre-existing condylar pathology may predispose patients to skeletal relapse, while surgical manipulation of the jaw can alter TMJ loading and thereby exacerbate degenerative changes[12]. Therefore, accurately predicting which patients are at high risk for both skeletal relapse and TMJ deterioration remains an unmet clinical need[19].

Preoperative assessment of condylar status is therefore of paramount importance[20]. Among various imaging features, condylar morphology is a readily available and reproducible indicator that reflects the health and adaptive capacity of the TMJ[21-23]. Emerging evidence suggests that different condylar shapes may correspond to distinct biological behaviors under surgical stress[24]. Based on this rationale, our research group has previously classified skeletal Class II patients into three groups according to condylar morphology on preoperative computed tomography[22]. There are three typical types which were divided into Normal type (smooth and intact condylar surface), Erosion type (irregular or degraded cortical bone), and Stump type (severely shortened and deformed condylar remnant)[22]. However, whether these morphological subtypes differ in terms of postoperative skeletal stability and TMJ functional outcomes remains unknown. Specifically, it is unclear which subtype is more prone to significant relapse and which subtype carries a higher risk of developing or worsening TMJ dysfunction.

To address these gaps, we designed a retrospective cohort study to investigate the association between preoperative condylar morphology classification and long-term outcomes following orthognathic surgery in skeletal Class II patients. The findings are expected to inform preoperative risk stratification and guide individualized surgical planning.

METHODS

Study Design

This retrospective cohort study was approved by the Institutional Ethics Review Board of Sichuan University West China Hospital of Stomatology, and conducted in accordance with the Declaration of Helsinki. Written informed consent was obtained from all participants. Patients with skeletal Class II malocclusion who underwent orthognathic surgery between July 2019 and June 2023 were enrolled. Inclusion criteria were: (1) skeletal Class II malocclusion treated with orthognathic surgery; (2) stable mandibular retrusion without progressive retraction over >6 months; (3) symmetrical facial profile; (4) bilateral condylar consistency; and (5) minimum 24 months of postoperative follow-up. Exclusion criteria included: (1) prior maxillofacial trauma; (2) congenital craniofacial anomalies; (3) systemic bone disorders; (4) previous TMJ symptoms or surgery; (5) idiopathic condylar resorption or TMJ osteoarthritis; and (6) incomplete records. Based on CT imaging in the coronal plane, condylar morphology was classified into three types: Normal (smooth, rounded head with intact cortex) (Figure 1A), Erosion (surface irregularities or bone resorption) (Figure 1B), and Stump (shortened, flattened, or markedly deformed condyle) (Figure 1C)[22]. All patients had at least 24 months of follow-up, with clinical assessments using the Helkimo index and CT evaluations. Data were interpreted by a TMJ specialist and analyzed by a statistician.

3D CT superimposition and condylar displacement measurement

CT scans were acquired using a Somatom Sensation 10® scanner (Siemens, Germany). DICOM (Digital Imaging and Communications in Medicine) images were obtained at three time points: preoperatively (T0), immediately postoperatively (T1), and at the final follow-up (T2). All scans were performed with the patients in the supine position and in centric occlusion. Using Mimics 19.0 software (Materialise HQ Co., Leuven, Belgium), CT images from T0, T1, and T2 were accurately superimposed onto stable cranial reference points that remained unaffected by surgery (Figure 2A). Condylar margins were delineated using three distinct colors to represent T0, T1, and T2. Three reference points (A, B, and C) were marked at the apex of the condylar margin to quantify condylar displacement along the x- (sagittal), y- (coronal), and z- (axial) axes (Figure 2B, 2C). The perpendicular distance between each pair of points was calculated and defined as the magnitude of condylar displacement (Figure 2C).

Evaluation of the changes of mandibular condylar remodelling

Condylar size (including length, height, width, and volume) was measured and compared between the three groups for postoperative changes (T2–T0). The largest slice of the condyle was identified on both the axial and coronal planes. Subsequently, condylar length, width, and height were measured according to the definitions illustrated in Figure 3A, 3B. For volumetric measurement, the mandible was cropped using a tangent line parallel to the frankfort horizontal (FH) plane passing through point Sig in Mimics 19.0, with the superior portion of the condyle designated as the condylar head for volume calculation (Figure 3C). A single examiner performed all measurements. To assess measurement repeatability, 20 patients were randomly selected, and landmarks were re-digitized. The same operator repeated the measurements after a 2-week interval.

Evaluation of the postoperative skeletal stability

Postoperative skeletal stability in the maxilla and mandible was evaluated by analyzing surgical changes (T1-T0) and postoperative changes (T2-T1), respectively, using five midsagittal skeletal landmark: anterior nasal spine (ANS), posterior nasal spine (PNS), point A, point B, and pogonion (Pog). Prior to analysis, the 3D images were reoriented using the following steps: (1) the midsagittal plane was constructed from nasion, basion, and the anterior nasal spine (ANS); (2) the axial plane was defined as perpendicular to the midsagittal plane, passing through either the right or left (clear side) porion and orbitale (FH plane); (3) the coronal plane was set perpendicular to both the midsagittal plane and FH plane, passing through nasion (Figure 3D, 3E). Mandibular advancement was quantified as the positional change of Pog between T1 and T0, and skeletal relapse was defined as a postoperative displacement of Pog $\geqslant$ 2 mm from T1 to T2.

Evaluation of the patients by Helkimo index scoring system

The Helkimo index scoring system is a well-established functional assessment method for TMJ, comprising the Anamnestic (Ai) and Clinical Dysfunction (Di) indices[25]. The Ai index categorizes TMJ dysfunction based on subjective symptoms, while the Di index evaluates clinical findings, including restricted range of motion, impaired TMJ function, muscle pain, TMJ tenderness, and pain during mandibular movement. All patients were scored for TMJ function at T0 and T2.

Statistical analysis

The data were analyzed using SPSS 19.0 statistical software packages (Chicago). Functional outcomes (Helkimo scores) were compared between the three groups using Wilcoxon signed rank test. Categorical data were compared using the chi-square test, or Fisher exact test. One-way ANOVA was also used to assess the differences in condylar size and volume changes, condylar displacement and skeletal stability. $P<0.05$

was accepted as statistically significant.

RESULTS

Patients' information

A total of 193 patients were initially enrolled in this study. However, 23 patients were excluded due to incomplete medical information, including poor-quality images, insufficient follow-up time, and changes in treatment methods, resulting in a final cohort of 170 patients. Based on the condylar morphology, the patients were divided into three groups: the Normal group, consisting of 35 patients (12 males, 23 females; mean age 26.7 ± 7.1 years), the Erosion group, comprising 78 patients (30 males, 48 females; mean age 25.8 ± 8.9 years) and the Stump group, consisting of 57 patients (13 males, 44 females; mean age 27.2 ± 6.5 years). All patients underwent similar surgical procedures and were followed up for at least 24 months. No significant difference was observed in mandibular advancement and counter-clock rotation between the three groups (Normal: 9.9 ± 3.9 mm, Erosion: 9.5 ± 4.3 mm, Stump: 10.3 ± 4.5, $p = 0.5753$). The relative general characteristics of all patients are summarized in Table 1.

TMJ condylar displacement in three groups

In the T1-T0 interval, condylar displacement exceeding the measurement error occurred predominantly in the posterior (88.6% in Normal, 89.7% in Erosion and 92.1% in Stump), lateral (91.4% in Normal, 87.1% in Erosion and 95.6% in Stump), and upward (64.3% in Normal, 78.9% in Erosion and 64.0% in Stump) directions. Regarding the magnitude of condylar displacement, the Stump and Erosion groups exhibited significantly greater distances compared to the Normal group along the x-, y- and z-axes ($p < 0.05$) (Table 2). During the T2-T0 interval, condylar displacement showed a reduction in all three directions for three groups (Normal: 0.97 ± 0.11 mm, 1.03 ± 0.25 mm, and 0.89 ± 0.35 mm; Erosion: 1.27 ± 0.43 mm, 1.33 ± 0.23 mm, and

0.91 ± 0.29 mm; Stump: 1.58 ± 0.89 mm, 1.22 ± 0.0.63 mm, and 1.29 ± 0.37 mm). However, the Stump group still demonstrated significantly greater displacement than the Normal group along the x- and z-axes ($p < 0.05$), while the Erosion group showed comparable or greater displacement along the y-axis. Similarly, the predominant directions of displacement remained posterior (51.5% in Normal, 85.7% in Erosion and 80.6% in Stump), lateral (55.2% in Normal, 78.2% in Erosion and 94.6% in Stump), and upward (47.0% in Normal, 71.1% in Erosion and 54.5% in Stump), though the proportions showed slight variations compared to the T1-T0 interval (Table 3).

TMJ condylar remodelling in three groups

In the T2-T0 interval, the Erosion group exhibited significantly greater reductions in condylar size and volume compared to the Normal and Stump groups, particularly in condylar height (−2.64 ± 0.32 mm) and volume (−344.70 ± 28.1 mm^3). In contrast, the Normal group remained relatively stable, showing only minor changes (−1.67 ± 0.25 mm in height and −35.12 ± 18.2 mm^3 in volume). The degree of reduction in the Stump group fell between the two groups (1.83 ± 0.41mm in height and −68.93 ± 25.7 mm^3 in volume) (Table 4).

Skeletal stability during follow-up in the three groups

During T1-T0, no significant differences were observed in the horizontal or vertical movement of these landmarks in the three groups. However, during T2-T1, skeletal instability was primarily observed in the Erosion group, particularly in the mandibular landmarks point B and Pog. Compared to the Normal and Stump group, point B and Pog in the Erosion exhibited relapse by 3.88 ± 0.87 mm and 4.27 ± 1.22 mm horizontally, and 2.70 ± 0.31 mm and 3.65 ± 0.86 mm vertically, respectively (Table 5). Furthermore, the skeletal relapse rate was significantly higher in the Erosion group (22.5%) than that in Normal and Stump group (2.2% in Normal; 7.6% in Stump,

p = 0.0031) (Table 6).

TMJ function evaluation by Helkimo scores in three groups

At T0, there were no significant differences in the Ai index and Di index among the three patient groups (Di, p=0.8835; Ai, p = 0.5576), indicating that temporomandibular joint function was generally comparable across the three groups prior to orthognathic surgery. However, at T2, the Erosion and Stump groups exhibited a significantly increased proportion of dysfunction compared with the Normal group. Regarding the Di index, the Erosion group primarily showed a decrease in Di 0 from 42.7% to 32.0%, an increase in Di II from 10.1% to 14.0%, and a new occurrence of Di III in 12.4% of cases during follow-up. In contrast, the Normal group and the Stump group remained generally stable, except for the Stump group, which showed a certain proportion of Ai II (22.9%) (Table 7).

DISCUSSION

Skeletal instability and TMDs are two common and challenging complications following orthognathic surgery in skeletal Class II patients[13]. Despite advances in surgical techniques and rigid internal fixation, a considerable proportion of patients still experience postoperative mandibular setback, anterior open bite, or new-onset joint pain, clicking, and limited mouth opening[26-28]. Notably, condylar morphology correlates with the severity of skeletal Class II deformity[29], suggesting its potential as a basis for preoperative subtype classification. Based on this rationale, the present study prospectively enrolled skeletal Class II patients and classified them into three groups according to preoperative condylar morphology classification[22], systematically comparing postoperative skeletal stability and TMJ function.

Previous studies have indicated that condylar displacement, an inevitable consequence of bilateral sagittal split osteotomy for mandibular advancement, may be

a critical factor leading to TMDs and skeletal relapse[18, 21, 30-33]. Condylar displacement occurs predominantly in posterior, superior, and lateral directions, with magnitude positively correlated with the degree of advancement[32, 34, 35]. Beyond advancement, condylar size and joint space also influence displacement[30, 32, 36]. In this study, the Erosion and Stump groups exhibited significantly greater postoperative condylar displacement than the Normal group, suggesting that these morphologies render the condyle more susceptible to iatrogenic malpositioning. This predisposes patients to postoperative internal derangement and progressive condylar resorption (PCR).

PCR appears to be a major contributor to skeletal instability, and the extent of condylar remodeling is closely related to intraoperative condylar displacement. Our results demonstrated that during follow-up (T2-T1), the Erosion group exhibited significantly greater horizontal and vertical relapse at point B and pogonion (3.88 ± 0.87 mm and 4.27 ± 1.22 mm, respectively), with a skeletal relapse rate of 22.5% substantially higher than in the Normal (2.2%) and Stump (7.6%) groups. Concurrently, condylar displacement along sagittal, coronal, and axial axes was most pronounced in the Erosion group, accompanied by marked reductions in condylar height (−2.64 ± 0.32 mm) and volume (−344.70 ± 28.1 mm^3), whereas the Normal group remained relatively stable. These findings indicate that Erosion-type condyles, when subjected to greater intraoperative displacement, are prone to progressive resorption and unfavorable remodeling, thereby compromising anterior mandibular stability. Xi et al. reported that 78% of PCR cases occurred in skeletal Class II patients, with average volume loss of 12%[21]. Among these, 64% exhibited horizontal relapse exceeding 2 mm at the Pog point, and a strong correlation was observed between condylar volume loss and reduced posterior facial height[21].

Although preoperative TMJ function was similar across groups, both the Erosion and Stump groups showed significantly higher dysfunction at final follow-up (T2) compared with the Normal group. Notably, the Erosion group had a marked increase in moderate-to-severe clinical dysfunction (Di II and Di III), indicating detectable joint functional deterioration. Potential mechanisms include: (1) intraoperative condylar displacement disrupting the disc-condyle relationship and causing internal derangement; and (2) persistent abnormal mechanical stress stimulating PCR, further compromising joint biomechanical stability[33]. Thus, patients with Erosion-type or Stump-type condyles should be considered a high-risk population for postoperative TMJ dysfunction. These findings carry direct clinical implications. During digital surgical planning, surgeons should anticipate potential mandibular setback due to PCR in Erosion-type patients. Mitigation strategies include stabilization occlusal splints, intraoperative overcorrection, orthodontic compensatory mechanics, and most critically, meticulous intraoperative condylar positioning to enhance postoperative condylar stability[37-39]. More broadly, preoperative condylar subtyping enables individualized surgical planning: avoiding excessive mandibular advancement in high-risk patients, ensuring precise condylar positioning, and implementing enhanced postoperative follow-up.

This study confirms that preoperative condylar morphologies in skeletal Class II patients reflect distinct structural and biological characteristics of the temporomandibular joint, rather than mere radiological variations. The Normal type exhibited minimal postoperative displacement, negligible remodeling, stable skeletal outcomes, and preserved TMJ function, representing a "stable and tolerant" joint. The Erosion type showed the most pronounced displacement, bone resorption, and skeletal relapse despite absent preoperative TMJ symptoms, indicating a structurally vulnerable,

poorly adaptive joint, a "high-risk unstable" status (Graphical abstract). The Stump type demonstrated intermediate remodeling and relapse between the Normal and Erosion groups, possibly because its markedly reduced condylar volume leaves little space for further intraoperative displacement, resulting in relatively "limited compensatory" behavior.

Several limitations should be acknowledged. First, the classification was based solely on CT-derived osseous morphology, overlooking soft-tissue components such as the articular disc, capsule, and ligaments; future MRI studies could provide a more comprehensive assessment. Second, the classification remains relatively coarse, and more refined subtypes may be needed to identify patients at the highest risk. Third, potential confounders, including parafunctional habits, trauma history, and the extent of maxillary surgical movements, were not adjusted for in multivariate analysis, although no significant intergroup differences were observed in these parameters. Finally, while the 24-month follow-up is reasonable, longer observation would help determine whether the observed differences persist or evolve. Future prospective multicenter studies with extended follow-up may help overcome these limitations.

CONCLUSIONS

In conclusion, preoperative condylar morphology classification, particularly the Erosion type, are strongly associated with increased risk of postoperative skeletal relapse and TMJ dysfunction. This morphology-based classification facilitates preoperative risk stratification and may guide individualized surgical planning to improve outcomes in skeletal Class II patients undergoing orthognathic surgery.

DECLARATIONS

Ethics approval

This study was conducted in accordance with the Declaration of Helsinki . Written

informed consent was obtained from all participants prior to their inclusion in this study. All patient data were anonymized and handled confidentially. The retrospective review of clinical and radiographic records was performed in accordance with institutional and national ethical guidelines.

Consent to participate

Written informed consent was obtained prior to patients' enrollment in this study.

Competing interests

The authors declared no potential conflicts of interest with respect to the research, authorship, and/or publication of this article.

Data availability

The data that support the findings of this study are available from the corresponding author upon reasonable request.

Authors' contribution

Xinyi Deng: Conceptualization, Methodology, Investigation, Project administration, Writing the original draft. **Zizhou Ye, Jialu Li and Xinyu Chen**: Supervision, Project administration, data curation, Formal analysis, Writing and review of the manuscript. **Haozhe Chen, Ruicheng Liu and Liping Wu**: Validation, Writing, review and editing of the manuscript. **Nan Jiang, Songsong Zhu, Pinyin Cao and Rong Ren**: Supervision, Project administration, Visualization, Funding acquisition, Conceptualization, Methodology, Investigation, Writing and review of the manuscript. All authors read and approved the final manuscript.

REFERENCES

[1] A.G. McCollum, J.P. Reyneke, L.M. Wolford, An alternative for the correction of the Class II low mandibular plane angle, Oral Surg Oral Med Oral Pathol 67(3) (1989) 231-41.

[2] J.P. Reyneke, R.S. Bryant, R. Suuronen, P.J. Becker, Postoperative skeletal stability following clockwise and counter-clockwise rotation of the maxillomandibular complex compared to conventional orthognathic treatment, Br J Oral Maxillofac Surg 45(1) (2007) 56-64.

[3] J.W. Choi, W.S. Jeong, M.K. Kang, J.Y. Lee, Y.S. Chung, Counterclockwise Rotational Orthognathic Surgery for the Obstructive Sleep Apnea in Class II

Dentofacial Deformity: Polysomnography and 3D Computed Tomographic Analysis, Ann Plast Surg 86(6) (2021) 640-646.
[4] J.W. Choi, W.S. Jeong, Occlusal Plane Altering 2 Jaw Surgery Based on the Clockwised Rotational Surgery-First Orthognathic Approach, Plast Reconstr Surg Glob Open 5(10) (2017) e1492.
[5] S. Wang, W. Ge, L. Qi, N. Cao, J. Meng, L. Zhang, Mandible-First Sequencing Increase Surgical Accuracy for Patients With Skeletal Class II Malocclusion Concomitant With Unstable Condyle-Fossa Relation, J Craniofac Surg 35(2) (2024) 559-563.
[6] W. Poolsin, E.W. Ko, C.Y. Chen, C.H. Lin, Impact of vertical facial patterns on three-dimensional surgical outcomes and stability in skeletal Class II malocclusion, Biomed J 49(2) (2025) 100894.
[7] T.W. Nielsen, M.B. Holte, G. Berg-Beckhoff, J.J. Thorn, J. Ingerslev, E.M. Pinholt, Three-dimensional assessment of temporomandibular joint changes following maxillomandibular advancement surgery: a five-year follow-up study, Int J Oral Maxillofac Surg 54(7) (2025) 617-623.
[8] Q. Deng, F. Li, L. Bai, X. Yang, Z. Guo, Q. Wan, The Effects of Different Bimaxillary Orthognathic Surgery Sequencing on the Temporomandibular Joint Space of Skeletal Class II Malocclusion Patients, J Oral Maxillofac Surg 83(10) (2025) 1233-1243.
[9] A. Al Khatib, A. Thor, F. Jabbari, Long-term follow-up of Class II malocclusion treated with bilateral sagittal split osteotomy: a retrospective study with 6-19 years of follow-up, Int J Oral Maxillofac Surg (2025).
[10] T.W. Nielsen, M.B. Holte, G. Berg-Beckhoff, J. Ingerslev, J.J. Thorn, E.M. Pinholt, Five-year follow up on risk factors for condylar resorption after maxillomandibular advancement surgery, Br J Oral Maxillofac Surg 63(10) (2025) 739-746.
[11] W. Jia, H. Wu, L. Mei, J. Wu, M. Wang, Z. Cui, Fully automated evaluation of condylar remodeling after orthognathic surgery in skeletal class II patients using deep learning and landmarks, J Dent 159 (2025) 105819.
[12] R. Grillo, F. de Oliveira Andriola, R. Gravalos, W. Calais, L. da Silva Caixeta Neto, F. Melhem-Elias, Orthognathic surgery biomechanics revisited: Simple machine concepts, force distribution, and surgical predictability, J Craniomaxillofac Surg 54(5) (2026) 104517.
[13] C. Lin, J. Zhang, M. Zheng, C. Zhu, C. Zhang, Q. Wan, Association between orthognathic surgery and temporomandibular disorder in dentofacial disharmony patients: a systematic review and meta-analysis, Br J Oral Maxillofac Surg 64(1) (2026) 33-42.
[14] K. Takahashi, K. Kamei, T. Eda, Y. Suzuki, M. Tajima, T. Hirano, The preoperative condition of the temporomandibular joint and role of disc perforation in postoperative condylar resorption in Class II orthognathic surgery patients, Int J Oral Maxillofac Surg 55(5) (2026) 569-577.
[15] E.A. Al-Moraissi, L.M. Wolford, D. Perez, D.M. Laskin, E. Ellis, 3rd, Does Orthognathic Surgery Cause or Cure Temporomandibular Disorders? A Systematic Review and Meta-Analysis, J Oral Maxillofac Surg 75(9) (2017) 1835-1847.

[16] A.Q.J. Toh, Y.Y. Leung, The effect of orthognathic surgery on temporomandibular disorder, J Craniomaxillofac Surg 50(3) (2022) 218-224.
[17] M. Rahbar, A. Sharifi, J. Hayati Garjan, M. Sheykhian, Evaluating fractal value of mandibular ramus and condylar volume in patients undergoing orthognathic surgery: a systematic review and meta-analysis, Maxillofac Plast Reconstr Surg 47(1) (2025) 14.
[18] N.S. Abdul, G. Minervini, Prevalence of Temporomandibular Disorders in Orthognathic Surgery patients: A systematic review conducted according to PRISMA guidelines and the Cochrane Handbook for Systematic Reviews of Interventions, J Oral Rehabil 50(10) (2023) 1093-1100.
[19] F. Civita, I. Rota, D.S. Rossi, A. Sinatra, G.A. Beltramini, A.R. Bolzoni, Augmented reality vs CAD/CAM system in orthognathic surgery: development and accuracy evaluation, Maxillofac Plast Reconstr Surg 47(1) (2025) 33.
[20] Z. He, H. Ji, W. Du, C. Xu, E. Luo, Management of condylar resorption before or after orthognathic surgery: A systematic review, J Craniomaxillofac Surg 47(7) (2019) 1007-1014.
[21] T. Xi, R. van Luijn, F. Baan, R. Schreurs, M. de Koning, S. Bergé, T. Maal, Three-dimensional analysis of condylar remodeling and skeletal relapse following bimaxillary surgery: A 2-year follow-up study, J Craniomaxillofac Surg 45(8) (2017) 1311-1318.
[22] R. Ren, L. Li, J. Li, Z. Ye, Z. Su, P. Cao, X. Xiong, N. Jiang, Condylar morphology in skeletal Class II malocclusion: relationship to mandibular retrognathia and airway stenosis, J Craniomaxillofac Surg 54(5) (2026) 104529.
[23] B. Lekroengsin, C. Tachiki, T. Takaki, Y. Nishii, Relationship between Changes in Condylar Morphology and Masticatory Muscle Volume after Skeletal Class II Surgery, J Clin Med 12(14) (2023).
[24] J. Liu, Z. Lv, Y. Zhu, M. Chung, L. Jiang, Characteristics of condylar joint space, position and morphology in skeletal class II malocclusion patients with bilateral idiopathic condyle resorption, BMC Oral Health 26(1) (2026) 305.
[25] M. Hlawitschka, R. Loukota, U. Eckelt, Functional and radiological results of open and closed treatment of intracapsular (diacapitular) condylar fractures of the mandible, International journal of oral and maxillofacial surgery 34(6) (2005) 597-604.
[26] A.F. Ayoub, D.R. Stirrups, K.F. Moos, Stability of sagittal split advancement osteotomy: single- versus double-jaw surgery, Int J Adult Orthodon Orthognath Surg 10(3) (1995) 181-92.
[27] O.L. Haas Junior, R. Guijarro-Martínez, A.P. de Sousa Gil, L. da Silva Meirelles, N. Scolari, M.E. Muñoz-Pereira, F. Hernández-Alfaro, R.B. de Oliveira, Hierarchy of surgical stability in orthognathic surgery: overview of systematic reviews, Int J Oral Maxillofac Surg 48(11) (2019) 1415-1433.
[28] J.E. Van Sickels, C. Dolce, S. Keeling, B.D. Tiner, G.M. Clark, J.D. Rugh, Technical factors accounting for stability of a bilateral sagittal split osteotomy advancement: wire osteosynthesis versus rigid fixation, Oral Surg Oral Med Oral Pathol Oral Radiol Endod 89(1) (2000) 19-23.
[29] J.R. Gonçalves, D.S. Cassano, L.M. Wolford, A. Santos-Pinto, I.M. Márquez, Postsurgical stability of counterclockwise maxillomandibular advancement surgery: affect of articular disc repositioning, J Oral Maxillofac Surg 66(4) (2008) 724-38.

[30] D. Pachnicz, A. Ramos, Mandibular condyle displacements after orthognathic surgery-an overview of quantitative studies, Quant Imaging Med Surg 11(4) (2021) 1628-1650.
[31] Q. Yin, R. Bi, B. Abotaleb, N. Jiang, Y. Li, S. Zhu, Changes in the position of the condyle after bilateral sagittal split ramus osteotomy in patients with mandibular retrusion and protrusion: a new condyle: fossa matching concept, The British journal of oral & maxillofacial surgery 57(10) (2019) 1086-1091.
[32] J. Valladares-Neto, L.H. Cevidanes, W.C. Rocha, A. Almeida Gde, J.B. Paiva, J. Rino-Neto, TMJ response to mandibular advancement surgery: an overview of risk factors, J Appl Oral Sci 22(1) (2014) 2-14.
[33] O. Ploder, G. Sigron, A. Adekunle, L. Burger-Krebes, B. Haller, A. Kolk, The Effect of Orthognathic Surgery on Temporomandibular Joint Function and Symptoms: What are the Risk Factors? A Longitudinal Analysis of 375 Patients, J Oral Maxillofac Surg 79(4) (2021) 763-773.
[34] R. Ren, Y. Li, W. Telha, S. Zhu, N. Jiang, Effect of the magnitude of condylar head displacement on the TMJ function in skeletal class II patients undergoing different degrees of mandibular advancement: A retrospective comparative study, Journal of plastic, reconstructive & aesthetic surgery : JPRAS 84 (2023) 241-249.
[35] R. Tabrizi, S. Shahidi, E. Bahramnejad, H. Arabion, Evaluation of Condylar Position after Orthognathic Surgery for Treatment of Class II Vertical Maxillary Excess and Mandibular Deficiency by Using Cone-Beam Computed Tomography, Journal of dentistry (Shiraz, Iran) 17(4) (2016) 318-325.
[36] C. van der Linden, W.J. van der Linden, J.P. Reyneke, Skeletal stability following mandibular advancement with and without advancement genioplasty, Int J Oral Maxillofac Surg 44(5) (2015) 621-6.
[37] A. Özdemir, E. Bozkaya, N. Üçüncü, Management of temporomandibular joint dysfunction after orthodontic relapse using stabilization splints and clear aligners: a case report, BMC Oral Health (2026).
[38] N. Wei, Q. Liang, C. Zhao, H. Ai, Z. Chen, Combined Orthodontic-Orthognathic Retreatment of Adult Skeletal Class II Deformity With Mandibular Deviation: A Surgery-Early Approach, J Esthet Restor Dent 38(1) (2026) 34-48.
[39] W. Chow, Z. He, Y. Liu, J. Song, C. Xu, E. Luo, Intraoperative condylar positioning techniques on mandible in orthognathic surgery, Orthod Craniofac Res 25(4) (2022) 449-458.

Figure legends

Figure 1: Preoperative CT-based condylar morphology classification in skeletal Class II patients.

A: Normal type: smooth, rounded head with intact cortex;

B: Erosion: surface irregularities or bone resorption;

C: Stump: shortened, flattened, or markedly deformed condyle.

Figure 2: The methods of 3D CT superimposition and condylar displacement measurement.

A. Accurate reproduction points superimposed CT images at T0, T1 and T2 on the skull that did not change due to surgery;

B. Condylar displacement direction in x, y and z axis;

C. The perpendicular distances between point pairs (A-B, B-C, and A-C) representing the same anatomical position at T0, T1, and T2, respectively, were calculated as the magnitude of condylar displacement along each axis.

Figure 3: The methods of skeletal stability evaluation and condylar size measurement.

A. The definition and measurement of condylar height, width;

B. The definition and measurement of condylar length;

C. The condylar volume was automatically calculated by a segmental plane in mimics 19.0, which is parallel to the FH plane through point Sig point;

D. Anatomic landmarks and planes;

E. The front and oblique view of the set-up of the Coronal and horizonal planes.

Figure 1A

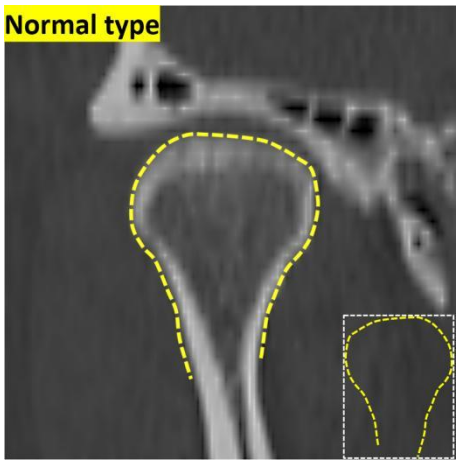

Figure 1B

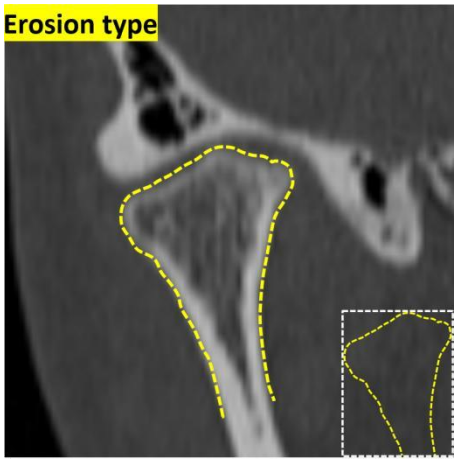

Figure 1C

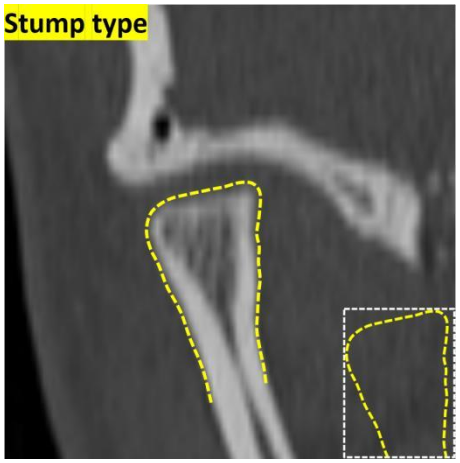

Figure 2A

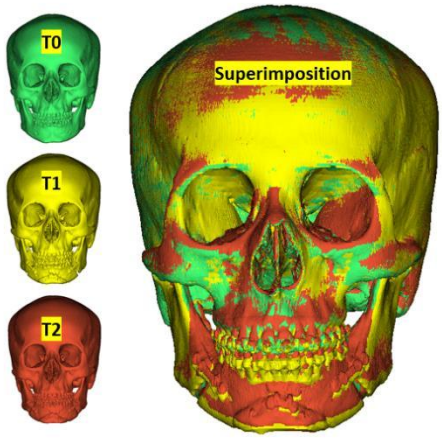

Figure 2B

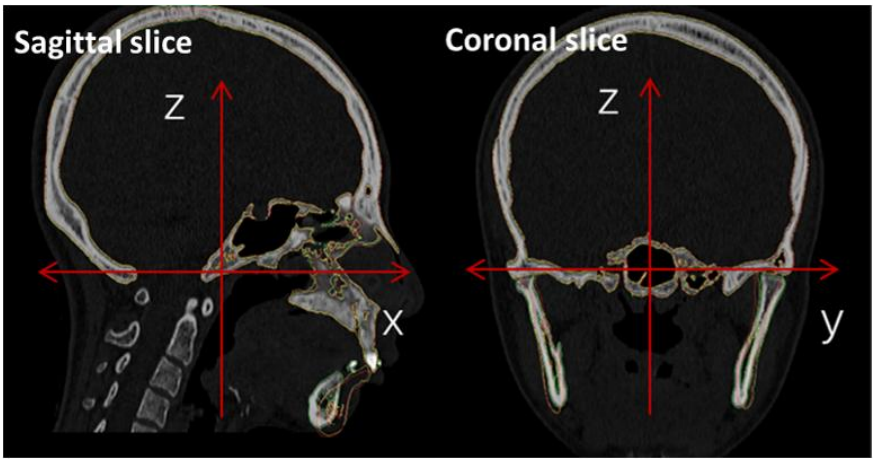

Figure 2C

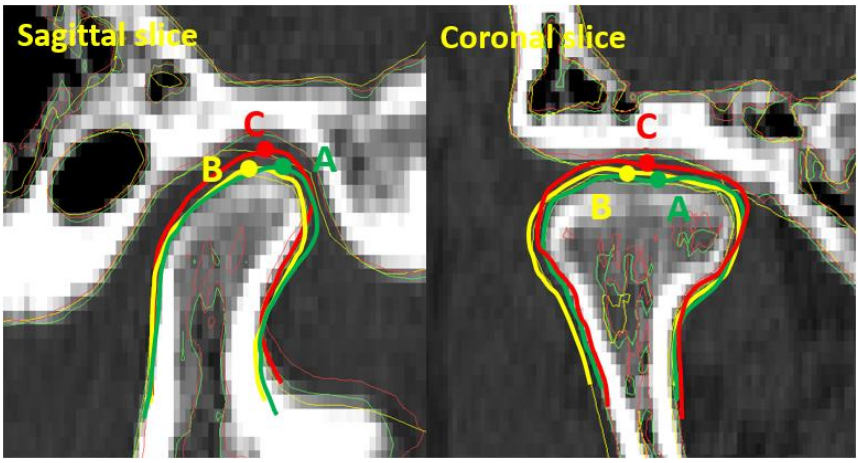

Figure 3A-B

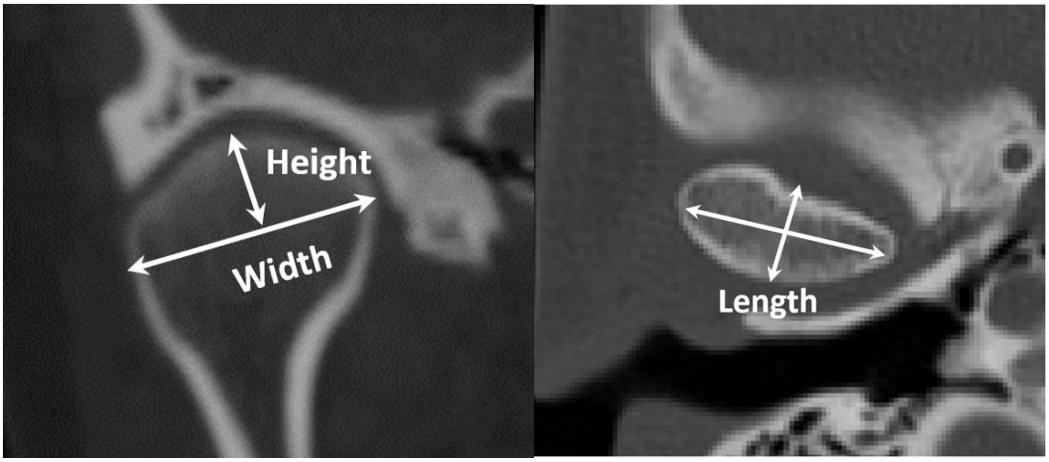

Figure 3C

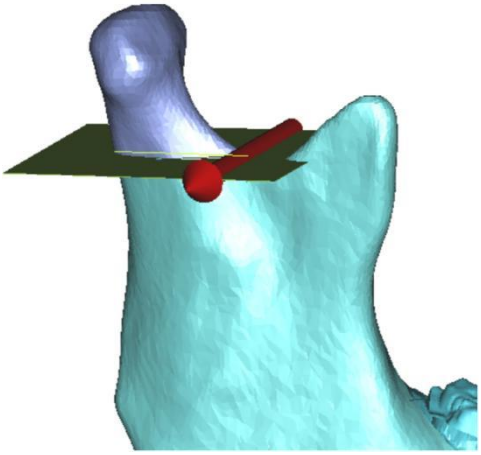

Figure 3D-E

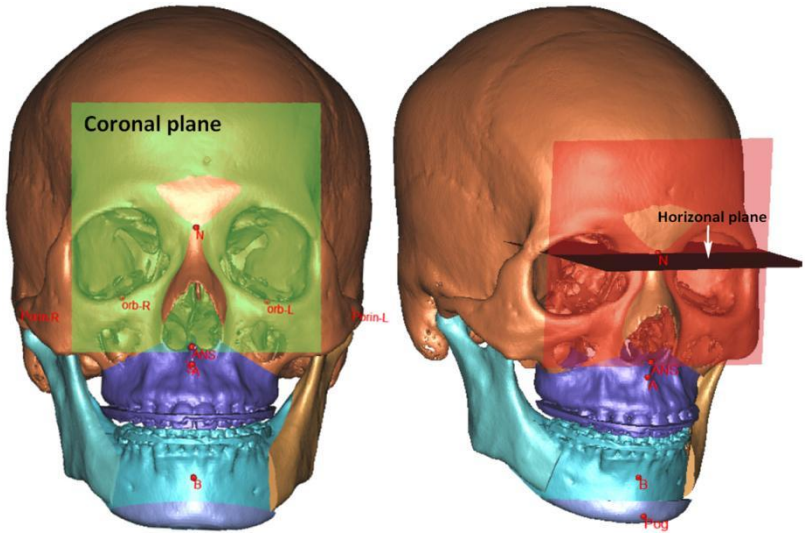

Tables

Table 1. Demographic data of patients with skeletal class II malocclusion.

Characteristics	Normal (n=35) %	Erosion (n=78) %	Stump (n=57) %	p value
Mean age ±SD, yr	26.7 ± 7.1	25.8±8.9	27.2 ± 6.5	0.5773
Gender				
Male	12 (34.3)	30 (38.5)	13 (22.8)	0.1524
Female	23 (65.7)	48 (61.5)	44 (77.2)	
ANB (°)	9.5±2.3	10.2±2.8	9.7±3.4	0.4216
Follow-up time				
24≤ F ≤ 36	8 (22.9)	20 (25.6)	13 (22.8)	0.9077
36 < F ≤ 48	19 (54.3)	43 (55.1)	35 (61.4)	
F > 48	8 (22.8)	15 (19.3)	9 (16.8)	
Surgical treatment				
BSSO or (+Genioplasty)	5 (14.3)	17 (21.8)	13 (22.8)	0.5794
LF I+BSSO or (+Genioplasty)	30 (85.7)	61 (78.2)	44 (77.2)	
Advancement distance (mm)	9.9±3.9	9.5±4.3	10.3±4.5	0.5753
Counter-clock rotation				
Yes	28 (80.0)	59 (75.6)	44 (77.2)	0.8779

No	7 (20.0)	19 (24.4)	13 (22.8)	
Counter-clock rotation angle (°)	7.3±3.1	7.5±2.7	6.8±3.9	0.4570

BSSO, bilateral ramus sagittal split osteotomy; LF1, Lefort I osteotomy.

p-value by one-way ANOVA and chi-square test (α=0.05).

Table 2: Comparison of condylar displacement of three groups in T1-T0.

Group	Normal (n=35, 70 TMJs)		Erosion (n=78, 156 TMJs)		Stump (n=57, 114 TMJs)		p value
	Frequency (n%)	Displacement (mean±SD)	Frequency (n%)	Displacement (mean±SD)	Frequency (n%)	Displacement (mean±SD)	
Displacement in x direction (%, mm)							
Posterior	62 (88.6)	1.19±0.71	140 (89.7)	1.56±0.41	105 (92.1)	1.62±1.03	0.0008
No	7 (10.0)	*NA*	13 (8.3)	*NA*	5 (4.4)	*NA*	*NA*
Anterior	1 (1.4)	1.64±0.00	3 (2.0)	1.21±0.18	4 (3.5)	1.33±0.51	0.6834
Displacement in y direction (%, mm)							
Lateral	64 (91.4)	1.22±0.51	136 (87.1)	1.47±0.68	109 (95.6)	1.43±0.84	0.0626
No	2 (2.9)	*NA*	9 (5.8)	*NA*	4 (3.5)	*NA*	*NA*
Medial	4 (5.7)	1.21±0.33	11 (7.1)	1.55±0.37	1 (0.9)	0.87±0.00	0.1165
Displacement in z direction (%, mm)							
Upward	45 (64.3)	0.73±0.45	123 (78.9)	1.08±0.54	73 (64.0)	1.16±0.61	0.0001
No	9 (12.9)	*NA*	24 (15.4)	*NA*	15 (13.2)	*NA*	*NA*
Downward	16 (22.8)	1.38±0.86	9 (5.7)	0.87±0.24	26 (22.8)	1.96±0.74	0.0007

p-value by one-way ANOVA and Fisher's exact test (α=0.05).

Table 3: Comparison of condylar displacement of three groups in T2-T0.

Group	Normal (n=35, 70 TMJs)		Erosion (n=78, 156 TMJs)		Stump (n=57, 114 TMJs)		p value
	Frequency (n%)	Displacement (mean±SD)	Frequency (n%)	Displacement (mean±SD)	Frequency (n%)	Displacement (mean±SD)	
Displacement in x direction (%, mm)							
Posterior	36 (51.5)	0.97±0.11	133 (85.7)	1.27±0.43	92 (80.6)	1.58±0.89	< 0.0001
No	17 (24.8)	*NA*	16 (10.7)	*NA*	14 (12.1)	*NA*	*NA*
Anterior	17 (23.7)	0.94±0.32	7 (3.6)	1.31±0.11	8 (7.3)	1.21±0.15	0.0047
Displacement in y direction (%, mm)							
Lateral	39 (55.2)	1.03±0.25	122 (78.2)	1.33±0.23	108 (94.6)	1.22±0.63	0.0010
No	20 (29.3)	*NA*	18 (10.9)	*NA*	3 (2.9)	*NA*	*NA*
Medial	11 (15.5)	0.89±0.35	16 (10.9)	1.28±0.31	3 (2.5)	0.87±0.31	0.0100
Displacement in z direction (%, mm)							
Upward	33 (47.0)	0.81±0.33	110 (71.1)	0.91±0.29	62 (54.5)	1.29±0.37	< 0.0001
No	22 (31.5)	*NA*	29 (18.5)	*NA*	23 (20.1)	*NA*	*NA*
Downward	15 (21.5)	0.91±0.43	17 (10.4)	0.68±0.17	29 (25.4)	1.85±0.61	< 0.0001

p-value by one-way ANOVA and Fisher's exact test (α=0.05).

Table 4: Comparison of condylar size, volume in three groups in T2-T0.

Group	T2-T0 (mean±SD)	p value

	Normal (n=35, 70 TMJs)	Erosion (n=78, 156 TMJs)	Stump (n=57, 114 TMJs)	
Condylar head size (mm)				
Height	-1.67±0.25	-2.64±0.32	-1.83±0.41	< 0.0001
Length	-0.20±0.07	-1.71±0.24	-0.45±0.19	< 0.0001
Width	-0.19±0.09	-1.26±0.08	-0.72±0.39	< 0.0001
Condylar head volume (mm^3)				
Volume	-35.12±18.2	-344.70±28.1	-68.93±25.7	< 0.0001

p-value by one-way ANOVA (α=0.05).

Table 5. Postoperative changes of the facial skeleton.

Landmark	T1-T0 (mean±SD)			p value	T2-T1 (mean±SD)			p value
	Normal (n=35)	Erosion (n=78)	Stump (n=57)		Normal (n=35)	Erosion (n=78)	Stump (n=57)	
Horizontal (-anterior, + posterior), points-CP								
ANS	2.31±1.41	2.40±1.28	2.57±1.13	0.5904	-0.15±0.05	-0.97±0.17	0.21±0.09	< 0.0001
PNS	2.27±1.15	2.36±1.43	2.66±0.28	0.1816	-0.17±0.03	-1.22±0.38	-0.31±0.11	< 0.0001
Point A	2.46±1.09	2.60±0.54	2.94±0.18	0.0009	-0.32±0.10	-0.79±0.43	-0.52±0.21	< 0.0001
Point B	-5.69±1.33	-6.33±1.52	-5.97±1.12	0.0551	1.21±0.73	3.88±0.87	1.62±0.90	< 0.0001
Pog	-8.9±2.5	-9.5±4.3	-10.3±3.5	0.1075	1.77±0.51	4.27±1.22	1.95±0.83	< 0.0001

Vertical (-inferior, + superior), points-HP								
ANS	0.54±0.08	0.77±0.12	0.94±0.21	< 0.0001	0.03±0.01	-0.58±0.21	0.30±0.09	< 0.0001
PNS	-3.21±0.72	-3.68±0.54	-3.35±1.08	0.0062	-0.99±0.63	-1.35±0.83	-2.31±1.05	< 0.0001
Point A	1.64±0.10	1.73±0.23	2.02±0.58	0.3256	-0.53±0.21	-1.83±0.25	-0.93±0.08	< 0.0001
Point B	-2.33±0.64	-2.44±0.79	-2.93±0.82	0.0002	0.77±0.42	2.70±0.31	1.21±0.74	< 0.0001
Pog	-5.52±0.85	-5.87±0.76	-6.02±1.25	0.0562	1.01±0.33	3.65±0.86	2.88±1.31	< 0.0001

ANS, anterior nasal spine; PNS, posterior nasal spine.

p-value by one-way ANOVA (α=0.05).

Table 6. Comparison of skeletal relapse rate among the three groups.

Group	**Normal (n=35)**	**Erosion (n=78)**	**Stump (n=57)**	**p value**
Skeletal relapse (Vertical or horizontal deviation of Pog point ≥ 2mm)				
Yes	1 (2.2)	18 (22.5)	4 (7.6)	0.0031
No	34 (97.8)	60 (77.5)	53 (92.4)	

p-value by Fisher's exact test (α=0.05)

Table 7. Comparison of TMJ function among the three groups by Helkimo index scores evaluation

Helkimo index	**T0 (n%)**			**p value**	**T2 (n%)**			**p value**
	Normal (n=35)	**Erosion (n=78)**	**Stump (n=57)**		**Normal (n=35)**	**Erosion (n=78)**	**Stump (n=57)**	

Di								
Di 0	15 (42.2)	33 (42.7)	23 (40.8)	0.8835	21 (60.7)	25 (32.0)	17 (30.6)	0.0026
Di I	18 (52.6)	36 (47.2)	27 (49.0)		13 (37.8)	32 (41.6)	30 (52.2)	
Di II	2 (5.2)	7 (10.1)	7 (10.2)		1 (1.5)	11 (14.0)	9 (15.3)	
Di III	0 (0.0)	0 (0.0)	0 (0.0)		0(0.0)	10 (12.4)	1 (1.9)	
Ai								
Ai 0	26 (75.6)	50 (64.6)	39 (69.4)	0.5576	28 (80.0)	18 (22.5)	20 (35.7)	<
Ai I	9 (24.4)	28 (35.4)	18 (30.6)		7 (20.0)	39 (50.0)	24 (41.4)	0.0001
Ai II	0 (0.0)	0 (0.0)	0 (0.0)		0 (0.0)	21 (27.5)	13 (22.9)	

Di, clinical dysfunction index; Ai, anamnestic index.

p-value by Wilcoxon signed rank test (α=0.05).