Research Square

Preprints are preliminary reports that have not undergone peer review.
They should not be considered conclusive, used to inform clinical practice,
or referenced by the media as validated information.

Surgical Clinical Outcomes of Pediatric Ovarian Dysgerminoma: A 10-Year Experience at INCA, Rio de Janeiro, Brasil

Juliana Alves Maia
Instituto Nacional de Câncer - INCA
Simone Oliveira Coelho
Instituto Nacional de Câncer - INCA
Francisca Norma Albuquerque
Instituto Nacional de Câncer - INCA
Arovel Oliveira Moura Júnior
Instituto Nacional de Câncer - INCA
Bruno César Honório Albuquerque
Instituto Nacional de Câncer - INCA
Lorena Sherman Beretta Castro
Instituto Nacional de Câncer - INCA
Victor Gonçalves Liberal Costa
Instituto Nacional de Câncer - INCA
Larissa Lima Martins Uemoto
Instituto Nacional de Câncer - INCA
Erica Jorge Antunes
Instituto Nacional de Câncer - INCA
Fabiane Carvalho Macedo
Instituto Nacional de Câncer - INCA
Ricardo Vianna Carvalho
cir_oncologica.pediatrica@inca.gov.br

Instituto Nacional de Câncer - INCA

Research Article

Keywords:

Posted Date: November 25th, 2026

DOI: https://doi.org/10.21203/rs.3.rs-11242770/v1

License: This work is licensed under a Creative Commons Attribution 4.0 International License.
Read Full License

Additional Declarations: No competing interests reported.

Surgical Clinical Outcomes of Pediatric Ovarian Dysgerminoma: A 10-Year Experience at INCA, Rio de Janeiro, Brasil

Authors: Juliana Alves Maia[1], Simone de Oliveira Coelho[1], Francisca Norma Albuquerque Girão Gutierrez[1], Arovel Oliveira Moura Júnior[1], Bruno César Honório de Albuquerque[1], Lorena Sherman Beretta de Castro[1], Victor Gonçalves Liberal da Costa[1], Larissa Lima Martins Uemoto[1], Erica Jorge Antunes[1], Fabiane Carvalho de Macedo[1], Ricardo Vianna de Carvalho[1].

1 National Cancer Institute (INCA), Rio de Janeiro, Brazil.

Abstract

Introduction: Pediatric ovarian neoplasms are rare. Dysgerminoma is an uncommon malignant germ cell tumor, and surgery is a key component of treatment. **Objective:** To describe the treatment of ovarian dysgerminoma in pediatric patients at Brazilian National Cancer Institute (INCA). **Methods:** We conducted a retrospective study of female patients younger than 16 years of age with ovarian neoplasms treated at the Pediatric Surgery Department at INCA, between January 2016 and January 2026. Ethic research number 93292925.0.0000.5274. **Results:** 91 patients were diagnosed with ovarian neoplasms, of whom 11 (12.1%) had dysgerminoma. Unilateral oophorectomy and/or salpingo-ophorectomy was performed using fertility-preserving techniques whenever oncological feasible. One patient (9.1%) underwent surgery outside our institution. Four patients (36.4%) received neoadjuvant chemotherapy, and one (9.1%) received adjuvant chemotherapy. According to the International Federation of Gynecology and Obstetrics (FIGO) staging system, most patients presented with early-stage disease, distributed as follows: Four cases stage I, including two stage IA and one stage IC, while one patient had stage IIB disease. Two patients had stage III, including one with pulmonary metastasis. All patients remain under clinical follow-up. **Discussion:** The clinical presentation of ovarian dysgerminoma is nonspecific, with abdominal pain and a pelvic mass being common findings. Serum tumor markers, ultrasonography, and computed tomography are important for the diagnostic evaluation and staging. Histopathological examination with immunohistochemistry confirms the diagnosis. Fertility preservation should be considered whenever oncological safe,

with careful surgical techniques to avoid tumor spillage. Chemotherapy provides favorable outcomes, including advanced disease and salvage settings. The rarity of dysgerminoma and the limited number of published pediatric series restrict the available evidence. **Conclusion:** Multidisciplinary management in specialized centers may optimize oncological outcomes while reducing morbidity and preserving reproductive potential. Further studies with larger cohorts and longer follow-up are needed to evaluate fertility, ovarian function, and quality of life.

Keywords: Ovarian tumor; dysgerminoma; children; adolescents; surgery

Introduction

Ovarian neoplasms in the pediatric population are rare and represent a heterogeneous group of diseases, accounting for approximately 1% of all childhood malignancies [1]. According to Uhde et al. (2022) [2], the annual incidence of ovarian tumors is approximately 2.6 cases per 100,000 girls younger than 15 years. Given their low incidence and often nonspecific clinical presentation, these tumors may follow an insidious course and are frequently identified during the evaluation of nonspecific symptoms or incidental findings on physical examination and imaging studies. Abdominal pain associated with a palpable pelvic mass is the most common clinical presentation, while imaging modalities and serum tumor markers, particularly alpha-fetoprotein (AFP) and beta-human chorionic gonadotropin (β-hCG), play important roles in the diagnostic evaluation and disease characterization [3].

Histopathological, germ cell tumors constitute the predominant category of ovarian neoplasms in children and adolescents, accounting for approximately 90% of cases. Other important histological subtypes include sex cord–stromal tumors, such as Sertoli–Leydig cell tumors, which may present distinct diagnostic and therapeutic challenges [4,5].

Dysgerminoma is the most common malignant ovarian germ cell tumor and represents a small proportion of all pediatric ovarian neoplasms, with an estimated incidence of approximately 0.2% [6]. Surgical resection remains a fundamental component of treatment, and the extent of surgery must achieve adequate oncologic control while minimizing unnecessary loss of reproductive tissue. Whenever oncological safe, fertility-sparing surgery should be considered,

particularly in children and adolescents. Appropriate management of metastatic disease and systematic long-term surveillance are also essential components of comprehensive care [7,8].

Dysgerminomas are highly chemo sensitive and radiosensitive tumors. Although radiotherapy can achieve effective disease control, its use in pediatric patients is generally limited because of the potential for significant long-term toxicity, particularly gonadal dysfunction and the risk of secondary malignancies. Consequently, platinum-based chemotherapy has become an important component of treatment, with bleomycin, etoposide, and cisplatin (BEP) representing a widely used regimen, particularly for advanced-stage disease [9].

The present study evaluates the clinical and surgical management of pediatric patients with ovarian dysgerminoma neoplasms treated between January 2016 and January 2026 at the Pediatric Surgical Oncology Department of the Brazilian National Cancer Institute (INCA), in Rio de Janeiro, Brazil.

Methods

A retrospective review of the medical charts' patients younger than 16 years who were treated for ovarian dysgerminoma at the Brazilian National Cancer Institute (INCA) between 2016 and 2026. The study was conducted in accordance with the applicable ethical requirements under number CAAE 93292925.0.0000.5274.

Results

During the study period, a total of 539 surgical patients were identified, 314 (58.3%) were female. Among these, 91 (29%) patients presented with ovarian neoplasms of various histological types. Dysgerminoma was an uncommon diagnosis, with cases occurring irregularly throughout the study period. Eleven patients with ovarian dysgerminoma were treated and included in this analysis.

As shown in **Table 1**, patients ranged in age from 6 to 15 years, with a mean age of 11.55 ± 2.81 years and a median age of 11.0 years. Regarding pubertal development, menarches occurred either before or after treatment in a proportion of patients (**Table 1**). Among patients with documented menarche after treatment, ages at menarche were 11, 12, and 14 years, suggesting preservation

of endocrine function of the contralateral ovary in patients who underwent fertility-sparing surgery.

The most common presenting feature was a palpable abdominal mass, reported in 88.9% of cases, followed by abdominal or pelvic pain in 55.6%. Imaging studies demonstrated ovarian masses of variable dimensions, including large-volume lesions.

Serum tumor marker evaluation revealed predominantly low or near-normal &-protein (AFP) levels, although one patient had a marked elevation, with a value of 104; *β*-human chorionic gonadotropin (*β*-hCG) levels were variable, ranging from 27.7 to 509 in some patients, while other measurements were below 0.1 or reported as normal. These findings highlight the significance of interpreting tumor markers collectively in the evaluation and representation of ovarian germ cell tumors. Lactate dehydrogenase (LDH), a clinically relevant marker in germ cell tumors, was markedly elevated in eight patients, with values ranging from 780 to 3,558 U/L, a mean of 1,926 U/L, and a median of 1,585.5 U/L.

The surgical approach was mostly open, with the objective of realizing complete tumor resection while avoiding intraoperative tumor rupture or spillage. In patients with extensive disease and/or diagnostic uncertainty, minimally invasive procedures were performed when considered oncological recommendations. All 11 patients underwent unilateral oophorectomy and/or salpingo-ophorectomy, with an intentional fertility-sparing approach whenever oncological feasible. Additional procedures, including appendectomy and lymphadenectomy, were performed in selected cases according to intraoperative findings and clinical characteristics. One patient underwent ovarian resection in another institution.

Neoadjuvant chemotherapy was administered to four patients (36.4%). There were three patients: One patient (9.1%) received postoperative chemotherapy following surgical treatment. Among patients who received neoadjuvant chemotherapy, histopathological examination demonstrated extensive fibrosis and necrosis without viable neoplastic cells in the examined sections, findings consistent with a favorable pathological response to treatment.

On histopathological examination, tumor weight ranged from 31 to 3,285 g, with a median of 2,156 g. Immunohistochemical analysis demonstrated expression of

characteristic dysgerminoma markers, including OCT3/4, OCT4, PLAP, and CD117 (c-KIT), with SALL4 expression documented in selected cases. Vimentin positivity and focal AE1/AE3 expression were also reported in specific cases. Collectively, these findings supported the diagnosis of ovarian dysgerminoma. **(Figure 1)**

Disease stage was evaluated according to the International Federation of Gynecology and Obstetrics (FIGO) staging system. Seven patients (63.6%) had stage I disease, including four classified as FIGO stage I, two as stage IA, and one as stage IC. One patient (9.1%) had FIGO stage IIB disease, whereas two patients (18.2%) had FIGO stage III disease, including one classified as FIGO stage IIIR1. Overall, four patients (36.4%) had diseases beyond FIGO stage I, including stages IC, IIB, and III. One patient with stage III disease had documented pulmonary metastasis.

Despite the presence of advanced-stage disease and/or large-volume tumors in several patients, no deaths were recorded during the study period. All 11 patients remain under multidisciplinary outpatient surveillance, including clinical, surgical, and endocrinological follow-up.

Overall, these findings demonstrate that ovarian dysgerminoma predominantly affects patients in the second decade of life and may present with large tumor masses and elevated tumor markers while remaining amenable to fertility-preserving treatment. The combination of reproductive organ-preserving surgery and chemotherapy when clinically indicated was associated with favorable clinical outcomes in this cohort.

Discussion

Malignant germ cell tumors represent the most common histological category of ovarian malignancies in this population. The literature indicates that pediatric ovarian neoplasms occur during adolescence, between 10 and 14 years of age; discussion reinforces that ovarian dysgerminoma is a rare malignancy in pediatric patients. Epidemiological data regarding pediatric ovarian tumors in the Brazilian population remain limited. Clinical and epidemiological studies conducted at referral institutions, such as the Brazilian National Cancer Institute (INCA), are therefore essential for characterizing these neoplasms and defining their clinical,

surgical, and histopathological profiles within the context of national oncology practice [10].

In our cohort, most patients were in late childhood or adolescence and presented with large, unilateral ovarian tumors identified during subsequent imaging exams studies. These findings are consistent with the clinical characteristics described in previous reports.

Malignant germ cell tumors represent the most common histological category of ovarian malignancies in this population. Dysgerminomas arise from primordial germ cells that embryologically give rise to the gonads and share a common developmental origin with testicular seminoma [11]. Case reports included in the present review demonstrate that the clinical presentation is nonspecific and may include abdominal pain, abdominal distension, increased abdominal girth, and a palpable pelvic mass. Less frequently, patients may present with an acute abdomen secondary to ovarian torsion [11,12].

Accurate histopathological diagnosis is essential, particularly because several entities may enter the differential diagnosis. Lymphoma, for example, may present with overlapping gross and microscopic features; therefore, immunohistochemical evaluation is critical for establishing the diagnosis and guiding treatment and prognostic assessment. Dysgerminomas are typically large, encapsulated ovarian tumors with a smooth or lobulated external surface. On cut sections, they are generally solid and multinodular, with a reddish-tan appearance before formalin fixation, and may contain areas of hemorrhage and necrosis. Microscopically, tumor cells are arranged in well-defined nests separated by fibrous septa containing predominantly T lymphocytes. Less common architectural patterns include cords, trabeculae, solid tubules, and pseudo glandular structures. The neoplastic cells are relatively uniform and polygonal, with distinct cytoplasmic borders, abundant clear or eosinophilic and finely granular cytoplasm, and large nuclei with angular contours containing one or two prominent nucleoli. Mitotic figures are frequently observed [13,14].

Scattered syncytiotrophoblastic cells may occasionally be identified within the tumor. The surrounding stroma may contain poorly formed granulomas, which can complicate the diagnosis, particularly in metastatic sites.

Immunohistochemically, dysgerminomas typically express SALL4, OCT4, CD117 (c-KIT), D2-40, LIN28, and NANOG. Cytokeratin expression may be focal, whereas EMA, CD30, and glypican-3 are generally negative [13].

The microscopic morphology, ultrastructural features, immunohistochemical and cytogenetic profiles, biological behavior, and, most likely, histogenesis of ovarian dysgerminomas—derived from primordial or undifferentiated germ cells—are analogous to those of classic testicular seminoma. The principal differences relate to anatomic location and the type and frequency of activating point mutations involving the *KIT* (CD117) gene [14].

As emphasized above, definitive histopathological diagnosis is essential. Findings from the literature support the observations of Birbas et al. [15], who highlighted the diagnostic complexity associated with the nonspecific nature of the initial clinical presentation. These findings reinforce the value of early diagnosis using imaging modalities such as ultrasonography and CT scan, together with serum tumor markers. Tumor marker results may support the diagnostic assessment and help guide subsequent imaging evaluation of the abdomen and pelvis. Across most of the reports reviewed, ultrasonography and computed tomography were central to tumor detection and characterization, whereas definitive diagnosis was established by histopathological examination, which remains the diagnostic gold standard [15]. In addition, substantial elevations in serum lactate dehydrogenase (LDH) were observed in many patients, supporting its potential role as an adjunctive biomarker in ovarian dysgerminoma [15].

Forwarding to specialized centers may reduce the risk of unseemly surgical procedures. The involvement of pediatric surgeons with expertise in surgical oncology is remarkable for guiding operative decision-making and optimizing oncologic outcomes, as well as in emergency presentations. The International Society of Paediatric Surgical Oncology (IPSO) is a leading international organization dedicated to pediatric surgical oncology. Through collaboration among specialists worldwide, IPSO promotes the development and propagation of expertise in the surgical management of children with cancer [16]. An essential surgical principle is complete tumor resection without tumor rupture or spillage into the peritoneal cavity. Collection of peritoneal fluid for cytological evaluation

may also contribute to accurate surgical staging. Unilateral salpingo-ophorectomy, when conducted with oncologic surgical principles, has generally provided excellent disease control while preserving the uterus and the contralateral ovary. This approach is particularly relevant in pediatric patients because of their potential future reproductive function [11]. Similar findings were reported in the studies included in this review, in which fertility preservation was prioritized whenever the extent of disease permitted. During follow-up, serial assessment of tumor markers, combined with imaging studies, may assist in monitoring treatment response, detecting recurrence, and evaluation disease progression [17,18].

When chemotherapy is indicated, treatment is usually based on a combination of bleomycin, etoposide, and cisplatin (BEP). This regimen is also used as adjunctive therapy in patients with advanced diseases. Patients with advanced-stage dysgerminoma may achieve substantial treatment responses and favorable long-term outcomes [15]. These findings are consistent with the studies reviewed in the present analysis, which report high overall survival rates.

Another recurrent theme in the literature is the importance of multidisciplinary management. Coordinated care involving pediatric surgeons, pediatric oncologists, gynecologists, pathologists, radiologists, endocrinologists, and other specialists may facilitate individualized treatment while preserving the patient's future reproductive potential [15]. This multidisciplinary strategy has been associated with reduced surgical morbidity, greater preservation of ovarian function, and favorable long-term oncologic outcomes.

Most publications on pediatric ovarian dysgerminoma consist of case reports and small case series, reflecting the limited level of evidence available because of the rarity of this disease. Considerable heterogeneity has also been observed in treatment duration, criteria used to assess disease progression, surgical techniques, and reporting of fertility-related outcomes, limiting direct comparisons among studies [11].

Given these limitations, future research should prioritize prospective multicenter studies involving larger patient populations, standardized treatment protocols, and long-term follow-up. Outcomes should extend beyond overall survival to

include ovarian function, fertility, endocrine health, quality of life, and psychosocial outcomes. Such studies are essential to better define the balance between oncologic control and preservation of reproductive potential in pediatric patients with ovarian dysgerminoma.

We believe that the findings of the present study contribute to the growing body of knowledge regarding clinical presentation, surgical and systemic treatment, and long-term follow-up of children and adolescents with histologically confirmed ovarian neoplasms, with particular emphasis on dysgerminoma. The experience of specialized pediatric oncology centers may help inform evidence-based clinical decision-making and support the development of standardized multidisciplinary treatment strategies for this rare malignancy.

Conclusion

Laboratory investigations and imaging studies are essential for right disease characterization and staging. Complete surgical resection of the tumor, thorough exploration of the abdominal cavity, and the use of fertility-preserving surgical techniques, whenever oncological feasible, are critical components of the management of pediatric ovarian dysgerminoma. Histopathological examination, complemented by immunohistochemical analysis, is essential for establishing the diagnosis and guiding therapeutic decisions, including adjuvant treatment strategies.

Although ovarian dysgerminoma is rare, its favorable prognosis with appropriate multimodal management emphasizes the importance of standardized diagnostic and therapeutic approaches. Our present case may contribute to the development of treatment strategies for this pathology. In Brazil, despite advances in pediatric oncology care, multicenter studies remain limited. Collaborative, multicenter research certainly increases treatment protocols, and further evaluates long-term outcomes, including fertility preservation, endocrine function, and quality of life.

References

[1] JÁUREGUI, Y. J. et al. Malignant ovarian tumors in girls: a report of three cases. **Archivos Venezolanos de Puericultura y Pediatría**, v. 85, n. 2, p. 46-50, 2022.

[2] UHDE, S. P. R.; FRIEDRICH, J. V.; FIORI, C. M. C. M. Ovarian tumors in children and adolescents: a case analysis at a pediatric oncology referral center. **Research, Society and Development**, v. 11, n. 13, e78111335202, 2022.

[3] ŽILINSKIENĖ, G. et al. An ovarian Sertoli–Leydig cell tumor with elevated alpha-fetoprotein in an adolescent: a rare case report and literature review. **Medicina**, v. 60, n. 9, p. 1477, 2024. DOI: 10.3390/medicina60091477.

[4] SCHNEIDER, D. T. et al. Ovarian sex cord-stromal tumors in children and adolescents. **Journal of Clinical Oncology**, v. 21, n. 12, p. 2357-2363, 2003. DOI: 10.1200/JCO.2003.05.038.

[5] AKMAN, L. et al. Ovarian Sertoli–Leydig cell tumors: a multicenter long-term clinicopathological analysis of 27 patients. **Journal of Cancer Research and Therapeutics**, v. 12, n. 1, p. 290-295, 2016.

[6] SAS, I. et al. Ovarian dysgerminoma in pregnancy: a case report. **Medicine (Baltimore),** v. 100, n. 14, e25364, 2021.

[7] LI, J.; LI, J.; JIANG, W. Oncological prognosis and fertility outcomes of different surgical extents for malignant ovarian sex-cord stromal tumors: a narrative review. **Cancer Management and Research**, v. 14, p. 697-717, 2022.

[8] CHAPUT, L. et al. Fertility preservation in oncology. **Bulletin du Cancer**, Paris, v. 104, n. 12, p. 1034-1042, 2017. DOI: 10.1016/j.bulcan.2017.11.001.

[9] MAIDARTI, M.; GARINASIH, P. D.; ANGGRAENI, T. D. Conservative surgical staging as a means to preserve fertility in patients with dysgerminoma: a case report. **Annals of Medicine and Surgery**, v. 85, n. 3, p. 427-430, 2023. DOI: 10.1097/MS9.0000000000000146.

[10] TCG-2008 PROTOCOL. Brazilian Cooperative Group for the Treatment of Childhood Germ Cell Tumors. São Paulo, 2008. Available at: https://xodo.onelink.me/MzCS/r9imbau3.

[11] MITRANOVICI, M.-I. et al. Diagnosis and management of dysgerminomas with a brief summary of primitive germ cell tumors. **Diagnostics**, Basel, v. 12, n. 12, p. 3105, 2022. DOI: 10.3390/diagnostics12123105. Available at: https://pmc.ncbi.nlm.nih.gov/articles/PMC9776801/.

[12] ADHIKARI, Siddhant et al. Paediatric ovarian dysgerminoma: a case report. **Journal of Nepal Medical Association**, Kathmandu, v. 60, n. 255, p. 985–988, 2022. DOI: 10.31729/jnma.7894. Available at: https://pmc.ncbi.nlm.nih.gov/articles/PMC9795100/

[13] Rosai and Ackerman's Surgical Pathology - 2 Volume, 11th Edition, female reproductive system, germ cell tumors, dysgerminoma.

[14] WHO classification of tumors, female genital tumors (5th edition); tumors of the ovary, germ cell tumors, dysgerminoma

[15] BIRBAS, E. et al. *Ovarian masses in children and adolescents: a review of the literature with emphasis on the diagnostic approach*. **Children,** Basel, v. 10, n. 7, p. 1114, 2023. DOI: 10.3390/children10071114. Available at: https://pmc.ncbi.nlm.nih.gov/articles/PMC10377960/.

[16] DE CAMPOS et al. International Society of Paediatric Surgical Oncology (IPSO) Surgical Practice Guidelines. **Ecancermedicalscience**, v. 17, p. 1356, 2022. DOI: 10.3332/ecancer.2022.1356.

[17] GHADDAB, I. et al. Clinical, therapeutic and prognostic aspects of malignant germ cell tumors of the ovary: experience of 21 years in Tunisia. **Pan African Medical Journal,** v. 36, p. 178, 2020. DOI: 10.11604/pamj.2020.36.178.23916.

[18] GBARY-LAGAUD, E. et al. Ovarian dysgerminoma associated with pregnancy presenting as hemoperitoneum: an obstetric case report. **Clinical Case Reports,** v. 13, n. 2, e70203, 2025. DOI: 10.1002/ccr3.70203

Recognition of Author Responsibilities

The authors' contributions and responsibilities for the research were as follows: **Juliana Alves Maias** conducted the medical record review, contributed to the case description, and participated in the surgical procedures. **Simone Oliveira Coelho, Arovel Oliveira Moura Junior, Francisca Norma Albuquerque Girão**

Gutierrez, Bruno Arovel Oliveira Moura Junior, Lorena Sherman, Bruno Cesar Honorio de Albuquerque, and **Victor Gonçalves Liberal da Costa** performed the surgical procedures. **Erica Jorge Antunes** contributed to the review and interpretation of the imaging studies. **Larissa Lima Martins Uemoto** was responsible for the chemotherapy protocol. **Fabiane Carvalho de Macedo** was responsible for reviewing the histopathological reports. **Ricardo Vianna de Carvalho** and **Simone Oliveira Coelho** supervised the final manuscript and overall study report.

Acknowledgments

The authors would like to thank the administrative staff of the Pediatric Surgical Oncology Department at the Brazilian National Cancer Institute (INCA), as well as all individuals who contributed in any way to the completion of this research.

Research Ethics

This study was conducted in accordance with applicable ethical standards and was registered under CAAE No. 93292925.0.0000.5274.

Conflict of Interest

The authors declare that they have no conflicts of interest.

Figure 1: IMAGE 1—CD117, 100×: Diffuse proliferation of medium- and large-sized cells with clear or eosinophilic cytoplasm and well-defined cytoplasmic membranes. Delicate fibrous bands containing inflammatory cells. IMAGE 2—H&E, 200×: Cells with large nuclei, prominent eosinophilic nucleoli, and well-defined cytoplasmic membranes. Delicate fibrous bands containing inflammatory cells. Apoptotic bodies and mitotic figures are present. IMAGE 3—OCT4, 100×: Immunohistochemical staining for the OCT4 antibody, showing strong and diffuse nuclear positivity. IMAGE 4—CD117, 100×: Diffuse immunohistochemical staining for the CD117 antibody in the cell membrane and cytoplasm.

Figure 1

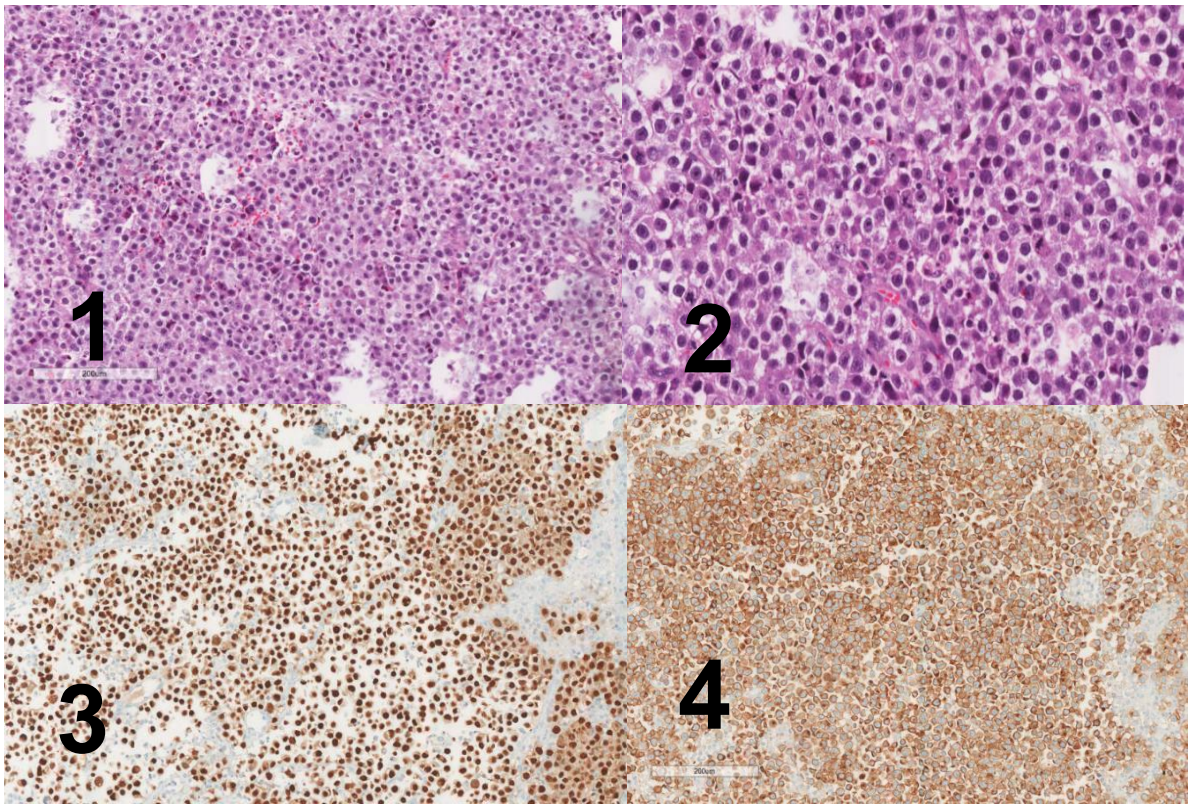

Table 1: The table below presents the clinical and epidemiological profile, surgical procedures, histopathological diagnosis with immunohistochemical results, staging, chemotherapy protocol for patients with an indication for treatment, and outpatient follow-up.

Notes: No. = number; y = years; pre-treat. = pretreatment; post-treat. = post-treatment; US = ultrasound; CT = computed tomography; MRI = magnetic resonance imaging; pre-op chemo = preoperative chemotherapy; pathology report = histopathological report; post-op chemo = postoperative chemotherapy; LDH = lactate dehydrogenase; R = right; L = left; NR = not reported; FIGO = International Federation of Gynecology and Obstetrics; GCT = germ cell tumor.

No.	AGE (y)	MENARCHE		CLINICAL		IMAGING			MARKERS			PREVIOUS BIOPSY	Pre-op chemo	SURGERY	HISTOPATHOLOGY	FLUID	WEIGHT	SIZE	POSITIVE IMMUNOHISTOCHEMISTRY	Post-op chemo	STAGE	Chemo PROTOCOL	Notes	FOLLOW UP
		pre-treat	post-treat	mass	pain	US	CT	MRI	α-feto	β-hcg	other													
1	10		14	X			X		104	509	LDH 2075			left oophorectomy, appendectomy, partial omentectomy	Left ovary, intact capsule, bosselated outer surface, light brown and smooth, without lacerations. Completely solid, light brown and lobulated.	P	672	13X9X8	NO		FIGO IIB			ALIVE 2025
2	11		12		X		X		2.10	27.7	2558	Germinoma. 22/09/2016	YES	left salpingo-oophorectomy	Left ovary, areas of fibrosis. No viable neoplasm.	Negative/POS	-	7,5X3,5X3	PLAP		FIGO IA	TCG 2008	Lung metastasis	ALIVE 2020
3	11	10		X		X	X	X	1.92	54.1	LDH1096	Dysgerminoma 12/07/2018		left salpingo-oophorectomy / right biopsy	Left ovary, outer surface smooth, shiny, bosselated, multinodular, brown with whitish septa of diffuse distribution. Right ovary normal.	N	879	18X9,0X8,5	PLAP, OCT4 and CD117		FIGO I			ALIVE 2021
4	14		no informatio n	X	X	X	X		post-op 0.94	post-op < 0.1	post-op CA125 17.09	Dysgerminoma 01/03/2019		right oophorectomy. Outside INCA	Dysgerminoma - REVIEW	N/R	-	12X10X6.7	Oct-4, C-kit, PLAP, SALL4, AE1-Ae3 (focal)		FIGO IA		11.17.18 Ovary tumor first resection, Second surgery 2 months later	ALIVE 2023
5	14	11			X	X	X	X	0.49	148,1	LDH3450			left salpingo-oophorectomy	Left ovary, with bosselated, light brown and shiny surface. Parenchyma entirely occupied by a light brown, firm-elastic tumor, outlining nodules.	N	2.666	21,5X15,5X12,3	FALP, OCT 3/4 and C-Kit antibodies		FIGO I		18 days in ICU afterwards. Covid. Renal failure / hemodialysis	ALIVE 2025
6	10		11	X	X	X	X		7.1	N	D-dimer 2436			right oophorectomy	Right ovary, intact capsule, smooth and shiny, showing cystic, compact areas of brownish-pink color.	N	3285	23X19X12	c-Kit (CD117) dot-like Ki67		FIGO I			ALIVE 2025
7	12	11		X		X	X		1,03	206,5	LDH909			left salpingo-oophorectomy	Left ovary, bosselated outer capsule, intact, greyish-brown and smooth with evident vascularization; solid, homogeneous, brownish-pink and fleshy, without vascular invasion, foci of necrosis.	N	2192	22X18X30	OCT3/4 and CD-117 antibodies		FIGO I			ALIVE 2026
8	15	14		X		X	X		2,62	204,5	LDH982			left salpingo-oophorectomy, resection of implant	Left ovary, whitish color, intact capsule, soft consistency, solid, white/pink. No necrosis, with vascular invasion of the tubal wall, as well as infiltration of the wall and mucosa of the fallopian tube. Ovarian surface free of neoplastic involvement. Metastatic dysgerminoma.	N	2397	21X20X39	OCT4 and PLAP		FIGO I		congenital heart disease. VSD	ALIVE 2025
9	9		no menarche until Jan ne	X	X		X	X	1,6	38.73	LDH780	Dysgerminoma 15/07/24	YES	left salpingo-oophorectomy / right biopsy, lymphadenectomy, partial omentectomy	Left ovary, greyish and opaque outer surface, post-treatment changes (fibrosis, necrosis). No residual neoplasm in the sections examined.	Negative/POS	-	5,7X4,0X2,3	Vimentin, OCT4, C-kit positive		FIGO St. III Intermediate Risk	TCG GALOP 2017		ALIVE 2025
10	6		underage							124		Dysgerminoma 24/05/2025	YES	right salpingo-oophorectomy. Outside INCA	Right ovary with smooth, opaque, translucent serosa; gre	N/R	31	6.5X4.0X3.2	SALL4, CD117 and b-HCG	YES	FIGO III High Risk	TCG GALOP 2017		ALIVE 2026
11	15	12		X	X	X		X	1	348	LDH3558			right salpingo-oophorectomy	Right ovary, smooth surface, brown with evident vascular network, brownish-wine colored, elastic, somewhat friable. No rupture or capsular involvement. No vascular invasion.	N/R	2120	22,5X16,0X4,5	OCT3/4 and CD117		FIGO IA			ALIVE 2026

Supplementary Files

This is a list of supplementary files associated with this preprint. Click to download.

- Surgicaldysgerminomainternationalpediatric01.10.26tabel.xlsx