Research Square

Preprints are preliminary reports that have not undergone peer review.
They should not be considered conclusive, used to inform clinical practice,
or referenced by the media as validated information.

Title：Metal-Coated Stents as a Treatment Option for Complex Posterior Urethral Strictures in Men: A Retrospective Analysis

Wu Tang
The Second Affiliated Hospital of Kunming Medical University
Jinyi Chu
The Second Affiliated Hospital of Kunming Medical University
Yuanzhi Li
Diqing Tibetan Autonomous Prefecture People's Hospital
Junchao Wu
The Second Affiliated Hospital of Kunming Medical University
Tao Yang
The Second Affiliated Hospital of Kunming Medical University
Tongxin Yang
The Second Affiliated Hospital of Kunming Medical University
Kewei Fang
fkw_waley@126.com

The Second Affiliated Hospital of Kunming Medical University

Research Article

Keywords: urethral stricture, dysuria, urethral stent, urinary incontinence

Posted Date: November 23rd, 2026

DOI: https://doi.org/10.21203/rs.3.rs-11232705/v1

License: This work is licensed under a Creative Commons Attribution 4.0 International License.
Read Full License

Additional Declarations: No competing interests reported.

Title Page

Title： Metal-Coated Stents as a Treatment Option for Complex Posterior Urethral Strictures in Men: A Retrospective Analysis

Authors: Wu Tang[1, *]; Jinyi Chu[1, *]; Yuanzhi Li [2, *]; Junchao Wu[1, *]; Tao Yang [1, *]， Tongxin Yang[1], MD[#]; Kewei Fang[1], MD[##]

* These authors contributed equally to this work

# These two authors contributed equally as co-corresponding authors

Affiliations:

1: Department of Urology, The Second Affiliated Hospital of Kunming Medical University, Kunming 650000，China

2: Department of Urology, Diqing Tibetan Autonomous Prefecture People's Hospital，Diqing，674400，China

Corresponding Author:

Tongxin Yang；Email: yangtongxin@kmmu.edu.cn；Affiliation: Department of Urology, The Second Affiliated Hospital of Kunming Medical University, Yunnan Province, China；Tel: +86-18314360427

Kewei Fang；Email: fkw_waley@126.com；Affiliation: Department of Urology, The Second Affiliated Hospital of Kunming Medical University, Yunnan Province, China；Tel: +86-13529357542

Abstract:

Background: Complex posterior urethral strictures pose a significant therapeutic challenge, particularly in patients who are unsuitable candidates for urethroplasty or in whom such procedures have failed. This study evaluated the efficacy and safety of temporary metal-coated stents in the management of these complex cases.

Methods: A retrospective study was conducted between May 2023 and May 2025 involving 17 male patients with complex posterior urethral strictures treated with Allium metal-coated stents (BUS80 for the membranous urethra; RPS for the bladder neck). We analyzed patient demographics, procedural details, stent retention duration, complications, and urinary outcomes following stent removal.

Results: The median operative time was 90 minutes, with minimal blood loss. Although complications occurred frequently during the stent retention period, they remained manageable. Specifically, patients in the membranous urethral stent group experienced urinary incontinence (7/13, 54%) and pain/discomfort (7/13, 54%), while all patients with bladder neck stents (4/4) developed overactive bladder (OAB) symptoms. A novel “threading” fixation technique effectively mitigated stent migration. Following stent removal (retention duration: 1–21 months), 8 of 9 (89%) patients with membranous urethral strictures achieved spontaneous voiding, while all 4 patients in the bladder neck stent group experienced complete resolution of OAB symptoms.

Conclusion: Metal-coated urethral stents represent an effective therapeutic option for men with complex posterior urethral strictures. While the incidence of complications, including urinary incontinence and OAB, was high during the stent retention period, these were effectively managed and largely reversible following stent removal.

Keywords: urethral stricture; dysuria; urethral stent; urinary incontinence

1. Background

Male urethral stricture is a prevalent urological condition characterized by a high rate of recurrence; its etiology is broadly categorized as idiopathic, iatrogenic, inflammatory, or traumatic [1]. Posterior urethral strictures are primarily attributed to trauma and iatrogenic complications [2]. The prevalence of male urethral stricture in developed nations is approximately 0.6%, with higher rates observed in developing countries[3,4]. The hallmark clinical manifestation is lower urinary tract obstruction; disease progression often precipitates secondary complications, including recurrent urinary tract infections, bladder stones, and urethral fistulae, which may culminate in chronic renal insufficiency, severely compromising the patient's physical and mental well-being [5,6]. Current standard treatments comprise urethral dilation, transurethral incision, and urethroplasty. Given the intricate anatomy and function of the male urethra, the management of strictures remains a significant clinical challenge. In recent years, there has been a notable increase in iatrogenic strictures resulting from complications following transurethral surgery[7]. Management of complex posterior urethral strictures is particularly demanding; these strictures are often deeply situated, exceed 2 cm in length, and are frequently associated with surrounding tissue damage, extensive fibrosis, and urethral fistulae. Such cases necessitate highly invasive surgical interventions, often yielding suboptimal outcomes and high recurrence rates. Furthermore, patients with prior surgical failures typically present with limited healthy tissue and denser, more extensive scarring, rendering reoperation exceedingly challenging. There is an urgent requirement to explore simpler, safer, and more effective modalities to provide therapeutic alternatives for patients with complex posterior urethral strictures who are unsuitable candidates for, or have failed, previous surgical reconstruction.

Urethral stenting is a minimally invasive technique for managing urethral strictures. The procedure involves endoscopic dilation of the narrowed urethral segment, followed by stent insertion.

In cases of complete obstruction, a holmium laser is utilized to establish a lumen, followed by scar tissue dilation prior to stent placement. Initial iterations of this technique were associated with high rates of long-term complications and poor outcomes [8]. With ongoing advancements and the development of metal-coated urethral stents, the morbidity associated with postoperative stenting has been mitigated. While urethral stents are primarily utilized for bulbar urethral strictures, their application in complex posterior urethral strictures—particularly those involving the membranous urethra—remains limited. Nevertheless, based on our clinical experience and emerging literature, metal-coated stents may represent a viable therapeutic option for patients with posterior urethral strictures who have failed prior reconstruction, face technically insurmountable surgical challenges, or decline further reconstructive surgery. This study aims to evaluate the clinical efficacy of metal-coated urethral stents in the treatment of complex posterior urethral strictures in men.

2. Methods

2.1. Clinical data

To evaluate the efficacy and safety of temporary metal-coated stents in the management of Posterior Urethral Strictures in Men, we conducted a retrospective analysis of 17 male patients with complex posterior urethral strictures who underwent Allium metal-coated urethral stent placement at the Second Affiliated Hospital of the Medical University between May 2023 and May 2025. Inclusion criteria were as follows: previous failure of urethroplasty, strictures in deep positions rendering surgical repair technically challenging, or patient refusal of urethroplasty. The stricture locations were the membranous urethra in 13 cases (76%) and the bladder neck in 4 cases (24%). The etiologies included post-pelvic fracture urethral stricture (n=10, 59%), post-transurethral surgery complications (n=5,

29%), recurrent urinary tract infection (n=1, 6%), and idiopathic causes (n=1, 6%). Patient age ranged from 31 to 80 years (mean: 56.8 ± 14.1 yr). Stricture length was determined via retrograde and antegrade urethrography (Additional file 1), with a mean length of 2.0 (1.6–3.0) cm. Among these patients, 13 with primary membranous urethral strictures were treated with a membranous-crossing bulbous urethral stent (BUS80), while 4 with bladder neck strictures received an RPS stent.

2.2. Surgical techniques

All 17 patients were placed in the lithotomy position under general anaesthesia. A cystoscope was inserted via the urethral meatus to evaluate the urethral anatomy, with the location and length of the stricture confirmed by preoperative urethrography. In 9 cases, a guidewire was inserted transurethrally, and the stricture was dilated to 22 Fr under guidance. In the remaining 8 cases, following cystostomy, a urethral probe was inserted retrogradely through the stoma to identify the proximal segment; the distal urethra was subsequently cleared in a proximal direction using a holmium laser, and the stricture was dilated to 22 Fr under guidewire guidance. For the 13 patients with membranous urethral strictures, an Allium BUS-80 stent was placed across the membranous segment, with the proximal end at the bladder neck and the distal end at the bulbous urethra. To mitigate the high risk of stent displacement common in the membranous segment, a novel "needle-and-thread" fixation technique was employed to secure the stent to the bulbous urethra (Figure 1). The 4 patients with bladder neck strictures underwent RPS stent placement. Following the procedure, bladder compression was performed to evaluate urine flow and ensure urethral patency.

3. Results

All procedures were completed successfully, with a median operative time of 90 (range: 83–113) min, intraoperative blood loss of 10 (3.5–20) mL, and a postoperative hospital stay of 3 (2–4) d. Sixteen patients were followed up for a median of 19.5 (12.3–23.8) months (one case involving a trans-membranous urethral stent was lost to follow-up). Stents were removed in 13 cases: 9 BUS80 stents from the membranous urethra and 4 RPS stents from the bladder neck.

Complications during the stent retention period: Almost all patients in the membranous urethral group (13/13) experienced at least one complication. Seven cases (54%) developed urinary incontinence: 5 (38%) with stress urinary incontinence and 2 (15%) with urge urinary incontinence. Four cases (31%) required a penile clamp due to an inability to control urination; however, these symptoms were managed via medication or improved over time. Seven patients (54%) reported pain or discomfort. Five (38%) experienced a decline in urinary flow between 1 and 11 months postoperatively, all associated with the formation of wall-adherent stones. Additionally, 1 patient (8%) required endoscopic repositioning due to stent migration, and 1 (8%) required re-implantation due to stent fracture. All 4 patients in the bladder neck stent group developed varying degrees of overactive bladder (OAB) and pain, with 3 cases (75%) accompanied by urge incontinence.

Follow-up after stent removal: Among the 13 patients in the membranous group, 9 stents were removed. The median stent retention duration was 12 (5–21) months, with a median follow-up of 15 (9–19) months post-removal. Three patients (33%) continued to experience urge incontinence. Eight of these 9 patients (89%) achieved spontaneous voiding post-removal. Among these, 2 (22%) reported a diminished urinary stream but remained capable of spontaneous voiding, requiring urethral dilation

every 2 months; 1 patient (11%) developed recurrent urethral stricture with dysuria. All 4 stents in the bladder neck group (retention duration: 1–15 months) were removed. These patients were followed up for 11–22 months post-removal; all achieved spontaneous voiding, and OAB symptoms resolved completely. One patient underwent early stent removal at another facility due to pain 1 month postoperatively but remained free of voiding difficulty during 22 months of follow-up (Table 1).

4. Discussion

The etiology of posterior urethral stricture in men is frequently associated with pelvic fractures resulting from trauma; severe pelvic fractures may precipitate haemorrhagic shock [9]. These fractures exert significant shearing and compressive forces on the urethra, often resulting in injury to or complete rupture of the membranous urethra. Subsequent scar tissue formation and fibrosis in the surrounding tissues culminate in posterior urethral stricture.

Urethral stricture typically manifests as lower urinary tract obstruction; prolonged voiding difficulty often precipitates secondary conditions, such as lithiasis and infection, and may culminate in upper urinary tract complications. However, due to the unique anatomical location and physiological function of the urethra, alongside a high recurrence rate, management remains a persistent clinical challenge for urologists. Currently, urethroplasty is the gold standard for posterior urethral strictures, offering superior success rates and lower restenosis rates[10]. Nevertheless, posterior urethroplasty is a technically demanding procedure with prolonged operative duration, placing substantial requirements on the surgeon; clinical outcomes and prognosis are highly dependent on surgical expertise. This is particularly evident in complex cases involving post-traumatic membranous urethral stricture and postoperative recurrence, where the stricture is deeply situated, the surgical field is confined with

limited visualization, and the posterior urethra is in close proximity to the prostate, rectum, and the neurovascular bundles of the corpora cavernosa. Intraoperative complications are common, potentially leading to severe haemorrhage, sexual dysfunction, or rectal fistula. Furthermore, scar tissue is characterized by poor vascularity; if not excised thoroughly, it is prone to re-contraction, while factors such as local infection and urinary extravasation can exacerbate stricture recurrence[11,12]. When stricture length exceeds 2 cm, the tension associated with end-to-end urethroplasty is considerable, often compromising surgical success. Failure of primary urethral reconstruction may further complicate subsequent management or necessitate additional procedures[13]. Therefore, exploring safer and more effective treatment modalities for complex posterior urethral strictures—particularly in patients who have failed previous surgery or are unsuitable candidates for further reconstruction—is an urgent clinical necessity.

This study investigated the use of metal-coated urethral stents placed across the membranous urethra or the bladder neck in patients who had failed prior urethroplasty, those with deep-seated strictures confirmed by transurethral cystography that rendered surgery technically challenging, or those who declined further urethroplasty. Compared with urethroplasty, urethral stenting is a more convenient, minimally invasive procedure with relatively lower demands on surgical expertise. Although urethral stenting has been utilized since 1988, initial outcomes were marred by high long-term complication rates, reaching up to 55%[8]. Issues associated with first-generation permanent stents—such as encrustation, migration, stone formation, excessive granulation tissue proliferation, and difficulty in retrieval—have limited their clinical utility [14]. Metal-coated urethral stents, a second-generation

temporary alternative, are manufactured from high-purity nickel-titanium alloy and coated with a copolymer layer to minimize exuberant granulation tissue growth. While primarily designed for bulbar urethral strictures, a multicentre study reported an overall success rate of 76.9% for metal stents, though 49% of cases experienced complications, including foreign body sensation and urinary incontinence[15].

In our investigation of complex posterior urethral conditions, nearly all patients experienced at least one complication during stent therapy. In the trans-membranous placement group, 54% of patients developed urinary incontinence, and 54% reported pain or foreign body sensation. This is closely associated with the placement site: stents deployed trans-membranously are more likely to impinge upon the sphincter, inevitably impairing its function. However, these effects are largely reversible and can be managed with M3 receptor antagonists, β_3-adrenoceptor agonists, and non-steroidal anti-inflammatory drugs; most complications resolve following stent removal at the completion of treatment. Minimizing complications remains a pivotal factor in improving patient satisfaction and clinical outcomes. In this study, the metal-coated, ball-type urethral stent was positioned across the membranous urethra, where displacement is common. To mitigate migration, we employed a "threading" fixation technique: after stent deployment, an 18G needle was used to puncture the perineum at multiple sites to introduce fixation sutures. Two sutures were retrieved transurethrally using lithotripsy forceps and tied together. One suture was then tensioned, and the knot was secured in the perineum to anchor the stent in the bulbous urethra. This procedure significantly reduced the incidence of stent migration.

Regarding the duration of stent placement, some studies suggest that shorter retention periods minimize complications such as tissue ingrowth; a six-month duration is considered safe while providing a bridge for urethral reconstruction[15].Conversely, other data suggest that longer retention may yield superior outcomes; in our series, patients whose stents were left in place for less than six months experienced significantly worse outcomes[16].In this study, the majority of patients retained stents for over six months. In the bladder neck stent group, three patients underwent early removal (before three months) due to severe overactive bladder (OAB) symptoms and pain; however, follow-up indicated no recurrence of voiding difficulty.

In patients who remain symptom-free for over six months post-stent placement and exhibit unobstructed urethral patency on anterograde and retrograde urethrography, stent removal may be considered. Metal-coated urethral stents are easily and completely retrievable under endoscopic guidance (Figure 2), with no observed tissue ingrowth or urethral injury during removal. While some researchers suggest that temporary stent insertion may induce mucosal abrasion proximal or distal to the stricture, promoting granulation tissue proliferation and potentially complicating subsequent urethroplasty[17] , others maintain that no significant urethral injury or subsequent increase in reconstructive complexity is observed[15].The latter finding is consistent with our clinical experience.

We define treatment efficacy as the absence of dysuria recurrence following stent removal, no requirement for further reconstructive surgery, and unobstructed patency on urethrography. While the overall efficacy of stents in the trans-membranous segment may be inferior to that in the bulbous segment, it must be acknowledged that the management of complex posterior urethral strictures is

substantially more challenging than that of anterior strictures. Although urethroplasty remains the treatment of choice for primary membranous urethral strictures, stent placement represents a viable alternative for complex cases where surgery is technically insurmountable, refused by the patient, or has previously failed.

This study has several limitations: firstly, as a retrospective analysis, we were unable to prospectively assess urinary flow rates; secondly, the small sample size and limited follow-up restrict the generalizability of our findings, necessitating larger-scale, long-term validation; finally, given the high incidence of lower urinary tract complications following trans-membranous stent implantation, treatment protocols require further optimization to mitigate patient discomfort.

5. Conclusion

Metal-coated urethral stents, as a simple, safe, and minimally invasive modality, represent a viable therapeutic alternative for men with complex posterior urethral strictures. In particular, the deployment of a ball-tipped urethral stent across the membranous segment demonstrates favourable efficacy in managing traumatic membranous urethral strictures that are recalcitrant to surgical reconstruction. Although the incidence of complications, such as urinary incontinence and pain, remains relatively high during the stent retention period, these are effectively manageable and typically resolve following stent removal. Optimizing treatment protocols to mitigate complications during stent placement is pivotal for enhancing patient satisfaction and clinical outcomes. Given the current sample size, further research is warranted to evaluate long-term efficacy and to refine clinical management protocols.

List of abbreviations :

BUS80 - Bulbar Urethral Stent 80

Fr – French (catheter size)

OAB – Overactive Bladder

RPS – Round Posterior Stent

Declarations

Ethics approval and consent to participate： This study was conducted in accordance with the Declaration of Helsinki and relevant guidelines and regulations. Ethics approval for this study was granted by the Ethics Committee of the Second Affiliated Hospital of Kunming Medical University (Approval No.: PJ-KY-2026-147). Written informed consent was obtained from all participants prior to data collection, treatment, and follow-up.

Consent for publication： Not applicable. All data were anonymized, and no identifying personal or clinical details or images are presented in this manuscript. Therefore, written consent for publication was not required. All participants provided written informed consent for their participation in this study.

The authors declare that they have no known competing financial interests or personal relationships that could have appeared to influence the work reported in this paper.

Funding: This study was supported by Grant No. 202403AP140016 from the Yunnan International Joint R&D Center of Key Technologies in Urological Diagnosis and Treatment, and Grant No. 202405AF140058 from the Yunnan Provincial Department of Science and Technology Expert Workstation Fund， Grant No. XDYC-YLWS-2024-0024 and XDYC-

QNRC-2022-0308 from the Yunnan Revitalization Talent Support Program, and Grant No. RCTDXS-202306 from the Second Affiliated Hospital of Kunming Medical University Talent Echelon Training Project.

Author Contributions: Conceptualization, Wu Tang. And Kewei Fang.; methodology, Tongxin Yang and Jinyi Chu.; val-idation, Junchao Wu. and Yuanzhi Li.; formal analysis, Wu Tang; investigation, Wu Tang and Tao Yang.; data curation, Wu Tang.; writing—original draft preparation, Wu Tang and Jinyi chu.; writing—review and editing, Kewei Fang and Tongxin Yang; funding acquisition, Kewei Fang and Tongxin Yang. All authors have read and agreed to the published version of the manuscript.

Clinical trial number: not applicable.

Availability of data and materials: The data presented in this study are available on request from the corresponding author. The data are not publicly available because no public repository or data link was established for this dataset.

References:

[1] Fenton A S, Morey A F, Aviles R, et al. Anterior urethral strictures: etiology and characteristics[J]. Urology, 2005, 65(6): 1055-1058.

[2] De Farias R B, Neto F T L, De Aguiar Cavalcanti G, et al. Evaluation of the etiological profile, age and findings in retrograde and voiding urethrocystography of men with urethral stricture[J].

Scientific Reports, 2025, 15(1): 5935.

[3] Zheng X, Han X, Cao D, et al. Comparison between cold knife and laser urethrotomy for urethral stricture: a systematic review and meta-analysis of comparative trials[J]. World Journal of Urology, 2019, 37(12): 2785-2793.

[4] Dornbier R A, Kirshenbaum E J, Nelson M H, et al. Socioeconomic and patient-related factors for the management of Male urethral stricture disease[J]. World Journal of Urology, 2019, 37(11): 2523-2531.

[5] Hampson L A, McAninch J W, Breyer B N. Male urethral strictures and their management[J]. Nature Reviews. Urology, 2014, 11(1): 43-50.

[6] King C, Rourke K F. Urethral stricture is frequently a morbid condition: incidence and factors associated with complications related to urethral stricture[J]. Urology, 2019, 132: 189-194.

[7] Cheng X, Ding M, Peng M, et al. The changing trend in clinical characteristics and outcomes of Male patients with urethral stricture over the past 10 years in China[J]. Frontiers in Public Health, 2021, 9: 794451.

[8] Hussain M, Greenwell T J, Shah J, et al. Long-term results of a self-expanding wallstent in the treatment of urethral stricture[J]. BJU International, 2004, 94(7): 1037-1039.

[9] Horiguchi A. Management of Male pelvic fracture urethral injuries: review and current topics[J]. International Journal of Urology: Official Journal of the Japanese Urological Association, 2019, 26(6): 596-607.

[10] Mangir N, Chapple C. Recent advances in treatment of urethral stricture disease in men[J]. F1000Research, 2020, 9: F1000 Faculty Rev-330.

[11] Basile G, Karakiewicz P I, Tian Z, et al. The impact of surgical volume on perioperative safety

after urethroplasty: a population-based study[J]. Minerva Urology and Nephrology, 2023, 75(3): 381-387.

[12] Fossati N, Barbagli G, Larcher A, et al. The surgical learning curve for one-stage anterior urethroplasty: a prospective single-surgeon study[J]. European Urology, 2016, 69(4): 686-690.

[13] Baradaran N, Hampson L A, Edwards T C, et al. Patient-reported outcome measures in urethral reconstruction[J]. Current Urology Reports, 2018, 19(7): 48.

[14] Culha M, Ozkuvanci U, Ciftci S, et al. Management of recurrent bulbar urethral stricture-a 54 patients study with allium bulbar urethral stent (BUS)[J]. International Journal of Clinical and Experimental Medicine, 2014, 7(10): 3415-3419.

[15] Sedigh O, Dalmasso E, Gobbo A, et al. Feasibility and outcomes of temporary bulbar urethral stent placement after internal urethrotomy in the largest multicenter series[J]. European Urology, 2023, 84(3): 313-320.

[16] Üstüner M, Teke K, Bosnalı E, et al. Bulbar urethral stents for bulbar urethral strictures: long-term follow-up after stent removal[J]. Urologia Internationalis, 2022, 106(3): 243-248.

[17] Horiguchi A, Shinchi M, Masunaga A, et al. Do transurethral treatments increase the complexity of urethral strictures?[J]. Journal of Urology, 2018, 199(2): 508-514.

Figure1:

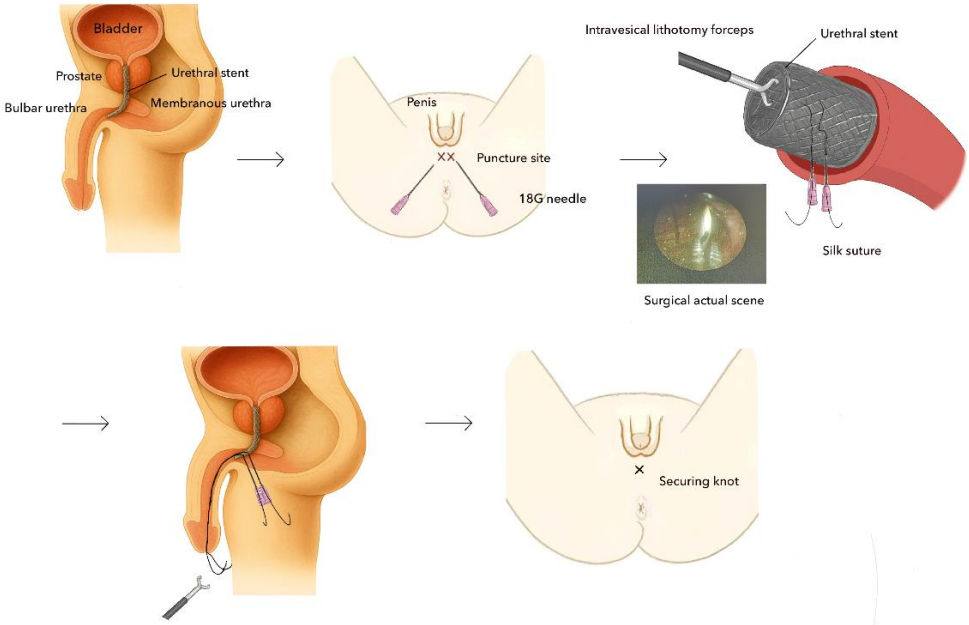

To mitigate migration, we employed a “threading” fixation technique: after stent deployment, an 18G needle was used to puncture the perineum at multiple sites to introduce fixation sutures. Two sutures were retrieved transurethrally using lithotripsy forceps and tied together. One suture was then tensioned, and the knot was secured in the perineum to anchor the stent in the bulbous urethra. This procedure significantly reduced the incidence of stent migration.

Figure 2:



Removal of the stent after treatment. The stent was easily and completely extracted transurethrally, without fragmentation or urethral injury.

Table 1: haracteristics and perioperative outcomes of patients undergoing stent placement for urethral stricture.

Patient No	Etiology	Disease Course, mo	Stricture Location	Stent Type	Stricture Length, cm	Percutaneous Cystostomy	Previous Treatment	Operative Time, min	Intraoperative Bleeding, ml	Postoperative Hospital Stay, days	Postoperative Voiding	Postoperative Incontinence	Calculus	Pain	Recurrent Dysuria	Stent Migration/Collapse	Stent Removal	Stent Indwelling Time, mo	Post-removal Incontinence	Post-removal Voiding Difficulty	Follow-up after Stent Placement, mo
1	Traumatic pelvic fracture	1	Membranous urethra	BUS80	2.00	Yes	Urethroplasty + Urethral dilation	90	1	1	Unobstructed	None	Yes	No	Yes	No	Yes	17	None	Yes	36
2	Traumatic pelvic fracture	48	Membranous urethra	BUS80	3.00	No	Urethroplasty	280	50	2	Unobstructed	Urgency incontinence	No	Yes	No	No	Yes	8	Urgency incontinence	NO	34
3	Traumatic pelvic fracture	3	Membranous urethra	BUS80	3.00	Yes	None	136	50	3	Unobstructed	None	Yes	Yes	Yes	Collapse and Migration	Yes	21	Urgency incontinence	NO	34
4	Traumatic pelvic fracture	6	Membranous urethra	BUS80	3.00	Yes	None	83	10	5	Unobstructed	Stress incontinence	Yes	No	No	No	Yes	16	Urgency incontinence	NO	33

Patient No	Etiology	Disease Course, mo	Stricture Location	Stent Type	Stricture Length, cm	Percutaneous Cystostomy	Previous Treatment	Operative Time, min	Intraoperative Bleeding, ml	Postoperative Hospital Stay, days	Postoperative Voiding	Postoperative Incontinence	Calculus	Pain	Recurrent Dysuria	Stent Migration/Collapse	Stent Removal	Stent Indwelling Time, mo	Post-removal Incontinence	Post-removal Voiding Difficulty	Follow-up after Stent Placement, mo
5	Traumatic pelvic fracture	2	Membranous urethra	BUS80	0.95	No	None	90	1	1	Unobstructed	Stress incontinence	No	No	No	No	Yes	11	None	NO	30
6	Traumatic pelvic fracture	23	Membranous urethra	BUS80	1.00	Yes	None	120	20	2	Unobstructed	Stress incontinence	Yes	No	No	No	Yes	18	None	NO	26
7	Post-prostatectomy	6	Membranous urethra and Bladder neck	BUS80	1.00	No	None	83	10	2	Unobstructed	Stress incontinence	No	Yes	Yes	No	Yes	12	None	NO	24
8	Traumatic pelvic fracture	6	Membranous urethra	BUS80	3.00	No	Urethroplasty	111	20	3	Unobstructed	None	Yes	Yes	No	No	Yes	5	None	NO	23
9	Idiopathic	60	Membranous urethra	BUS80	2.00	No	Urethral dilation	52	2	4	Unobstructed	Stress incontinence	No	Yes	No	No	Yes	11	None	NO	20

Patient No	Etiology	Disease Course, mo	Stricture Location	Stent Type	Stricture Length, cm	Percutaneous Cystostomy	Previous Treatment	Operative Time, min	Intraoperative Bleeding, ml	Postoperative Hospital Stay, days	Postoperative Voiding	Postoperative Incontinence	Calculus	Pain	Recurrent Dysuria	Stent Migration/Collapse	Stent Removal	Stent Indwelling Time, mo	Post-removal Incontinence	Post-removal Voiding Difficulty	Follow-up after Stent Placement, mo
10	Traumatic pelvic fracture	6	Membranous urethra	BUS80	2.00	Yes	Urethroplasty	113	10	2	Unobstructed	None	No	Yes	Yes	Migration	No	.	.	.	35
11	Traumatic pelvic fracture	4	Membranous urethra	BUS80	5.40	Yes	None	201	20	5	Unobstructed	None	No	Yes	Yes	No	No	.	.	.	22
12	Post-prostatectomy	24	Membranous urethra and Bladder neck	BUS80	3.00	No	None	44	5	3	Unobstructed	Urgency incontinence	No	No	No	No	No	.	.	.	18
13	Traumatic pelvic fracture	3	Membranous urethra	BUS80	2.00	Yes	Urethroplasty	83	2	4	Unobstructed	Lost to follow-up	Lost to follow-up	Lost to follow-up	Lost to follow-up	Lost to follow-up	Lost to follow-up	Lost to follow-up	Lost to follow-up	Lost to follow-up	Lost to follow-up

Patient No	Etiology	Disease Course, mo	Stricture Location	Stent Type	Stricture Length, cm	Percutaneous Cystostomy	Previous Treatment	Operative Time, min	Intraoperative Bleeding, ml	Postoperative Hospital Stay, days	Postoperative Voiding	Postoperative Incontinence	Calculus	Pain	Recurrent Dysuria	Stent Migration/Collapse	Stent Removal	Stent Indwelling Time, mo	Post-removal Incontinence	Post-removal Voiding Difficulty	Follow-up after Stent Placement, mo
14	Post-bladder tumor resection	24	Bladder neck	RPS	5.00	No	None	61	10	5	Unobstructed	Urgency incontinence	No	Yes	No	No	Yes	3	None	NO	16
15	Urinary tract infections	1	Bladder neck	RPS	1.00	No	None	74	10	2	Unobstructed	Urgency incontinence	Yes	Yes	No	No	Yes	3	None	NO	20
16	Post-prostatectomy	1	Bladder neck	RPS	1.60	No	None	90	5	2	Unobstructed	Urgency incontinence	Yes	Yes	No	Migration	Yes	15	None	NO	11
17	Post-prostatectomy	6	Bladder neck	RPS	2.00	Yes	Urethral dilation + Scar release	83	5	3	Unobstructed	None	No	Yes	No	No	Yes	1	None	NO	23

Supplementary Files

This is a list of supplementary files associated with this preprint. Click to download.

- Additionalfile1Urethrographyimagesofpatients.docx
- Additionalfile1Urethrographyimagesofpatients.pdf