Research Square

Preprints are preliminary reports that have not undergone peer review.
They should not be considered conclusive, used to inform clinical practice,
or referenced by the media as validated information.

Paracoracoid versus costoclavicular infraclavicular block: a prospective two arm non- inferiority randomized comparative trial

Brigid Brown

brigid.brown@gmail.com

Western University

Richard Woodman

Flinders University

D-Yin Lin

Flinders Medical Centre

Pauline Magsaysay

De Los Santos Medical Center

Yves Bureau

Western University

Janice Yu

McMaster University

Shalini Dhir

Western University

Research Article

Keywords: paracoracoid, costoclavicular, infraclavicular block, non-inferiority, brachial plexus, regional anesthesia

Posted Date: November 25th, 2026

DOI: https://doi.org/10.21203/rs.3.rs-11226812/v1

License: This work is licensed under a Creative Commons Attribution 4.0 International License.
Read Full License

Additional Declarations: No competing interests reported.

Abstract

Background

Paracoracoid approach (PC) for the infraclavicular brachial plexus block is the conventional technique for upper limb surgeries. In this approach, the ultrasound transducer is placed in the coronal plane below the clavicle, medial to the coracoid process. In this view, all three cords are separated from each other around the axillary artery and are rarely visualized in a single ultrasound window. The costoclavicular approach (CC) is a recently described technique in which the ultrasound transducer is placed parallel to the clavicle and the block needle is inserted in-plane from a lateral direction into the costoclavicular space. The cords are clustered together around the lateral edge of the artery at a more superficial level and may be easier to visualize with less needle manipulation to perform the block. We conducted a non-inferiority randomized trial comparing these two infraclavicular approaches, hypothesizing that the costoclavicular technique would be non-inferior to the paracoracoid technique in sensory block onset time.

Methods

In this observer-blinded trial, we randomised 70 patients to receive either a paracoracoid or costoclavicular infraclavicular block. Both groups received 35 mL of 0.5% ropivacaine injected under ultrasound guidance with nerve stimulation assistance. The primary outcome was sensory block onset time while secondary measured outcomes included performance times, complications during block insertion (paresthesia, vascular puncture, pleural puncture), block failure, patient satisfaction, and postoperative complications. Patients were followed up by phone call at postoperative days one and seven.

Results

In per-protocol analysis (n = 64), mean sensory onset was 18.68 ± 4.36 minutes (PC) vs 22.17 ± 6.18 minutes (CC; p = 0.042). In intention to treat analysis (ITT) (N = 70), the between-group difference was 1.00 minute (95% CI, -2.05 to 4.05). The upper CI limit (4.05 minutes) was below the pre-specified 5-minute non-inferiority margin.

Trial Registration

This trial was prospectively registered with Clinicaltrials.gov in December 2015, NCT02657291

KEY FINDINGS

Non-Inferiority Demonstrated: For the primary outcome (Sensory Onset), the gold standard ITT analysis shows that the upper bound of the 95% CI for the difference is 4.05 minutes. This falls safely within the pre-specified 5-minute non-inferiority margin, allowing us to conclude that the costoclavicular (CC) approach is clinically non-inferior to the paracoracoid (PC) approach.

Impact of ITT on Secondary Outcomes: While the PC and CC groups were borderline in Total Procedure Time in the PP analysis (p=0.058), the inclusion of the full ITT cohort makes this difference statistically significant (p=0.023) utilizing the 'worse case scenario' method.

Clinician Trade-off: The final data indicates that although the CC approach is non-inferior in clinical block onset, the traditional PC approach remains significantly faster to perform, particularly regarding needling time (p=0.006 in ITT).

Background

The infraclavicular brachial plexus block is a widely used regional anesthesia technique for distal upper-limb surgery (1). Though multiple approaches have been described, paracoracoid approach is traditionally used worldwide(2, 3). In the last fifteen years, the use of ultrasound guidance has become popular for this conventional approach (4). However, with this approach, all three cords of the brachial plexus are separated from one another and may not be seen in a single ultrasound window (5-7). There can also be significant variation in the position of the individual cords relative to the axillary artery (6).

A new approach to the infraclavicular block has been described in the literature in which the ultrasound transducer is placed parallel and inferior to the clavicle and the block needle is inserted in-plane from a lateral to medial direction into the costoclavicular area, the space between the posterior surface of the clavicle and the second rib. Sala-Blanch and colleagues have described how at this position, the cords are clustered together around the lateral edge of the artery at a more superficial level compared with the paracoracoid view (8). It has been suggested that the cords and needle may therefore be easier to visualize with less needle manipulation to perform the procedure, potentially resulting in a faster onset of the block and a lower incidence of complications. Promising results have been reported by several researchers (9-12). Block onset time has significant implications in smooth running of the operating room, and it can influence the choice of the anesthetic technique. The primary aim of this study was to compare sensory block onset time between the costoclavicular and conventional paracoracoid approaches.

We undertook a non-inferiority randomized trial to test whether the costoclavicular approach was not clinically worse than the paracoracoid approach by more than 5 minutes in sensory onset time. Secondary endpoints included procedure time, procedure related pain and complications, surgical block success and any supplementation and patient satisfaction.

Ethics Approval and Consent to Participate

Institutional ethics was approved (#106875, London Health Sciences Centre Research Institute, London, Ontario) and registration in December 2015 with clinicaltrials.gov (NCT02657291). Written informed consent was gained from all participants in the study in accordance with the Declaration of Helsinki.

Methods

We prospectively enrolled 70 adult American Society of Anesthesiologists physical status I-III patients aged 18-80 years scheduled for elective ambulatory upper limb surgery of the elbow, forearm, wrist, or hand under regional anesthesia. Exclusion criteria included coagulopathy, local anesthetic drug allergy, local site infection or scarring, body mass index greater than 35 kg/m2, failure to understand pain scores, pregnancy and breastfeeding, and chronic narcotic use. The study was conducted at the Hand and Upper Limb Centre, St. Joseph's Hospital in London, Ontario. The study methodology aligns to CONSORT guidelines (available as appendix A).

Patients were randomly assigned by computer-generated sequence to one of two groups, each with 35 subjects, to receive either a paracoracoid or costoclavicular approach to their infraclavicular block. Group allocations were concealed in opaque envelopes and opened by the anesthetist performing the block, who performed the designated block and then had no further involvement in data collection. All blocks were initiated in a dedicated block room space under aseptic conditions, following intravenous access and the application of standard monitoring and performed by operators well versed with both techniques (SD, BB, PM). All blocks were ultrasound-guided and peripheral nerve stimulation assisted. Lidocaine 1% (3-5 ml) was used for subcutaneous infiltration prior to initiation of the block, with further supplements as necessary. A Sonosite M-Turbo ultrasound (SonoSite Inc., Bothell, WA, USA) with a high-frequency 10-6 MHz linear array transducer probe with a sterile cover and an 80 mm needle (Pajunk® Geisingen, Germany) were used for all blocks. All patients received a total of 35 mL of 0.5% ropivacaine delivered in aliquots. Patients in both groups also received an intercostobrachial nerve block with 5 ml of 1.5% lidocaine for tourniquet pain(13). Complications during block performance such as vascular puncture and paresthesia with needle placement were documented. Once the block was completed, the injection sites of both possible injection areas were concealed with a dressing to ensure observer blinding.

Block performance

The paracoracoid approach: An ultrasound guided parasagittal paracoracoid (deltopectoral) approach as described earlier was used, with the needle positioned at the six o' clock position, just inferior to the axillary artery, in an in-plane approach (14). Correct position was confirmed with a motor response at 0.5 mA (pulse width 0.1 ms, frequency 2 Hz) with electric nerve stimulation marking either medial cord (finger flexion) or posterior cord (wrist/elbow extension). Two third of the drug was deposited at the six

o'clock location aiming at the posterior cord while remaining one third was deposited at the nine o'clock location aiming at the lateral cord, during needle retraction.

The costoclavicular approach: An ultrasound guided approach as described by Karmakar et al (15) was used. The ultrasound transducer was placed parallel and inferior to the clavicle and angled cephalad to optimize the view. The block needle inserted in-plane from a lateral to medial direction into the costoclavicular space (the space between the posterior surface of the clavicle and the second rib). Correct position was confirmed with a motor response at 0.5 mA (pulse width 0.1 ms, frequency 2 Hz) with electric nerve stimulation marking either medial cord (finger flexion) or posterior cord (wrist/elbow extension).

After block and dressing placement, a blinded observer (JY) unaware of block assignments and not present during block placement performed all assessments of block onset. Motor and sensory block onset of median, radial, ulnar, musculocutaneous, and axillary nerves was evaluated every 5 minutes until the block was complete, or until 30 minutes had elapsed. Sensory block was tested with ice in the appropriate dermatomes of the brachial plexus (2 = normal sensations; 1 = loss of some cold sensations; and 0 = total loss of cold sensations). An effective sensory block was complete absence of cold sensations (score of 0) in all nerve distributions. Concurrently, motor block was evaluated (median: thumb opposition; ulnar: finger abduction; radial: wrist/elbow extension; musculocutaneous: elbow flexion) using a similar scale (2 = normal movements possible, 1 = reduced movements but not able to perform movements against resistance, and 0 = total loss of motor power). For incompletely blocked patients at the end of 30 minutes, the surgery proceeded either with supplemental blocks and/or deep sedation or general anesthesia. A single unblocked nerve territory was supplemented distally, at the axilla. If there were more than one unblocked nerve, a plexus block was repeated at a different site. If there was insufficient time for local anesthetic supplementation, patients underwent a general anesthetic.

Outcomes measurements

The primary outcome was time from completion of local anesthetic injection to complete sensory block (score 0 in all five nerve distributions), assessed up to 30 minutes. Secondary outcomes included procedure time, block failure leading to technique supplementation or conversion to general anesthetic, complications during block insertion (vascular puncture, pleural puncture, and paresthesia) and other postoperative complications and patient satisfaction. Patients whose block data could not be collected were excluded from the analysis. Patients who required deep sedation because they did not want to be awake/aware during the surgery were not assigned as block failures.

All patients were telephoned on postoperative day 1 and 7 by the blinded observer who asked standardized questions regarding postoperative complications including nausea, vomiting, opioid use, weakness, persistent paresthesia, pain (standardized scale from 0 = no pain to 10 = worst pain imaginable) and overall block/anesthesia related satisfaction (standardized scale from 0 = completely dissatisfied to 10 = completely satisfied). All adverse events were followed up until resolved.

Statistical Analysis

SAMPLE SIZE CALCUALTION

Sample size was based on the mean sensory block onset time. We used comparison of two means to calculate the sample size with a type 1 error of 5% (two-sided alpha of 0.05) and power (1-beta) of 85% (16). We prespecified a non-inferiority margin of 5 minutes, considering smaller differences in onset time to be clinically unimportant. Assuming an onset time SD of 7.1 minutes taken from a previously published study (17), we calculated that 58 patients total were required to achieve a power of 85% to declare that the lower limit of a one-sided 95% confidence interval (or equivalently a 90% two-sided confidence interval) would be above the limit of -5(18). To accommodate for loss of retention, enrollment was increased to a total of 70 patients for this study. Assuming a procedure time SD of 17 sec from the same study [14], this sample size was also sufficient to be 80% sure that the lower limit of a one sided 95% confidence interval (or equivalent 90% two-sided confidence interval was above the limit of -12 sec. We did a post-hoc power calculation based on the mean (SD) onset time of 20.8 (6.4) min for all study patients and found that the study was powered to detect a 5 min difference in mean onset time at p = 0.05 and 90% power.

INTENTION TO TREAT AND PER PROTOCOL ANALYSES

Data entry and statistical analyses were conducted in a blinded fashion. Primary and secondary outcomes were analyzed on an Intention-to-Treat (ITT) basis, including all 70 randomized patients (35 per group) to preserve the benefits of randomization. For the primary outcome, missing data for the six patients who did not complete the assessment (5 in the PC group, 1 in the CC group) were handled using a conservative "worst-case" imputation, assigning them the maximum study observation time of 30 minutes. For continuous secondary outcomes (e.g., procedure time), missing values were handled by imputing the group mean.

Between-group differences were assessed using independent samples t-tests assuming equal variances to remain consistent with prior preliminary analyses. Non-inferiority was established if the upper limit of the two-sided 95% confidence interval (CI) for the mean difference in sensory onset (CC minus PC) was less than 5 minutes. Categorical variables were compared using the Chi-squared test or Fisher’s exact test. All statistical analyses were performed using Stata 19 (StataCorp, College Station, Texas, USA). A p-value of <0.05 was considered statistically significant.

Results

74 patients were assessed for eligibility, of which 70 patients were randomized for this study, with 35 patients in each group (Figure 1. CONSORT diagram). Of 70 randomized patients (35 per group), 30 in the paracoracoid (PC) group and 34 in the costoclavicular (CC) group were included in the per-protocol

analysis. One patient in CC group had local anesthetic systemic toxicity (LAST) and was resuscitated with intralipid. Figure 1 is a Consort Diagram demonstrating the study protocol.

There were 5 patients in the PC group whose assessment could not be completed. The two groups were comparable in terms of patient characteristics and surgical procedures performed (table 1).

Table 1 - Patient Demographics. Values are reported as mean or number of subjects (n) or (%) as indicated.

	Paracoracoid	Costoclavicular
Age mean (SD) yr	47.4 (20)	49.4 (15.7)
Weight mean (SD) kg	80.2 (14.2)	74.6 (15.6)
BMI mean (SD) kgm-2	27.6 (5.5)	26.2 (4.6)
Male:Female (n)	19:11	15:19
ASA 1 (n)	10	12
ASA 2 (n)	15	18
ASA 3 (n)	5	4
Surgery Type		
Elbow (n)	6	7
Wrist (n)	13	14
Hand (n)	11	13

Primary Outcome: Sensory Block Onset

In the per-protocol analysis (N=64), the mean sensory onset time was 18.68 ± 4.36 minutes for the PC group and 22.17 ± 6.18 minutes for the CC group (p=0.042). However, in the intention-to-treat (ITT) analysis (N=70), the mean difference between groups was only 1.00 minute (95% CI, -2.05 to 4.05). Because the upper limit of the 95% CI (4.05 minutes) did not exceed the pre-specified non-inferiority margin of 5 minutes, the costoclavicular approach was demonstrated to be non-inferior to the paracoracoid approach for sensory block onset. These findings are summarized in Table 2.

Table 2: Comparison of Per-Protocol vs. Intention-to-Treat Results. *Denotes significance

Outcome Measure	Analysis Type	PC Mean (SD/95% CI)	CC Mean (SD/95% CI)	Difference (95% CI)	P-value
Sensory Onset	PP (N=64)	18.68 (16.58–20.79)	22.17 (19.50–24.85)	3.49 (0.13–6.85)	0.042
(Minutes)	ITT (N=70)	23.86 (21.61–26.10)	24.86 (22.71–27.00)	1.00 (-2.05–4.05)	0.515
Total Procedure	PP (N=64)	188.83 (168.59–209.07)	215.54 (195.94–235.15)	26.71 (-1.11–54.54)	0.058
(Seconds)	ITT (N=70)	188.83 (171.18–206.49)	215.54 (199.30–231.79)	26.71 (3.78–49.64)	0.023*
Needling Time	PP (N=64)	162.17 (145.33–179.01)	188.47 (169.97–206.97)	26.30 (1.54–51.06)	0.038*
(Seconds)	ITT (N=70)	162.17 (148.16–176.18)	188.47 (174.15–202.79)	26.30 (7.84–44.77)	0.006*

Secondary Outcomes: Procedural Efficiency

Significant differences were observed in procedural metrics. In the ITT analysis, the paracoracoid approach was significantly faster than the costoclavicular approach for both total procedure time (PC: 188.83s vs. CC: 215.54s; p=0.023) and needling time (PC: 162.17s vs. CC: 188.47s; p=0.006). Imaging times remained comparable between the two groups.

There were no intergroup differences in block failure, motor block onset, complications during block performance or postoperatively (table 3).

Table 3 – Block Characteristics - Values are reported as mean or number of subjects (n).

	Paracoracoid (n=35)	Costoclavicular (n=35)	p-value
Block Success/Interventions			
Supplemental local anesthetic in Block Room required(n)	1	2	0.63
Surgical supplementation required (n)	0	2	0.18
General anesthetic required (n)	1	2	0.63
Complications			
Paresthesia during procedure (n)	3	0	0.06
Vascular Puncture (n)	1	0	0.28
Postoperative Nausea and/or Vomiting (n)	2	2	0.95
Postoperative Numbness or Tingling (n)	5	6	0.92
Postoperative Weakness (n)	0	2	0.16
Patient Satisfied and Would Have Procedure Again (n)	35	34	0.96

At 30 minutes, complete sensory block was achieved in 28/30 patients (93.3%) in the paracoracoid group and 28/34 (82.3%) in the costoclavicular group (risk difference 11.0%, 95% CI −8.9 to 30.9; p=0.63). The need for conversion to GA (PC 1 vs CC 2, p=0.63), local anesthetic supplementation (PC 0 vs CC 2, p=0.18) or rescue block (PC 1 vs CC 2, p=0.63) were similar between the groups. The block onset pattern varied between the groups. The CC group had a faster initial onset with 21% of patients demonstrating a sensory block after 5 minutes compared with only 13% in the PC group. However, beyond 10 minutes from the completion of the block, the sensory block onset was comparable between the two groups. Details of the pattern of surgical readiness are in the figure and show no difference between the two groups (Figures 2 and 3. Block onset, Motor onset respectively).

Discussion

The primary finding of this study is that the costoclavicular approach is non-inferior to the paracoracoid approach regarding sensory block onset. While the cords are anatomically clustered in the

costoclavicular space, this did not translate into a faster clinical onset compared to the traditional paracoracoid approach. This suggests that the depth and orientation of the cords in the costoclavicular space may offset the theoretical advantage of their proximity.

The paracoracoid approach was faster to perform. It could be argued that the difference in times is statistically significant, but not clinically significant for both total procedure time (PC: 188.83s vs. CC: 215.54s; p=0.023) and needling time (PC: 162.17s vs. CC: 188.47s; p=0.006). This increased time for costoclavicular block time may be attributed to the steeper angle of needle insertion required or the more medial location, which can be technically more challenging than the more lateral paracoracoid view. Clinicians must weigh the purported benefits of the costoclavicular approach such as easier visualization of all three cords in one window against the increased procedural time required to achieve the block.

A surprising finding from this investigation was the pattern of the sensory block onset. In the first 5 minutes after the block performance, the CC group showed sensory block onset in 21% patients whereas only 13% were blocked in the PC group. However, by ten minutes, there was no difference noted (figure block onset). In the CC group, only a very small percentage of blocks required greater than 20 minutes for complete sensory onset (2.3%) whereas in the PC group, the block continued to progress and another 10% of patients showed sensory block onset by the end of 30 minutes. This pattern was not observed in the motor block onset, where the block onset continued to progress in both groups until the end of the testing time of 30 minutes. It is not possible to speculate on the reason for this. Previous authors have noted and explained this difference as a result of using large volumes of local anesthetic affecting the pattern of block onset (19). Minimum effective volume studies were proposed to further investigate if lower volumes would influence the block onset in a similar way. While it is possible that the volume theory may account for some component of the block onset, it does not seem to fully explain this phenomenon. It has been noted that the minimum effective volume for 90% of the patient population (MEV90) for the paracoracoid as well as costoclavicular approaches are 34 ml (20, 21). Therefore, the doses used in the current study were consistent with these studies and do not fully explain the sensory block onset behaviour. Another interesting finding was the earlier sensory block onset of the axillary nerve in the paracoracoid approach. While this study was not powered to evaluate the significance of individual nerve block onset, one possible explanation could be the pattern in which the axillary nerve fibers are located in the posterior cord. Nerve fibers supplying the proximal anatomic structures form the outer mantle of the nerve and may be exposed the local anesthetic agent earlier (22). This may account for an earlier sensory block onset of the axillary nerve in the paracoracoid group. The paracoracoid block is performed in the lateral infraclavicular fossa where the axillary nerve is ready to branch off the posterior cord. At this distal location, the nerve fibers may be more superficial with the potential of the local anesthetic reaching its fibers it earlier. On the other hand, because the costoclavicular space is in the medial infraclavicular fossa where the axillary nerve is still an integral part of the posterior cord, the fibers may be more embedded within the posterior cord matrix.

One patient in the CC group had LAST and required intralipid for resuscitation. Though rare, the quoted incidence of LAST is 0.27% (23) and its possibility cannot be excluded despite very careful technique.

Limitations

We need to remark on several limitations of this study. First, it was designed as a non-inferiority study. With an equivalence trial on the subject showing no intergroup differences (19), we chose a non-inferiority design for this study. It is known that equivalence dismisses the option that the new treatment could be superior. Failure to demonstrate a statistically significant difference does not prove that the two treatments are equivalent or even similar (24). In a non-inferiority design, the difficulty is in choosing the value of delta. The non-inferiority margin or delta of 5 min was based purely on clinical grounds and required us to choose a cut-off point.

We chose a volume of 35 mL for both techniques. This volume has been established as the MEV90 for the conventional paracoracoid approach (20). However, the right volume for the costoclavicular approach has not been established though a similar MEV90 has been suggested (21).

There has been much interest in a more medial approach to the brachial plexus in the infraclavicular area. Though the costoclavicular approach has been a recent nomenclature, proximal, medial, vertical approaches essentially describe the same location and there have been multiple studies evaluating the block characteristics of these approaches (9, 11, 15, 25). Results from past studies comparing the two techniques have been equivocal. Some technical reports have led us to believe that medial approaches like costoclavicular may be better and quicker for infraclavicular block (8, 9, 19, 26). Multiple studies evaluating the feasibility of the costoclavicular approach to the infraclavicular block have been undertaken but there are very few studies directly comparing the two approaches. There have also been a few comparative studies with different results. Leurcharusmee et al compared the costoclavicular approach it to the conventional paracoracoid approach and found no difference (19). The study by Mosaffa and colleagues compared the nerve stimulation guided conventional coracoid approach to the more medial vertical infraclavicular approach and found the former to be superior (27). Songthamwat et al found faster block onset and readiness for surgery with the costoclavicular approach (28). In the present study, we found faster sensory block onset with the conventional paracoracoid approach. The procedure time was not different statistically though there was a mean difference of a few seconds between the two techniques. Both techniques were found to be effective techniques for ambulatory upper limb surgery. Given the small number of comparative studies and modest sample sizes, these findings should be interpreted with caution.

There may be indications for using the proximal technique for catheter insertion and in obese patients as the space is narrower and shallower in the more proximal approach. It is known that the space narrows further with arm abduction and this may be useful in obese patients whose plexus is located deeper in the more distal paracoracoid area (29). This may justify the need for further studies to evaluate the feasibility of this approach in special subgroup of patients as well indwelling regional catheter techniques.

Conclusion

Compared with the traditional paracoracoid technique, the novel costoclavicular approach to infraclavicular brachial plexus block did not outperform the traditional paracoracoid technique and resulted in longer time to the sensory block onset but demonstrated similar procedure time, block success and similar complication rates for ambulatory upper limb surgery.

Abbreviations

PC
Paracoracoid
CC
Costoclavicular
LAST
Local Anesthestic Systemic Toxicity
n
number

Declarations

Ethics approval and consent to participate

Institutional ethics was approved (#106875, London Health Sciences Centre Research Institute, London, Ontario) and registration in December 2015 with clinicaltrials.gov (NCT02657291). Written informed consent was gained from all patients in accordance with the Declaration of Helsinki.

Consent for publication

Not applicable

Availability of data and materials

All materials described in this manuscript can be made freely available to scientists wishing to use them for non-commercial purposes on request. Please contact the primary author Brigid Brown at brigid.brown@gmail.com to obtain access to the raw data analyzed in this study.

Competing Interests

No authors have conflicts of interest to declare

Funding

No funding was received for this study

Authors' contributions

BB – study design, data collection, data analysis, manuscript writing
RW – methodological input, statistical analysis
DYL – data analysis, manuscript preparation
PM – study design, data collection, manuscript drafting
YB – methodological input, manuscript drafting
JY – data collection, manuscript drafting
SD – overall supervision, study design, and approval of final manuscript

Acknowledgements

No acknowledgements

References

1. Chin KJ, Alakkad H, Adhikary SD, Singh M. Infraclavicular brachial plexus block for regional anaesthesia of the lower arm. Cochrane Database Syst Reviews. 2013(8).
2. MacFarlane A, Anderson K. Infraclavicular brachial plexus blocks. Continuing Educ Anaesth Crit Care Pain. 2009;9(5):5.
3. Tran DH, Russo G, Munoz L, Zaouter C, Finlayson RJ. A Prospective, Randomized Comparison Between Ultrasound-Guided Supraclavicular, Infraclavicular, and Axillary Brachial Plexus Blocks. Reg Anesth Pain Med. 2009;34(4):366–71.
4. Porter JM, McCartney CJL, Chan VWS. Needle placement and injection posterior to the axillary artery may predict successful infraclavicular brachial plexus block: a report of three cases. Can J Anaesthesia-Journal Canadien D Anesthesie. 2005;52(1):69–73.
5. Di Filippo A, Orando S, Luna A, Gianesello L, Boccaccini A, Campolo MC, et al. Ultrasound identification of nerve cords in the infraclavicular fossa: a clinical study. Minerva Anestesiol. 2012;78(4):450–5.
6. Sauter AR, Smith H-J, Stubhaug A, Dodgson MS, Klaastad O. Use of magnetic resonance imaging to define the anatomical location closest to all three cords of the infraclavicular brachial plexus. Anesth Analg. 2006;103(6):1574–6.
7. Lapegue F, Faruch-Bilfeld M, Demondion X, Apredoaei C, Bayol MA, Artico H, et al. Ultrasonography of the brachial plexus, normal appearance and practical applications. Diagn Interv Imaging. 2014;95(3):259–75.

8. Sala-Blanch X, Reina MA, Pangthipampai P, Karmakar MK. Anatomic Basis for Brachial Plexus Block at the Costoclavicular Space A Cadaver Anatomic Study. Reg Anesth Pain Med. 2016;41(3):387–91.
9. Li JW, Songthamwat B, Samy W, Sala-Blanch X, Karmakar MK. Ultrasound-Guided Costoclavicular Brachial Plexus Block Sonoanatomy, Technique, and Block Dynamics. Reg Anesth Pain Med. 2017;42(2):233–40.
10. Garcia-Vitoria C, Vizuete J, Lopez Navarro AM, Bosch M. Costoclavicular Space A Reliable Gate for Continuous Regional Anesthesia Catheter Insertion. Anesthesiology. 2017;127(4):712.
11. Silva GR, Borges DG, Lopes IF, Ruzi RA, Rabello de Macedo Costa PR, da Silva Mandim BL. Ultrasound-guided costoclavicular block as an alternative for upper limb anesthesiain obese patients. Revista brasileira de anestesiologia. 2019;69(5):510–3.
12. Beh ZY, Hasan MS. Ultrasound-guided costoclavicular approach infraclavicular brachial plexus block for vascular access surgery. J Vasc Access. 2017;18(5):E57–61.
13. Hadzic A. Cutaneous Blocks for the Upper Extremity – Landmarks and Nerve Stimulator Technique 2020 [Available from: https://www.nysora.com/techniques/upper-extremity/distal-nerves/cutaneous-blocks-upper-extremity/
14. Dhir S, Brown B, Mack P, Bureau Y, Yu J, Ross D. Infraclavicular and supraclavicular approaches to brachial plexus for ambulatory elbow surgery: A randomized controlled observer-blinded trial. J Clin Anesth. 2018;48:67–72.
15. Karmakar MK, Sala-Blanch X, Songthamwat B, Tsui BCH. Benefits of the Costoclavicular Space for Ultrasound-Guided Infraclavicular Brachial Plexus Block Description of a Costoclavicular Approach. Reg Anesth Pain Med. 2015;40(3):287–8.
16. Donner A. Approaches to sample-size estimation in the design of clinical trials - a review. Stat Med. 1984;3(3):199–214.
17. Fredrickson MJ, Patel A, Young S, Chinchanwala S. Speed of onset of 'corner pocket supraclavicular' and infraclavicular ultrasound guided brachial plexus block: a randomised observer-blinded comparison. Anaesthesia. 2009;64(7):738–44.
18. Dhand N, Khatkar M, Statulator. An online statistical calculator. Sample Size Calculator for Comparing Two Independent Means. 2014 [Available from: http://statulator.com/SampleSize/ss2M.html
19. Leurcharusmee P, Elgueta MF, Tiyaprasertkul W, Sotthisopha T, Samerchua A, Gordon A, et al. A randomized comparison between costoclavicular and paracoracoid ultrasound-guided infraclavicular block for upper limb surgery. Can J Anesthesia-Journal Canadien D Anesthesie. 2017;64(6):617–25.
20. Tran DQH, Dugani S, Dyachenko A, Correa JA, Finlayson RJ. Minimum Effective Volume of Lidocaine for Ultrasound-Guided Infraclavicular Block. Reg Anesth Pain Med. 2011;36(2):190–4.
21. Sotthisopha T, Elgueta MF, Samerchua A, Leurcharusmee P, Tiyaprasertkul W, Gordon A, et al. Minimum Effective Volume of Lidocaine for Ultrasound-Guided Costoclavicular Block. Reg Anesth Pain Med. 2017;42(5):571–4.

22. Strichartz G, Pastijin E, Sugimoto K. Neural Physiology and Local Anesthetic Action. In: Cousins M, Bridenbaugh P, Carr D, Horlocker T, editors. Cousins and Bridenbaug's neural blockade in clinical anesthesia and pain. 4th ed. Philadelphia, PA: Lippincott, Williams and Wilkins; 2009. pp. 26–48.
23. El-Boghdadly K, Pawa A, Chin KJ. Local anesthetic systemic toxicity: current perspectives. Local Reg Anesth. 2018;11:35–44.
24. Pocock SJ. The pros and cons of noninferiority trials. Fundam Clin Pharmacol. 2003;17(4):483–90.
25. Yoshida T, Watanabe Y, Furutani K. Proximal approach for ultrasound-guided infraclavicular brachial plexus block. Acta anaesthesiologica Taiwanica: official J Taiwan Soc Anesthesiologists. 2016;54(1):31–2.
26. Bigeleisen P, Wilson M. A comparison of two techniques for ultrasound guided infraclavicular block. Br J Anaesth. 2006;96(4):502–7.
27. Mosaffa F, Gharaei B, Rafeeyan M, Gachkar L. Comparing vertical and coracoid approaches for infraclavicular block in orthopedic surgery of the forearm and hand. J Clin Anesth. 2012;24(3):196–200.
28. Songthamwat B, Karmakar MK, Li JW, Samy W, Mok LYH. Ultrasound-Guided Infraclavicular Brachial Plexus Block Prospective Randomized Comparison of the Lateral Sagittal and Costoclavicular Approach. Reg Anesth Pain Med. 2018;43(8):825–31.
29. Hooper TL, Denton J, McGalliard MK, Brismee J-M, Sizer PS Jr. Thoracic outlet syndrome: a controversial clinical condition. Part 1: anatomy, and clinical examination/diagnosis. J Man Manip Ther. 2010;18(2):74–83.

Figures

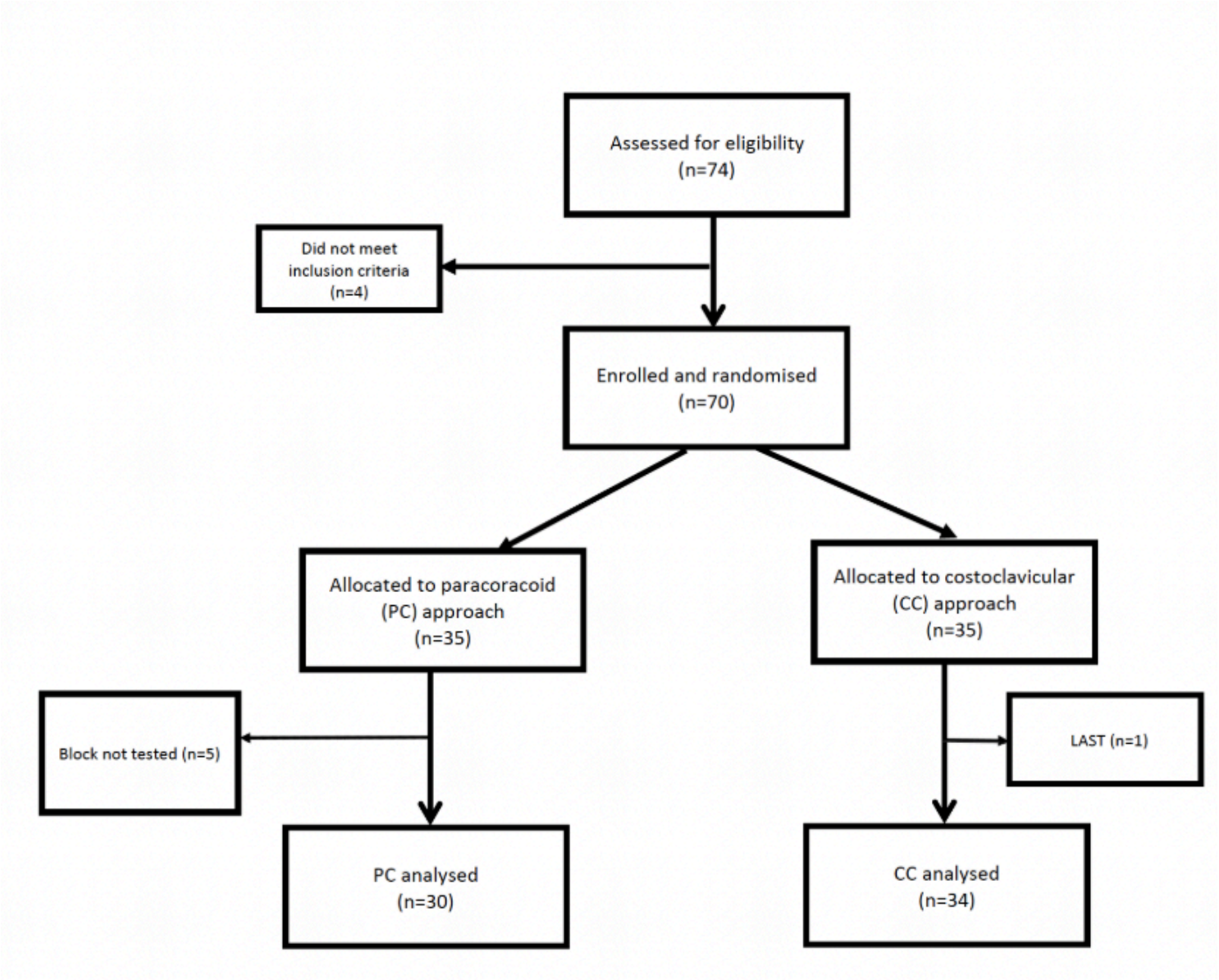

Figure 1

Legend not included with this version.

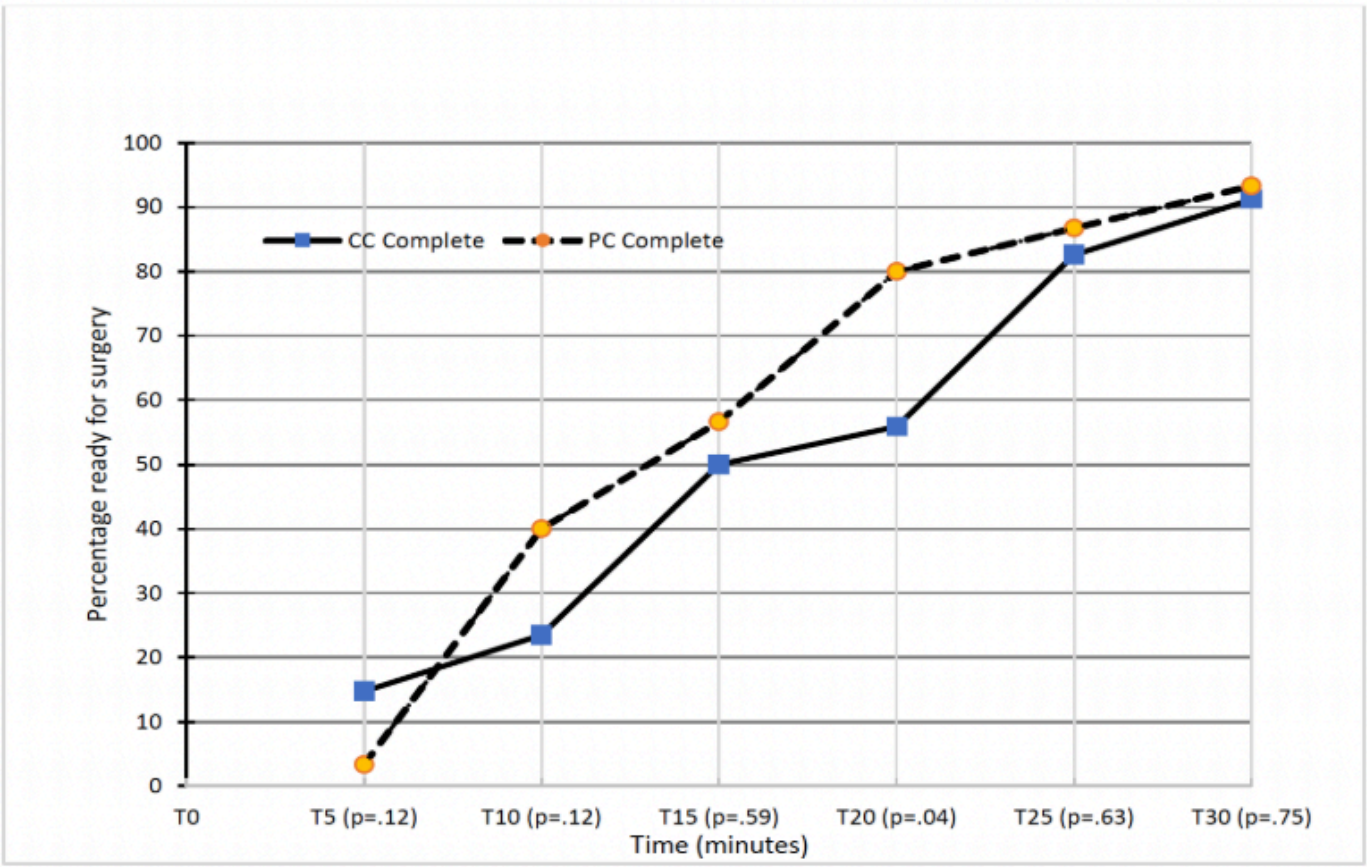

Figure 2: Percentage ready for surgery at the end of 30 minutes

Figure 2

See image above for figure legend

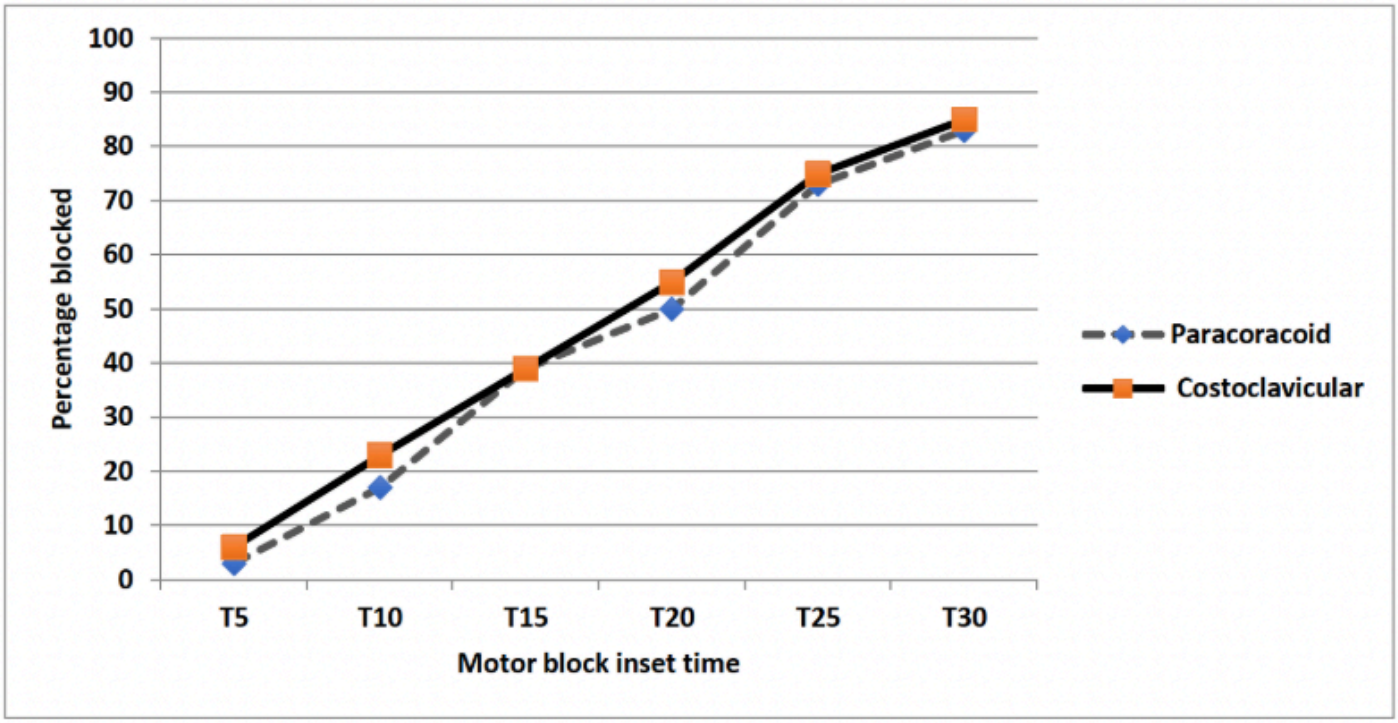

Figure 3: Motor block onset time

Figure 3

See image above for figure legend

Supplementary Files

This is a list of supplementary files associated with this preprint. Click to download.

- CONSORT2025editablechecklistinfraclavicular.docx