Research Square

Preprints are preliminary reports that have not undergone peer review. They should not be considered conclusive, used to inform clinical practice, or referenced by the media as validated information.

Combined ovarian tissue cryopreservation and in vitro maturation of ovarian- tissue oocytes (OTO-IVM) for emergency fertility preservation in the early postpartum period: a case report and systematic review of the literature

Roza Berkovitz-Shperling

raz.bershp@gmail.com

Tel Aviv Sourasky Medical Center

Shai Trigerman

Tel Aviv Sourasky Medical Center

Yael Kalma

Tel Aviv Sourasky Medical Center

Hadar Feder

Tel Aviv Sourasky Medical Center

Benny Almog

Tel Aviv Sourasky Medical Center

Yoni Cohen

Tel Aviv Sourasky Medical Center

Adiel Kahana

Tel Aviv Sourasky Medical Center

Case Report

Keywords: oocyte maturation, lactation, Ewing sarcoma, oncofertility

Posted Date: October 22nd, 2026

DOI: https://doi.org/10.21203/rs.3.rs-11190164/v1

License: This work is licensed under a Creative Commons Attribution 4.0 International License. Read Full License

Additional Declarations: No competing interests reported.

Abstract

Purpose.

In vitro maturation of oocytes recovered ex vivo from ovarian cortex (OTO-IVM), combined with ovarian tissue cryopreservation (OTC), is an adjunct for urgent fertility preservation (FP) when controlled ovarian stimulation is precluded; its performance in the immediate postpartum, lactating patient has not been described.

Methods.

We searched PubMed/MEDLINE along two axes: a PRISMA-guided systematic review of IVM (OPU-IVM, OTO-IVM) for FP (Axis A), and a scoping search of fertility treatment after the end of a pregnancy (Axis B).

Results.

A 23-year-old woman, three weeks after a cesarean delivery and still lactating, was diagnosed with metastatic Ewing-type pelvic sarcoma and referred for FP before VAC-IE chemotherapy. Prolactin was 504.8 mIU/L and antral follicle count ~ 19. Truncated gonadotropin priming (4 days) followed by an hCG trigger preceded right oophorectomy for OTC, transvaginal aspiration and OTO-IVM. Despite follicular growth to > 10 mm, aspiration yielded no oocytes. The cortex yielded 11 cumulus–oocyte complexes; 6 were degenerate, and 5 were at the germinal-vesicle stage, none of which matured after 48 h of IVM. Thirty-five ovarian cortical fragments were cryopreserved. A systematic review (13 IVM studies; 15 post-pregnancy reports) found no prior report of IVM-based FP in a postpartum or lactating woman.

Conclusion.

In this first reported attempt at OTO-IVM in the immediate postpartum period, oocyte retrieval and maturation failed despite adequate follicular growth, although medication exposure and concurrent illness are important confounders. OTC remained the durable component of FP. The case is hypothesis-generating regarding reduced oocyte maturational competence in the early postpartum, lactational ovary and informs counseling.

Introduction

Fertility preservation before gonadotoxic therapy is the standard of care for young women with cancer [1]. When the interval to treatment is too short for controlled ovarian stimulation, or when stimulation is contraindicated, OTC and IVM offer alternatives that do not require stimulating a cohort of mature follicles. Immature oocytes can be recovered transvaginally (OPU-IVM) or, increasingly, harvested ex vivo

from cortical tissue processed for OTC (OTO-IVM), maximizing gamete yield from a single surgical procedure [2–4]. Live births, though uncommon, have been reported after OTO-IVM combined with OTC [2, 3], and the technique is now an accepted adjunct in experienced centers [2, 3]. Maturation competence, however, is variable and is reduced at the extremes of the reproductive lifespan and after chemotherapy [4, 5].

Fertility preservation after delivery is established: in pregnancy-associated cancer, it is typically deferred until the patient is no longer pregnant. OTC can be performed intraoperatively at the time of cesarean section, or ovarian stimulation can be used for oocyte or embryo freezing in the postpartum period [6]; transvaginal oocyte retrieval during lactation has also been described [7, 8]. Notably, however, the large cohort studies almost never specify how long after delivery the procedure was performed or whether the woman was lactating at the time; although some case reports do state this interval, the puerperal window, arguably the variable that matters most, remains poorly characterized. What remains unknown is how the ovary behaves in this window. The immediate postpartum period is a distinctive endocrine state: lactational hyperprolactinemia, hypothalamic–pituitary suppression with relative hypogonadotropism, and ongoing uterine and ovarian involution. Whether antral oocytes recovered at this time retain normal maturational competence, and how the early-postpartum ovary responds to gonadotropin priming, remain essentially uncharacterized. We found no prior report of IVM- or OTO-IVM-based FP performed in the immediate postpartum period or in a lactating patient. We describe such an attempt, unsuccessful in its laboratory yield but, in our view, informative, in a young woman requiring emergency FP weeks after delivery.

Case presentation

Clinical background

A 23-year-old woman, gravida 2 para 2 (one prior vaginal delivery and one cesarean delivery) with spontaneous conceptions, presented three weeks after a cesarean section performed for breech presentation. She was breastfeeding. Several weeks before delivery she had developed progressive right lower-back pain radiating to the leg, initially attributed to radiculopathy, together with hyperemesis and marked anxiety. Cross-sectional imaging demonstrated a destructive lesion involving the right ilium and sacrum with cortical breach and adjacent muscle involvement, as well as bilateral pulmonary nodules consistent with metastatic disease; histology was consistent with Ewing sarcoma. She was scheduled for at least 16 cycles of interval-compressed VAC-IE chemotherapy (vincristine, doxorubicin and cyclophosphamide alternating with ifosfamide and etoposide), a regimen with a high cumulative alkylating-agent burden and a correspondingly high risk of primary ovarian insufficiency [9]. Oncology advised that chemotherapy begin without delay.

Her course was complicated by postpartum depression, without regular psychiatric follow-up at presentation. Concurrent medications comprised an SSRI (sertraline; Lustral, Pfizer, New York, NY, USA), an anxiolytic benzodiazepine (oxazepam; Vaben, Teva Pharmaceutical Industries, Petah Tikva, Israel), an

antipsychotic used for sedation (quetiapine), and multimodal analgesia: oxycodone (Oxycod; Rafa Laboratories, Jerusalem, Israel), tramadol (Tramadex; Dexcel Pharma, Or Akiva, Israel), transdermal fentanyl, and dipyrone (Optalgin; Teva Pharmaceutical Industries, Petah Tikva, Israel). These exposures, and the systemic effects of metastatic disease, are relevant confounders in any interpretation of oocyte quality.

Fertility-preservation work-up

At the FP consultation, baseline endocrinology showed prolactin 504.8 mIU/L (lactational-range elevation), FSH 7.3 IU/L, LH 5.1 IU/L, TSH 3.29 mIU/L, and low estradiol with progesterone < 2 nmol/L. Anti-Müllerian hormone was not measured. Transvaginal ultrasound showed an antral follicle count of approximately 19 (follicles 5–7 mm). The uterine cavity contained heterogeneous avascular material (~ 12 mm) consistent with postpartum clot; the cesarean scar was healing normally. After multidisciplinary counseling, the patient consented to OTC, with the intention of adding oocyte recovery and OTO-IVM, and to oocyte (or embryo) cryopreservation where feasible.

Strategy. Given the short interval to chemotherapy and the recent delivery, a truncated, random-start gonadotropin priming was used as a bridge rather than a full stimulation: Pergoveris (follitropin alfa/lutropin alfa; Merck Serono, Darmstadt, Germany) 225 IU daily for 4 days, followed by an hCG trigger (Ovitrelle, choriogonadotropin alfa 250 µg; Merck Serono, Darmstadt, Germany). Right unilateral oophorectomy for OTC was performed, with concurrent transvaginal oocyte aspiration from both ovaries and ex vivo harvesting of cumulus–oocyte complexes from the excised ovarian cortex (OTO-IVM).

Laboratory and surgical outcomes

Over 4 days of Pergoveris priming, the leading follicles grew to > 10 mm (seven follicles 10–12 mm and two follicles 13–14 mm), and an hCG trigger was administered 36 hours before oocyte aspiration. At surgery, transvaginal aspiration of these stimulated follicles from both ovaries yielded no oocytes. Ex vivo dissection and rinsing of the cortical fragments yielded 11 cumulus–oocyte complexes. Six oocytes were degenerate; the remaining five were arrested at the germinal-vesicle (GV) stage. The GV oocytes were cultured in maturation medium from a commercial IVM kit (SAGE IVM Media Kit, REF ART-1600; Origio, CooperSurgical, Trumbull, CT, USA) supplemented with FSH and LH to a final concentration of 75 mIU/mL each, as previously described [10], for 48 h; none reached maturity, and none were cryopreserved. Thirty-five ovarian cortical fragments were cryopreserved. Histology of the fresh ovarian medulla and cortex showed fragments containing follicles, a small inclusion cyst and focal calcifications, with no tumour identified; immunostaining for NKX2.2, a sensitive marker of Ewing sarcoma, was negative, supporting the absence of malignant involvement of the cryopreserved tissue.

Outcome and follow-up. Because no mature oocytes were obtained, fertilization was not performed and the choice between embryo and oocyte cryopreservation did not arise; the cryopreserved ovarian cortex

remained the sole preserved reproductive material. The patient commenced gonadotoxic chemotherapy, which is ongoing at the time of writing.

Systematic review of the literature

Search strategy and study selection

Because the present case sits at the intersection of two distinct literatures, we searched PubMed/MEDLINE from database inception to July 2026 along two axes. Axis A (IVM-based fertility preservation) used variants of: (“in vitro maturation” OR IVM OR OTO-IVM OR OPU-IVM) AND (“fertility preservation” OR “ovarian tissue cryopreservation”) AND (“ex vivo” OR “ovarian tissue oocyte”). Axis B (fertility treatment or preservation after the end of a pregnancy) used variants of: (“fertility preservation” OR “ovarian stimulation” OR “oocyte retrieval” OR “in vitro fertilization” OR “ovarian tissue cryopreservation”) AND (postpartum OR puerperium OR lactation OR breastfeeding OR “cesarean” OR “pregnancy-associated cancer” OR abortion OR “pregnancy loss” OR miscarriage). Eligible reports described IVM of immature oocytes for FP and reported maturation and/or reproductive outcomes (Axis A), or described fertility treatment or preservation performed at, or after, the end of a pregnancy and reported the timing and the reproductive outcome (Axis B). Animal studies, conference abstracts and non-English reports without available translation were excluded. Records were screened independently by two reviewers (RBS and AK), first by title and abstract and then by full text, with disagreements resolved by discussion. For Axis A, the search was conducted and reported following PRISMA guidance; it yielded 93 records, and after title and abstract screening, 25 full-text articles were assessed, and 13 studies met the inclusion criteria (Fig. 1; Table 1). Axis B was conducted as a structured scoping search rather than a formal systematic review: its broad post-pregnancy vocabulary (postpartum, puerperium, cesarean, abortion, lactation) returns several thousand PubMed records dominated by unrelated obstetric and oncological topics that cannot be screened exhaustively by hand. We therefore ran targeted component searches spanning each treatment-term by pregnancy-end-term combination and screened these by title and abstract against the eligibility criteria, identifying 15 eligible clinical reports (Table 2). Because Axis B was a scoping rather than an exhaustive search, its results are reported descriptively and are not represented in the PRISMA flow diagram (Fig. 1), which applies to Axis A only. The review was not prospectively registered.

Table 1
Principal reported series of IVM applied to immature oocytes for fertility preservation (ex-vivo/OTO-IVM and transvaginal/OPU-IVM). No published series includes postpartum or lactating patients.

Study	Population / setting	Technique	Oocytes / maturation	Key outcome
Fasano 2011, Reprod Biol Endocrinol [10]	57 patients (8–35 y), FP	Ex-vivo IVM + OTC	266 oocytes; maturation 31% (CooperSurgical medium + FSH 75 + LH 75 mIU/mL)	Immature oocytes retrievable in any cycle phase and age
Park 2016, Clin Exp Reprod Med [4]	6 gynecologic-cancer patients	Ex-vivo IVM pre-radical surgery	53 oocytes; maturation 67.9%	Feasible without spillage risk or delay
Abir 2016, Hum Reprod [12]	42 paediatric (pre/post chemo)	Ex-vivo IVM + OTC	395 oocytes; matured 32% (pre-) / 26% (post-chemo)	Feasible before and after chemotherapy
Fasano 2017, RBMO [14]	136 (130 adults + 6 prepubertal)	Ex-vivo IVM + vitrification	Maturation 28.1% adult vs 10.3% prepubertal; degeneration 17.1% vs 35.5%	Age drives yield; IVM rate independent of AMH
Segers 2020, Hum Reprod [2]	77 adults, urgent FP (cancer)	OTO-IVM + OTC	1220 COCs; maturation 39% ± 23%	First case series of live births from OTO-IVM
Delattre 2020, Hum Reprod [13]	207 patients, medical FP	Combined COS / OPU-IVM / OTO-IVM + OTC	OTO-IVM 4.0 ± 4.3 MII/patient	Live births incl. 3 after OTO-IVM; 'spread the baskets'
Nogueira 2023, Life [3]	89 FP patients (cancer)	OTO-IVM & OPU-IVM	OTO-IVM 57–70%, OPU-IVM 73–82% (24–48 h)	1 live birth (OPU-IVM)
Ito 2023, JARG [5]	60 paediatric OTC	OTO-IVM	Oocytes in 36/60; cryopreserved in 18	Premenarchal ↓ maturation; AMH predictive
Puy 2023, Hum Reprod [11]	51 FP patients	OTC ± COH (stim vs unstim)	MII 8.5 (stim) vs 2.0 (unstim/IVM)	OTC feasible after stimulation; COH out-yields IVM
Ding 2026, J Ovarian Res [15]	44 haematological patients, pre-HSCT	OTO-IVM + OTC	Maturation ~ 36–50%; MII 2.2–3.6/patient	Stromal-cell apoptosis linked to ↓ oocyte maturation competence
Zhang 2024, Zhejiang Univ (Med) [17]	Case: 15 y, Hodgkin lymphoma	OTO-IVM + OTC	1 MII + 3 GV; the 3 GV failed IVM	1 MII + 12 cortex slices cryopreserved

Study	Population / setting	Technique	Oocytes / maturation	Key outcome
Higuchi 2026, Reprod Med Biol [16]	Case: 23 y, ovarian fibromatosis	OTO-IVM, dbcAMP biphasic	7 GV → 3 MII (biphasic cycle)	Live birth after biphasic OTO-IVM (first report)
Tatishcheva 2026, Front Med [18]	Case: 29 y, recurrent borderline serous tumour, single ovary	OTO-IVM (single-phase), ex vivo from removed tumour ovary	22 OCC → 12 MII (55%)	First live birth after blastocyst-stage transfer in OTO-IVM

Table 2
Reported fertility-preservation and assisted-reproduction procedures performed at, or after, the end of a pregnancy, with timing and reproductive outcome. None involved IVM.

Study	Setting / disease	Timing relative to end of pregnancy	FP method	Outcome
Salama 2019, Gynecol Endocrinol [21]	Acute lymphocytic leukaemia in pregnancy	During pregnancy (2nd trimester), before delivery	OTC (ovarian tissue extraction)	FP feasible without contraindicating treatment; no oocyte data
Cheng 2021, J Ovarian Res [22]	Breast cancer during pregnancy	At cesarean delivery (week 32)	OTC at time of cesarean; 23 cortical slices	No delay to oncological therapy; ovarian function preserved at 2 y; no IVM attempted
Cunningham 2015, Clin Nucl Med [7]	Breast cancer, lactating woman	During established lactation (~ months after delivery; exact interval not stated)	Ovarian stimulation + transvaginal oocyte retrieval	Retrieval feasible during lactation; oocyte yield/quality not detailed
Nilsson 2026, Front Endocrinol [6]	50 women, cancer in pregnancy or postpartum (largest cohort)	'At delivery' / 'planned postpartum', weeks elapsed not reported; lactation not recorded	~ 57% OTC, ~ 43% ovarian stimulation	FP feasible postpartum; one postpartum stimulation attempt unsuccessful
Yang 2026, Reprod Biol Endocrinol [36]	2,620 women, ART after pregnancy loss	< 6 months after biochemical/clinical loss	Frozen–thawed embryo transfer	No adverse effect of immediate resumption, early loss differs from term/lactational postpartum
Goeckenjan 2013, Gynecol Endocrinol [23]	Breast cancer (37 y)	After first-trimester induced abortion	OTC + ovarian stimulation for ICSI despite elevated hCG	Successful stimulation; oocyte/embryo cryopreservation
Gundelach 2014, J Assist Reprod Genet [39]	Hodgkin lymphoma in pregnancy	At caesarean delivery	OTC after caesarean delivery	FP feasible at cesarean; no oocyte/IVM data
Datar 2015, J Gynecol Surg [40]	Pregnancy-associated breast cancer	Puerperal (postpartum) period	Random-start COS + ICSI + embryo cryopreservation	Successful embryo cryopreservation
Cohade 2017, Gynecol	Breast cancer in early pregnancy	Days after surgical abortion	Ovarian stimulation	Normal follicular growth but absence of

Study	Setting / disease	Timing relative to end of pregnancy	FP method	Outcome
Endocrinol [27]			(rFSH + GnRH antagonist)	oocyte/cumulus maturation
Pereira 2019, Gynecol Endocrinol [24]	ER+/PR+/HER2 − breast cancer	Random-start COS 5 days after termination	Random-start COS (letrozole) + embryo cryopreservation	29 oocytes retrieved
Giuliani 2019, J Assist Reprod Genet [26]	Newly diagnosed Ewing sarcoma (same disease)	Immediately after full-term delivery	Random-start COS + embryo cryopreservation	Successful embryo cryopreservation shortly after delivery
Carpinello 2020, F S Rep [25]	Grade 3 invasive ductal breast cancer	COH 7 days after medical termination	Random-start COH despite low positive hCG	18 oocytes, 12 MII, all vitrified
Hamada 2021, Gynecol Endocrinol [28]	Mixed-phenotype acute leukaemia	Two COS cycles after therapeutic abortion	COS + oocyte cryopreservation	C1: 0 oocytes (early luteinization); C2 (hCG < 100 IU/L): mature oocytes obtained
Marin 2023, J Assist Reprod Genet [41]	Pregnant cancer patients (review + 2 cases)	After first-trimester abortion	OTC ± oophorectomy; literature review	Feasibility discussion; 2 illustrative cases
Kim (Rosenwaks) 2026, J Assist Reprod Genet [29]	Pregnancy-associated colorectal cancer	Random-start COS 7 days after second-trimester termination	Random-start COS (GnRH-antagonist) + ICSI	19 oocytes, 15 mature, 11 fertilized
Present case, 2026	Metastatic Ewing sarcoma, lactating	3 weeks after term cesarean, during lactation	Priming + OTC + transvaginal aspiration + OTO-IVM	Follicles grew; 0 oocytes at aspiration; 11 ex-vivo COCs, 0 matured; OTC successful

Axis A — IVM-based fertility preservation

Thirteen reports met the inclusion criteria (Table 1) [2–5, 10–18]. Across cohorts, in-vitro maturation rates of ex-vivo/OTO-IVM oocytes cluster around 30–40% (e.g. 31% [10], 32%/26% pre-/post-chemotherapy [12], 39% [2]) and are consistently lower than for transvaginally retrieved oocytes (73–82%) [3]. Maturation and yield decline at the reproductive extremes: prepubertal girls show higher oocyte numbers but higher degeneration (35.5% vs 17.1%) and lower IVM rates (10.3% vs 28.1%) than adults [14], and premenarchal status independently predicts poorer maturation [5]. Anti-Müllerian hormone predicts oocyte number more than IVM rate [5, 14]. Where reproductive outcomes are reported, OTO-IVM

has produced live births, albeit uncommonly [2, 3, 13], most recently a blastocyst-stage transfer that achieved a live birth from an oocyte matured ex vivo from a tumour-bearing ovary at a 55% maturation rate [18]; controlled stimulation, when time allows, out-yields unstimulated IVM [11]. Two themes bear directly on the present case. First, the ovarian somatic microenvironment appears to govern oocyte competence: in a 2026 urgent-FP cohort, ovarian stromal-cell apoptosis was linked to impaired maturation competence [15]. Second, maturation is strongly protocol-dependent, biphasic (capacitation/CAPA- or dbcAMP-enhanced) IVM improves oocyte competence over the conventional monophasic approach and has produced a live birth from ovarian-tissue oocytes [16, 19], while complete failure of recovered immature oocytes to mature has itself been reported [17]. Critically, across all thirteen reports, spanning children and adults, chemotherapy-naive and chemotherapy-exposed, benign and malignant disease, none involved a postpartum or lactating woman, the population represented by the present case; existing narrative reviews of OTO-IVM likewise do not address this setting [19, 20].

Axis B — fertility treatment and preservation after the end of a pregnancy

Fifteen reports met the Axis B criteria (Table 2). In pregnancy-associated cancer, fertility preservation is undertaken during pregnancy, at delivery, or postpartum: OTC has been performed in the second trimester [21] and at the time of cesarean section [22] without delaying oncological treatment, and in the largest cohort roughly 57% underwent OTC and 43% ovarian stimulation after delivery or abortion [6]. More informative for the present case are the reports of ovarian stimulation performed shortly after the end of a pregnancy. Several describe successful retrieval: random-start stimulation begun days after surgical or medical termination has yielded normal oocyte numbers [23–25], and embryo cryopreservation has been achieved immediately after a full-term delivery [26]. Critically, Giuliani et al. [26] reported the latter in a woman with newly diagnosed Ewing sarcoma, the same malignancy as the present case, making it the closest disease-matched precedent and one in which retrieval succeeded. Other reports, however, describe the same failure pattern seen here, namely normal follicular growth but absent oocyte or cumulus maturation at retrieval, days after surgical abortion (Cohade et al. [27]) and after therapeutic abortion (Hamada et al. [28], who attributed it explicitly to early luteinization). These were non-lactating women, which argues against lactation being a necessary condition and points instead to a broader disturbance of the recently pregnant ovary. Two further points bear on our argument. First, the interval from the end of pregnancy to the procedure, essentially never reported in the large cohort studies, is in fact specified in days in several of these case reports [24, 25, 28, 29]; it is therefore more accurate to say the interval is inconsistently reported and rarely captured at cohort level than that it is never reported. Second, no report describes IVM or OTO-IVM in an immediate-postpartum, lactating woman; a near-contemporaneous case report and literature review of this axis reaches the same conclusion [29]. The present case therefore occupies the empty cell at the junction of Tables 1 and 2, and is, to our knowledge, the first in which the interval from delivery (three weeks) and the lactational status are specified alongside the oocyte-level outcome.

Discussion

To our knowledge, this case documents the first attempt at OTO-IVM in the immediate postpartum period. Two observations are worth highlighting. First, there was a striking dissociation between somatic follicular development and oocyte competence: despite an adequate antral cohort (AFC 19), the leading follicles grew to > 10 mm over only 4 days of 225 IU gonadotropin, and an hCG trigger was administered. Yet aspiration of these stimulated follicles yielded no oocytes, and none of the oocytes recovered ex vivo completed maturation. Of the 11 cumulus–oocyte complexes obtained from the cortex, 6 were degenerate, and the remaining 5 were arrested at the germinal-vesicle stage; none matured after 48 h of IVM. Second, because transvaginal aspiration was unproductive, every oocyte obtained came from ex vivo processing of the cortex, underscoring the value of OTO-IVM as a salvage step when in vivo retrieval fails, even when, as here, the matured yield is ultimately nil.

The unproductive aspiration warrants comment. Oocyte recovery from follicles that appear to have developed normally is not invariable, and yield is intrinsically lower and more variable in IVM-based than in conventional stimulated cycles: immature oocytes are collected from small antral follicles, hCG priming is not universally employed, and it has not been shown to increase the number of oocytes retrieved or to improve outcomes [30]. The absence of any retrievable oocyte is nonetheless striking against an antral count of 19 and nine follicles exceeding 10 mm, and represents a yield far below that expected at retrieval. The decisive laboratory finding, moreover, is independent of the trigger: the immature (germinal-vesicle) oocytes recovered ex vivo were matured in vitro, a process that does not require an in vivo hCG surge, yet none reached metaphase II, and most were degenerate. This in-vitro maturation failure, together with the dissociation between follicular growth and oocyte recovery, is the more robust evidence for compromised oocyte competence in the immediate-postpartum, lactational ovary.

Why might the early-postpartum ovary perform poorly? Because somatic follicular growth appeared adequate here, the failure points less to follicular recruitment than to the oocyte compartment itself. The complete failure of GV-stage oocytes to resume meiosis despite an hCG trigger and adequate follicular size is consistent with an oocyte-intrinsic maturation defect rather than a simple gonadotropin-response failure. Several non-exclusive mechanisms are plausible: lactational hyperprolactinemia and hypothalamic suppression create a relatively hypogonadotropic milieu, and recent gestational steroid exposure together with ovarian involution and the local inflammatory and anatomic effects of recent cesarean surgery may compromise oocyte cytoplasmic and nuclear maturational competence, as well as the technical yield at retrieval. These mechanisms parallel, but are distinct from, the reduced competence seen at the reproductive extremes and after chemotherapy described in the OTO-IVM literature [4, 5]. Consistent with an oocyte-level rather than a follicle-level deficit, histology of the cortex confirmed the presence of follicles, arguing against depletion of the follicle pool as the explanation. Supporting a microenvironmental contribution, ovarian stromal-cell apoptosis has recently been linked to impaired oocyte maturation competence in another urgent-FP cohort [15].

A coherent mechanism can be proposed. During lactation, suckling sustains hyperprolactinemia, which suppresses hypothalamic kisspeptin (Kiss1) neurons and disrupts pulsatile GnRH secretion; the resulting low-amplitude LH pulses and absent pre-ovulatory surge attenuate follicular development and, critically, the LH-driven signal that initiates oocyte nuclear maturation [31, 32]. Any follicle that does grow, therefore, matures in a hypogonadotropic, high-prolactin environment ill-suited to completing meiotic and cytoplasmic maturation, consistent with our findings of somatically grown yet 'empty' follicles at aspiration and ex-vivo oocytes that were degenerate or arrested at the germinal-vesicle stage. Two further hits are plausible: intensive opioid analgesia, which suppresses GnRH centrally and, via opioid peptides produced within granulosa cells, may act directly on oocyte maturation [33]; and the recently pregnant, involuting ovarian microenvironment, in which stromal changes have been linked to reduced maturation competence [15]. A further, non-lactational mechanism deserves emphasis: the same dissociation of adequate follicular growth with absent or immature oocytes at retrieval has been reported after surgical and therapeutic abortion in non-lactating women, where it has been attributed to residual pregnancy-derived hCG and premature (early) luteinization of the growing follicles [27, 28]. This is distinct from the trigger-hCG considerations that do not apply to IVM retrieval; it concerns the endocrine aftermath of the pregnancy itself. Because our patient was approximately three weeks after a term delivery, circulating hCG should have been largely cleared, so residual hCG is a less likely driver here than in the post-abortion reports; the shared failure pattern across lactational and non-lactational post-pregnancy contexts nonetheless suggests a common final pathway, a disordered peri-ovulatory maturation of the recently pregnant ovary, reachable by more than one route. In this framework the deficit is oocyte-intrinsic and micro-environmental rather than a shortage of follicles, consistent with the preserved follicle numbers on histology, and would be expected to ease as suckling declines and the hypothalamic–pituitary–ovarian axis recovers. Importantly, this suppression is graded rather than absolute and tracks suckling intensity: non-lactating women resume ovulation within weeks of delivery (mean first ovulation ~ 45–94 days) [34], whereas lactating women may ovulate even while breastfeeding, with suckling frequency and duration determining the degree of suppression [35]. Crucially, even when ovarian activity resumes early, it is often qualitatively deficient; roughly half of these first ovulatory cycles show inadequate luteal-phase progesterone [35]. Our patient, at ~ 3 weeks postpartum and lactating, therefore likely occupied an intermediate position on this spectrum: a partially reactivated axis able to drive follicular growth under exogenous gonadotropin, yet still functionally suboptimal, plausibly yielding follicles whose oocytes had not regained full maturational competence.

Restraint is essential in attributing the failure to the postpartum state alone. The priming duration used here (4 days) lies within the range customary for IVM (3–6 days) and is therefore unlikely to account for the failure on its own. Heavy opioid and psychotropic exposure, and metastatic systemic illness, remain potential confounders of oocyte quality, and the unproductive transvaginal aspiration may in part be technical, reflecting altered postpartum/post-cesarean pelvic anatomy. The case is therefore hypothesis-generating, not confirmatory.

Where this case fits. OTO-IVM with OTC is an accepted urgent-FP adjunct, with reported maturation rates broadly in the 30–70% range and documented live births [2–4]; OTC can also be combined with

same-day oocyte retrieval after stimulation when time permits [11]. As Table 1 shows, none of these series includes postpartum patients. Indeed, in the most recent OTO-IVM live birth, oocytes recovered ex vivo from a surgically removed, tumour-bearing ovary in a non-postpartum woman matured at 55% and produced a healthy child [18]; that a comparably handled ovary yielded competent oocytes where our fully lactating, early-postpartum patient's yielded none reinforces the postpartum substrate as the salient difference. Notably, in the largest cohort of FP for pregnancy-associated cancer, a postpartum hormonal-stimulation attempt was also unsuccessful [6], an anecdotal but concordant signal that ovarian response after delivery may be suboptimal. Our report extends the clinical map to this unstudied window and suggests that the early-postpartum, lactating ovary may be a poor substrate for IVM-based gamete recovery.

Fertility preservation after the end of pregnancy. In the pregnancy-associated-cancer literature, FP is deferred until the woman is no longer pregnant and is then undertaken at, or shortly after, delivery or pregnancy termination. In the largest such cohort, most women underwent FP postpartum or post-abortion, approximately 57% by OTC and 43% by ovarian stimulation, with several of the tissue-cryopreservation procedures performed intraoperatively at the time of cesarean section [6]; transvaginal oocyte retrieval during established lactation, some months after delivery, has also been described [7]. However, the exact interval from delivery or abortion to FP is rarely specified, and the immediate postpartum window, the first weeks after birth, during active lactation, as in our patient (~ 3 weeks), is essentially unstudied. This window is also endocrinologically distinct from early pregnancy loss: after a first-trimester miscarriage or termination, gestational hormones decline rapidly, and there is no lactation, allowing assisted-reproduction treatment to resume without delay and with reproductive outcomes comparable to later starts [36]. By contrast, the immediate lactational postpartum period is characterized by sustained hyperprolactinemia, relative hypogonadotropism, and ongoing ovarian involution, factors that may impair the final stages of follicular maturation and oocyte competence and limit ovarian responsiveness to stimulation [31, 32]. A second, non-mutually exclusive hypothesis relates to the developmental history of the follicles themselves. The antral follicles available for retrieval during the first weeks after delivery are likely to have spent much of their growth phase within the hormonally suppressed environment of pregnancy rather than during normal cyclic ovarian activity. Because acquisition of oocyte developmental competence is a gradual process throughout folliculogenesis, prolonged exposure to the endocrine and intraovarian milieu of pregnancy may compromise granulosa-cell function, cumulus–oocyte communication, and the progressive acquisition of developmental competence. Consequently, follicles that appear morphologically normal at the antral stage may nevertheless harbour immature, developmentally compromised, or even non-retrievable oocytes, providing one possible explanation for the dissociation between follicular growth and oocyte recovery observed in our case [37, 38]. The distinction therefore extends beyond lactation itself: both the acute endocrine environment of the immediate postpartum period and the preceding follicular development during pregnancy may contribute to reduced ovarian responsiveness and oocyte competence. Where oncological timing allows, deferring FP by even a few weeks, or suppressing lactation before priming, might therefore improve oocyte yield, a hypothesis that warrants study.

Practical implications. For the rare patient needing FP shortly after delivery: (i) counsel explicitly that mature-oocyte yield from IVM may be low and cannot be assumed from the AFC; (ii) anchor the strategy on OTC, which is independent of immediate oocyte maturation and was successfully completed here; (iii) where oncologically permissible, consider whether even a short delay would allow a conventional stimulation, which substantially out-yields unstimulated IVM [11]; and (iv) retain OTO-IVM as a no-cost salvage at the time of OTC, since the cortex is being processed regardless. The role of lactation suppression before priming in this setting is unknown and merits study.

Limitations. This is a single, unsuccessful case with the confounders detailed above. We used a conventional monophasic IVM protocol; biphasic (capacitation) IVM improves maturation competence and has yielded live births from ovarian-tissue oocytes [16, 19], so a different protocol might have altered the laboratory outcome. No causal inference about the postpartum state is possible, and the data inform hypotheses and counseling rather than practice change.

Conclusion

Emergency multimodal FP, truncated priming, OTC and OTO-IVM, is logistically feasible in the immediate postpartum period, but in this first reported case oocyte retrieval and maturation failed despite adequate follicular growth and an adequate antral follicle count. Whether this reflects a genuine limitation of the early-postpartum, lactational ovary or the confounders of heavy medication exposure and concurrent illness cannot be resolved from a single case. OTC remained the durable preservation method. We report the case to flag an unstudied scenario and to inform realistic counseling.

Declarations

Funding. The authors declare that no funds, grants or other support were received during the preparation of this manuscript.

Competing interests. The authors declare that they have no relevant financial or non-financial interests to disclose.

Ethics approval. The study was approved by the Institutional Review Board (Helsinki Committee) of Tel Aviv Sourasky Medical Center (approval no. 0728-25-TLV). The report was prepared in accordance with the principles of the Declaration of Helsinki.

Consent to participate / Consent for publication. Written informed consent for publication of anonymized clinical details was obtained from the patient; the signed form is retained by the authors.

Author contributions. RBS and AK conceived the report; RBS drafted the manuscript; ST and HF contributed clinical data; YK and AK contributed the laboratory and embryology data; BA and YC critically revised the manuscript; all authors read and approved the final version.

Data availability. Data supporting this case report are included in the article; further details are available from the corresponding author upon reasonable request, subject to patient privacy constraints.

References

1. ESHRE Guideline Group on Female Fertility Preservation; Anderson RA, Amant F, Braat D, et al. ESHRE guideline: female fertility preservation. Hum Reprod Open. 2020;2020(4):hoaa052. doi:10.1093/hropen/hoaa052.
2. Segers I, Bardhi E, Mateizel I, et al. Live births following fertility preservation using in-vitro maturation of ovarian tissue oocytes. Hum Reprod. 2020;35(9):2026–2036. doi:10.1093/humrep/deaa175.
3. Nogueira D, Fajau-Prevot C, Clouet M, et al. Outcomes of different in vitro maturation procedures for oocyte cryopreservation for fertility preservation and yet another live birth in a cancer patient. Life (Basel). 2023;13(6):1355. doi:10.3390/life13061355.
4. Park CW, Lee SH, Yang KM, et al. Cryopreservation of in vitro matured oocytes after ex vivo oocyte retrieval from gynecologic cancer patients undergoing radical surgery. Clin Exp Reprod Med. 2016;43(2):119–125. doi:10.5653/cerm.2016.43.2.119.
5. Ito K, Takae S, Nakamura K, et al. The study of the efficiency of in vitro maturation of ovarian tissue oocytes in pediatric patients. J Assist Reprod Genet. 2023;40(12):2787–2797. doi:10.1007/s10815-023-02958-x.
6. Nilsson HP, Bornhede R, Johansson ALV, Rodriguez-Wallberg KA. Trends and outcomes of fertility preservation in patients presenting with cancer during pregnancy or postpartum — a longitudinal observational cohort study. Front Endocrinol (Lausanne). 2026;17:1771764. doi:10.3389/fendo.2026.1771764.
7. Cunningham JR, O'Malley JP, Bhambhvani P. Ovarian hyperstimulation and breast cancer on PET imaging with sonographic correlation. Clin Nucl Med. 2015;40(5):430–432. doi:10.1097/RLU.0000000000000743.
8. Azim HA, Peccatori FA, de Azambuja E, Piccart MJ. Motherhood after breast cancer: searching for la dolce vita. Expert Rev Anticancer Ther. 2011;11(2):287–298. doi:10.1586/era.10.208.
9. Spears N, Lopes F, Stefansdottir A, et al. Ovarian damage from chemotherapy and current approaches to its protection. Hum Reprod Update. 2019;25(6):673–693. doi:10.1093/humupd/dmz027.
10. Fasano G, Moffa F, Dechène J, Englert Y, Demeestere I. Vitrification of in vitro matured oocytes collected from antral follicles at the time of ovarian tissue cryopreservation. Reprod Biol Endocrinol. 2011;9:150. doi:10.1186/1477-7827-9-150.
11. Puy V, Dupeux M, Mayeur A, et al. Ovarian tissue cryopreservation can be combined simultaneously with oocyte retrieval after controlled ovarian hyperstimulation. Hum Reprod. 2023;38(5):860–871. doi:10.1093/humrep/dead041.

12. Abir R, Ben-Aharon I, Garor R, et al. Cryopreservation of in vitro matured oocytes in addition to ovarian tissue freezing for fertility preservation in paediatric female cancer patients before and after cancer therapy. Hum Reprod. 2016;31(4):750–762. doi:10.1093/humrep/dew007.
13. Delattre S, Segers I, Van Moer E, et al. Combining fertility preservation procedures to spread the eggs across different baskets: a feasibility study. Hum Reprod. 2020;35(11):2524–2536. doi:10.1093/humrep/deaa193.
14. Fasano G, Dechène J, Antonacci R, et al. Outcomes of immature oocytes collected from ovarian tissue for cryopreservation in adult and prepubertal patients. Reprod Biomed Online. 2017;34(6):575–582. doi:10.1016/j.rbmo.2017.03.007.
15. Ding Y, Su T, Wan Y, et al. Ovarian tissue oocyte-in vitro maturation combined with ovarian tissue cryopreservation: a promising urgent fertility preservation strategy for hematological patients before HSCT. J Ovarian Res. 2026;19:74. doi:10.1186/s13048-026-02136-4.
16. Higuchi S, Miyamoto T, Mochizuki M, et al. Live birth following dibutyryl-cAMP-enhanced biphasic in vitro maturation of ovarian tissue oocytes from a patient with ovarian fibromatosis: a first report. Reprod Med Biol. 2026;25(1):e70024. doi:10.1002/rmb2.70024.
17. Zhang H, Shi L, Wang H, Zhu H. Mature oocyte found during ovarian tissue cryopreservation in an early adolescent female. Zhejiang Da Xue Xue Bao Yi Xue Ban. 2024;53(4):527–530. doi:10.3724/zdxbyxb-2023-0561.
18. Tatishcheva Y, Lavrinovich O, Gerkulov D, Kalugina A, Slominskaya N, Kuzminih N, et al. Clinical case: successful birth as a result of the transfer of an embryo at the blastocyst stage from an oocyte obtained from a tumoral ovary using the OTO-IVM method. Front Med (Lausanne). 2026;13:1857432. doi:10.3389/fmed.2026.1857432.
19. Gilchrist RB, Ho TM, De Vos M, et al. A fresh start for IVM: capacitating the oocyte for development using pre-IVM. Hum Reprod Update. 2024;30(1):3–25. doi:10.1093/humupd/dmad023.
20. De Roo C, Tilleman K. In vitro maturation of oocytes retrieved from ovarian tissue: outcomes from current approaches and future perspectives. J Clin Med. 2021;10(20):4680. doi:10.3390/jcm10204680.
21. Salama M, Isachenko E, Ludwig S, et al. A successful multidisciplinary approach for treatment and for preserving the reproductive potential in a rare case of acute lymphocytic leukemia during pregnancy. Gynecol Endocrinol. 2019;35(2):115–118. doi:10.1080/09513590.2018.1498833.
22. Cheng J, Ruan X, Du J, et al. Ovarian tissue cryopreservation in a patient with breast cancer during pregnancy: a case report. J Ovarian Res. 2021;14(1):176. doi:10.1186/s13048-021-00929-3.
23. Goeckenjan M, Rösner S, Toth B, Strowitzki T, Germeyer A. Successful controlled ovarian stimulation despite elevated hCG levels after first-trimester abortion in the context of fertility preservation. Gynecol Endocrinol. 2013;29(11):960–962. doi:10.3109/09513590.2013.824961.
24. Pereira N, Kligman I, Hunt R, Kopparam R, Wahmann B, Rosenwaks Z. Fertility preservation with random-start controlled ovarian stimulation and embryo cryopreservation for early pregnancy-

associated breast cancer. Gynecol Endocrinol. 2019;35(3):214–216. doi:10.1080/09513590.2018.1522298.

25. Carpinello O, Aserlind A, Chang F, Sagoskin A, Widra E. Fertility preservation in an oncology patient who presented with positive human chorionic gonadotropin. F S Rep. 2020;1(1):51–53. doi:10.1016/j.xfre.2020.04.007.
26. Giuliani E, Ellman EM, Chugh R, Moravek MB. Successful embryo cryopreservation immediately following a full-term delivery in a woman with newly diagnosed Ewing's sarcoma. J Assist Reprod Genet. 2019;36(5):1023–1028. doi:10.1007/s10815-019-01445-6.
27. Cohade C, Moreau J, Gatimel N, Gladieff L, Parinaud J, Leandri R. Follicular growth but absence of oocyte and cumulus maturation during ovarian stimulation in the days following surgical abortion: a case report. Gynecol Endocrinol. 2017;33(9):680–681. doi:10.1080/09513590.2017.1320386.
28. Hamada H, Hayama T, Ijuin A, Miyakoshi A, Kasai M, Tochihara S, et al. Fertility preservation immediately after therapeutic abortion results in multiple normal follicular growth with the absence of mature oocytes due to early luteinization: a case report and literature review. Gynecol Endocrinol. 2021;37(11):1050–1053. doi:10.1080/09513590.2021.1950135.
29. Kim AE, Chung PH, Stewart JD, Rosenwaks Z. Urgent fertility preservation following second-trimester termination in a patient with pregnancy-associated colorectal cancer: a case report and literature review. J Assist Reprod Genet. 2026;43(3):895–899. doi:10.1007/s10815-025-03775-0.
30. Reavey J, Vincent K, Child T, Granne IE. Human chorionic gonadotrophin priming for fertility treatment with in vitro maturation. Cochrane Database Syst Rev. 2016;11:CD008720. doi:10.1002/14651858.CD008720.pub2.
31. Calik-Ksepka A, Stradczuk M, Czarnecka K, Grymowicz M, Smolarczyk R. Lactational amenorrhea: neuroendocrine pathways controlling fertility and bone turnover. Int J Mol Sci. 2022;23(3):1633. doi:10.3390/ijms23031633.
32. McNeilly AS. Lactational amenorrhea. Endocrinol Metab Clin North Am. 1993;22(1):59–73. PMID: 8449188.
33. Seeber B, Böttcher B, D'Costa E, Wildt L. Opioids and reproduction. Vitam Horm. 2019;111:247–279. doi:10.1016/bs.vh.2019.07.001.
34. Jackson E, Glasier A. Return of ovulation and menses in postpartum nonlactating women: a systematic review. Obstet Gynecol. 2011;117(3):657–662. doi:10.1097/AOG.0b013e31820ce18c.
35. Campbell OM, Gray RH. Characteristics and determinants of postpartum ovarian function in women in the United States. Am J Obstet Gynecol. 1993;169(1):55–60. doi:10.1016/0002-9378(93)90131-2.
36. Yang W, Wang S, Zhu Q, Yin M, Kong P. Impact of interpregnancy interval after pregnancy loss on clinical pregnancy and neonatal outcomes of subsequent frozen-thawed embryo transfer cycles: a retrospective cohort study. Reprod Biol Endocrinol. 2026;24(1):46. doi:10.1186/s12958-026-01556-7.
37. Gilchrist RB, Smitz J. Oocyte in vitro maturation: physiological basis and application to clinical practice. Fertil Steril. 2023;119(4):524–539. doi:10.1016/j.fertnstert.2023.02.010.

38. Köninger A, Schmidt B, Damaske D, et al. Follistatin during pregnancy and its potential role as an ovarian suppressing agent. Eur J Obstet Gynecol Reprod Biol. 2017;212:150–154. doi:10.1016/j.ejogrb.2017.03.001.
39. Gundelach T, Stuck D, Widschwendter P, Weiss JM, Janni W, Hancke K. Fertility preservation after caesarean delivery in a woman diagnosed with Morbus Hodgkin disease during pregnancy. J Assist Reprod Genet. 2014;31(1):51–53. doi:10.1007/s10815-013-0126-7.
40. Datar RS, Pereira N, Anderson SH, Stillman J, Glassner MJ. Puerperal fertility preservation with controlled ovarian stimulation and embryo cryopreservation for pregnancy-associated breast cancer. J Gynecol Surg. 2015;31(3):173–176. doi:10.1089/gyn.2014.0086.
41. Marin L, Ambrosini G, Vio C, Conley J, Bordin L, Sabbadin C, Andrisani A. Fertility preservation in pregnant cancer patients after first-trimester abortion: a new challenge with possible solutions. J Assist Reprod Genet. 2023;40(12):2819–2825. doi:10.1007/s10815-023-02950-5.

Figures

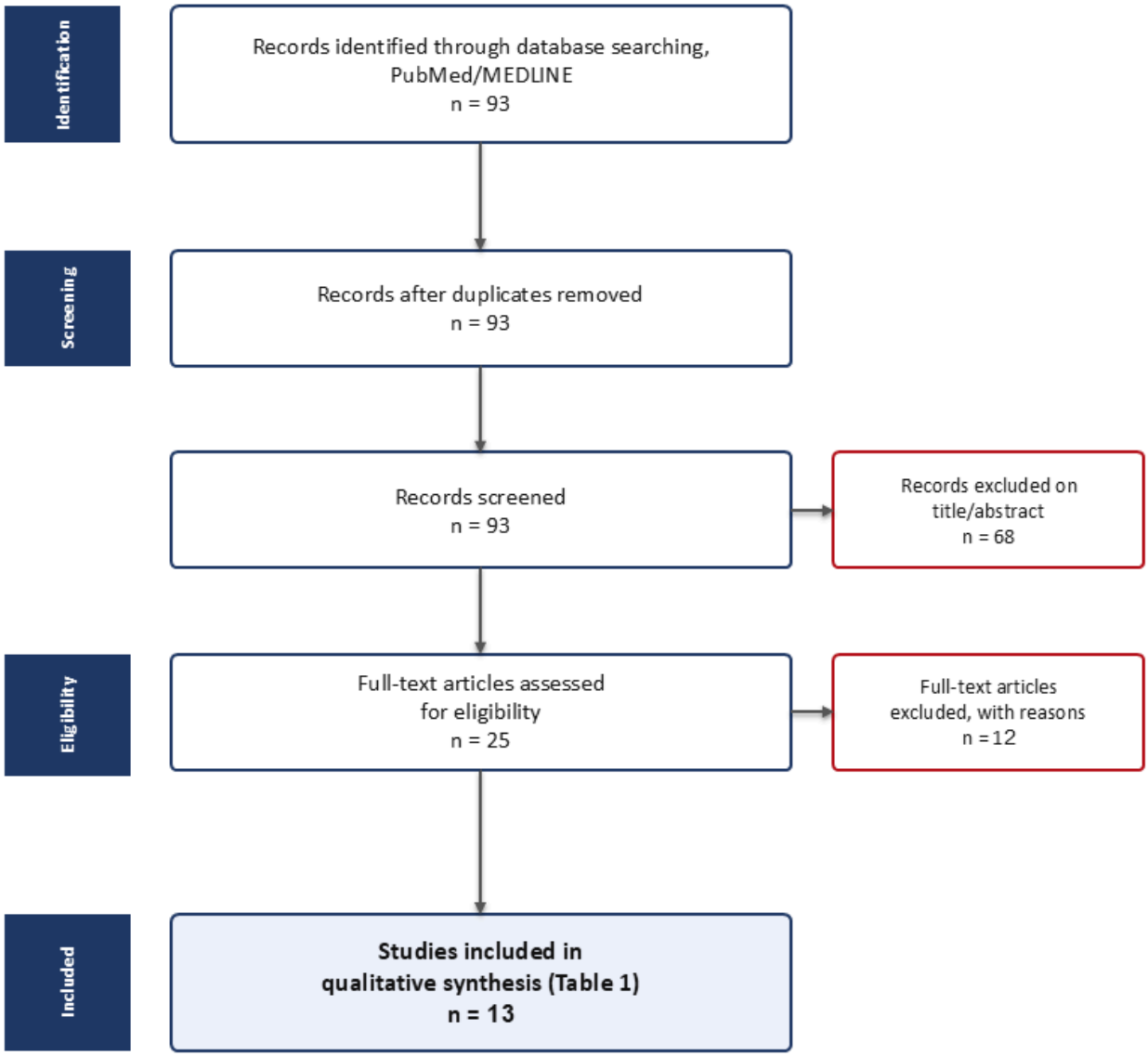

Figure 1

PRISMA flow diagram of study identification, screening and inclusion for Axis A (IVM-based fertility preservation). Database: PubMed/MEDLINE (inception–July 2026). Axis B was a structured scoping search and is not represented here.