Research Square

Preprints are preliminary reports that have not undergone peer review.
They should not be considered conclusive, used to inform clinical practice,
or referenced by the media as validated information.

Atypical MPO-ANCA–Associated Vasculitis Presenting as Acute Tubulointerstitial Nephritis and Cardiac Involvement: A Case Report

Huajian Ying
Shanghai Fourth People's Hospital
Rui Zhu
Shanghai Fourth People's Hospital
Huijuan Wu
Department of Pathology of School of Basic Medical Sciences, Fudan University
Shunjie Chen
Shanghai Fourth People's Hospital
Xiang Gao
gaoxiang43100636@163.com

Shanghai Fourth People's Hospital

Case Report

Keywords: ANCA-associated vasculitis, Microscopic polyangiitis, Tubulointerstitial nephritis, Cardiac involvement, Case report

Posted Date: October 22nd, 2026

DOI: https://doi.org/10.21203/rs.3.rs-11174995/v1

License: This work is licensed under a Creative Commons Attribution 4.0 International License.
Read Full License

Additional Declarations: No competing interests reported.

Abstract

Background

Antineutrophil cytoplasmic antibody-associated vasculitis (AAV) usually presents with pauci-immune necrotizing and crescentic glomerulonephritis, hematuria, and rapidly progressive kidney dysfunction. However, AAV may rarely manifest as tubulointerstitial-dominant renal injury without hematuria, creating diagnostic uncertainty. Cardiac involvement in AAV can also mimic acute coronary syndrome, particularly when dynamic electrocardiographic changes and elevated cardiac biomarkers are present.

Case presentation:

A 64-year-old man with hypertension and type 2 diabetes mellitus presented with severe oliguric acute kidney injury and acute left heart failure. Urinalysis showed predominantly tubular proteinuria without hematuria. After continuous renal replacement therapy, his heart failure improved substantially, but dynamic electrocardiographic changes and marked Troponin I elevation to 1.6 ng/mL developed on hospital day 3. Coronary angiography revealed moderate left anterior descending artery stenosis of 60–70%, which was insufficient to explain the extent of myocardial injury. MPO-ANCA was strongly positive at 215.6 AU/mL. Kidney biopsy demonstrated predominant acute tubulointerstitial nephritis with relative glomerular sparing and pauci-immune immunofluorescence, supporting a diagnosis of microscopic polyangiitis with atypical renal involvement. Although heart failure had improved, cardiac biomarkers continued to rise before subsequently normalizing in parallel with ANCA decline, suggesting vasculitis-driven myocardial injury. The patient received double filtration plasmapheresis combined with immunosuppressive therapy. ANCA titers rapidly normalized, cardiac biomarkers improved, and the patient was gradually weaned off renal replacement therapy.

Conclusion

This case illustrates an unusual presentation of MPO-ANCA-associated microscopic polyangiitis with tubulointerstitial-dominant nephritis without hematuria and concurrent cardiac involvement mimicking acute coronary syndrome. Improvement in volume overload or heart failure does not exclude ongoing vasculitis-related myocardial injury. In patients with unexplained acute kidney injury and concurrent myocardial injury, AAV should be considered even when hematuria is absent, and early ANCA testing, kidney biopsy, and timely immunosuppressive therapy may be crucial for organ recovery.

Introduction

Microscopic polyangiitis (MPA), a major subtype of antineutrophil cytoplasmic antibody (ANCA)-associated vasculitis (AAV), classically causes systemic small-vessel inflammation(1). In the kidneys, it predominantly manifests as pauci-immune necrotizing and crescentic glomerulonephritis. The classic

clinical hallmark is rapidly progressive kidney failure accompanied by an active urinary sediment characterized by dysmorphic hematuria and glomerular proteinuria(2–4). Predominant acute tubulointerstitial lesions are rare in AAV and often lead to diagnostic delays(5).

While subclinical cardiovascular involvement in AAV is increasingly recognized, acute life-threatening cardiac manifestations such as vasculitis-induced myocardial injury mimicking ischemic heart disease are rare but carry high mortality if untreated(6). The simultaneous presentation of severe atypical renal and cardiac involvement poses substantial diagnostic challenges. Herein, we describe a case of severe AKI driven by MPO-ANCA vasculitis manifesting as acute tubulointerstitial lesions without hematuria, concurrent with acute ANCA-associated cardiac injury.

Case Presentation

A 64-year-old retired male, with a history of hypertension and type 2 diabetes mellitus, presented with a two-month course of fatigue and anorexia. Progressive oliguria (about 400 mL/day), chest tightness, and dyspnea developed one week prior to admission. The outpatient medical records documented a serum creatinine (SCr) level of 87 μmol/L one month prior to admission, which had increased to 144 μmol/L one week later, accompanied by elevated C-reactive protein (CRP). Upon admission, physical examination revealed anemic appearance, bibasilar lung crackles, and moderate generalized edema.

Initial laboratory findings confirmed severe AKI (SCr 722 μmol/L), severe anemia (Hb 66 g/L), and marked systemic inflammation (CRP 145.19 mg/L). Urinalysis showed no hematuria (RBC 0.9/μL). The urinary protein spectrum indicated predominantly tubular damage, with elevated Microalbumin (158 mg/L) and α1-microglobulin (73.1 mg/L). Chest computed tomography on admission revealed bilateral diffuse pulmonary infiltrates, and B-type natriuretic peptide (BNP) was markedly elevated at 2873 pg/mL, consistent with acute left heart failure (Table 1 and Fig. 1).

Table 1
.Laboratory parameters at admission and at three-month follow-up

Parameter	On Admission	3-Month Follow-up
Hematology		
White Blood Cell(10^9/L)	13.30	9.05
Red Blood Cell(10^9/L)	2.72	3.88
Hemoglobin(g/L)	66	136
Blood Chemisty		
Albumin(g/L)	29.21	39.58
Serum Creatinine(umol/L)	766.0	280.3
Cystatin C(mg/L)	5.59	3.19
eGFR(mL/min/1.73m^2)	7.08	21.11
BNP(pg/ml)	2870	155
Inflammatory Markers		
Interleukin-6 (pg/mL)	64.33	<7
CRP (mg/L)	145.19	<0.50
Immunology		
MPO(AU/ml)	215.60	3.00
P-ANCA	Postive	Negative
Urinalysis		
Urine Occult Blood	Negative	Negative
Urine Protein	2+	1+
Urine RBC (/μL)	0.90	14.40
Microalbumin (mg/L)	158	283
α1-Microglobulin (mg/L)	73.10	39.90

CRRT was initiated promptly for fluid removal and renal support. Following CRRT-mediated fluid removal, heart failure symptoms improved and pulmonary infiltrates partially resolved on follow-up imaging. However, on hospital day 3, dynamic changes appeared on the electrocardiogram (ECG) and Troponin I rose to 1.6 ng/mL, with echocardiography demonstrating a reduced ejection fraction (51%) and global biventricular hypokinesia. The persistence of cardiac biomarker elevation and dynamic ECG changes

despite hemodynamic improvement after heart failure correction raised concern for myocardial injury beyond a purely congestive etiology (Fig. 2). Emergency coronary angiography revealed moderate stenosis of the left anterior descending artery (LAD, 60–70%), which was judged insufficient to account for the dynamic ECG changes or the magnitude of troponin elevation; antiplatelet therapy and statin were initiated for this incidental coronary finding (Fig. 2).

An extended autoimmune panel returned strongly positive for MPO-ANCA (215.6 AU/mL) and positive P-ANCA by indirect immunofluorescence. Integrating the unexplained myocardial injury without significant coronary obstruction, the marked systemic inflammation, and the rapidly progressive renal failure, a diagnosis of systemic AAV with atypical renal injury and ANCA-associated cardiac involvement was established.

The patient underwent double filtration plasmapheresis (DFPP) to clear pathogenic autoantibodies, complemented by intravenous albumin and immunoglobulins. Concurrently, methylprednisolone and cyclophosphamide were administered. ANCA titers declined rapidly and systemic inflammatory markers normalized. Within three weeks of immunosuppressive therapy, cardiac enzymes (Troponin I and BNP) rapidly decreased to baseline levels (Fig. 4).

During ongoing immunosuppressive therapy, a percutaneous kidney biopsy was performed to clarify the renal pathology and confirm the underlying diagnosis. Kidney biopsy demonstrated predominant acute tubulointerstitial nephritis with relative glomerular sparing: dense interstitial inflammatory infiltrates, acute tubulitis, moderate tubular atrophy, and interstitial fibrosis, with pauci-immune immunofluorescence. Only 1 of 13 glomeruli harbored small cellular crescent, and fibrinoid necrosis was absent(Fig. 3). This pattern directly explained the clinical paradox of severe AKI with tubular proteinuria in the absence of hematuria. After three months of continuous immunosuppression and volume management, the patient's urine output increased to 2,000 mL/day and pre-dialysis SCr stabilized at approximately 280 μmol/L in 3 months, enabling withdrawal from renal replacement therapy.

Discussion

To our knowledge, this is the first reported case of MPO-ANCA-associated vasculitis simultaneously presenting with predominant acute tubulointerstitial nephritis as the exclusive renal manifestation and clinically overt cardiac involvement mimicking acute coronary syndrome. Isolated tubulointerstitial nephritis accounts for fewer than 5% of AAV renal cases (7–10), while overt cardiac involvement occurs in only about 6–10% of AAV patients, and is more commonly seen in eosinophilic granulomatosis with polyangiitis (EGPA)(11, 12). Their co-occurrence in a single patient has not been previously documented. We propose that MPO-ANCA-driven microvasculitis simultaneously targeted two microvascular beds—the peritubular capillaries of the renal interstitium and the coronary microvasculature—unified by a shared pauci-immune necrotizing mechanism. Unexplained AKI with concurrent myocardial injury, particularly without hematuria, should prompt immediate ANCA serology.

Fewer than 30 cases of AAV presenting as primary acute tubulointerstitial nephritis without significant glomerular damage have been reported (7–9). MPO released from activated neutrophils depletes CD34-positive endothelial markers preferentially in peritubular vessels, selectively injuring the interstitial microvasculature while sparing glomerular tufts (13). The resulting mismatch—severe oliguric AKI with predominantly tubular proteinuria and a silent urinary sediment—can mislead clinicians toward drug-induced acute tubulointerstitial nephritis. The absence of hematuria or glomerular crescents does not exclude AAV.

Cardiac involvement in AAV varies substantially by subtype. In EGPA, cardiac involvement occurs in up to 20–50% of patients and driven by eosinophil-mediated myocardial infiltration, endomyocardial fibrosis, and Loeffler endocarditis(6, 14). By contrast, cardiac involvement in MPA is less frequent and is mediated by neutrophil-driven pauci-immune microvasculitis of the coronary microcirculation, without eosinophilia or granuloma formation(12, 15–17). In this patient, the pattern of global left ventricular hypokinesia without regional wall motion abnormality is consistent with diffuse myocardial microvasculitis. The persistence of cardiac biomarker elevation and dynamic ECG changes after heart failure correction—a dissociation between hemodynamic recovery and ongoing myocardial enzyme elevation—argues against a purely congestive mechanism and supports active vasculitic myocardial injury. The synchronized normalization of cardiac biomarkers and ANCA titers following targeted immunosuppression confirmed a vasculitis-driven etiology.

The prognosis of AAV with tubulointerstitial-dominant renal injury is strongly shaped by the extent of IFTA and kidney function at the time of diagnosis—parameters that are directly worsened by diagnostic delay (18, 19). Validated risk stratification tools, including the ARRS and the revised AKRiS, consistently demonstrate that accumulated IFTA, rather than the degree of glomerular crescent formation, is the principal histological driver of ESKD risk(19). In tubulointerstitial-dominant AAV, the absence of hematuria frequently postpones diagnosis, allowing ongoing peritubular microvasculitis to progress silently to irreversible interstitial fibrosis. In this patient, the moderate-to-severe IFTA already present at biopsy—compounded by pre-existing diabetic nephropathy and hypertensive nephrosclerosis—reflects the cumulative cost of diagnostic delay and underscores that the window for renal salvage is narrow. Early ANCA serology and prompt immunosuppression are therefore not merely recommended but essential to interrupt the fibrotic cascade before irreversible nephron loss occurs. The parallel normalization of cardiac biomarkers and ANCA titers following timely immunosuppression in this case further reinforces that early intervention preserves not only renal but also cardiac function.

Conclusion

AAV must remain a key differential diagnosis in patients with unexplained acute myocardial injury and severe AKI, even without hematuria or when confounded by baseline metabolic diseases. Atypical predominant tubulointerstitial AAV lesions warrant early clinical suspicion. The persistence of cardiac biomarker elevation after heart failure correction should alert clinicians to ongoing vasculitic myocardial injury. Prompt angiographic exclusion of coronary disease, coupled with timely ANCA serology and

kidney biopsy, can expedite the implementation of combined plasmapheresis and tailored immunosuppression, thereby preserving organ function and minimizing infectious complications.

Patient perspective

The patient reported that the sudden onset of severe kidney dysfunction, oliguria, and the need for renal replacement therapy had caused significant anxiety and emotional distress. He was also worried by the concurrent cardiac abnormalities, especially because myocardial injury persisted despite improvement in heart failure symptoms. After discussion with the medical team, he understood that both the renal and cardiac manifestations were likely related to the same systemic immune-mediated disease. Following double filtration plasmapheresis and immunosuppressive therapy, the patient reported marked improvement in symptoms, urine output, and confidence in recovery. Discontinuation of renal replacement therapy substantially reduced his psychological burden. He hoped that sharing his experience would help improve awareness of atypical presentations of ANCA-associated vasculitis.

Declarations

Acknowledgements

The authors appreciate the patient for his patience and cooperation in the diagnostic work-up and follow-up.

Funding

This work was supported by the Research Startup Funding of Shanghai Fourth People's Hospital Affiliated to Tongji University (Grant No. sykyqd11801, China to X. Gao.) ,and Shanghai Municipal Committee of Science and Technology for Program of Shanghai Academic/Technology Research Leader (Grant No.23XD1402600).

Conflicts of Interest

The authors declare that they have no relevant financial interests.

Ethics Statement

This case report was conducted in accordance with the principles of the Declaration of Helsinki. According to the policy of our institution, ethical approval was not required for the publication of a single anonymized case report. Written informed consent was obtained from the patient for publication of this case report and any accompanying images or clinical data. All identifying information has been removed to protect the patient's privacy.

Consent for Publication

Written informed consent was obtained from the patient for the publication of this case report, including his clinical details and any accompanying images. A copy of the written consent is available for review by the Editor-in-Chief of this journal.

Data Availability Statement

The data that support the findings of this study are available on request from the corresponding author. The data are not publicly available due to privacy or ethical restrictions.

Author Contributions

Huajian Ying, Huijuan Wu and Rui Zhu participated in patient case management, collected clinical data, and drafted and revised the manuscript. Xiang Gao and Shunjie Chen were involved in the patient case, delivered the necessary data, and critically revised the manuscript for intellectual content. Xiang Gao and Shunjie Chen were accountable for all aspects of the work in ensuring that questions related to the accuracy or integrity of any part of the work were appropriately investigated and resolved. All authors contributed to the article and approved the submitted version.

References

1. Seo P, Stone JH. The antineutrophil cytoplasmic antibody-associated vasculitides. Am J Med. 2004;117(1):39–50.
2. Haas M, Eustace JA. Immune complex deposits in ANCA-associated crescentic glomerulonephritis: a study of 126 cases. Kidney Int. 2004;65(6):2145–52.
3. Eisenberger U, Fakhouri F, Vanhille P, Beaufils H, Mahr A, Guillevin L, et al. ANCA-negative pauci-immune renal vasculitis: histology and outcome. Nephrol Dial Transpl. 2005;20(7):1392–9.
4. Hauer HA, Bajema IM, van Houwelingen HC, Ferrario F, Noel LH, Waldherr R, et al. Renal histology in ANCA-associated vasculitis: differences between diagnostic and serologic subgroups. Kidney Int. 2002;61(1):80–9.
5. Lin ZS, Liu XL, Cui Z, Wang SX, Yu F, Zhou FD, et al. Acute tubulointerstitial nephritis with germinal centers in antineutrophil cytoplasmic antibody-associated vasculitis: A case report and literature review. Med (Baltim). 2019;98(48):e18178.
6. Sanchez Alamo B, Moi L, Bajema I, Faurschou M, Flossmann O, Hauser T, et al. Long-term outcomes and prognostic factors for survival of patients with ANCA-associated vasculitis. Nephrol Dial Transpl. 2023;38(7):1655–65.
7. Kasahara H, Hiroyuki N, Shinohara M, Koike T. AP-VAS 2012 case report: an atypical case of microscopic polyangiitis presenting with acute tubulointerstitial nephritis without glomerular change. CEN Case Rep. 2014;3(1):1–4.
8. Plafkin C, Zhong W, Singh T. ANCA vasculitis presenting with acute interstitial nephritis without glomerular involvement. Clin Nephrol Case Stud. 2019;7:46–50.

9. He X, Wen Y, Hu R, Wu H, Ye W, Yue C, et al. Interstitial nephritis without glomerulonephritis in ANCA-associated vasculitis: a case series and literature review. Clin Rheumatol. 2022;41(11):3551–63.
10. Taniguchi T. Tubulointerstitial nephritis as a rare manifestation of ANCA-associated vasculitis: the challenge for its diagnosis and classification. CEN Case Rep. 2024;13(1):78–9.
11. Zycinska K, Borowiec A. Cardiac manifestations in antineutrophil cytoplasmic autoantibody (ANCA) - associated vasculitides. Kardiol Pol. 2016;74(12):1470–6.
12. Sarmad A, Gholizadeh Ghozloujeh Z, Hanna PE, Kronbichler A, Geetha D, Heidari-Bateni G, et al. Cardiovascular involvement in ANCA-associated vasculitis. Nephrol Dial Transpl. 2025;40(12):2256–67.
13. Nakabayashi K, Sumiishi A, Sano K, Fujioka Y, Yamada A, Karube M, et al. Tubulointerstitial nephritis without glomerular lesions in three patients with myeloperoxidase-ANCA-associated vasculitis. Clin Exp Nephrol. 2009;13(6):605–13.
14. Wallace ZS, Fu X, Harkness T, Stone JH, Zhang Y, Choi H. All-cause and cause-specific mortality in ANCA-associated vasculitis: overall and according to ANCA type. Rheumatology (Oxford). 2020;59(9):2308–15.
15. Khanna S, Garikapati K, Goh DSL, Cho K, Lo P, Bhojaraja MV, et al. Coronary artery vasculitis: a review of current literature. BMC Cardiovasc Disord. 2021;21(1):7.
16. Pagnoux C, Guillevin L. Cardiac involvement in small and medium-sized vessel vasculitides. Lupus. 2005;14(9):718–22.
17. Wang CR, Tsai YS, Tsai HW. Acute Myocarditis in Patients with Antineutrophil Cytoplasmic Antibody-positive Microscopic Polyangiitis and Receiving Rituximab Therapy. J Rheumatol. 2019;46(12):1645–6.
18. Wang RX, Wang JW, Li ZY, Chen SF, Yu XJ, Wang SX, et al. A modified renal risk score for Chinese patients with antineutrophil cytoplasmic antibody-associated vasculitis. BMC Med. 2023;21(1):45.
19. Bate S, McGovern D, Costigliolo F, Tan PG, Kratky V, Scott J, et al. The Improved Kidney Risk Score in ANCA-Associated Vasculitis for Clinical Practice and Trials. J Am Soc Nephrol. 2024;35(3):335–46.

Figures

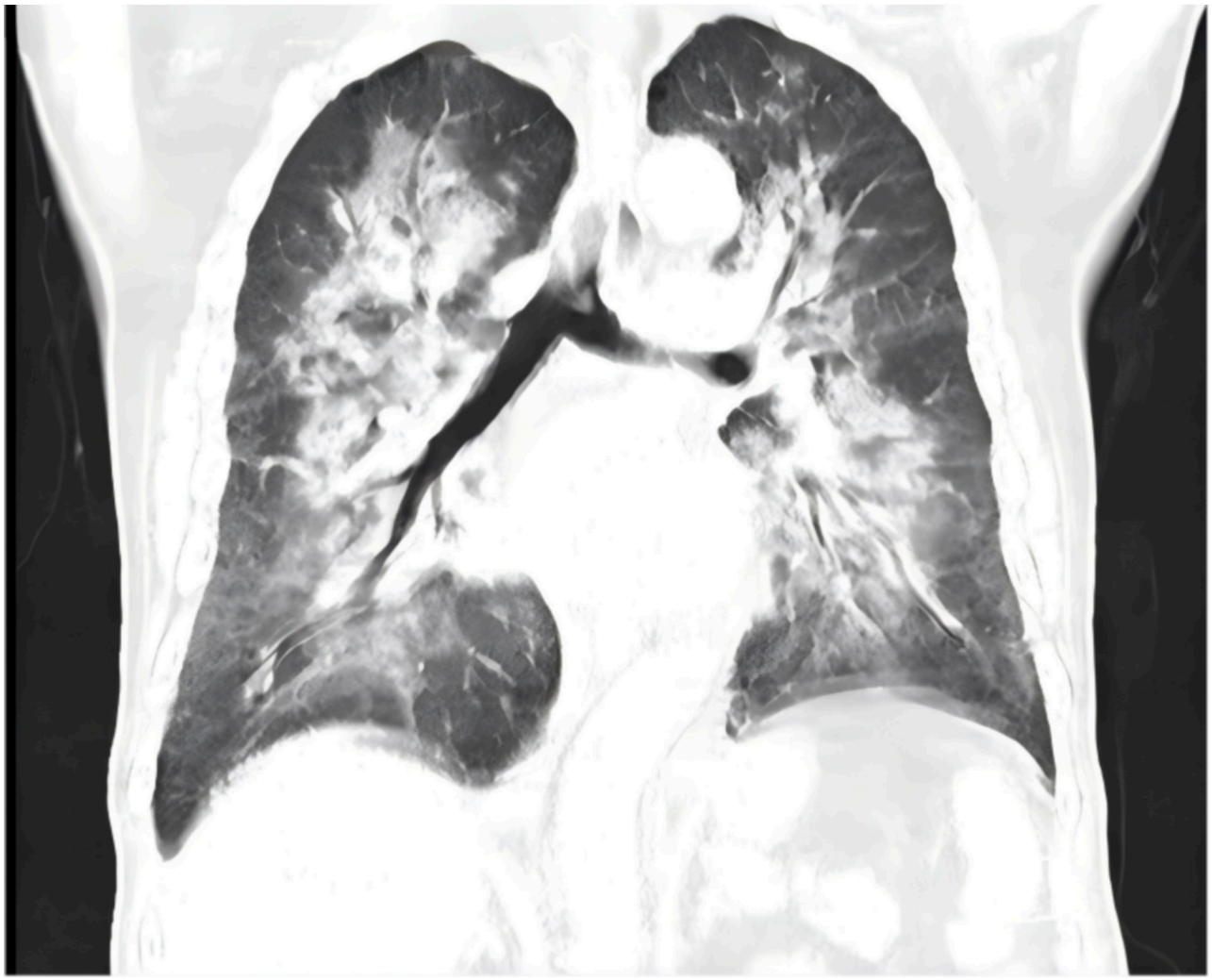

Figure1: Chest CT on admission demonstrating bilateral multifocal pulmonary infiltrates with pulmonary edema, consistent with acute left heart failure.

Figure 1

Chest imaging on admission

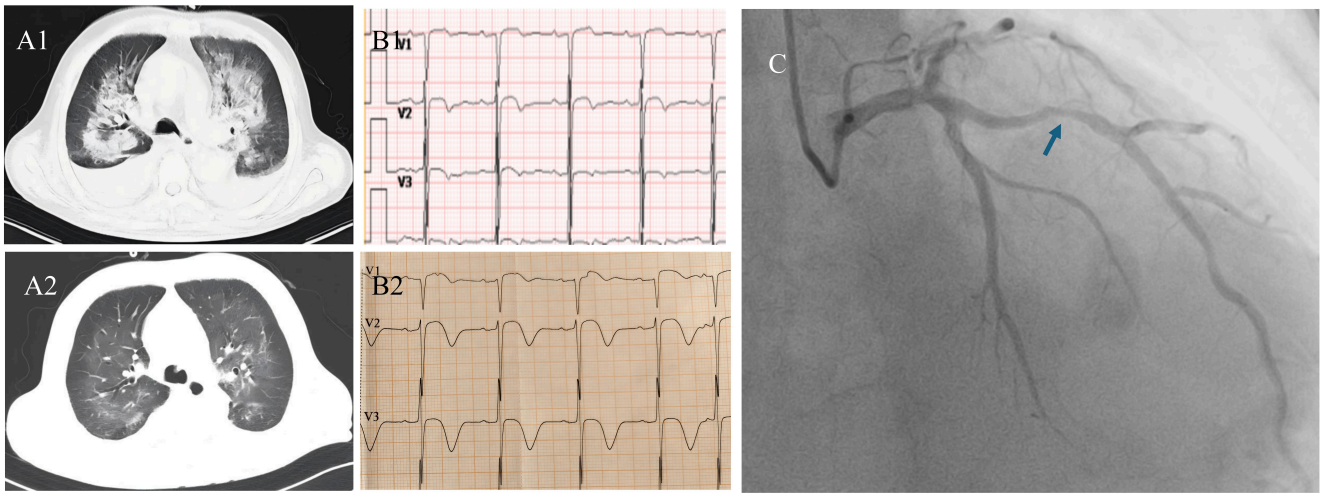

Figure2 : **(A1)** Admission chest CT demonstrating bilateral diffuse pulmonary infiltrates consistent with acute left heart failure. **(A2)** Repeat chest CT on hospital day 3 showing marked resolution of bilateral pulmonary infiltrates following CRRT-mediated fluid removal. **(B1)** Admission ECG showing left ventricular high voltage and sinus tachycardia without significant ST-segment abnormalities. **(B2)** Repeat ECG on hospital day 3 revealing new dynamic ST-segment changes in leads V1–V4, despite concurrent resolution of heart failure and improvement of pulmonary infiltrates, raising concern for myocardial injury beyond a purely congestive etiology. **(C)** Emergency coronary angiography demonstrating moderate left anterior descending artery (LAD) stenosis (60–70%), judged insufficient to account for the dynamic ECG changes and the magnitude of troponin elevation, supporting an inflammatory microvascular etiology.

Figure 2

Serial chest CT, ECG findings, and coronary angiography

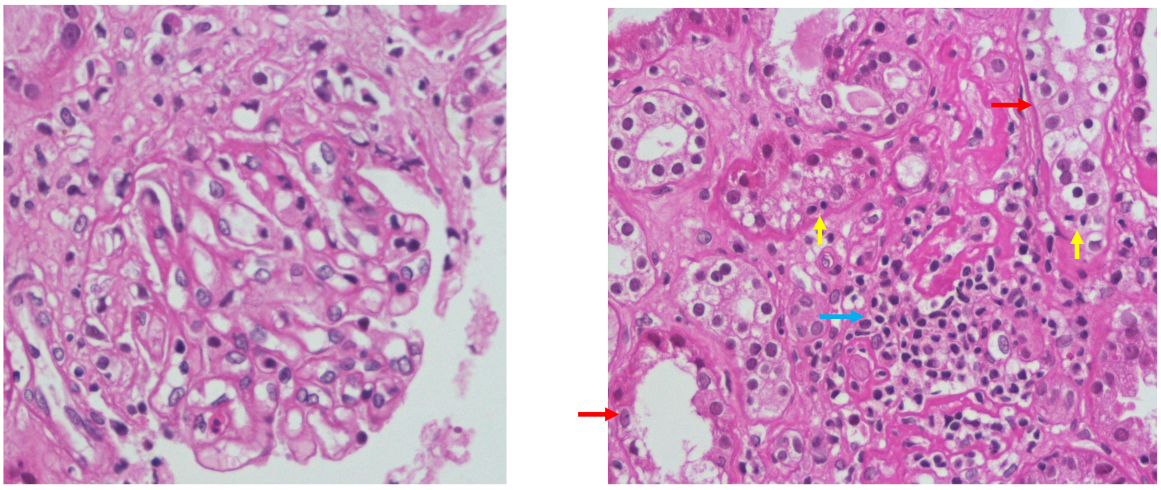

Figure3: Histology reveals extensive focal and diffuse interstitial inflammatory infiltrates, predominantly composed of lymphocytes and monocytes with admixed neutrophils, accompanied by overt tubulitis and acute tubular injury. A small number of renal arterioles demonstrate localized wall thickening and hyalinization. Cellular crescent was present in a minority of glomeruli (1/13), with fibrinoid necrosis absent. This pattern of predominant tubulointerstitial injury with relative glomerular sparing, in the context of positive MPO-ANCA, is consistent with microscopic polyangiitis (MPA).

Figure 3

Pathological findings of kidney biopsy

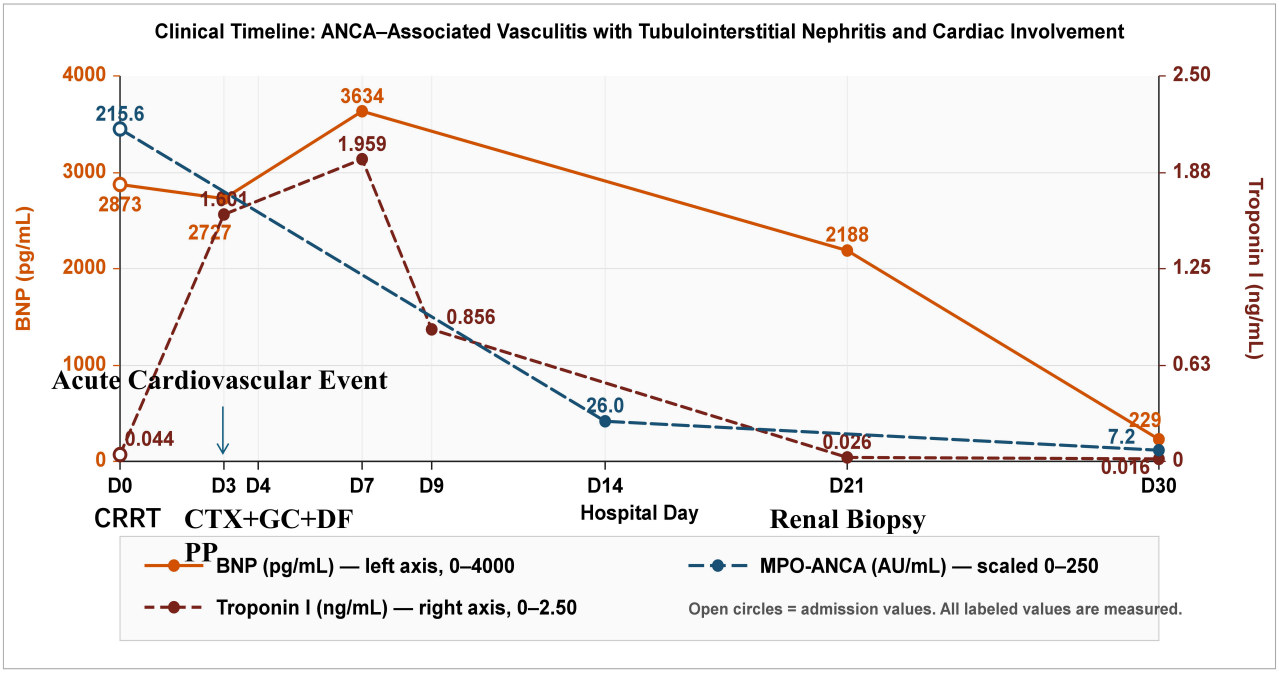

Figure4: Dynamic changes in key laboratory parameters (BNP, Troponin I, and MPO-ANCA titers) and major therapeutic interventions over the one-month hospitalization. The dissociation between early hemodynamic improvement and persistent cardiac biomarker elevation is highlighted, with subsequent parallel normalization of cardiac biomarkers and ANCA titers following sustained immunosuppression.

Figure 4

Clinical timeline of laboratory parameters and therapeutic interventions