Research Square

Preprints are preliminary reports that have not undergone peer review.
They should not be considered conclusive, used to inform clinical practice,
or referenced by the media as validated information.

Tubeless uniportal thoracoscopic resection and reconstruction of a distal tracheal pleomorphic adenoma: a case report

Hongjin Wang
Fujian Medical University Affiliated Longyan First Hospital: Longyan First Hospital
Zhixiang Tu
Fujian Medical University Affiliated Longyan First Hospital: Longyan First Hospital
Jiehuan Lin
Fujian Medical University Affiliated Longyan First Hospital: Longyan First Hospital
Mengjun Chen
Fujian Medical University Affiliated Longyan First Hospital: Longyan First Hospital
Guobing Xu
Drxgb0811@163.com

Fujian Medical University Union Hospital

Research Article

Keywords: Tracheal neoplasms, pleomorphic adenoma, video-assisted thoracic surgery, laryngeal mask airway, spontaneous ventilation

Posted Date: November 23rd, 2026

DOI: https://doi.org/10.21203/rs.3.rs-11137172/v1

License: This work is licensed under a Creative Commons Attribution 4.0 International License.
Read Full License

Additional Declarations: No competing interests reported.

Abstract

Pleomorphic adenoma of the trachea is rare, and a lesion immediately above the carina creates competing demands for airway control and surgical exposure. We describe a 56-year-old woman with a 14-mm tumor 1 cm above the carina who underwent two-ring distal tracheal resection and end-to-end reconstruction through uniportal video-assisted thoracoscopic surgery. A size-3 laryngeal mask airway supported a nonintubated, tube-free operative field during reconstruction. Transient peripheral oxygen saturation to 82% recovered with assisted ventilation without cross-field intubation or extracorporeal membrane oxygenation. Histology confirmed pleomorphic adenoma with negative margins, and computed tomography at 1 month showed a patent airway. This case emphasizes the geometry-driven surgical benefit of a tube-free field and the need for predefined rescue strategies when physiologic reserve becomes limited.

INTRODUCTION

Primary tracheal tumors are uncommon, and pleomorphic adenoma is an especially rare salivary gland-type neoplasm showing epithelial and myoepithelial differentiation.[1-4] For a localized, operable lesion, segmental resection offers a full-thickness specimen and the possibility of a negative margin, whereas bronchoscopic treatment may be limited by tumor base, bleeding risk, and uncertainty regarding the deep margin.[2-5] The challenge becomes greater when a lesion is immediately above the carina because the airway is simultaneously the surgical target and the route for ventilation.

Conventional cross-field ventilation is reliable during tracheal reconstruction, but a tube positioned across a very distal anastomosis can obstruct visualization and compete with the thoracoscope, needle holder, and suture within a uniportal working axis. Minimally invasive tracheal surgery under spontaneous ventilation has therefore been explored in carefully selected patients.[6-15] We report a near-carinal tracheal pleomorphic adenoma treated by uniportal video-assisted thoracoscopic segmental resection and reconstruction using a laryngeal mask airway (LMA) to maintain a nonintubated, tube-free operative field. The case is distinctive not because nonintubated tracheal surgery is unprecedented, but because it demonstrates both the geometric advantage of removing a cross-field tube near the carina and the physiologic limits of that strategy through a documented episode of transient hypoxemia.

CASE REPORT

A 56-year-old woman presented with chest pain and cough for more than 1 month. Contrast-enhanced computed tomography showed a 14-mm intraluminal mass in the distal trachea, with the inferior margin approximately 1 cm above the carina (Fig. 1A). Bronchoscopy confirmed a protruding, vascular-appearing endotracheal lesion partially occupying the lumen (Fig. 1B). Because the lesion was localized and technically resectable, complete surgical excision with segmental tracheal reconstruction was selected after multidisciplinary assessment.

General anesthesia was induced and a size-3 LMA was inserted. The airway plan was designed to avoid an endotracheal or cross-field tube within the operative field during tracheal opening and anastomosis. A double-lumen tube was prepared for rescue ventilation, and extracorporeal membrane oxygenation (ECMO) was available as a further rescue option if adequate gas exchange could not be maintained.

With the patient in the lateral decubitus position, a uniportal video-assisted thoracoscopic approach was established through the fourth intercostal space at the midaxillary line. The distal trachea was exposed and mobilized (Fig. 2A). The tumor-bearing segment was identified (Fig. 2B), and 2 tracheal rings, corresponding to approximately 1 cm of trachea, were resected en bloc. The distal tracheal end was prepared for reconstruction (Fig. 2C), and primary end-to-end anastomosis was performed with interrupted full-thickness polypropylene sutures (Fig. 2D). Cervical flexion was maintained postoperatively to minimize anastomotic tension.

During the open-airway phase, spontaneous ventilation through the LMA allowed the anastomotic field to remain free of an intratracheal tube. Temporary assisted ventilation was used when required. A brief episode of hypoxemia occurred, with peripheral oxygen saturation decreasing to 82%; the intraoperative airway setup and physiologic trend are shown in Fig. 3. Oxygenation recovered after assisted ventilation, and neither cross-field/endotracheal intubation nor extracorporeal membrane oxygenation was required. The total operative time was 170 minutes. Detailed arterial blood gas measurements and complete ventilatory settings were not available for retrospective reporting.

Histopathologic examination showed a benign biphasic epithelial-myoepithelial neoplasm consistent with pleomorphic adenoma (Fig. 4A). SOX-10, S-100, p63, and calponin were positive in the myoepithelial component, whereas CK19 and CD117 were positive in epithelial components. The Ki-67 proliferation index was approximately 8%, and surgical margins were negative.

The postoperative course was uncomplicated, without anastomotic leak, hoarseness, or pulmonary infection. The chest tube was removed on postoperative day 5, and the patient was discharged on postoperative day 7. Computed tomography at 1 month demonstrated a patent reconstructed distal trachea without apparent stenosis (Fig. 4B). At 3 months, the patient remained asymptomatic with no evidence of recurrence.

COMMENT

This case has 2 linked lessons: one oncologic and one technical. From the oncologic perspective, tracheal pleomorphic adenoma is generally indolent, but its natural history is incompletely defined and local recurrence has been reported after incomplete treatment.[2–4] Bronchoscopic excision can be reasonable for selected endoluminal lesions, and long-term disease control after bronchoscopic treatment has been described even when the margin was not clearly negative.[4] That experience should not, however, be generalized to every near-carinal lesion. A recent report of pleomorphic adenoma only 1 to 2 rings above the carina described bleeding, bronchospasm, and acute airway collapse during

bronchoscopic cryotherapy, illustrating how a seemingly less invasive approach can become hazardous when the tumor occupies a critical airway location.[5] In our patient, the lesion was localized and the anticipated resection length was short; segmental resection therefore provided a full-thickness specimen and a negative-margin resection while avoiding uncertainty at the tumor base.

The technical problem was not simply how to perform a thoracoscopic tracheal anastomosis, but how to share a short distal airway. Video-assisted thoracoscopic tracheal and carinal reconstruction has been feasible in multicenter experience,[6] and Guo and colleagues subsequently demonstrated uniportal tracheal resection under spontaneous ventilation without cross-field ventilation.[7] Jiang and colleagues compared spontaneous-ventilation video-assisted thoracoscopic surgery with intubated thoracoscopic surgery and reported shorter operative and anastomotic times in highly selected patients undergoing spontaneous ventilation.[8] These studies establish that the concept is not new. The particular value in the present case is geometry-driven: when the lesion is only approximately 1 cm above the carina, there is little distal tracheal length in which to place a cross-field tube, and the camera, ventilation device, needle holder, and suture all converge on the same narrow single-port axis. Removing the cross-field tube therefore does more than improve appearance of the field; it can reduce instrument collision precisely where symmetrical full-thickness bites and controlled suture handling are most important.

That ergonomic gain comes with a physiologic price. Once the trachea is opened, ventilation through a supraglottic airway no longer operates as a conventional closed circuit. Gas exchange may become sensitive to anesthetic depth, spontaneous respiratory effort, mediastinal motion, surgical manipulation, ventilation-perfusion mismatch, and dilution or escape of inspired gas through the open airway. A systematic review of airway strategies for tracheal resection emphasized that no single method is universally optimal and that technique selection must be individualized.[9] LMA-based airway management has been feasible in open tracheal surgery: Krecmerova and colleagues reported a patent airway throughout the operation in 52 of 54 patients,[10] and a matched comparison found no significant disadvantage in major short-term outcomes with LMA versus endotracheal-tube management.[11] Those studies support the LMA as a useful proximal airway device, but they do not eliminate the vulnerability created by an open intrathoracic airway.

For that reason, the nadir oxygen saturation of 82% should be regarded as a central learning point rather than an adverse detail to minimize. In a 33-patient series of intended “tubeless” spontaneous-ventilation thoracoscopic tracheal surgery, the tube-free visual-field strategy failed in 9 patients and ventilation was escalated to cross-field intubation or high-frequency jet ventilation.[13] In our patient, oxygenation recovered with temporary assisted ventilation and conversion was avoided. The episode nevertheless argues against defining success as the absence of any respiratory intervention. A safer definition is completion of the reconstruction without loss of airway control: deterioration is recognized early, an effective rescue maneuver is immediately available, and conversion is undertaken before hypoxemia or hypercapnia becomes dangerous. In that framework, conversion is not a technical failure; it is a prespecified safety endpoint.

This distinction also clarifies what “nonintubated” should mean in complex airway surgery. The goal is not ideological avoidance of an endotracheal tube, but selective removal of a device that interferes with a critical operative step while maintaining a credible path back to controlled ventilation. Published alternatives include small-caliber oxygen insufflation, cross-field ventilation, high-frequency jet ventilation, and extracorporeal support.[9,12,13] More recent pediatric and robotic reports further demonstrate that spontaneous-ventilation strategies can be adapted to different operative platforms, but all remain highly selected experiences.[14,15] A reasonable rescue ladder is therefore context dependent: optimize oxygen delivery and spontaneous breathing first; use brief assisted ventilation through the LMA when effective; introduce cross-field or jet ventilation if gas exchange remains inadequate; and consider ECMO as a planned adjunct or rescue when interruption of ventilation is expected to be prolonged or conventional methods are unlikely to be sufficient. The exact thresholds must be set before the airway is opened and agreed upon by the surgeon and anesthesiologist.

Patient selection is consequently more important than the label applied to the technique. Favorable features include adequate cardiopulmonary reserve, a short and technically resectable tracheal segment, limited anticipated bleeding, and no expectation of prolonged complex carinal reconstruction. Equally important are team factors that are difficult to capture in anatomic criteria: experience with spontaneous-ventilation thoracic anesthesia, the ability to establish distal cross-field ventilation rapidly, continuous physiologic monitoring, and immediate access to extracorporeal support when appropriate. The approach should therefore be considered an option for selected patients in experienced multidisciplinary teams rather than a replacement for conventional airway management.

The present report has important limitations. It describes a single selected patient, detailed arterial blood gas and ventilatory data were not available, and follow-up is limited to 3 months. Hypercapnia during the open-airway phase therefore cannot be characterized, and the current follow-up is insufficient to establish durable freedom from late anastomotic stenosis or recurrence of pleomorphic adenoma. The conclusion should remain deliberately narrow: LMA-supported nonintubated uniportal reconstruction can provide a valuable tube-free field for a very distal tracheal lesion, but the benefit is inseparable from rescue planning and should be reported together with physiologic events rather than technical success alone.

Declarations

DECLARATION OF INTERESTS

The authors declare that they have no known competing financial interests or personal relationships that could have appeared to influence the work reported in this paper.

ETHICS AND PATIENT CONSENT

According to institutional policy, ethical approval was not required for this single-patient case report. Written informed consent was obtained from the patient for publication of this case report and the accompanying images.

FUNDING

This research did not receive any specific grant from funding agencies in the public, commercial, or not-for-profit sectors.

Author Contribution

H.W. and Z.T. performed the surgical resection and reconstruction, and collected the clinical data. J.L. conducted the pathological examination and prepared Figure 4A. M.C. analyzed the radiological data and prepared Figures 1 and 4B. G.X. (corresponding author) conceived the study, supervised the project, and critically revised the manuscript. H.W. wrote the main manuscript text. All authors read and approved the final manuscript.

ACKNOWLEDGMENTS

None.

References

1. Macchiarini P. Primary tracheal tumours. Lancet Oncol. 2006;7:83–91. 10.1016/S1470-2045(05)70541-6.
2. Liao QN, Fang ZK, Chen SB, et al. Pleomorphic adenoma of the trachea: a case report and review of the literature. World J Clin Cases. 2020;8:6026–35. 10.12998/wjcc.v8.i23.6026.
3. Chen L, Zhang W, Li X. Analysis of clinical features of 7 cases of primary pleomorphic adenoma of lower respiratory tract and review of literature. Med (Baltim). 2023;102:e36258. 10.1097/MD.0000000000036258.
4. Ishibashi N, Tabata T, Nonomura R, et al. Long-term follow-up of tracheal pleomorphic adenoma: a case report. Respir Med Case Rep. 2024;51:102073. 10.1016/j.rmcr.2024.102073.
5. Al Hazzouri A, Hneidi M, Attieh P, Atallah K, Saliba K, Mourad P. Critical airway obstruction from a near-carinal intratracheal tumor managed with intratracheal cryotherapy: a case report. Clin Med Insights Case Rep. 2026;19:11795476261462790. 10.1177/11795476261462790.
6. Li J, Wang W, Jiang L, et al. Video-assisted thoracic surgery resection and reconstruction of carina and trachea for malignant or benign disease in 12 patients: three centers' experience in China. Ann Thorac Surg. 2016;102:295–303. 10.1016/j.athoracsur.2016.01.080.

7. Guo M, Peng G, Wei B, He J. Uniportal video-assisted thoracoscopic surgery in tracheal tumour under spontaneous ventilation anaesthesia. Eur J Cardiothorac Surg. 2017;52:392–4. 10.1093/ejcts/ezx076.
8. Jiang L, Liu J, Gonzalez-Rivas D, et al. Thoracoscopic surgery for tracheal and carinal resection and reconstruction under spontaneous ventilation. J Thorac Cardiovasc Surg. 2018;155:2746–54. 10.1016/j.jtcvs.2017.12.153.
9. Schieren M, Böhmer A, Dusse F, Koryllos A, Wappler F, Defosse J. New approaches to airway management in tracheal resections-a systematic review and meta-analysis. J Cardiothorac Vasc Anesth. 2017;31:1351–8. 10.1053/j.jvca.2017.03.020.
10. Krecmerova M, Schutzner J, Michalek P, Johnson P, Vymazal T. Laryngeal mask for airway management in open tracheal surgery-a retrospective analysis of 54 cases. J Thorac Dis. 2018;10:2567–72. 10.21037/jtd.2018.04.73.
11. Menna C, Fiorelli S, Massullo D, Ibrahim M, Rocco M, Rendina EA. Laryngeal mask versus endotracheal tube for airway management in tracheal surgery: a case-control matching analysis and review of the current literature. Interact Cardiovasc Thorac Surg. 2021;33:426–33. 10.1093/icvts/ivab092.
12. Wang P, Wang Q, Zhang W, Zheng H, Zhao J. A simple and practical intraoperative ventilation technique for uniportal video-assisted thoracoscopic tracheal reconstruction: a case report. Ann Transl Med. 2022;10:529. 10.21037/atm-21-6215.
13. Liu Y, Liang L, Yang H. Airway management in tubeless spontaneous-ventilation video-assisted thoracoscopic tracheal surgery: a retrospective observational case series study. J Cardiothorac Surg. 2023;18:59. 10.1186/s13019-023-02157-w.
14. Zhang Y, Mo Z, Yang C, He J, Li S, Lan L. Non-intubated tracheal resection and reconstruction for a tracheal tumor in an 8-year-old child. J Cardiothorac Surg. 2024;19:468. 10.1186/s13019-024-02949-8.
15. Guido Guerra RE, Bolaños Morales FV, Silva Gómez OF, et al. Uniportal robotic-assisted tracheal resection and reconstruction under spontaneous ventilation. Case Rep Anesthesiol. 2025;2025:4991280. 10.1155/cria/4991280.

Figures

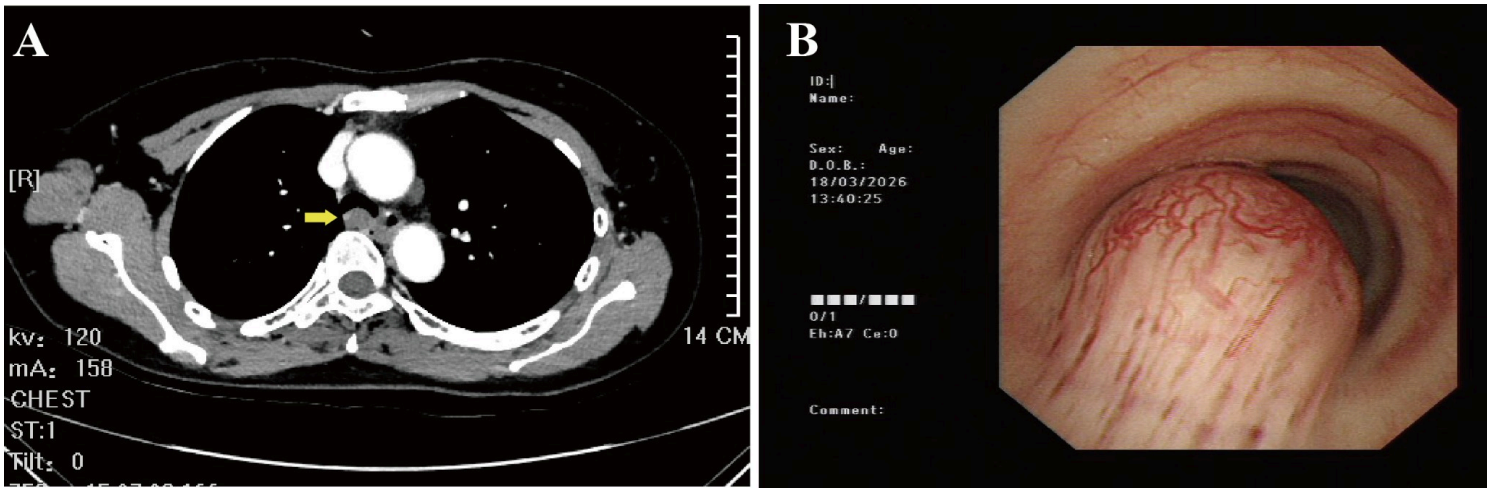

Figure 1

Preoperative evaluation of the distal tracheal tumor. (A) Contrast-enhanced chest computed tomography showing a 14-mm intraluminal lesion in the distal trachea (arrow), with the inferior margin approximately 1 cm above the carina. (B) Bronchoscopy showing a protruding, vascular-appearing endotracheal tumor partially occupying the lumen.

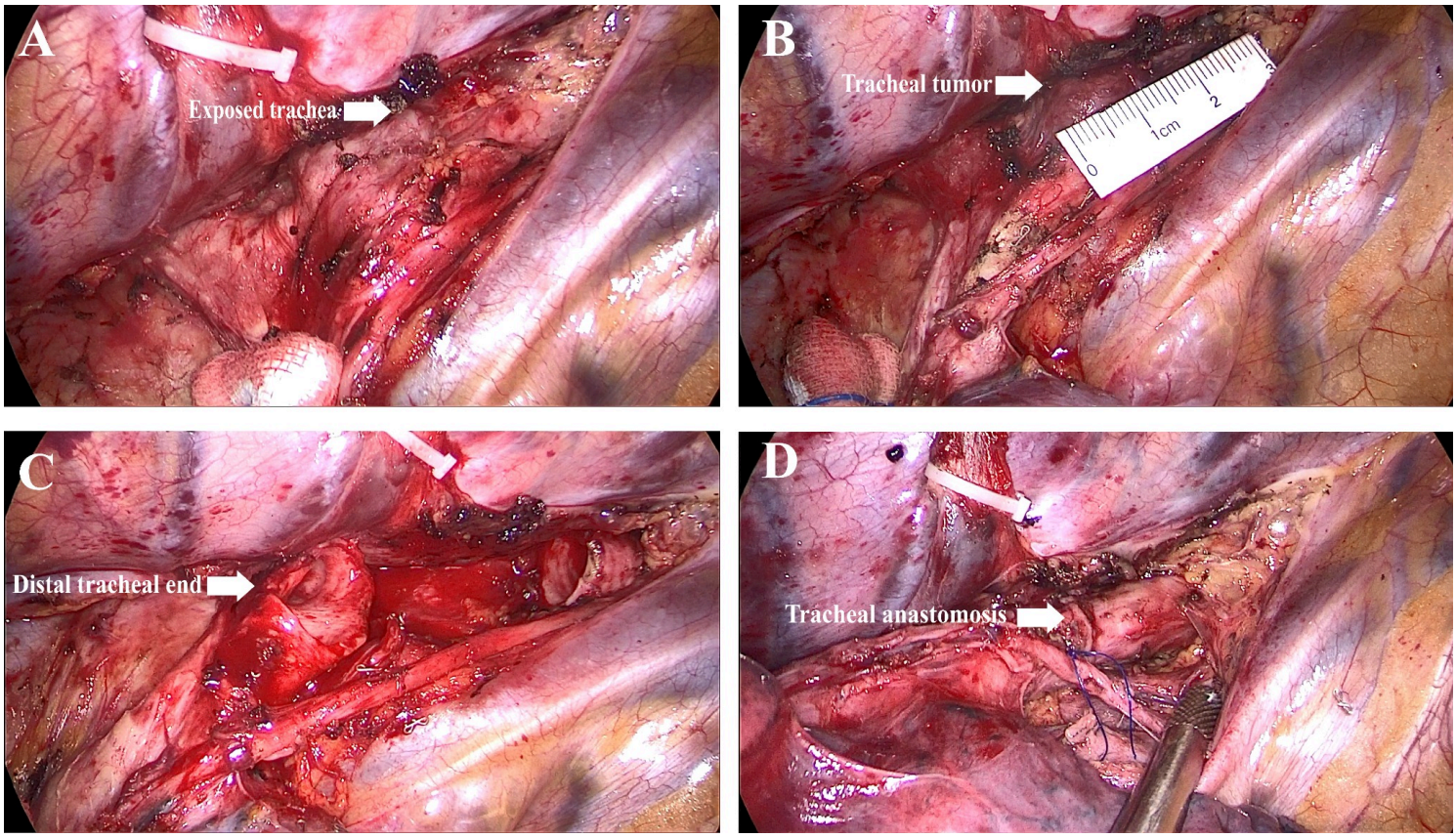

Figure 2

Uniportal video-assisted thoracoscopic distal tracheal resection and reconstruction. (A) Thoracoscopic exposure of the distal trachea. (B) Identification of the tumor-bearing tracheal segment. (C) Distal

tracheal end after segmental resection of 2 rings (approximately 1 cm). (D) Completed end-to-end tracheal anastomosis with interrupted full-thickness polypropylene sutures.

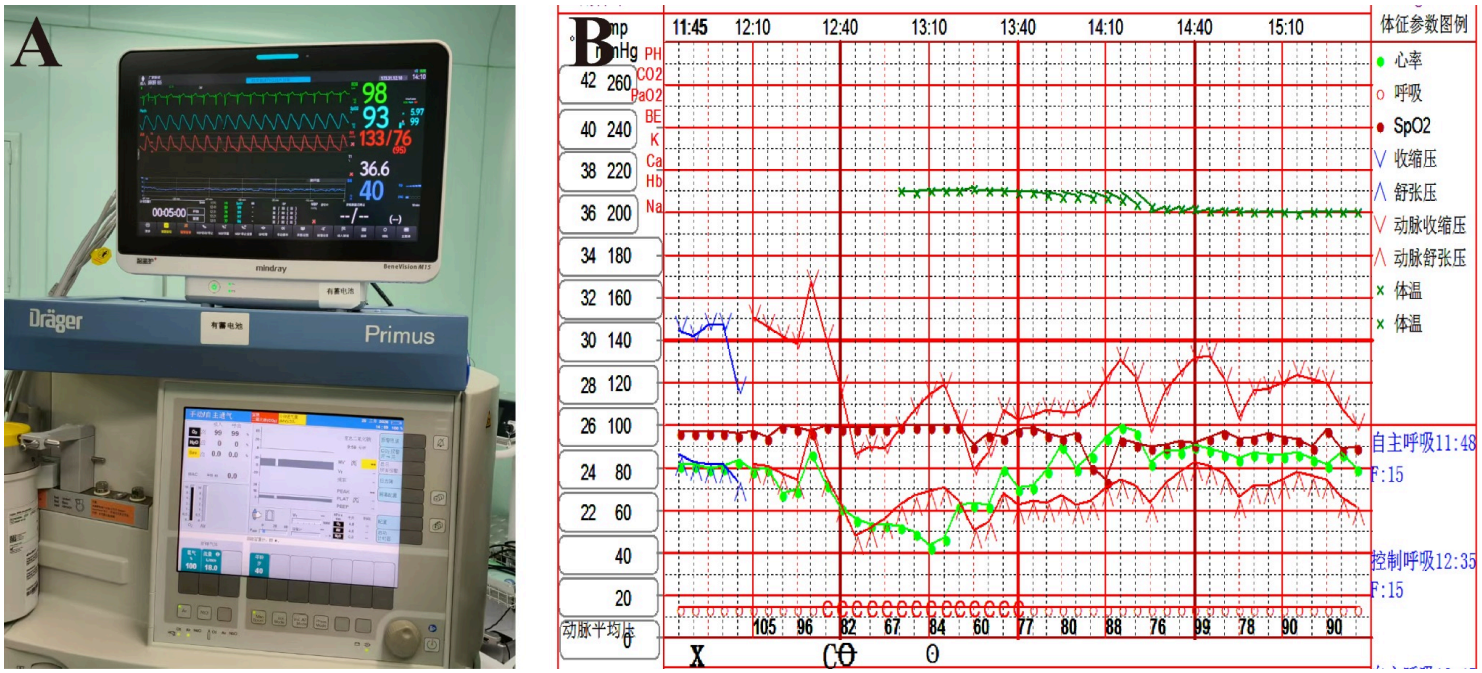

Figure 3

Airway management and intraoperative physiologic monitoring. (A) Anesthesia workstation and physiologic monitor during laryngeal-mask-supported nonintubated tracheal surgery. (B) Representative intraoperative trends demonstrating the transition between spontaneous and assisted/controlled ventilation and a transient oxygen-desaturation episode, which was corrected without endotracheal intubation or extracorporeal membrane oxygenation.

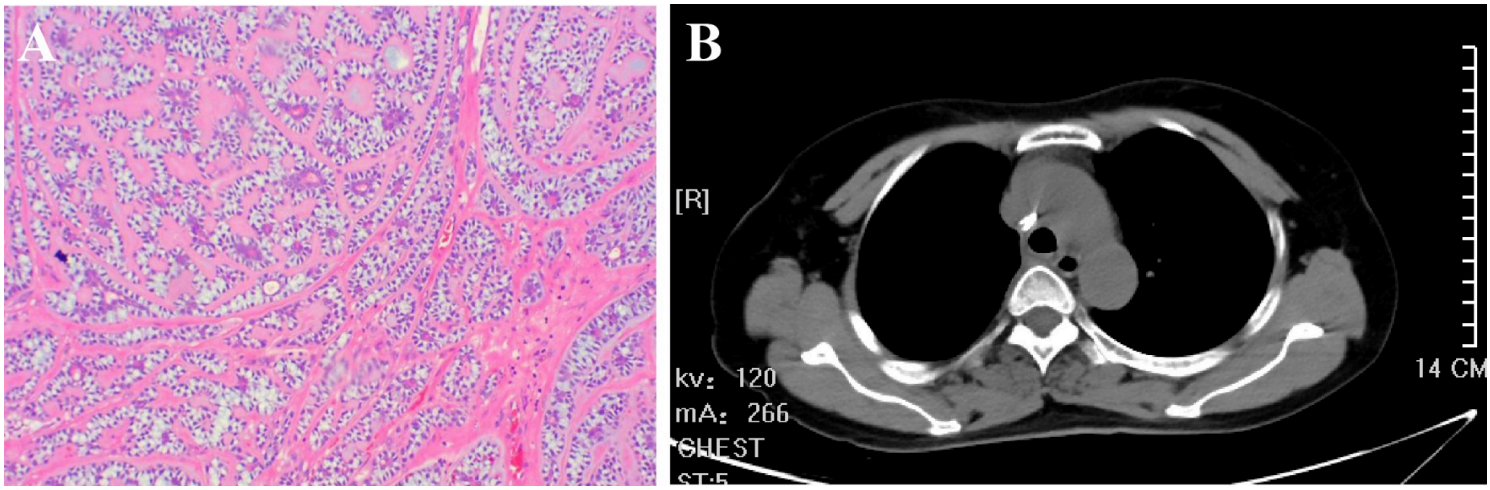

Figure 4

Histopathology and postoperative airway assessment. (A) Hematoxylin and eosin-stained section showing the biphasic epithelial-myoepithelial morphology of tracheal pleomorphic adenoma. (B) One-

month postoperative chest computed tomography showing a patent reconstructed distal trachea without apparent stenosis.