Research Square

Preprints are preliminary reports that have not undergone peer review.
They should not be considered conclusive, used to inform clinical practice,
or referenced by the media as validated information.

Ghost cell odontogenic carcinoma: an institutional reassessment over four decades with an integrated analysis of cases in Chinese patients

Pan Liu
Wuhan University
Xiao-long Guo
Wuhan University
Zhe Shao
Wuhan University
Xin-ming Chen
Wuhan University
Shao-dong Yang
ysd170811@whu.edu.cn

Wuhan University

Research Article

Keywords: ghost cell odontogenic carcinoma, calcifying odontogenic cyst, dentinogenic ghost cell tumor, adenoid ameloblastoma, odontogenic tumor, jaw

Posted Date: November 25th, 2026

DOI: https://doi.org/10.21203/rs.3.rs-11133564/v1

License: This work is licensed under a Creative Commons Attribution 4.0 International License. Read Full License

Additional Declarations: No competing interests reported.

Abstract

Backgroud:

Ghost cell odontogenic carcinoma (GCOC) is an exceedingly rare malignant odontogenic tumor. Due to its rarity and overlap with other odontogenic lesions, accurate diagnosis remains challenging. Moreover, the reliability of existing data is compromised by inconsistent diagnostic criteria across previous reports and a suggested but unverified Asian predilection. This study reassesses our institutional cases of GCOC and integrates vetted Chinese patient cases to refine the clinicopathological characterization of GCOC.

Methods

Nine cases previously diagnosed as GCOC at our institution (1983–2025) were re-evaluated and reclassified according to the 2022 WHO criteria. We also performed a comprehensive search of English and Chinese literature for additional Chinese GCOC cases. Duplicates and diagnostically unconvincing cases were excluded, and clinicopathological and follow-up data were extracted and analyzed.

Results

Only 4 of 9 institutional cases (44.4%) were confirmed as GCOC (55.6% reclassification). After exclusions, 15 literature-reported and 4 institutional cases formed a cohort of 19 patients (mean age, 44.4 years; male-to-female ratio, 5.3:1; maxillary involvement, 78.9%). Of these, 42.1% (8/19) were de novo lesions, 47.4% (9/19) arose from benign precursors, and 10.5% (2/19) were of uncertain origin. With radical resection, the recurrence rate was 18.8% (3/16); no distant metastases were documented. The crude overall survival, the proportion of patients alive at last follow-up with available follow-up data, was 88.2% (15/17).

Conclusion

In our institutional cohort, GCOC has been significantly overdiagnosed historically, with a 55.6% reclassification rate when the 2022 WHO criteria were applied. The apparent Asian predilection may reflect publication bias and historical overdiagnosis. The essential diagnostic requirement of “prominent ghost cells” may be overly restrictive, particularly for cases arising from benign precursors with sparse ghost cell differentiation. We propose modifying the criteria to “prominent ghost cells and/or definitive histopathological evidence of a benign precursor lesion” in the context of unequivocal cytological malignancy. Radical en bloc resection with negative margins was associated with excellent long-term disease control in our cohort, with all 4 confirmed institutional cases remaining recurrence-free for 6 to 19 years. Prospective multi-institutional studies using standardized criteria are needed to define the true epidemiology and optimal management of this rare malignancy.

Trail registration:

2023B35

Background

The family of odontogenic ghost cell lesions comprises the calcifying odontogenic cyst (COC), dentinogenic ghost cell tumor (DGCT), and ghost cell odontogenic carcinoma (GCOC) [1]. Currently, COC is classified as a developmental cyst, whereas DGCT and GCOC are classified as benign and malignant neoplasms, respectively [1]. The first well-documented case of GCOC, reported by Ikemura et al., 1985 [2], described the malignant transformation of COC. The 2005 WHO classification formally adopted the term GCOC, which has since gained universal acceptance [3].

GCOC is exceptionally rare, with fewer than 70 cases to date reported in the English literature, exclusively as case reports or small series [4, 5]. Its incidence across diverse populations ranges from 0% to 0.49% [6–10]. Currently, our understanding of the clinicopathological features, biological behavior, and optimal management of GCOC remains very limited. Several factors account for this knowledge gap. First, GCOC shares substantial histological overlap with other odontogenic entities, particularly DGCT, adenoid ameloblastoma (AA), and odontogenic carcinoma with dentinoid (OCD), rendering accurate diagnosis challenging [1, 11–13]. Second, the published literature on GCOC is itself problematic: when reassessed, some reported cases fail to meet the current WHO diagnostic criteria [14–17], and various reviews frequently cite conflicting case series, reflecting divergent opinions on which reported cases are genuine [4, 5, 17–20].

A further point of contention is the purported Asian predilection, a notion repeatedly cited in the literature [5, 17–20] and reflected in the WHO classification's epidemiological description [1, 3]. In support of this observation, two large Chinese series reported GCOC incidence rates of 0.39% and 0.49%, respectively [9, 10], and approximately one-third of all previously reported cases were from China [4], including 7 cases from our institution [15, 21, 22]. However, whether this reflects a true ethnic susceptibility or is confounded by diagnostic and publication bias remains to be clarified.

To address these gaps, the present study retrospectively re-evaluated all GCOC cases diagnosed at our institution over a 42-year period. Additionally, we performed an integrated analysis of cases involving Chinese patients retrieved from both English- and Chinese-language publications, aiming to refine the clinicopathological characterization of GCOC and provide updated baseline evidence for its accurate diagnosis and clinical management.

Materials and Methods

1. Re-evaluation of Institutional GCOC cases

Nine cases initially recorded as GCOC between January 1983 and December 2025 were retrieved from the archives of the Department of Oral Pathology, School and Hospital of Stomatology, Wuhan University. Of these, 7 cases had been previously reported in three publications [15, 21, 22]. Hematoxylin-eosin (H&E)-stained slides from all selected cases were re-evaluated by two experienced oral and maxillofacial pathologists (Yang S and Chen X). For lesions with recurrence, all available slides of the initial and recurrent specimens were reviewed and compared. Due to the significant time elapsed since the original diagnoses (spanning 42 years and encompassing four intervening WHO classification editions), the slides were re-evaluated strictly according to the 2022 WHO diagnostic criteria. For GCOC, these criteria require the presence of ameloblastoma-like epithelium, prominent ghost cells, and cytological evidence of malignancy [1]. Tumor necrosis and a high Ki-67 index (≥ 30%) support the diagnosis of GCOC, but they are not essential criteria [1]. Clinical data, including patient age, sex, lesion location, duration, clinical features, radiographic findings, and treatment, were collected from surgical and pathology records. Follow-up information was collected through medical records and telephone interviews. This study was approved by the Institutional Review Board of School and Hospital of Stomatology, Wuhan University (grant number 2023B35). The requirement for informed consent was waived due to the archival nature of the specimens. All experiments involving human samples or data were performed in accordance with the Declaration of Helsinki and relevant guidelines and regulations.

2. Review of Literature

2.1 Review of English-language Literature

Several reviews addressing GCOC have been published [4, 5, 17–19], the most recent in December 2025 [5]. We first identified and cross-checked cases from these publications. To ensure comprehensiveness, we subsequently performed a comprehensive literature search of PubMed/Medline, ScienceDirect, and Web of Science databases up to December 31, 2025, using the following keywords: "ghost cell odontogenic carcinoma", "calcifying odontogenic cyst with malignant transformation", "calcifying cystic odontogenic tumor with malignant transformation", and "dentinogenic ghost cell tumor with malignant transformation". This search identified only 1 additional candidate case (published online in November 2025, with the formal volume appearing in 2026) [23]. All reported cases involving Chinese patients were collected, with the exception of those from our own institution.

2.2 Review of Chinese-language Literature

A parallel search using the same set of keywords was conducted across three major Chinese electronic databases: the China National Knowledge Infrastructure (CNKI), the Wanfang Database, and the China Medical Journal Full-text Database, from their inception to December 31, 2025.

2.3 Inclusion and Exclusion Criteria

The primary inclusion criterion was the fulfillment of the diagnostic criteria for GCOC, as defined earlier, based on available photomicrographs and pathological descriptions. Cases that did not meet these criteria were excluded, even if they had been included in previous reviews. Publications available only in abstract form were also excluded. Duplicate cases, including those reported in both Chinese and English, were identified and counted only once. All retrieved articles were independently screened by two authors (Yang S and Chen X) based on the predefined inclusion and exclusion criteria. Discrepancies were resolved by consensus.

Results

1. Institutional GCOC cases

Of the 9 retrieved cases, 4 were confirmed as GCOC after histopathological re-evaluation. The remaining 5 cases were excluded from the GCOC diagnosis, comprising the 4 cases reported by Cheng et al., [21] and 1 case reported by Jia et al., [15]. After histopathological re-evaluation, these 5 cases were reclassified as AA (n = 3), DGCT (n = 1) (case 2 from Jia et al., [15], illustrated in Figs. 3A–3C of reference 24), and OCD (n = 1) (case 4 from Cheng et al., [21], illustrated in supplementary Figure S1 of reference 13). Notably, the 4 cases originally reported by Cheng et al., [21] were diagnosed in the early 2000s, when the diagnostic framework for GCOC was still evolving; their reclassification reflects the application of current WHO criteria rather than simply diagnostic error. The clinicopathological features of the 4 confirmed cases are briefly described below.

Case 1

(previously unreported): A female patient in her 30s presented with a 6-month history of right maxillary swelling, having undergone two prior curettage procedures at an external hospital with a pathology report suggestive of COC. A right partial maxillectomy revealed a 3 × 2 × 2 cm solid and partially cystic mass with bone destruction. Histologically, the tumor showed multicystic spaces lined by hyperchromatic basaloid cells within a fibrous stroma, with scattered ghost cells (Fig. 1A-C). Focally, benign odontogenic epithelial nests were present, associated with ghost cell clusters, dentinoid material, and occasional duct-like structures (Fig. 1D); these features were consistent with either DGCT or COC with ameloblastoma-like proliferations. Immunohistochemistry demonstrated diffuse nuclear/cytoplasmic β-catenin positivity in both benign and malignant components; the Ki-67 proliferation index was approximately 33% in malignant areas versus 1% in benign foci (Fig. 1E and 1F). No tumor recurrence was observed at 19 years of follow-up, although the patient later required removal of a titanium mesh (implant exposure/infection at 15 years) and curettage for osteomyelitis (at 17 years).

Case 2

(previously reported but inadequately documented [15]; clinical details were revised based on original records): A male patient in his 40s with a 30-year history of maxillary swelling and one prior surgery presented with recent epistaxis and a painful mucosal ulcer. Examination revealed right facial swelling with bony prominence in the infraorbital region and nasal ala; intraorally, marked expansion was observed on the right side, extending from the distal right lateral incisor to the maxillary tuberosity. A cone beam computed tomography scan showed a 6.2 × 5.6 × 5.2 cm unilocular, well-defined radiolucency extending across the midline from the left maxillary central incisor to the right maxillary tuberosity, with thinning/perforation of multiple bony walls, a patchy radiopaque focus, root resorption of the central/lateral incisors, and displacement of the canine to the orbital floor (Fig. 2). A right partial maxillectomy revealed two components: a cystic COC area and a solid GCOC component with focal transitional zones (Fig. 3A-C). The malignant component exhibited marked pleomorphism, frequent mitoses, and extensive necrosis (Fig. 3D). Immunohistochemistry showed nuclear/cytoplasmic β-catenin positivity in both components (Fig. 3E and 3F). No recurrence was observed at 12 years. The patient reportedly received adjuvant chemoradiotherapy at an outside hospital 1 year postoperatively, although specific details are unavailable.

Case 3

(previously reported and well-documented [22]): A male patient in his 30s presented with a rapidly growing right maxillary mass of 50 days' duration. Histopathological examination of the right subtotal maxillectomy specimen revealed prominent ghost cells, marked cellular pleomorphism, and frequent mitotic figures (Fig. 4A); no benign elements were identified. Immunohistochemistry showed diffuse nuclear/cytoplasmic β-catenin positivity (Fig. 4B). The patient remained recurrence-free for 6 years before being lost to follow-up (updated from the initial report).

Case 4

(previously unreported): A male patient in his 30s underwent enucleation of a left maxillary tumor at an external hospital; pathological consultation at our institution confirmed GCOC. The available preoperative computed tomography (from the external hospital, before enucleation) showed a 2.3 × 2.1 cm unicystic lesion with irregular, spiculated borders and punctate calcifications (Fig. 4C and 4D). Histopathology revealed islands of odontogenic epithelium with prominent ghost cell keratinization, occasional calcification, and large polygonal tumor cells with clear/pale eosinophilic cytoplasm, atypical nuclei, and scattered mitoses (Fig. 5A-D). Immunohistochemistry showed nuclear/cytoplasmic β-catenin positivity (Fig. 5E) and a Ki-67 index exceeding 50% (Fig. 5F). A left subtotal maxillectomy with partial right maxillectomy was performed (no residual tumor found). The patient showed no recurrence at 10 years post-surgery.

2. Cases Identified from Literature

Our initial literature search identified 13 cases of GCOC in Chinese patients from the English-language literature [16, 23, 25–32] and 8 cases from the Chinese-language literature [33–40], all of which originated from institutions other than our own. Two of these were identified as duplicate publications: the case reported by Zhu et al., [28] in 2012 was a duplicate of the case reported by Zhu et al., [37] in 2010; and the case reported by Zhang et al., [23] (published online in 2025, with the formal volume appearing in 2026) was a duplicate of the case reported by Zheng et al., [40] in 2022.

The following exclusions were then applied: 1) the case reported by Qin et al., [16] from the English-language literature was excluded due to unconvincing histomorphological description and photographic evidence; 2) Zhang et al., [23] (and its duplicate Chinese counterpart, Zheng et al., [40]) were excluded for the same reason; and 3) two additional cases from the Chinese-language literature were excluded for the same reason [38, 39].

In total, 21 candidate cases were identified. After excluding duplicate publications (n = 2), 19 unique cases remained. After applying histopathological exclusion criteria (n = 4), 15 independent cases met our inclusion criteria. These 15 literature-derived cases were then combined with the 4 institutionally confirmed cases (2 previously reported and 2 newly identified) to form a final cohort of 19 cases for comprehensive analysis.

The demographic and clinicopathological features of the 19 patients are presented in Table 1. The cohort comprised 16 males and 3 females, with a male-to-female ratio of approximately 5.3:1. The patients' ages ranged from 19 to 72 years, with a median age of 43 years (mean, 44.4 years). The maxilla was the predominant site of involvement, accounting for 15 cases (78.9%), while 4 cases (21.1%) occurred in the mandible. Clinical presentation was characterized by swelling or mass formation, with pain, paresthesia, or rapid growth noted in 11 cases. Radiographically, among the 18 cases with available imaging data, mixed radiolucent-radiopaque lesions accounted for 44.4% (8/18), whereas purely radiolucent lesions were more common, seen in 55.6% (10/18). Ill-defined borders were observed in 12 of these 18 cases (66.7%), while well-defined margins were noted in only 3 cases (16.7%); the remaining 3 cases (16.7%) lacked explicit description of border status in their original reports. One additional case had no imaging data available. Bone destruction was observed in the majority of cases, often accompanied by cortical perforation and root resorption. Regarding the origin of GCOC, definite de novo origin was identified in 42.1% (8/19) of cases. Secondary origin was confirmed in 47.4% (9/19) of cases: 6 arising from COC, 1 from DGCT, and 2 from a benign ghost cell precursor that could not be further subtyped as COC or DGCT. In 10.5% (2/19) of cases, the origin was suspected but unconfirmed histologically: 1 had a history of two prior maxillary cystic lesions suggesting possible COC [33], and the other had a prior history of ameloblastoma [29]; neither case showed residual benign components in the GCOC specimen.

Table 1
Summary of cases of ghost cell odontogenic carcinoma reported in Chinese patients

Case	Author/year	Age (y)/ sex	Site	Chief Complaint (Duration)	Size (cm) #	Radiographic findings	Precursor Lesion/ Origin	Treatment	Follo outc
1	Lu et al., 1999	20–30/M	Maxilla	Recurrent lesion (initial lesion 4 years prior)	7 × 5 × 3	An ill-defined multilocular, radiolucent and radiopaque lesion	COC	Hemimaxillectomy	Recu after hemi rese to fo
2	Lu et al., 1999	30–40/F	Maxilla	Right-sided facial swelling (11 years)	NA	Large, unicystic lesion with irregular borders	COC	Enucleation, then planned hemimaxillectomy one month later	NED post- hemi
3	Lu et al., 1999	10-20M	Mandible	Swelling (6 years), pain and rapid growth (1 month)	10 × 10 × 5	Ill-defined mixed radiolucency with radiopaque foci	COC	Subtotal mandibulectomy	Recu local exte post- mand
4	Lu et al., 1999	30–40/M	Mandible	Mass with paresthesia of lower lip (2 months)	NA	Expansile radiolucent lesion	De novo	Enucleation, then hemimandibulectomy	One 2 yea years treat recu
5	Li & Yu, 2003	40–50/M	Maxilla	Previous surgery for maxillary lesion (10 years prior), surgical-site swelling (4 years), pain and rapid tumor growth (past 3 months)	8 × 7 × 5	Ill-defined multilocular lesion with a mixed radiolucent and radiopaque image	COC	Partial maxillectomy	NED post- maxi
6	Li & Gao, 2009	70–80/M	Maxilla	Recurrent mass with moderate tenderness (third recurrence; two prior DGCT recurrences)	NA	A poorly demarcated osteolytic radiolucency	DGCT	Conservative surgery, then segmental resection with 1cm safety margin	Recu and a years mont surg
7	Zhong et al., 2009	30–40/M	Maxilla	Left facial swelling (5 years) with 2 prior enucleations for left maxillary cystic lesions	6 × 5 × 4	CT: linear soft tissue shadow on inferolateral wall of left maxillary sinus	Suspected COC (inferred from history; unconfirmed histologically)	Maxillary and zygomatic bone extended resection + skin graft	NA
8	Zhu et al., 2012	50–60/M	Maxilla	Painful, rapidly growing mass in the previous maxillary surgical site (history of COC curettage 1 year prior)	3 × 3 × 2.5	Nonopaque lesion with clear borders; root apex resorption	COC	Subtotal resection of right maxilla	NED post- rese maxi
9	Du et al., 2017	40–50/M	Mandible (crossing midline)	Swelling with gradual and slow growth (21 years prior), with history of ameloblastoma curettage 7 years prior	Maximum dimension > 8 cm	An ill-defined multilocular mixed radiolucency with radiopaque foci, root resorption	Ameloblastoma (history only; unconfirmed histologically)	Wide surgical resection + free vascularized fibular flap reconstruction	NED post- rese
10	Ye et al., 2021	60–70/M	Maxilla	Swelling and pain in the left posterior maxillary	6 × 5 × 4	Ill-defined solid mass in left posterior maxilla, with buccal bone destruction,	De novo	Left subtotal maxillectomy + left neck dissection + free vascularized	NED post- maxi

Abbreviations: NA = Not Available; NED = No Evidence of Disease; M = Male; F = Female; COC = Calcifying Odontogenic Cyst; GCOC = Ghost Cell Odontoge Carcinoma; CT = Computed Tomography;

CBCT = Cone Beam Computed Tomography.

Case	Author/year	Age (y)/ sex	Site	Chief Complaint (Duration)	Size (cm) #	Radiographic findings	Precursor Lesion/ Origin	Treatment	Follo outc
1	Lu et al., 1999	20–30/M	Maxilla	Recurrent lesion (initial lesion 4 years prior)	7 × 5 × 3	An ill-defined multilocular, radiolucent and radiopaque lesion	COC	Hemimaxillectomy	Recu after hemi rese to fo
2	Lu et al., 1999	30–40/F	Maxilla	Right-sided facial swelling (11 years)	NA	Large, unicystic lesion with irregular borders	COC	Enucleation, then planned hemimaxillectomy one month later	NED post- hemi
				region and mild tenderness on palatal mucosa (6 months), radiating pain (5 months)		protruding into nasal cavity and involving turbinates and maxillary sinus (CT)		fibular flap reconstruction + radiotherapy	
11	Pei et al., 2022	70–80/F	Maxilla	Right facial swelling (3 months)	3.8 × 4.4 × 3.9	Unilocular, ill-defined cystic-solid mass in right maxilla with heterogeneous density, punctate calcifications, and bone destruction, extending to right nasal cavity and maxillary sinus (CT)	De novo	Right maxillary tumor resection	NA
12	Xia et al., 2023	30–40/M	Maxilla	Right cheek trauma with incidental maxillary lesion, followed by massive nosebleed, pain in the right maxilla and visual loss due to recurrences	NA	Cystic lesion in right maxilla (Initial MRI); subsequent recurrences showed progressive involvement of bilateral nasal cavity, paranasal sinuses, nasopharynx, middle skull base, and cavernous sinuses.	De novo	Right maxillectomy + radiotherapy, then palliative resection, then Toripalimab + chemotherapy	Two recu achie remi Torip chem alive follo ongo
13	Zhang et al., 2024	50–60/M	Maxilla	Left maxillary mass (present for over two years)	6 × 6	Tumor encroaching alveolar process and maxillary sinus (CT)	De novo	Subtotal resection with negative margins	NED post- rese
14	Hu et al., 2024	50–60/M	Mandible	Painful feeling while eating in lower anterior teeth (2 months)	2.2 × 1.3 × 2.1	Soft tissue mass with bone destruction in median alveolar region (CT)	COC or DGCT	Partial resection of the mandible and the mass + bilateral cervical lymphadenectomy + vascularized free peroneal myocutaneous flap reconstruction	NED
15	Guo et al., 2024	50–60/M	Maxilla	Progressive left facial mass with pain (2 months)	NA	Large irregular soft tissue mass with bone destruction (MRI/CT)	De novo	Enucleation, then cranial base tumor resection + vascularized pedicled maxillary reconstruction	Recu mont tumo died half a (appr mont surg
16	Current Case 1	30–40/F	Maxilla	Swelling (6 months)	3 × 2 × 2	NA	COC or DGCT	Right partial maxillectomy	No re 19 ye right maxi
17	Current Case 2	40–50/M	Maxilla	Swelling (30 years), recent epistaxis and a painful mucosal ulcer	6.2 × 5.6 × 5.2	Unilocular, well-defined, quasi-circular radiolucency with bone expansion/perforation, patchy radiopaque	COC	Right partial maxillectomy + chemoradiotherapy	No re 12 ye right maxi

Abbreviations: NA = Not Available; NED = No Evidence of Disease; M = Male; F = Female; COC = Calcifying Odontogenic Cyst; GCOC = Ghost Cell Odontoge Carcinoma; CT = Computed Tomography;

CBCT = Cone Beam Computed Tomography.

Case	Author/year	Age (y)/ sex	Site	Chief Complaint (Duration)	Size (cm) #	Radiographic findings	Precursor Lesion/ Origin	Treatment	Follo outc
1	Lu et al., 1999	20–30/M	Maxilla	Recurrent lesion (initial lesion 4 years prior)	7 × 5 × 3	An ill-defined multilocular, radiolucent and radiopaque lesion	COC	Hemimaxillectomy	Recu after hemi rese to fo
2	Lu et al., 1999	30–40/F	Maxilla	Right-sided facial swelling (11 years)	NA	Large, unicystic lesion with irregular borders	COC	Enucleation, then planned hemimaxillectomy one month later	NED post- hemi
						focus, root resorption (CBCT)			
18	Current Case 3	30–40/M	Maxilla	Rapidly growing mass (50 days)	5 × 4 × 2.5	Ill-defined mixed radiolucent-radiopaque lesion on Waters' view	De novo	Right subtotal maxillectomy + secondary reconstruction with an obturator prosthesis	No re years subt maxi then follo
19	Current Case 4	30–40/M	Maxilla	N/A (enucleation done at external hospital 2 weeks prior)	2.3 × 2.1	Unicystic lesion with well-defined but irregular, spiculated borders and scattered punctate calcifications (CT)	De novo	Left subtotal maxillectomy + partial right maxillectomy	No re 10 ye subt maxi
Abbreviations: NA = Not Available; NED = No Evidence of Disease; M = Male; F = Female; COC = Calcifying Odontogenic Cyst; GCOC = Ghost Cell Odontoge Carcinoma; CT = Computed Tomography;									
CBCT = Cone Beam Computed Tomography.									

Surgical resection was the primary treatment for all cases. Among the 19 patients, 16 (84.2%) underwent radical resection (partial or subtotal maxillectomy/mandibulectomy) either as primary treatment or as planned early re-resection within 1 month after initial enucleation, while the remaining 3 patients initially received conservative surgery. All 3 patients who initially underwent conservative surgery subsequently experienced recurrence [25, 27, 36], whereas among the 16 patients who underwent radical resection, 3 developed recurrence, corresponding to a recurrence rate of 18.8% (3/16) [25, 30]. Adjuvant radiotherapy or chemotherapy was administered in 3 cases. Follow-up data were available for 17 patients, with a median follow-up period of 36 months (range: 3.5–336 months). The disease-related mortality rate was 11.8% (2/17), including 1 patient who died 24 months post-diagnosis [25] and 1 patient who died approximately 3.5 months after surgery [36]. Among the 15 patients with follow-up ≥ 12 months, 12 (80.0%) had no evidence of disease at last contact. No metastases were documented in any of the 17 patients with available follow-up data. The crude overall survival was 88.2% (15/17), representing the proportion of patients alive at last follow-up within this cohort.

Discussion

In the present study, histopathological re-evaluation according to the 2022 WHO Classification revealed far fewer confirmed GCOC cases (n = 4) than were historically diagnosed at our institution, with a reclassification rate of 55.6% (5 out of 9 cases), which were subsequently reclassified as AA (n = 3), DGCT (n = 1), and OCD (n = 1). This significant reduction highlights the historical overdiagnosis of GCOC and challenges the accuracy of its prior characterizations. Notably, our re-evaluation was based on stringent application of the 2022 WHO criteria, and cases that did not unequivocally meet these criteria were reclassified rather than retained as GCOC. Similarly, the published literature also includes reports of GCOC cases with insufficient histopathological evidence, which compromises the validity of these reports and, by extension, the reliability of previously published epidemiological data [14–17]. However, in the absence of original pathology slides, achieving a definitive diagnosis based solely on the often limited pathological descriptions and images in published reports is challenging, if not impossible.

The 2022 WHO criteria mandate “prominent ghost cells” as an essential diagnostic feature for GCOC [1]. While the diagnosis is straightforward when infiltrative growth and unequivocal cytological malignancy are present, as exemplified by our 4 confirmed cases, our data reveal a limitation in this requirement. Among the 4 institutionally confirmed cases, the 2 de novo GCOCs exhibited abundant ghost cells, whereas the 2 cases arising in association with histologically identifiable benign precursors (COC or DGCT) demonstrated only minimal ghost cell differentiation. Therefore, we propose a practical modification to the essential diagnostic criteria for GCOC. Specifically, we suggest modifying the requirement for ‘prominent ghost cells’ to ‘prominent ghost cells and/or definitive histopathological evidence of a benign precursor lesion (e.g., COC or DGCT)’ in the context of unequivocal cytological malignancy.

The principal differential diagnoses for GCOC include DGCT, AA, and OCD [1, 11–13]. In our cohort, the 5 cases excluded from GCOC diagnosis were reclassified into these three categories, underscoring the practical diagnostic challenges encountered in routine practice. All these entities share WNT/β-catenin pathway activation [1, 11–13], a molecular commonality that underlies their overlapping histomorphology; however, nuclear β-catenin immunopositivity alone lacks utility in distinguishing GCOC from its mimics. Diagnosing cases with intermediate morphology between DGCT and GCOC remains difficult due to poorly defined thresholds [1, 41, 42]. While GCOC generally exhibits a higher Ki-67 index than DGCT, reported values for DGCT vary widely (2% to 29%) [1], precluding a reliable diagnostic cutoff except in cases with uniformly high expression (e.g., ≥ 30%). In our cohort, 1 GCOC case exhibited a Ki-67 index exceeding 50%, illustrating its potential utility in extreme cases. Since its recognition as a distinct entity in the WHO classification, AA has sparked ongoing debate regarding its nosological relationship with DGCT, as they exhibit substantial overlap in clinical, histomorphological, and

molecular features [12, 43, 44]. Some authors have considered AA and DGCT to be within the same spectrum [43, 44]. In terms of differential diagnosis, the constellation of diagnostic features characteristic of AA, including duct-like structures, whorls/morules and cribriform architecture, rarely occurs in GCOC. More importantly, cytological evidence of malignancy is lacking in AA, although it can show aggressive clinical behavior and a high proliferative fraction [12].

It is worth noting that the diagnostic ambiguity is not necessarily binary (between the DGCT–AA spectrum and GCOC). Among our reclassified cases, some exhibited histological features that did not unequivocally fulfill either the essential criteria for GCOC or the classic description of DGCT. Such cases may represent a diagnostic gray zone, lesions showing increased mitotic activity or, at most, moderate pleomorphism without overt cytologic atypia, perineural invasion, necrosis, or distant metastases. This scenario parallels the long-recognized diagnostic challenges in ameloblastic neoplasms, where the term atypical ameloblastoma has been proposed for lesions that fall short of the overtly malignant features of ameloblastic carcinoma but exhibit increased proliferative activity or limited pleomorphism [45, 46]. Analogously, a subset of ghost cell lesions previously reported as GCOC, including some cases from our institution and from the literature, might be better conceptualized as atypical DGCT or DGCT with atypical features, rather than unequivocal GCOC. The existence of such borderline lesions underscores the inherent limitations of rigid diagnostic criteria in capturing the full biological spectrum of ghost cell lesions.

According to the 2022 WHO classification, GCOC shows a maxilla-to-mandible ratio of approximately 2:1, a male-to-female ratio of 3.2:1, and a peak incidence in patients aged 30 to 60 years (range: 10–89 years) [1]. In our review of Chinese GCOC cases, we found a higher maxillary predominance (78.9%, approximate ratio 3.8:1) and a higher male-to-female ratio (5.3:1), with the mean age (44.4 years) falling within the peak age range described by the WHO. The higher maxillary and male ratios observed in our cohort, compared with the WHO figures, may be partly explained by the exclusion of AA and DGCT. Both tumors exhibit a more balanced distribution or mandibular predilection [1] (AA: male-to-female ratio 1.3:1; DGCT: approximately 2:1, compared with 3.2:1 for GCOC), which would otherwise have diluted the maxillary and male predominance in the GCOC group. Radiographically, most lesions presented with ill-defined borders, although well-defined radiolucencies were also observed in a small subset of cases, particularly in those with a prominent cystic component or arising from pre-existing COCs. Internal calcifications were noted in 44.4% (8/18) of cases in our review of Chinese patients, which is comparable to the approximately 50% described in the WHO classification [1]. These overlapping and variable imaging features may add to the preoperative diagnostic challenge, particularly when the clinical and radiological findings do not clearly suggest malignancy. This diagnostic difficulty underscores the importance of histopathological evaluation for definitive diagnosis.

The histogenesis of GCOC remains debated, with proposed pathways including de novo origin, malignant transformation of COC/DGCT, and origin from other odontogenic tumors (e.g., ameloblastoma, calcifying epithelial odontogenic tumor, adenomatoid odontogenic tumor) [5, 17, 21]. The WHO classification does not currently recognize malignant transformation from these tumors as a valid pathway [1]. This interpretation is corroborated by our institutional review: (1) The sole case initially interpreted as arising from a calcifying epithelial odontogenic tumor was reclassified as OCD [13, 21]; (2) Cases reportedly originating from ameloblastoma and/or demonstrating duct-like structures were reclassified as AA [15, 21, 24]. The proposed ameloblastoma and adenomatoid odontogenic tumor as precursors in the literature also lacks substantive evidence [5, 17, 29]. Diagnoses in such cases rely on temporal associations (prior history of ameloblastoma or adenomatoid odontogenic tumor) without primary slide re-review. A critical confounding factor is the morphological overlap between DGCT and ameloblastoma, particularly when ghost cells are sparse or overlooked. In the absence of ancillary studies, including nuclear β-catenin immunostaining/CTNNB1 mutation analysis (supporting DGCT) or BRAF V600E testing (supporting ameloblastoma), the true nature of the original lesion cannot be determined with certainty. Pending cases with unequivocal histological and molecular documentation, these alternative origins remain unproven, and the COC/DGCT pathway should be regarded as the only well-substantiated precursor route for GCOC.

Another issue that warrants discussion is the apparent Asian predilection of GCOC, which has been repeatedly cited in the literature since the early 2000s [3, 5, 17–20]. While early Chinese series reported higher rates (0.39%–0.49%) [9, 10], more recent cohorts in Japan and India reported 0% [7, 8]. In the recent review by Almadan et al., [4], which included 65 reported GCOC cases, approximately half occurred in Asian patients, with China alone contributing approximately 33% of historical cases. This disproportionate contribution from a single country strongly suggests publication bias, reflecting the concentration of specialized oral pathology centers with large archival collections and high academic output. The institutional concentration of reported cases further supports this view. In our literature search, after excluding duplicate publications from 21 candidate cases, we identified 19 reported cases from the English and Chinese literature, prior to histopathological exclusion. Of these, 6 originated from West China Hospital of Stomatology, Sichuan University [25, 28, 29], and 2 from Peking University School and Hospital of Stomatology [26, 27]. When combined with 7 previously reported cases from our own institution [15, 21, 22], the total number of initially retrieved cases from Chinese sources reached 26. Notably, the three major centers contributed 15 of these 26 cases (57.7%). However, only 3 of these 15 cases were published after 2010 [15, 29]. This temporal pattern-most cases reported in the 1990s and 2000s, with a marked decline thereafter-suggests that the historical abundance of Chinese GCOC reports may partly reflect publication enthusiasm during a specific era rather than ongoing higher incidence. Additionally, our 55.6% institutional reclassification rate, though from a single institution, underscores the potential magnitude of historical misdiagnosis and raises concern that similar patterns elsewhere may have contributed to the perceived Asian predilection in the broader literature. Collectively, the available evidence does not support a genuine Asian ethnic predisposition; rather, the perceived predilection reflects publication bias, institutional concentration, and, most critically, systematic overdiagnosis prior to the 2022 WHO classification. Ultimately, definitive clarification of GCOC epidemiology would require future prospective studies using standardized, contemporary diagnostic criteria across diverse populations.

Surgical management remains the cornerstone of treatment for GCOC. Our institutional experience, supported by the literature review, strongly suggests that radical resection with negative margins is critical for long-term disease control. In our institutional case series, all 4 patients treated with en bloc resection via partial or subtotal maxillectomy remained recurrence-free during extended follow-up periods of 19, 12, 10, and 6 years, respectively. In our pooled cohort, all 3 patients who initially underwent conservative surgery subsequently experienced recurrence [25, 27, 36], whereas among the 16 patients who underwent upfront radical resection, 3 developed recurrence during follow-up [25, 30]. This contrast underscores the inadequacy of conservative surgery for this malignancy and highlights the importance of achieving clear surgical margins from the outset. The disparity between the two groups is likely compounded by

diagnostic uncertainty at initial presentation: cases that underwent enucleation were often not recognized as GCOC preoperatively, whereas those treated with upfront radical resection were diagnosed as malignancies from the outset. Of note, the recurrence rate in the radical resection group (18.8%, 3/16) is substantially lower than the 34–63% reported in earlier reviews [1, 5, 17–19]; however, these historical figures encompassed heterogeneous treatment modalities and should not be directly compared with outcomes from a uniformly resected cohort.

The role of adjuvant therapy remains ill-defined. While radiotherapy and chemotherapy have been administered in advanced or recurrent settings, standardized protocols are lacking. Notably, the emergence of immunotherapy (e.g., Toripalimab) as a salvage therapy for unresectable cases indicates a promising new avenue for management [30]. Despite the aggressive histological features, the prognosis for GCOC appears relatively favorable when treated aggressively at an early stage, with a crude overall survival of 88.2% (15/17) in our pooled Chinese cohort (calculated as the proportion of patients alive at last follow-up). However, this estimate is based on a small sample and variable follow-up durations, and should be interpreted with caution. In addition, the fatal outcomes observed in a subset of cases, including 1 patient who died of local extension within 3.5 months of surgery, underscore the potential for highly aggressive biological behavior in a minority of tumors. Notably, no distant metastases were documented in our cohort. Previous reviews have reported a metastasis rate of approximately 14.6% [5, 17]; however, the small sample size and relatively short follow-up in our cohort preclude direct comparison with historical data. Given the unpredictable clinical course and the possibility of late recurrence, rigorous long-term surveillance is strongly recommended for all patients [5, 6, 34, 36].

A recent review by Parks et al., [5] reported a higher recurrence rate for precursor-associated GCOCs (64%) than for de novo cases (26%) based on literature data, although their own institutional cases showed the opposite pattern. In our pooled Chinese cohort, recurrence occurred in 3 of the 9 histologically confirmed precursor-associated cases (33.3%), whereas 3 of 8 de novo cases (37.5%) recurred. This finding does not support the notion that precursor-associated GCOCs are inherently more aggressive. The modest difference observed in our cohort, together with the conflicting patterns reported in the literature, underscores the need for larger, rigorously defined cohorts to clarify the prognostic significance of precursor lesions in GCOC.

This study has several limitations. First, the institutional cohort of confirmed GCOC cases is small (n = 4), limiting the statistical power of our observations. Second, the retrospective nature of the study and the long time span (1983–2025) resulted in incomplete clinical and radiological data for some cases. Third, while we applied strict inclusion criteria to literature-derived cases, the lack of access to original pathology slides precluded definitive histopathological re-evaluation, and our assessment relied on published photomicrographs and descriptions. Fourth, follow-up durations varied widely (range: 3.5–336 months), and some patients had relatively short follow-up; this heterogeneity may have influenced the survival estimates and limits the comparability of long-term outcomes.

Conclusion

This 42-year institutional re-evaluation demonstrates that GCOC has been significantly overdiagnosed historically, with a 55.6% reclassification rate upon application of the 2022 WHO criteria. The essential diagnostic requirement of “prominent ghost cells” may be overly restrictive, particularly for GCOCs arising from benign precursors, where ghost cell differentiation may be sparse. We therefore propose a practical modification to the WHO diagnostic framework: “prominent ghost cells and/or definitive histopathological evidence of a benign precursor lesion (e.g., COC or DGCT)” in the context of unequivocal cytological malignancy. Radical en bloc resection with negative margins was associated with excellent long-term disease control in our cohort, with all 4 confirmed cases remaining recurrence-free for 6 to 19 years. Future prospective multi-institutional studies employing standardized contemporary criteria are needed to define the true epidemiology and optimal management of this rare malignancy.

Abbreviations

GCOC
Ghost cell odontogenic carcinoma
COC
calcifying odontogenic cyst
DGCT
dentinogenic ghost cell tumor
AA
adenoid ameloblastoma
OCD
odontogenic carcinoma with dentinoid

Declarations

Ethics approval and consent to participate

This study was approved by the Institutional Review Board of School and Hospital of Stomatology, Wuhan University (grant number 2023B35). The requirement for informed consent was waived due to the archival nature of the specimens. All experiments involving human samples or data were performed in accordance with the Declaration of Helsinki and relevant guidelines and regulations.

Consent for publication

Not applicable.

Competing interest:

The authors declare no potential conflicts of interest.

Funding

None.

Author Contribution

Shaodong Yang contributed to the study design and revised the manuscript and supervised the work. Pan Liu and Xiaolong Guo contributed to the data acquisition, analysis and interpretation, and wrote the manuscript draft. Zhe Shao and Xinming Chen contributed to the study design, the interpretation of the results.

Acknowledgements

Not applicable.

Data Availability

The data that support the findings of this study are not openly available due to patient privacy restrictions. Anonymized datasets extracted from archived clinical medical records are available from the corresponding author upon reasonable request.

References

1. WHO Classification of Tumours Editorial Board. Head and neck tumours. Lyon (France). International Agency for Research on Cancer; 2022.
2. Ikemura K, Horie A, Tashiro H, Nandate M. Simultaneous occurrence of a calcifying odontogenic cyst and its malignant transformation. Cancer. 1985;56(12):2861–4.
3. Sciubba JJ, Eversole LR, Slootweg PJ. Odontogenic tumors. In: Barnes L, Eveson JW, Reichart P, Sidransky D, editors. Pathology and genetics of head and neck tumours. World Health Organization Classification of Tumours. Lyon: IARC; 2005. pp. 287–95.
4. Almadan NM, Alghamdi D, AlOrf M, Alali H, Mohajrye M. Ghost Cell Odontogenic Carcinoma of the Anterior Maxilla with ARID1A Mutation: A Case Report and Literature Review. Head Neck Pathol. 2025;19:46.
5. Parks D, Zhou NJ, Vazquez DA, Fisher M, Budhathoki S, Chen J, et al. Ghost Cell Odontogenic Carcinoma: Case Series and Literature Review. Head Neck Pathol. 2025;19(1):133.
6. Rees V, Klare M, Samaniego V, Leiva F, Jara R, Martínez Rondanelli B, et al. Epidemiological Features of 4777 Cysts and Odontogenic Tumors Based on the 2022 WHO Classification. Oral Dis. 2025;31(2):532–40.
7. Kokubun K, Yamamoto K, Nakajima K, Akashi Y, Chujo T, Takano M, et al. Frequency of Odontogenic Tumors: A Single Center Study of 1089 Cases in Japan and Literature Review. Head Neck Pathol. 2022;16(2):494–502.
8. Asnani P, Ali S, Odedra S, Pillai J, Jayasheel N, Jadeja R. A comprehensive analysis of odontogenic tumors according to recent WHO (2022) classification: An institution-based retrospective study. J Oral Maxillofac Pathol. 2024;28(4):576–82.
9. Jing W, Xuan M, Lin Y, Wu L, Liu L, Zheng X, et al. Odontogenic tumours: a retrospective study of 1642 cases in a Chinese population. Int J Oral Maxillofac Surg. 2007;36(1):20–5.
10. Luo HY, Li TJ. Odontogenic tumors: a study of 1309 cases in a Chinese population. Oral Oncol. 2009;45(8):706–11.
11. Oh KY. β-catenin nuclear translocation and WNT pathway mutations in ghost cell odontogenic carcinoma: A literature review and proposal of a new molecular-based classification WNT pathway-altered malignant odontogenic tumor. Oral Oncol. 2024;155:106907.
12. Odell EW, Gomes CC, Thavaraj S. The evolving molecular characterisation, histological criteria and nomenclature of adenoid ameloblastoma as a World Health Organisation tumour type. Histopathology. 2024;85(6):846–52.
13. Zeng M, Guo X, Chen X, Shao Z, Yang S. Odontogenic carcinoma with dentinoid: case report and literature review of a rare entity. BMC Oral Health. 2024;24:704.
14. Namana M, Majumdar S, Uppala D, Avv A, Rao AK. Ghost Cell Odontogenic Carcinoma Arising Denovo with Distant Metastasis: A Case Report and Review of Literature. J Clin Diagn Res. 2017;11(8):ZD01–3.
15. Jia MQ, Jia J, Wang L, Zou HX. Ghost cell odontogenic carcinoma of the jaws: Report of two cases and a literature review. World J Clin Cases. 2019;7(3):357–65.
16. Qin Y, Lu Y, Zheng L, Liu H. Ghost cell odontogenic carcinoma with suspected cholesterol granuloma of the maxillary sinus in a patient treated with combined modality therapy: A case report and the review of literature. Med (Baltim). 2018;97(7):e9816.

17. Al-Sammak A, Rezki O, Pennington M, Manosca F, Cuevas-Nunez M, Qaisi M, et al. Treatment challenges of persistent ghost cell odontogenic carcinoma: a case report and literature review. Oral Surg Oral Med Oral Pathol Oral Radiol. 2023;136(4):e123–32.
18. de Souza Vieira G, de Pinho Montovani P, Rozza-de-Menezes RE, Cunha KSG, Conde DC. Comparative Analysis Between Dentinogenic Ghost Cell Tumor and Ghost Cell Odontogenic Carcinoma: A Systematic Review. Head Neck Pathol. 2021;15(4):1265–83.
19. Vijayakumar G, Kamboj M, Narwal A, Devi A. Ghost cell odontogenic carcinoma of anterior mandible: A rare case report with review of literature. J Oral Maxillofac Pathol. 2021;25(Suppl 1):S99–108.
20. Ghita I, Nagai MY, Lubek JE, Stashek KM, Basile JR, Price JB, et al. Ghost Cell Odontogenic Carcinoma Arising in a Previous Calcifying Odontogenic Cyst: A Case Report and Review of Literature. Head Neck Pathol. 2022;16(3):828–35.
21. Cheng Y, Long X, Li X, Bian Z, Chen X, Yang X. Clinical and radiological features of odontogenic ghost cell carcinoma: review of the literature and report of four new cases. Dentomaxillofac Radiol. 2004;33(3):152–7.
22. Sun ZJ, Zhao YF, Zhang L, Li ZB, Chen XM, Zhang WF. Odontogenic ghost cell carcinoma in the maxilla: a case report and literature review. J Oral Maxillofac Surg. 2007;65(9):1820–4.
23. Zhang Y, Yang F, Ge M, Xu J. Application of 3D printing technology in precise resection and reconstruction of ghost cell odontogenic carcinoma: Report of a rare case. Asian J Surg. 2026;49(3):1593–5.
24. Yang S, Chen X, Wang Y, Guo X, Shao Z. Dentinogenic ghost cell tumor revisited from a single institution in China with focus on adenoid ameloblastoma-like features. J Stomatol Oral Maxillofac Surg. 2024;125(4S):101551.
25. Lu Y, Mock D, Takata T, Jordan RC. Odontogenic ghost cell carcinoma: report of four new cases and review of the literature. J Oral Pathol Med. 1999;28(7):323–9.
26. Li TJ, Yu SF. Clinicopathologic spectrum of the so-called calcifying odontogenic cysts: a study of 21 intraosseous cases with reconsideration of the terminology and classification. Am J Surg Pathol. 2003;27(3):372–84.
27. Li BB, Gao Y. Ghost cell odontogenic carcinoma transformed from a dentinogenic ghost cell tumor of maxilla after multiple recurrences. Oral Surg Oral Med Oral Pathol Oral Radiol Endod. 2009;107(5):691–5.
28. Zhu ZY, Chu ZG, Chen Y, Zhang WP, Lv D, Geng N, et al. Ghost cell odontogenic carcinoma arising from calcifying cystic odontogenic tumor: a case report. Korean J Pathol. 2012;46(5):478–82.
29. Du W, Aladimi MT, Zhang Z, Xuan M, Helal HH, Liu Z, et al. Mandibular ghost cell odontogenic carcinoma: a case report and review of literature. Int J Clin Exp Med. 2017;10:8325–30.
30. Xia Y, Song Z, Zhang X, Guan X, Tan G, Le Y, et al. Ghost cell odontogenic carcinoma: A rare case report and review of literature. Med (Baltim). 2023;102(38):e35225.
31. Zhang L, Xu Q, Feng Z. Comprehensive clinical, genome and transcriptomic analysis of primary ghost cell odontogenic carcinoma. Oral Oncol. 2024;148:106616.
32. Hu SS, Yang J, Zhang HF, Chen J, Li XN, Liu FJ, et al. Challenging pitfalls in frozen section pathology: a case of mandible ghost cell odontogenic carcinoma and the literature review. BMC Oral Health. 2024;24(1):450.
33. Zhong P, Han J, Wang H. Odontogenic ghost cell carcinoma: a case report. Hua Xi Kou Qiang Yi Xue Za Zhi. 2009;27(4):464–5. Chinese.
34. Ye WL, Ma GW, Sun B. Ghost cell odontogenic carcinoma: a case report. J Dalian Med Univ. 2021;43(1):92–4. Chinese.
35. Pei CS, Chen YM, Zheng XC, Wang JT. Ghost cell odontogenic carcinoma of the right maxilla: a case report. Chin J Med Imaging. 2022;30(11):1123–4. Chinese.
36. Guo XD, Su QJ, Wang HH, He QQ, Chen ZY, Ji PZ, et al. Ghost cell odontogenic carcinoma in the left maxilla: a case report and literature review. China J Oral Maxillofacial Surg. 2024;22(6):618–21. Chinese.
37. Zhu ZY, Chu ZG, Yang MZ, Lyu D, Yao LH, Chen Y. Ghost cell odontogenic carcinoma arising from calcifying cystic odontogenic tumor: a case report. Zhonghua Kou Qiang Yi Xue Za Zhi. 2010;45(2):119–20. Chinese.
38. Wang SL, Yang DH, Zhang M, Zhang YG, Jia WC, Zhu XZ. Odontogenic ghost cell carcinoma: a case report. Kou Qiang He Mian Wai Ke Za Zhi. 1994;29(3):184–6. Chinese.
39. Liu JZ, Zang GX, Ke XL, Sun HZ. Odontogenic ghost cell carcinoma: a case report. Journal of Oral Science Research. 2007;25(5):501. Chinese.
40. Zheng Y, Su LZ, Xu JJ, Tan J, Ge MH. Digital three-dimensional reconstruction surgery for ghost cell odontogenic carcinoma of the maxillary sinus: a case report. Chin Archives Otolaryngology-Head Neck Surg. 2022;29(8):538–9. Chinese.
41. Ohata Y, Kayamori K, Yukimori A, Sumikura K, Ohsako T, Harada H, et al. A lesion categorized between ghost cell odontogenic carcinoma and dentinogenic ghost cell tumor with CTNNB1 mutation. Pathol Int. 2018;68(5):307–12.
42. Conde DC, Vieira GS, Montovani PP, Beserra JPR, Ribeiro MCG, Rozza-de-Menezes RE, et al. Dentinogenic ghost cell tumor with focal atypical features suggesting ghost cell odontogenic carcinoma: Report of a challenging diagnosis. Oral Oncol. 2022;124:105524.
43. Oh KY, Hong SD, Yoon HJ. Adenoid Ameloblastoma Shares Clinical, Histologic, and Molecular Features With Dentinogenic Ghost Cell Tumor: The Histologic Spectrum of WNT Pathway-Altered Benign Odontogenic Tumors. Mod Pathol. 2023;36(3):100051.
44. Xue J, Zhang W, Zhang J, Bai J, Zhang A, Guo X, et al. Adenoid Ameloblastoma Shares Clinicopathologic, Immunohistochemical, and Molecular Features With Dentinogenic Ghost Cell Tumor: A Comparative Analysis. Am J Surg Pathol. 2023;47(11):1274–84.
45. Chaisuparat R, Sawangarun W, Scheper MA. A clinicopathological study of malignant odontogenic tumours. Histopathology. 2012;61(1):107–12.

46. Bilodeau EA, Seethala RR. Update on Odontogenic Tumors: Proceedings of the North American Head and Neck Pathology Society. Head Neck Pathol. 2019;13(3):457–465.

Figures

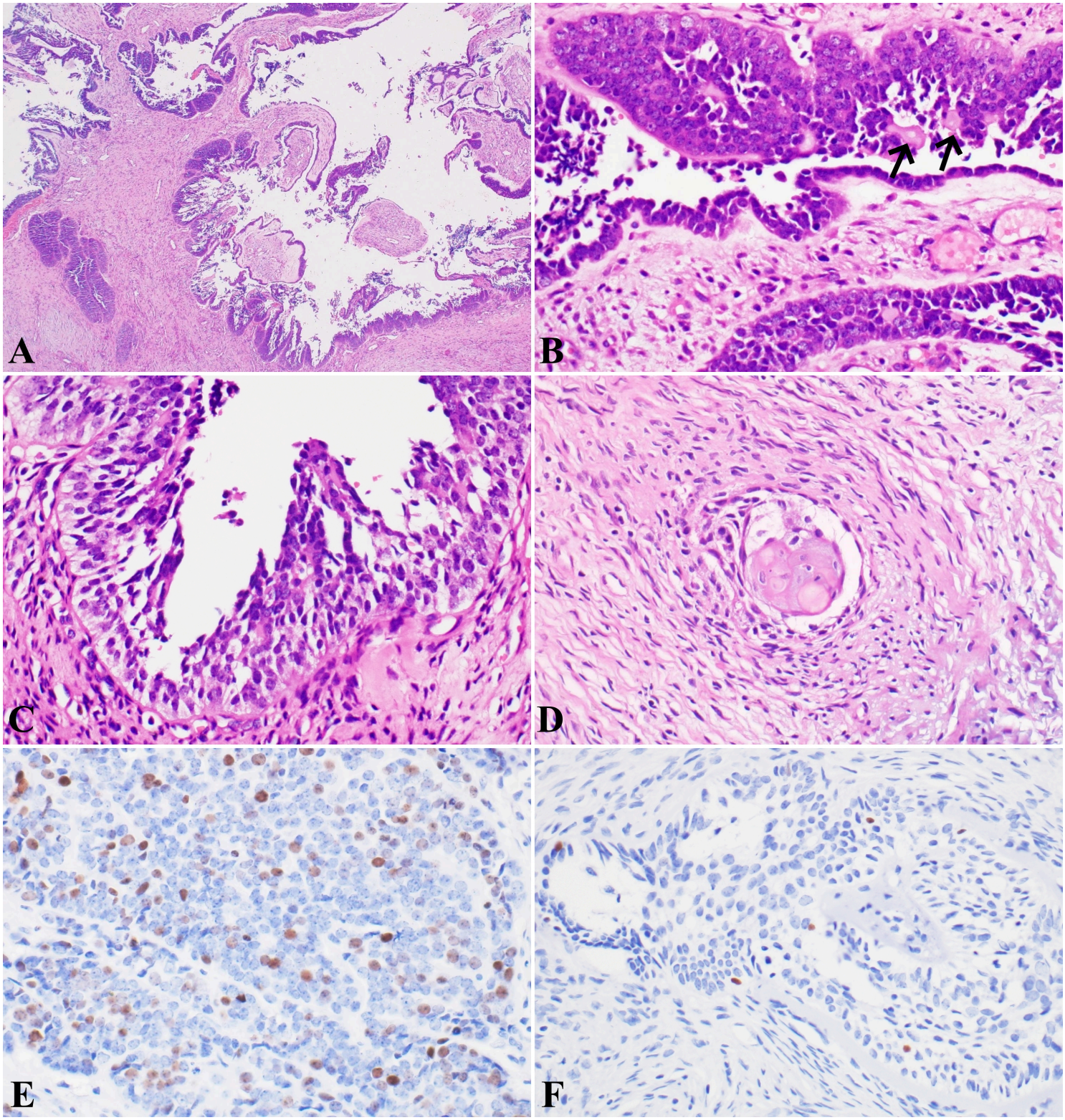

Figure 1

Histopathological and immunohistochemical features of case 1. A, Low-power view of the tumor showing multicystic architecture. B, Atypical tumor cells with scattered ghost cells (arrows). C, Islands of tumor cells with peripheral palisading and reverse nuclear polarity. D, A benign odontogenic epithelial nest with ghost cell keratinization within the fibrous stroma. E and F, The Ki-67 proliferative index was significantly higher in the malignant areas (E) than in the benign components (F).

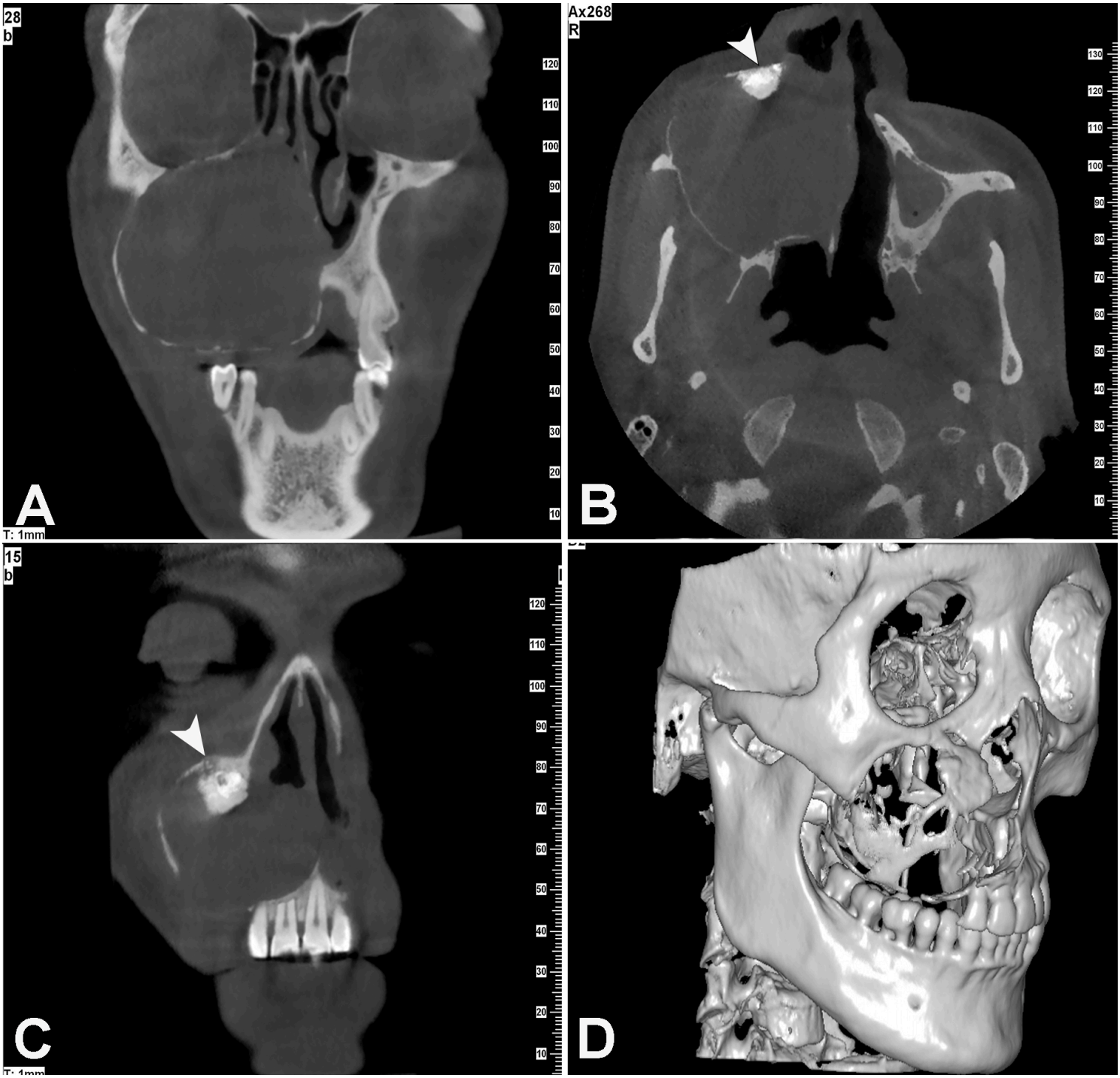

Figure 2

Cone-beam computed tomography images for case 2. A and B, Coronal and axial CBCT images demonstrated a unilocular, well-defined, quasi-circular radiolucency involving the right maxillary sinus, nasal cavity, orbital floor and the hard palate. The walls of the right maxillary sinus, the nasal floor and septum were thinned and perforated. A patchy radiopaque focus was observed at the anterosuperior margin of the lesion (B, C, arrowhead). C, The roots of the right maxillary central incisor and lateral incisor exhibited truncated resorption. D, The three-dimensional visual rendering view showed that the expansile radiolucent lesion extended from the left maxillary central incisor to the right maxillary tuberosity, occupying the entire right maxillary sinus.

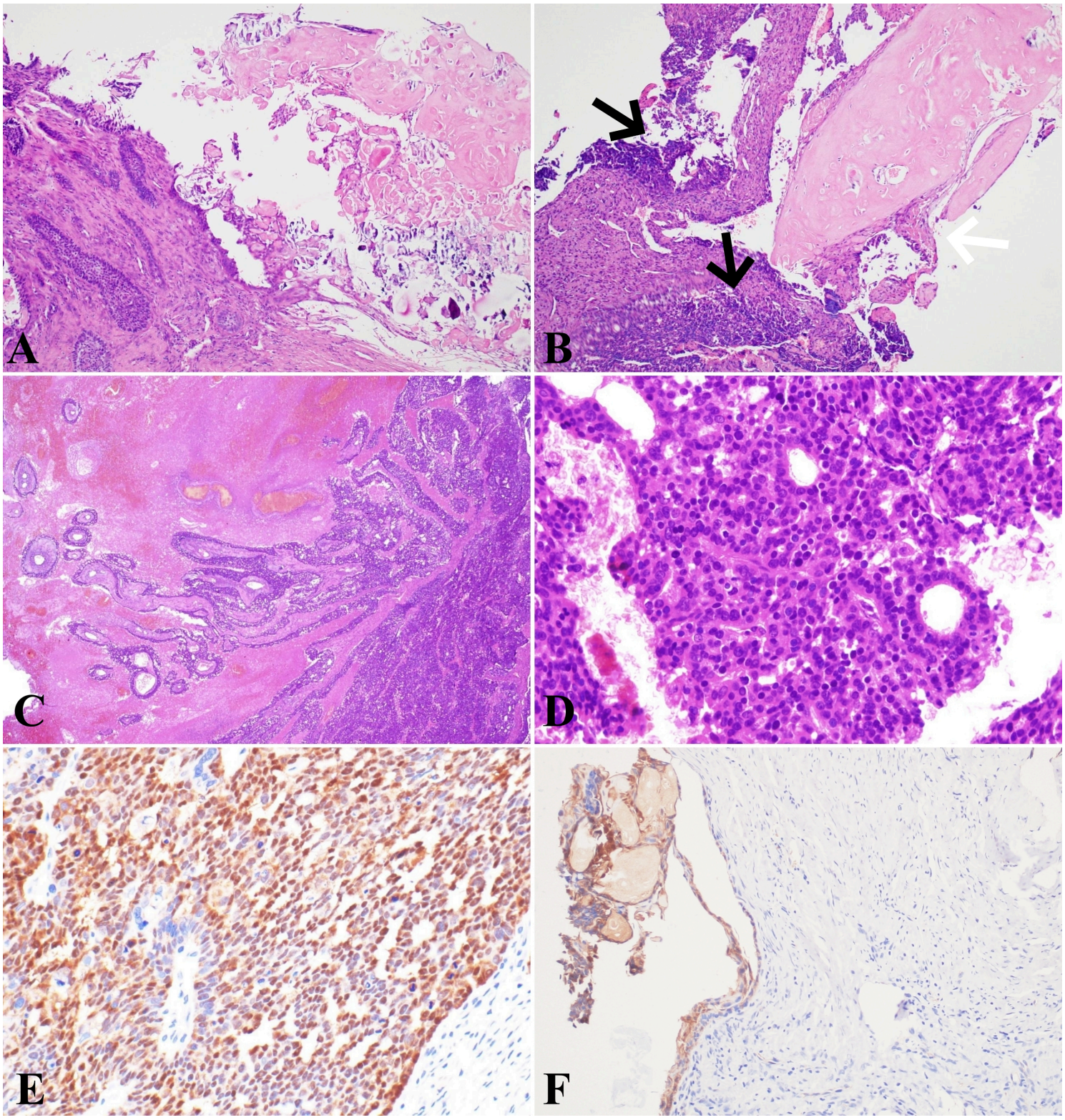

Figure 3

Histopathological and immunohistochemical features of case 2. A, Classic calcifying odontogenic cyst (COC) area showing a cystic space lined by ameloblastomatous epithelium with abundant ghost cells and mural epithelial proliferation. B, Transition zones between GCOC (black arrows) and COC (white arrow). C, Large zones of necrosis in the malignant component. D, The malignant component consisted of atypical tumor cells. Scattered pseudoducts were present. E and F, Cytoplasmic/nuclear β-catenin positivity in both malignant (E) and benign (F) components.

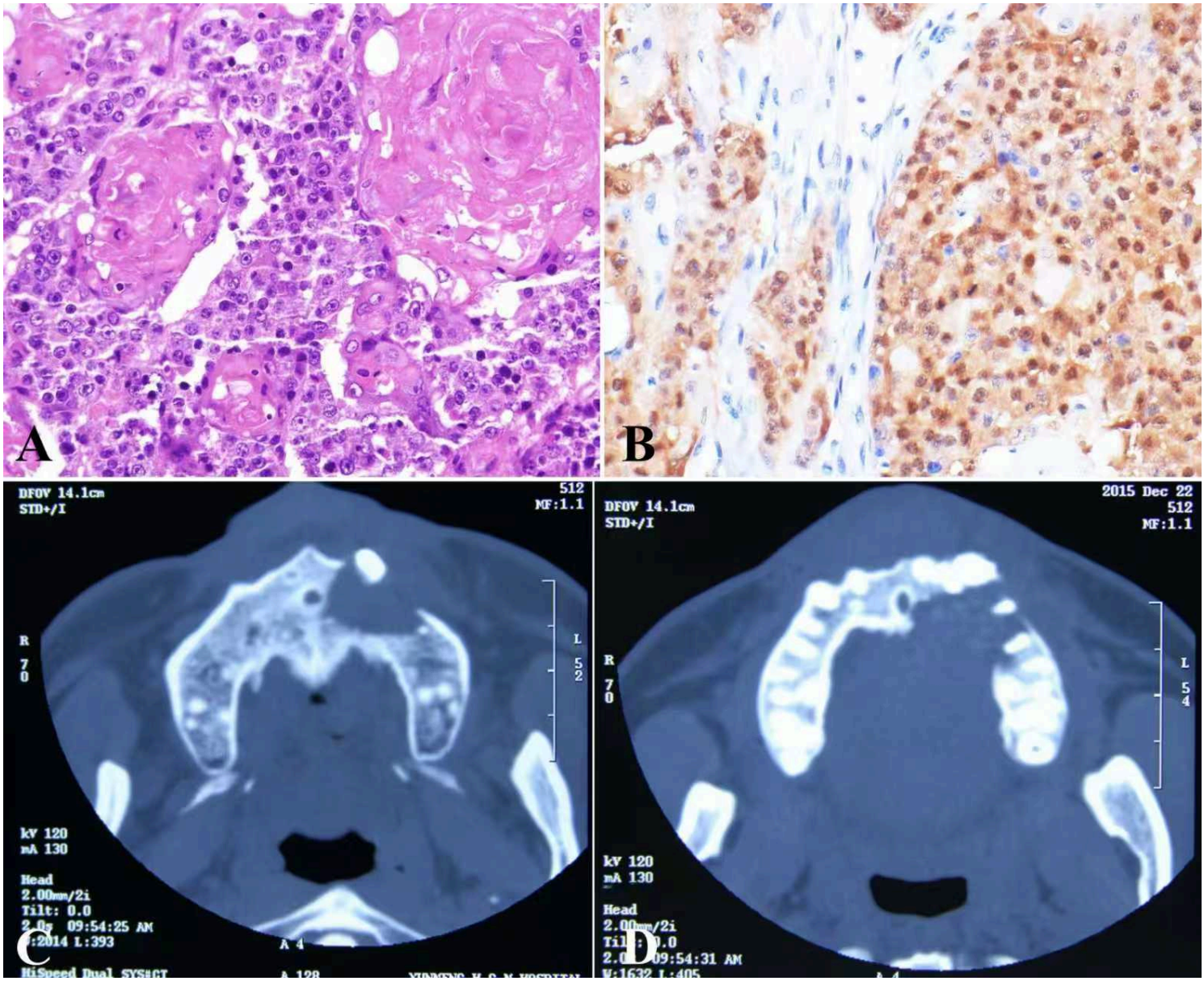

Figure 4

Histopathological and immunohistochemical features of case 3 (A and B) and imaging features of case 4 (C and D). A, Pleomorphic atypical cells admixed with abundant ghost cells. B, Strong and diffuse nuclear β-catenin expression. C, Computed tomography scan revealed a unicystic radiolucent lesion with relatively well-defined but irregular spiculated borders, extending from the left maxillary central incisor to the left maxillary second premolar. D, Scattered punctate calcifications were noted.

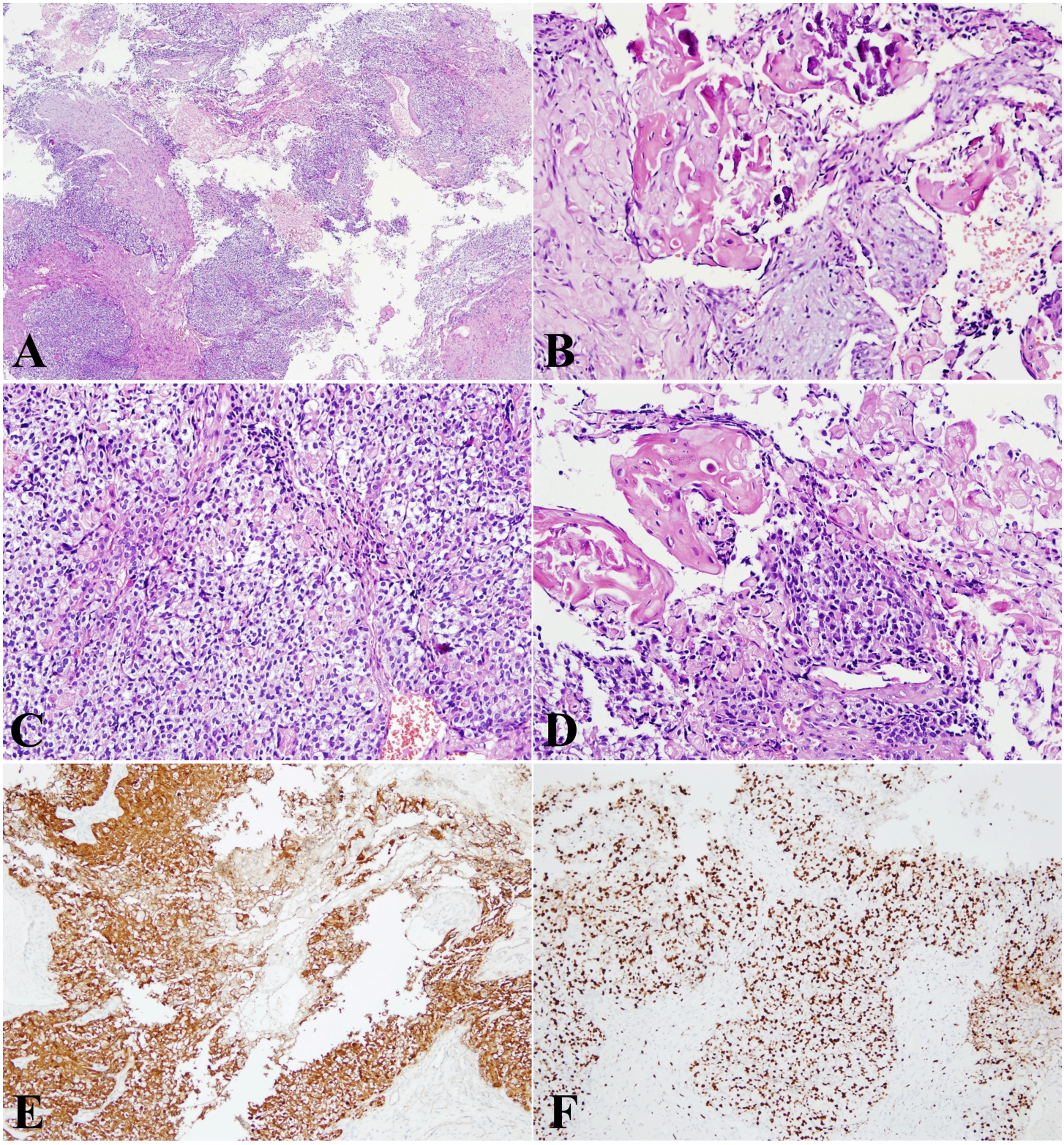

Figure 5

Histopathological and immunohistochemical features of case 4. A, Low-power view showing islands of odontogenic epithelium with ghost cell keratinization. B, Ghost cells with dystrophic calcification. C, High-power view showing the polygonal tumor cells with clear or pale eosinophilic cytoplasm mixed with ghost cells. D, Hyperchromatic atypical tumor cells with ghost cells. E, Tumor cells showing strong and diffuse cytoplasmic and nuclear positivity for β-catenin. F, Ki-67 was strongly positive with proliferative index of more than 50%.