Research Square

Preprints are preliminary reports that have not undergone peer review. They should not be considered conclusive, used to inform clinical practice, or referenced by the media as validated information.

Spontaneous Coronary Artery Dissection Presenting with Monomorphic Ventricular Tachycardia in a Young Man Hospitalized for Pneumonia and Severe Coughing Episodes: A Case Report

Alihan Ersin

alihanmuberraersin@gmail.com

Manisa Celal Bayar Üniversitesi Hafsa Sultan Hastanesi

Metin Açar

Manisa Celal Bayar Üniversitesi Hafsa Sultan Hastanesi

Mehmet Engin Berk

Manisa Celal Bayar Üniversitesi Hafsa Sultan Hastanesi

Mustafa Uçar

Manisa Celal Bayar Üniversitesi Hafsa Sultan Hastanesi

Ferhat Özyurtlu

Manisa Celal Bayar Üniversitesi Hafsa Sultan Hastanesi

Nurullah Çetin

Manisa Celal Bayar Üniversitesi Hafsa Sultan Hastanesi

Case Report

Keywords: Spontaneous coronary artery dissection, ventricular tachycardia, circumflex artery, ST-elevation myocardial infarction, young male, tirzepatide, case report

Posted Date: October 18th, 2026

DOI: https://doi.org/10.21203/rs.3.rs-11084443/v1

License: This work is licensed under a Creative Commons Attribution 4.0 International License. Read Full License

Additional Declarations: No competing interests reported.

Abstract

Background: Spontaneous coronary artery dissection (SCAD) accounts for approximately 5% of myocardial infarction (MI) cases and predominantly affects young women without traditional cardiovascular risk factors; it is markedly less common in men. Recognized triggers include severe physical exertion, emotional stress, and conditions that acutely raise intrathoracic pressure, such as severe coughing.

Case Presentation: A 21-year-old male was hospitalized with a preliminary diagnosis of pneumonia after severe coughing episodes. He had recently started tirzepatide for obesity. During hospitalization he developed chest pain and tachycardia; an electrocardiogram (ECG) captured monomorphic ventricular tachycardia (VT), and a repeat ECG after rate control showed inferior ST-segment elevation.

Echocardiography revealed a left ventricular ejection fraction (LVEF) of 35%. Coronary angiography demonstrated spontaneous dissection of the circumflex artery (CX) without atherosclerotic disease elsewhere. The patient was managed conservatively with dual antiplatelet therapy and enoxaparin, remained free of recurrent symptoms, and was discharged with an improved LVEF of 40%.

Conclusion: SCAD should be considered in young men presenting with chest pain or arrhythmia after severe coughing, even without classic cardiovascular risk factors. The co-occurrence of CX-related SCAD, inferior ST-elevation myocardial infarction (STEMI), and monomorphic VT is rarely reported and raises the possibility of Purkinje-related arrhythmogenesis in this territory, a mechanism warranting further study.

Introduction

Spontaneous coronary artery dissection (SCAD) is characterized by the spontaneous formation of an intramural hematoma within the coronary artery wall, arising either from an intimal tear that allows blood from the true lumen to create a false lumen, or from spontaneous rupture of the vasa vasorum within the arterial wall (1). SCAD accounts for approximately 5% of MI cases in the general population and predominantly affects young and middle-aged women without traditional coronary risk factors; it is reported far less frequently in men, in whom physical exertion is a more common precipitant than emotional stress (2, 3).

The majority of reported SCAD cases in the literature involve women. Here we report a case of SCAD in a young man who developed chest pain, dyspnea, and monomorphic ventricular tachycardia following prolonged and severe coughing episodes during hospitalization for pneumonia — an atypical presentation that, to our knowledge, has rarely been described in this combination.

Case Presentation

A 21-year-old man was admitted to the Department of Pulmonology following episodes of severe coughing and was hospitalized with a preliminary diagnosis of pneumonia, for which treatment was initiated. He had no known history of coronary artery disease but reported a history of cigarette smoking. Further history revealed that tirzepatide had been initiated approximately 10 days before admission for the management of obesity.

During follow-up on the pulmonology ward, the patient developed chest pain and episodes of tachycardia and was referred to the Cardiology Department. Further history revealed dyspnea and chest pain associated with the severe coughing episodes, as well as intermittent syncope. On examination, blood pressure was 130/80 mmHg, heart rate was 105 beats/min, and oxygen saturation was 92%.

Transthoracic echocardiography revealed a left ventricular ejection fraction of 35%, grade 1–2 mitral regurgitation, minimal aortic regurgitation, grade 2–3 tricuspid regurgitation, a D-shaped left ventricle, and an estimated pulmonary artery systolic pressure of 45 mmHg.

Timeline

Timeline of Clinical Events

Time Point	Event
~10 days before admission	Tirzepatide therapy was initiated for obesity.
Admission	Hospitalization in the Department of Pulmonology due to severe coughing episodes; pneumonia was the preliminary diagnosis and treatment was initiated.
During hospitalization	The patient developed chest pain, dyspnea, episodes of tachycardia, and intermittent syncope; Cardiology was consulted.
During tachycardia episode	Monomorphic ventricular tachycardia was detected on ECG (Figure 1); intravenous metoprolol was administered.
After rhythm control	Repeat ECG demonstrated ST-segment elevation in the inferior leads (II, III, and aVF) (Figure 2); peak troponin I was 10,125 ng/L, CRP was 9.56 mg/L, and D-dimer was 1,324 ng/mL.
Same day	Transthoracic echocardiography showed an LVEF of 35%, mild mitral and aortic regurgitation, moderate tricuspid regurgitation, a D-shaped left ventricle, and a pulmonary artery systolic pressure of 45 mmHg.
Catheterization	Coronary angiography via the right radial approach revealed spontaneous dissection of the circumflex artery (Figure 3); no significant stenosis was observed in the other coronary arteries.
Treatment	Conservative management was initiated with dual antiplatelet therapy (aspirin + clopidogrel) and anticoagulation with enoxaparin; no revascularization was performed.
Discharge	The patient was discharged asymptomatic; follow-up echocardiography showed improvement of LVEF to 40%. Repeat coronary angiography was not performed, and outpatient cardiology follow-up was planned.

An ECG obtained during an episode of tachycardia demonstrated a wide-QRS-complex tachycardia consistent with monomorphic ventricular tachycardia (Fig. 1).

Following intravenous metoprolol for rate control, a repeat ECG demonstrated ST-segment elevation in the inferior leads (II, III, and aVF) (Fig. 2), and the patient was referred for coronary angiography Laboratory investigations showed a C-reactive protein level of 9.56 mg/L, a D-dimer level of 1324 ng/mL, and a markedly elevated troponin I, peaking at 10,125 ng/L (8.4–18.3), consistent with acute myocardial injury.

Cardiac catheterization performed via a right radial approach revealed spontaneous coronary artery dissection involving the circumflex artery (Fig. 3)(Video 1). No significant atherosclerotic stenosis was detected in the other coronary arteries. Intravascular imaging (optical coherence tomography or intravascular ultrasound) was not performed, as these modalities were not available in the catheterization laboratory; the diagnosis of SCAD was established on the basis of characteristic angiographic findings. Differential diagnoses considered during the diagnostic work-up included pneumonia-associated tachyarrhythmia, myopericarditis, pulmonary embolism with right-heart strain, and stress (Takotsubo) cardiomyopathy; these were excluded based on the angiographic findings and clinical course.

Based on the clinical condition and angiographic findings, and in accordance with the 2023 European Society of Cardiology (ESC) Guidelines for acute coronary syndromes — which favor conservative medical management over percutaneous coronary intervention (PCI) in SCAD absent persistent ischemia, hemodynamic instability, or a large territory at risk — the patient was managed with dual antiplatelet therapy (acetylsalicylic acid and clopidogrel) and anticoagulation with enoxaparin sodium, without revascularization.

The patient remained free of recurrent chest pain, dyspnea, or arrhythmic events for the remainder of the hospitalization. Repeat transthoracic echocardiography before discharge showed improvement in LVEF to 40% (from 35% on admission). He was discharged home asymptomatic. Repeat coronary angiography was not performed prior to discharge; outpatient cardiology follow-up was planned to reassess the dissected segment and monitor for recurrence, in keeping with standard SCAD surveillance practice.

At the time of discharge, the patient reported feeling well, with complete resolution of chest pain, dyspnea, and palpitations, and expressed relief that his condition had been managed successfully without the need for stenting or surgery.

Discussion

Our patient differed from the typical SCAD phenotype in both age and sex, and his presentation with monomorphic ventricular tachycardia represents an unusual manifestation of the condition. Hormonal fluctuations, genetic and environmental factors, and physical or emotional stressors are thought to contribute to SCAD pathogenesis; the condition is also associated with fibromuscular dysplasia, connective tissue disorders, migraine, pregnancy, and hypertension. In a prospective cohort, 57% of patients reported a precipitating stressor before their SCAD event — 40% emotional stress and 24% significant physical activity (4). Most patients present with chest pain or an anginal equivalent and

biomarker/ECG findings consistent with STEMI or NSTEMI; ventricular arrhythmias, cardiogenic shock, or sudden cardiac arrest occur less frequently (5).

In our patient, severe and repetitive coughing associated with pneumonia may have raised intrathoracic pressure and generated mechanical stress on the coronary wall, potentially triggering the dissection; SCAD following severe coughing has previously been reported, including in a male patient described by Yirerong et al., who similarly emphasized coughing as a precipitating factor (6). The recent initiation of tirzepatide is another noteworthy temporal association in our patient; however, no causal relationship between tirzepatide and SCAD has been established in the literature, and this observation should be interpreted with caution. Regarding coronary distribution, the left anterior descending artery is the most frequently affected vessel (approximately 50% of cases), followed by the circumflex and right coronary arteries (7).

An additional notable feature was the occurrence of monomorphic VT in the setting of CX-related SCAD causing inferior STEMI. Although myocardial infarction is the most common presentation of SCAD, sustained ventricular arrhythmias are comparatively uncommon and are thought to arise from ischemia-related cellular electrical instability, increased sympathetic activity, and heterogeneous repolarization.

Acute ischemia may create regional conduction heterogeneity, favoring monomorphic VT through re-entry or triggered activity. The left circumflex artery typically supplies the inferolateral and, depending on coronary dominance, portions of the inferior left ventricular wall along with the associated Purkinje network (8); surviving but severely ischemic subendocardial Purkinje fibers in this territory may become arrhythmogenic foci. Nogami classified Purkinje-related monomorphic VTs into four groups — fascicular VT, post-infarction Purkinje-mediated VT, bundle-branch/interfascicular re-entry, and focal Purkinje VT

(9). Reports specifically describing Purkinje-related monomorphic VT associated with circumflex-artery SCAD are limited, so this case may add a useful data point on this mechanism, although a direct Purkinje-mediated pathway could not be confirmed here because no electrophysiological study or Purkinje mapping was performed.

Coronary angiography remains the diagnostic cornerstone for SCAD, with a dual-lumen appearance or arterial-wall contrast staining considered diagnostic, particularly for type 1 lesions; intravascular imaging (OCT/IVUS) can add value when angiographic findings are ambiguous (10). Per the 2023 ESC guideline, conservative medical management is generally preferred over PCI in SCAD; revascularization is reserved for persistent or recurrent ischemia, a large territory at risk, or reduced antegrade flow. When required, options include limited balloon angioplasty, targeted stenting of the dissected segment, longer stents to limit hematoma propagation, or coronary bypass grafting for left main or multivessel proximal involvement, or failed/infeasible PCI. In a small observational study, SCAD patients treated surgically had early outcomes comparable to conservatively managed patients through 5 years, despite a 68% graft occlusion rate at 5 years (11). Given the absence of ongoing ischemia or another indication for revascularization, our patient was appropriately managed conservatively.

Conclusion

Although SCAD is rare, it should be considered in the differential diagnosis of chest pain in young patients without traditional cardiovascular risk factors, including young men after severe coughing. This case demonstrates that circumflex-artery SCAD may be associated not only with acute coronary syndrome but also with potentially life-threatening ventricular arrhythmias such as monomorphic VT, and raises the possibility of a relationship between acute ischemia in the CX territory and Purkinje-related arrhythmogenesis. Larger prospective and epidemiological studies are needed to clarify the epidemiology, pathogenesis, diagnostic strategies, optimal management, and arrhythmic complications of SCAD.

Declarations

Ethics approval and consent to participate

Not applicable.

Consent for publication

Written informed consent was obtained from the patient for publication of this case report and any accompanying images and videos.

Competing interests

The authors declare that they have no competing interests.

Funding

The authors received no specific funding for this work.

Authors' contributions

[Author initials] contributed to the conception and design of the case report, data collection, analysis and interpretation of the data, and drafting and revising the manuscript. All authors read and approved the final manuscript.

Availability of data and materials

Not applicable.

References

1. Yip A, Saw J. Spontaneous coronary artery dissection—a review. Cardiovasc Diagn Ther. 2015;5(1):37. https://doi.org/10.3978/j.issn.2223-3652.2015.01.08

2. Fahmy P, Prakash R, Starovoytov A, Boone R, Saw J. Predisposing and precipitating factors in men with spontaneous coronary artery dissection. JACC Cardiovasc Interv. 2016;9(8):866–8. https://doi.org/10.1016/j.jcin.2016.02.024.
3. Saw J, Aymong E, Mancini GBJ, et al. Nonatherosclerotic coronary artery disease in young women. Can J Cardiol. 2014;30(7):814–9.
4. Saw J, Aymong E, Sedlak T, et al. Spontaneous coronary artery dissection: association with predisposing arteriopathies and precipitating stressors and cardiovascular outcomes. Circ Cardiovasc Interv. 2014;7(5):645–55.
5. Lindor RA, Tweet MS, Goyal KA, et al. Presentation of patients with spontaneous coronary artery dissection to the emergency department. J Emerg Med. 2017;52(3):286–91.
6. Yirerong JA, Hurlburt H. Spontaneous coronary artery dissection in a man with intense coughing spasms. BMJ Case Rep 2018;2018:bcr-2018-225932. https://doi.org/10.1136/bcr-2018-225932
7. Hayes SN, Kim ESH, Saw J, et al. Spontaneous coronary artery dissection. J Am Coll Cardiol. 2020;76(8):961–84.
8. Libby P, Bonow RO, Mann DL, Tomaselli GF, Bhatt DL, Solomon SD, Braunwald E. Braunwald's Heart Disease: A Textbook of Cardiovascular Medicine. 12th ed. Philadelphia, PA: Elsevier; 2021.
9. Nogami A. Purkinje-related arrhythmias: mechanisms and therapy. J Cardiovasc Electrophysiol. 2011;22:109–15.
10. Alfonso F, Paulo MG, Gonzalo N, Dutary J, Jimenez-Quevedo P, Lennie V, Escaned J, Bañuelos C, Hernandez R, Macaya C. Diagnosis of spontaneous coronary artery dissection by optical coherence tomography. J Am Coll Cardiol. 2012;59:1073–9.
11. Tweet MS, Eleid MF, Best PJM, Lennon RJ, Lerman A, Rihal CS, et al. Spontaneous coronary artery dissection: revascularization versus conservative therapy. Circ Cardiovasc Interv. 2014;7:777–86.
12. Vanzetto G, Berger-Coz E, Barone-Rochette G, et al. Prevalence, therapeutic management and medium-term prognosis of spontaneous coronary artery dissection: results from a database of 11,605 patients. Eur J Cardiothorac Surg. 2009;35:250–4. https://doi.org/10.1016/j.ejcts.2008.10.023.

Figures

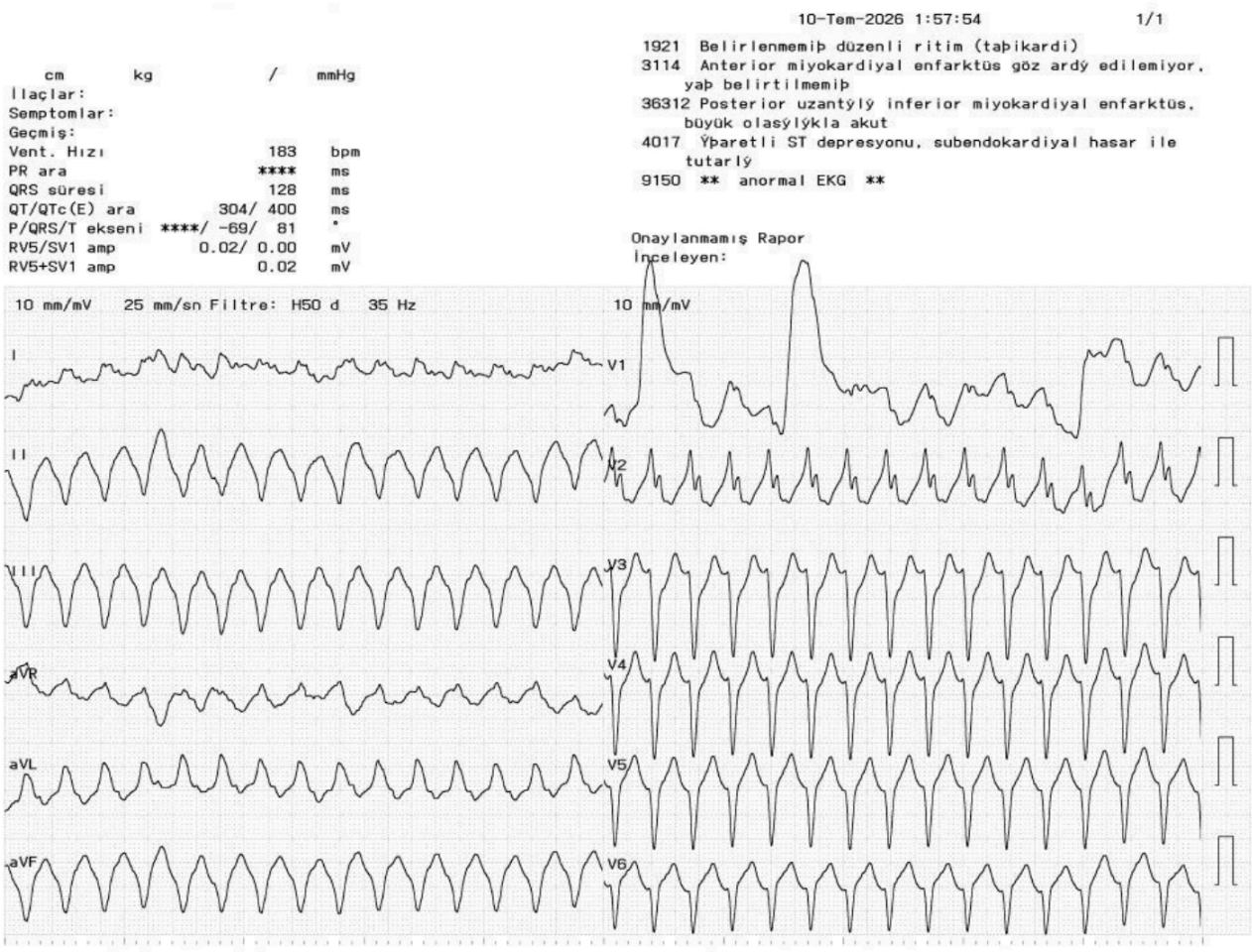

Figure 1

Monomorphic ventricular tachycardia is observed. Patient-identifying information has been removed from the original tracing.

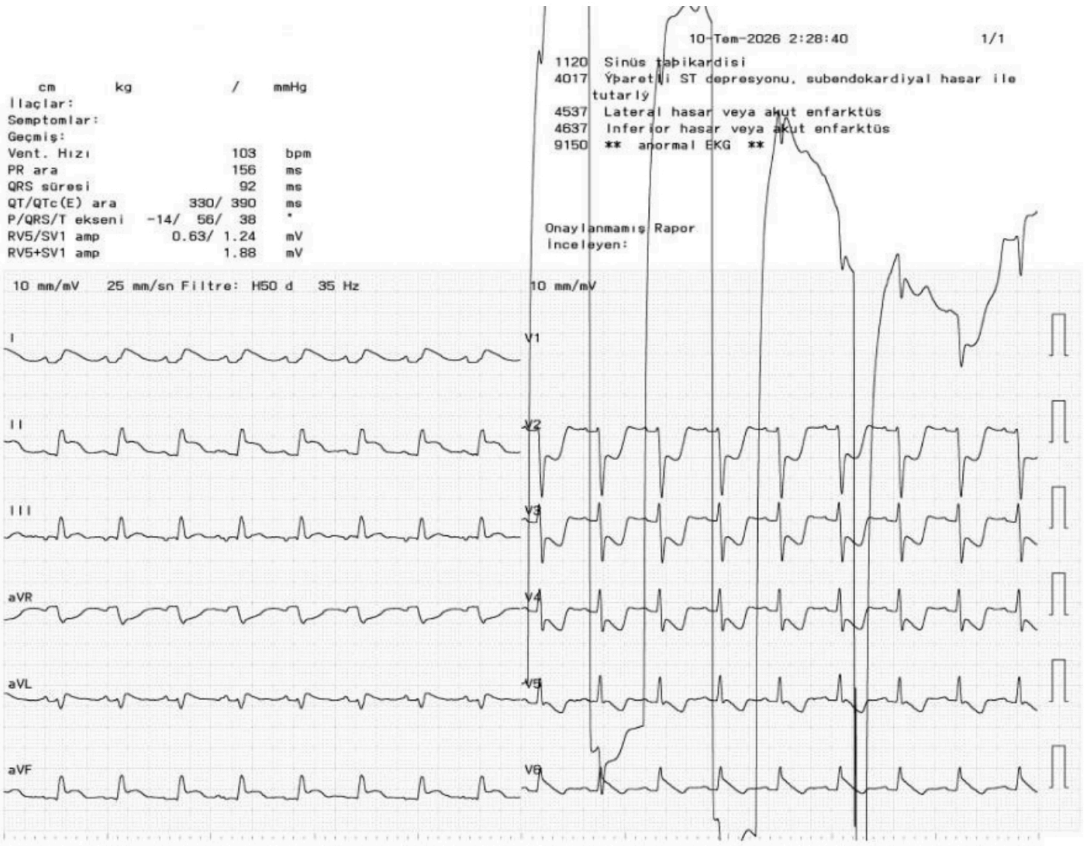

Figure 2

ST-segment elevation is observed in the inferior leads on electrocardiography. Patient-identifying information has been removed from the original tracing.

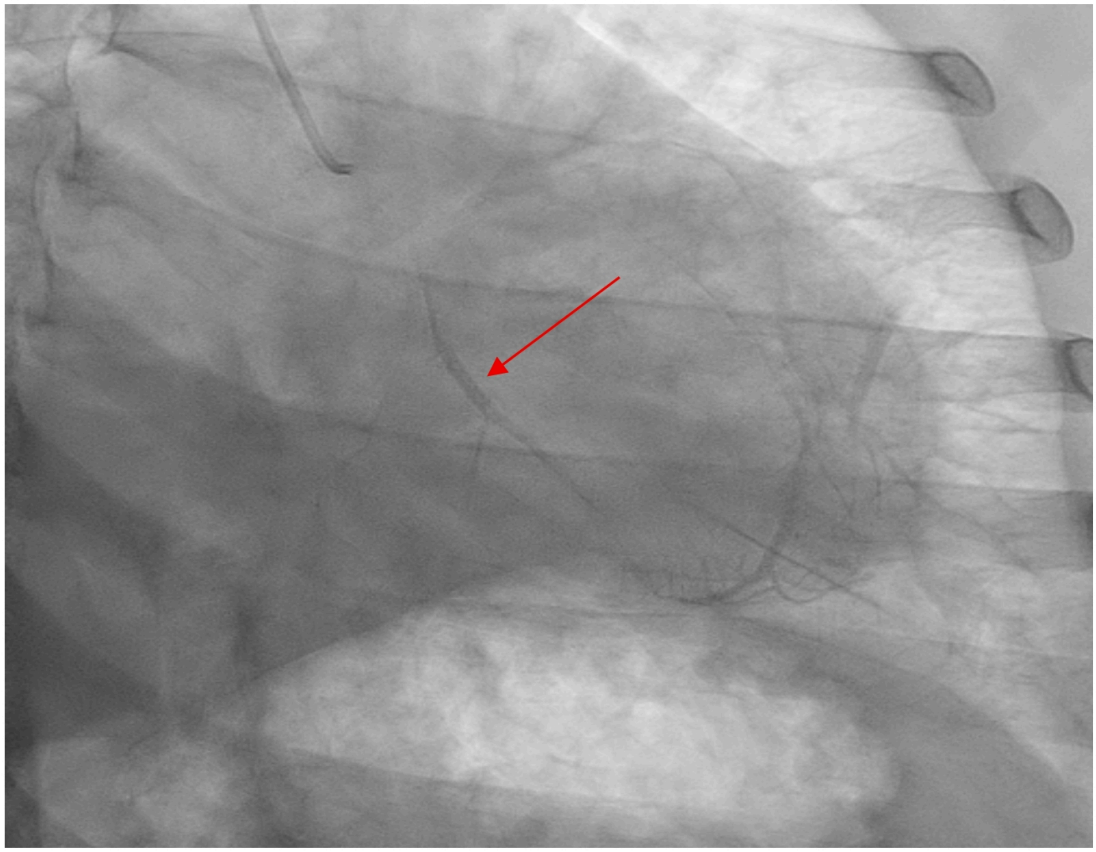

Figure 3

Coronary angiography demonstrating spontaneous dissection of the circumflex artery.

Supplementary Files

This is a list of supplementary files associated with this preprint. Click to download.

- scad.avi