Research Square

Preprints are preliminary reports that have not undergone peer review. They should not be considered conclusive, used to inform clinical practice, or referenced by the media as validated information.

Surgical Decompression of the Deep Motor Branch of the Ulnar Nerve After Fifth Metacarpal Fracture: Technique, Indications and Pitfalls

Francesco Zanchetta
MultiMedica Group
Giorgio Eugenio Pajardi
Università degli Studi Di Milano
Stephanie Hili
MultiMedica Group
Elisa Maria Ragaini
elisa.ragaini@gmail.com

Università degli Studi Di Milano
Luigi Troisi
MultiMedica Group

Case Report

Keywords:

Posted Date: October 21st, 2026

DOI: https://doi.org/10.21203/rs.3.rs-11058302/v1

License: This work is licensed under a Creative Commons Attribution 4.0 International License. Read Full License

Additional Declarations: No competing interests reported.

Surgical Decompression of the Deep Motor Branch of the Ulnar Nerve After Fifth Metacarpal Fracture: Technique, Indications and Pitfalls

Francesco Zanchetta[1], Giorgio Eugenio Pajardi[2,3], Stephanie Hili[1], Elisa Maria Ragaini[2,1], Luigi Troisi[1,2]

Affiliations:

1. Reconstructive Microsurgery Service, MultiMedica Group, Milan 20123, Italy.
2. Plastic Reconstructive and Aesthetic Plastic Surgery School, Università degli Studi Di Milano, Milan, Italy.
3. University Department of Hand Surgery & Rehabilitation, San Giuseppe Hospital, IRCCS MultiMedica Group, Milan, Italy.

Corresponding Author:

Elisa Maria Ragaini

elisa.ragaini@gmail.com

+393313162162

Plastic Reconstructive and Aesthetic Plastic Surgery School, Università degli Studi Di Milano, Milan, Italy.

ABSTRACT

Background:

Compression of the deep motor branch of the ulnar nerve (DBUN) is a well-recognized cause of intrinsic hand muscle weakness, most commonly occurring at the level of Guyon's canal. While a variety of etiologies have been described, traumatic causes are relatively uncommon and are typically associated with carpometacarpal fracture-dislocations or iatrogenic injury. Diagnosis may be delayed, particularly in cases presenting with isolated motor deficit and inconclusive imaging.

Technique:

We describe a surgical technique for decompression and neurolysis of the DBUN at the level of the distal wrist and proximal palm, in which the cause of compression is related to post-traumatic changes. The procedure involves a volar approach using anatomical landmarks such as the pisiform and hook of the hamate, proximal-to-distal identification of the ulnar nerve, and meticulous release of fibrotic adhesions along the course of the deep motor branch.

Indications:

This technique is indicated in patients presenting with persistent intrinsic muscle weakness following ulnar-sided hand trauma, particularly in the presence of isolated motor deficit with preserved sensation and electrophysiological evidence of DBUN compression.

Results:

Application of this technique in a patient with delayed presentation following a fifth metacarpal fracture resulted in progressive and complete recovery of intrinsic muscle function and hand strength at final follow-up.

Conclusion:

Surgical decompression of the DBUN is a reliable and effective option in selected patients with delayed motor deficit. Early recognition and targeted surgical release can lead to excellent functional outcomes, even in cases with prolonged symptom duration.

INTRODUCTION

Fractures of the fifth metacarpal are among the most common injuries of the hand and are generally associated with favorable outcomes following non-operative treatment [1]. However, due to the close anatomical relationship between the ulnar-sided metacarpals and the ulnar nerve, neurological complications may occasionally occur.

The deep motor branch of the ulnar nerve (DBUN) is particularly vulnerable as it courses through Guyon's canal and across the deep palm in close proximity to the base of the fifth metacarpal [2–4]. Injury or compression of this branch may result in selective motor deficits affecting the intrinsic muscles of the hand, often in the absence of sensory impairment, making clinical recognition challenging.

Most reported cases of DBUN injury in the context of metacarpal trauma are associated with carpometacarpal fracture-dislocations or dislocations without fracture [5–10], as well as iatrogenic injury following surgical fixation [11–13]. These patterns are thought to result from either direct mechanical compression by displaced bony structures or secondary scarring.

In contrast, isolated extra-articular fractures are generally considered benign and are rarely associated with nerve injury, which may lead to under-recognition of this complication. Diagnosis of DBUN compression may be further complicated by inconclusive imaging findings, making clinical examination and electrophysiological studies essential.

Surgical decompression and neurolysis represent an effective treatment option in selected patients; however, detailed descriptions of the surgical technique, indications, and intraoperative considerations remain limited in the literature.

The aim of this article is to describe a surgical technique for decompression of the deep motor branch of the ulnar nerve, with particular emphasis on indications, key technical steps, and potential pitfalls, supported by a representative clinical case.

INDICATIONS AND CONTRAINDICATIONS

Indications

Surgical decompression of the deep motor branch of the ulnar nerve (DBUN) is indicated in patients presenting with clinical and/or electrophysiological evidence of motor branch compression, particularly in the context of ulnar-sided hand trauma.

Specific indications include:

- persistent intrinsic muscle weakness following fifth metacarpal or ulnar-sided hand injury
- isolated motor deficit with preserved sensation, suggestive of selective involvement of the deep branch
- positive clinical signs of ulnar motor dysfunction, including Froment's and Wartenberg's signs [14].
- electromyographic confirmation of DBUN involvement
- failure of conservative management with no clinical improvement over time

Delayed presentations are not a contraindication, as satisfactory recovery may still be achieved following surgical decompression.

Contraindications

Surgical intervention may not be indicated in the following situations:

- early neurapraxia with signs of spontaneous recovery
- absence of objective motor deficit
- generalized ulnar nerve involvement with predominant sensory symptoms, suggesting a more proximal lesion
- severe joint instability or fracture patterns requiring primary orthopedic fixation as priority treatment
- patients with significant comorbidities or poor surgical candidacy

Careful clinical assessment remains essential, as imaging may be inconclusive in cases of isolated motor branch compression.

SURGICAL TECHNIQUE

Overview

Compression of the deep motor branch of the ulnar nerve (DBUN) at the distal wrist and proximal palm may present with isolated motor deficit and inconclusive imaging. In such cases, surgical decompression and neurolysis can provide reliable functional recovery when appropriately indicated.

Positioning and landmarks

The procedure is performed under regional anesthesia with tourniquet control.
The patient is positioned supine with the arm extended on an arm table.
Surface landmarks, including the pisiform and the hook of the hamate, are identified and marked to delineate the expected course of the ulnar nerve and its deep motor branch (Fig. 1).

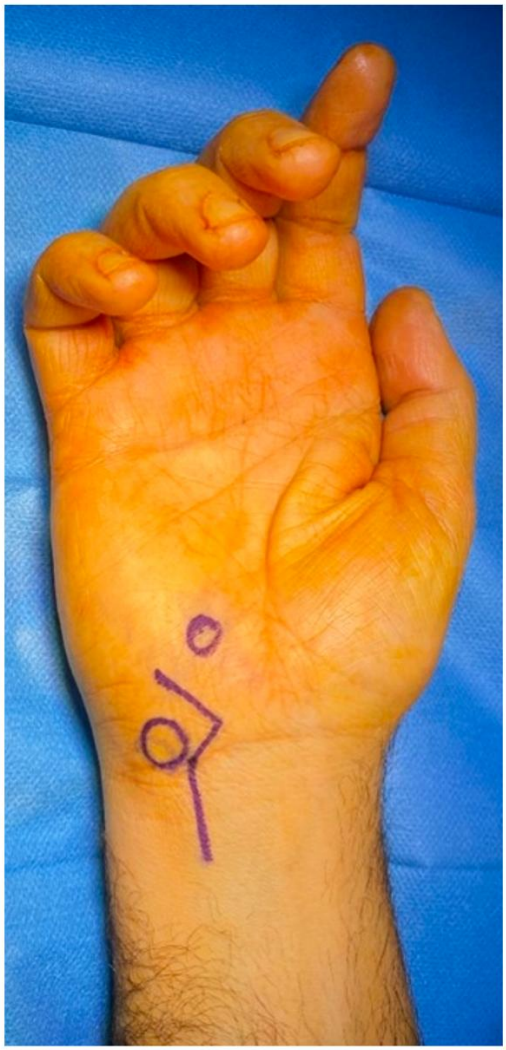

***Figure 1**: Pre-operative markings - the pisiform and hook of hamate were used as landmarks to delineate the course of the nerve.*

Skin incision and exposure

A longitudinal incision is made from the distal volar forearm extending into the palm, providing access to Guyon's canal and the proximal deep palmar space.
Careful dissection through the subcutaneous tissue is performed to expose the ulnar neurovascular bundle while preserving surrounding structures.

Identification of the ulnar nerve

The ulnar nerve is identified proximally, outside the zone of potential scarring, and dissected in a proximal-to-distal fashion toward its bifurcation.
The superficial sensory branch is first isolated and protected, allowing safe identification of the deep motor branch.

Dissection of the deep motor branch

The deep motor branch is carefully followed as it passes beneath the hypothenar fibrous arch and courses radially across the deep palm.
Particular attention is paid to known sites of potential compression, including the region between the pisiform and the hook of the hamate, as well as the base of the fifth metacarpal [2, 3].

Decompression and neurolysis

External neurolysis is performed with meticulous release of fibrotic adhesions along the entire course of the nerve.
In delayed presentations, dense scar tissue may tether the nerve to adjacent structures. In the illustrative case, the nerve demonstrated a focal hourglass deformity consistent with compressive neuropathy (Fig. 2).

Dissection is continued distally until complete decompression is achieved along the course of the deep motor branch toward the interosseous musculature. In our case, the nerve was followed distally up to the level of the fourth metacarpal. In general, distal dissection should be continued until the surgeon is confident that all potential sites of compression have been adequately released. Bony correction is not routinely required unless clear mechanical impingement is identified.

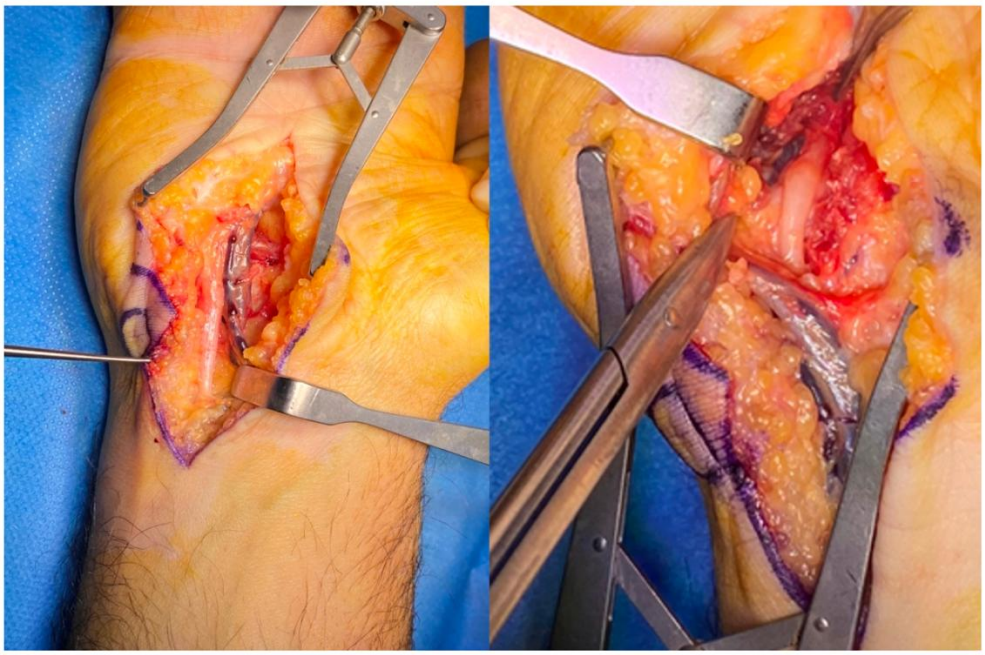

Figure 2*: The ulnar neurovascular bundle has been isolated all the way from the wrist, beyond its bifurcation into deep and superficial branches (left). and congested at the site of the lesion, with an hourglass appearance (right).*

Closure

Following meticulous haemostasis, the wound is closed in layers.
No postoperative immobilization is required, and a bulky dressing is applied.

Postoperative management

Early mobilization is encouraged, with rehabilitation initiated within the first few days after surgery.
Functional recovery is typically gradual, with progressive improvement in intrinsic muscle strength over several months.

PEARLS AND PITFALLS

Pearls

- A proximal-to-distal dissection allows identification of the ulnar nerve outside the zone of trauma, facilitating safer isolation of its branches.
- Early identification of the bifurcation within Guyon's canal helps distinguish the superficial sensory branch from the deep motor branch.
- Careful release of the hypothenar fibrous arch is essential to ensure complete decompression of the deep motor branch.
- The presence of an hourglass deformity may indicate focal compression and guide targeted neurolysis.
- The nerve should be systematically explored along its course to identify all potential sites of compression and ensure a complete and sufficiently extended neurolysis.
- Electrophysiological studies are particularly useful in confirming diagnosis when imaging findings are inconclusive.

Pitfalls

- Failure to recognize isolated motor deficits may delay diagnosis, as sensory function can be preserved in DBUN compression.
- Incomplete distal release of the deep motor branch may result in persistent symptoms.
- Misidentification of normal anatomical structures as pathological fibrotic tissue may lead to inadequate decompression.
- Over-reliance on imaging may result in missed diagnosis, as radiological findings can be normal despite significant nerve compression.

CASE ILLUSTRATION

A 42-year-old right-hand dominant man presented with progressive weakness, fatigability, and reduced dexterity of the right hand, 18 months following a closed extra-articular fracture of the base of the fifth metacarpal that had been managed conservatively (Fig. 3).

Clinical examination revealed marked wasting of the first dorsal interosseous muscle (Fig. 4), with positive Froment's and Wartenberg's signs, in the absence of sensory deficit. Grip strength was reduced compared to the contralateral side, as confirmed by Jamar dynamometer testing (right: 27.3 kg vs left: 38.6 kg). Radiographs demonstrated a healed extra-articular fracture without significant deformity (Fig. 5). Electrophysiological studies confirmed compression of the deep motor branch of the ulnar nerve.

The patient underwent surgical exploration and decompression as described. Intraoperatively, dense fibrotic tissue was identified at the level of the fifth metacarpal base, causing tethering and focal compression of the nerve, which demonstrated an hourglass deformity (Fig. 2).

Postoperatively, the patient experienced progressive recovery of intrinsic muscle function, with restoration of strength and resolution of clinical signs at final follow-up (Fig. 6).

Figure 3*: Radiographic views taken at the time of the initial trauma, after the hand had been immobilized in a cast.*

Figure 4*: Clinical appearance of the hands 18 months post-injury, at the time of initial presentation. There is obvious wasting of the right first dorsal interosseous muscle.*

Figure 5*: Radiographic appearances of the healed right 5th metacarpal fracture, 18 months post-injury.*

Figure 6: *Clinical appearance of the hands post-operatively - the right sided intrinsic atrophy has significantly recovered.*

RESULTS

The postoperative course was uneventful, with complete wound healing achieved within two weeks. Early improvement in hand dexterity was noted within the first postoperative weeks.

Functional recovery was progressive, with gradual restoration of intrinsic muscle strength over time. At final follow-up, the patient demonstrated full recovery of hand function, with resolution of intrinsic muscle wasting and normalization of clinical signs, including Froment's and Wartenberg's signs.

Grip strength returned to levels comparable to the contralateral side, as confirmed by Jamar dynamometer testing. Electrophysiological studies confirmed complete recovery of deep motor branch function, with no evidence of residual deficit.

DISCUSSION

DBUN compression at the wrist is an uncommon but clinically significant condition that may lead to isolated intrinsic muscle weakness. Due to its anatomical course through Guyon's canal and across the deep palm, the DBUN is particularly vulnerable to compression in relation to the pisiform, hook of the hamate, and the base of the fifth metacarpal [2, 3, 15].

Most reported cases of DBUN injury following metacarpal trauma are associated with carpometacarpal fracture-dislocations or dislocations without fracture [5–8, 10]. In addition, iatrogenic injuries have been described following surgical fixation techniques such as percutaneous pinning or open reduction [11–13]. These mechanisms are typically related to direct compression from displaced bony structures or intraoperative injury.

In contrast, isolated extra-articular fractures of the fifth metacarpal are generally considered benign and are not commonly associated with nerve injury. In our review of the literature, no cases of delayed DBUN compression following an isolated extra-articular fracture managed non-operatively were identified, suggesting that this mechanism may be under-recognized. The main findings from previously reported cases are summarized in Table 1.

The findings in this study support the hypothesis that delayed compression of the DBUN may occur secondary to post-traumatic fibrosis and tethering of the nerve rather than direct bony impingement. Chronic compressive mechanisms have also been described in association with post-traumatic changes such as pseudoarthrosis [16]. The intraoperative observation of a focal hourglass deformity (Fig. 2) is consistent with a chronic compressive process and highlights the potential for progressive nerve dysfunction even in the absence of significant radiographic abnormalities.

From a clinical perspective, diagnosis may be challenging, particularly in cases presenting with isolated motor deficit and preserved sensation. This reflects the early division of the ulnar nerve into superficial and deep branches within Guyon's canal, which may result in selective involvement of the motor component. As a result, careful clinical assessment remains essential, as imaging findings may be inconclusive in such cases.

Electrophysiological studies play a key role in confirming the diagnosis and guiding surgical decision-making. Persistent intrinsic muscle weakness following ulnar-sided hand trauma should therefore prompt consideration of DBUN compression, even when initial injury patterns appear benign.

The surgical technique described provides a systematic approach to decompression of the deep motor branch, emphasizing proximal-to-distal dissection, identification of key anatomical landmarks, and complete release of fibrotic adhesions. This approach allows safe and effective decompression, even in delayed presentations, and may result in excellent functional recovery.

STUDY	INJURY	NO. OF CASES	INVOLVED RAY	DIAGNOSIS N. DAMAGE	TIMING TO TREATMENT	TREATMENT	NERVE DAMAGE	RECOVERY
1971 Gore	dislocation (volar)	1	IV- V	pre-surgery	5 weeks	open reduction + neurolysis	compression	complete
1986 Peterson	fracture-dislocation (dorsal)	1	V	post-surgery	1 day	closed reduction + immobilization	neuropraxia	complete
1987 Young	dislocation (dorsal)	1	IV + V	pre-surgery	9 days	closed reduction + immobilization	neuropraxia	complete
1990 Murphy	fracture-dislocation (volar)	1	V	pre-surgery	8 weeks	open reduction + k wires + neurolysis	compression	complete
1993 Rourke	fracture-dislocation (volar)	1	V	pre-surgery	several months	open reduction+ k wires +neurolysis	compression	complete
1997 Pimpalnerkar	dislocation (dorsal)	1	IV+V	pre-surgery	immediate	closed reduction + k wires	neuropraxia	complete
1997 Pimpalnerkar	dislocation (dorsal)	1	IV+V	pre-surgery	immediate	closed reduction + k wires	neuropraxia	complete
2001 Maynou	fracture (pseudarthrosis)	1	IV+V	post-surgery	4 months	ORIF + neurolysis	compression	complete
2004 Dahlin	fracture (III-V) + fracture-dislocation (II)	1	II-V	post-surgery	4 days	ORIF (II) + immobilization	undefined (iatrogenic)	partial
2004 Dahlin	fracture-dislocation	1	III-IV	post-surgery	1)7 days 2) 7 months	1)ORIF 2)exploration	Undefined (iatrogenic)	partial
2008 Saing	fracture-dislocation	1	IV+V	post-surgery	1) 3 days 2) 4 weeks	1) closed reduction + K wires 2) neurolysis	compression	complete
2008 Saing	fracture-dislocation	1	IV+V	post-surgery	1) few days 2) 3 weeks	1) closed reduction + K wires 2) neurolysis	compression	complete
2008 Saing	fracture-dislocation	1	V	post-surgery	1) few days 2) 3 weeks	1) closed reduction + K wires 2) neurolysis	compression	complete
2023 Muneer	fracture	1	IV+V	post-surgery	1) immediate 2) 4 months	1) k wires 2) neuroma removal + nerve graft	section (iatrogenic)	partial

***Table 1**: Summary of relevant cases identified in the literature, describing injuries to the MBUN secondary to trauma to the ulnar sided metacarpals.*

CONCLUSION

Compression of the deep motor branch of the ulnar nerve should be considered in patients presenting with persistent intrinsic muscle weakness following ulnar-sided hand trauma, even in the absence of obvious radiological abnormalities.

The surgical technique described provides a safe and effective approach for decompression and neurolysis of the DBUN, with particular value in delayed presentations where diagnosis may be challenging.

Careful clinical assessment and appropriate patient selection are essential to achieve optimal outcomes. In this context, simple clinical maneuvers such as the crossed finger test described by Earle[14], can be useful to detect isolated motor dysfunction and avoid missed diagnosis, even in the acute setting.

When indicated, surgical intervention can result in excellent functional recovery, even after prolonged symptom duration.

DECLARATIONS

Abbreviations

DBUN: Deep motor branch of the ulnar nerve.

Ethics approval and consent to participate

Ethical approval was not required for this study in accordance with the institutional requirements of MultiMedica Group. The study was conducted in accordance with the principles of the Declaration of Helsinki. Written informed consent to participate was obtained from the patient.

Consent for publication

Written informed consent was obtained from the patient for publication of the clinical information and accompanying images.

Availability of data and materials

All data relevant to this study are included in the article. Further information is available from the corresponding author upon reasonable request.

Competing Interests

The authors declare that they have no competing interests.

Funding

The authors received no funding for this work.

Authors' contributions

F.Z. and S.H. conceived the study, contributed to the clinical and surgical management of the patient, collected and interpreted the clinical data, and contributed substantially to the preparation of the manuscript. E.M.R. contributed to the literature review and manuscript preparation. G.E.P. and L.T. contributed to the interpretation of the findings and critically revised the manuscript. All authors reviewed and approved the final version of the manuscript.

Acknowledgements

Not applicable.

REFERENCES

1. Gudmundsen TE, Borgen L (2009) Fractures of the fifth metacarpal. Acta radiol 50:296–300. https://doi.org/10.1080/02841850802709201
2. Khoo D, Carmichael SW, Spinner RJ (1996) Ulnar nerve anatomy and compression. Orthop Clin North Am 27:317–38
3. ATKINS SE, LOGAN B, MCGROUTHER DA (2009) The Deep (Motor) Branch of the Ulnar Nerve: A Detailed Examination of its Course and the Clinical Significance of its Damage. Journal of Hand Surgery (European Volume) 34:47–57. https://doi.org/10.1177/1753193408097489
4. Wolfe SW, Pederson WC, Kozin SH, Cohen MS (2017) Green's Operative Hand Surgery. In: Green's Operative Hand Surgery, 7th ed
5. Gore DR (1971) Carpometacarpal dislocation producing compression of the deep branch of the ulnar nerve. J Bone Joint Surg Am
6. Peterson P, Sacks S (1986) Fracture-dislocation of the base of the fifth metacarpal associated with injury to the deep motor branch of the ulnar nerve: a case report. J Hand Surg Am

7. MURPHY TP, PARKHILL WS (1990) Fracture-dislocation of the Base of the Fifth Metacarpal with an Ulnar Motor Nerve Lesion. The Journal of Trauma: Injury, Infection, and Critical Care 30:1585–1587. https://doi.org/10.1097/00005373-199012000-00027
8. O'ROURKE PJ, QUINLAN W (1993) Fracture Dislocation of the Fifth Metacarpal Resulting in Compression of the Deep Branch of the Ulnar Nerve. Journal of Hand Surgery 18:190–191. https://doi.org/10.1016/0266-7681(93)90106-P
9. Young TB (1987) Dorsal dislocation of the metacarpal base of the little and ring fingers with ulnar nerve branch compression. Injury 18:65–66. https://doi.org/10.1016/0020-1383(87)90392-5
10. Pimpalnerkar AL, Fakih R, Thomas AP (1997) Carpometacarpal dislocation producing transient motor neurapraxia of the ulnar nerve. Injury 28:397–400. https://doi.org/10.1016/S0020-1383(96)00207-0
11. Dahlin L, Palffy L, Widerberg A (2004) Injury to the deep branch of the ulnar nerve in association with dislocated fractures of metacarpals II–IV. Scand J Plast Reconstr Surg Hand Surg 38:250–252. https://doi.org/10.1080/02844310410027266
12. Saing MH, Lee SY, Raphael JS (2008) Percutaneous Pinning of Fifth Carpal–Metacarpal Fracture–Dislocations: An Alternative Pin Trajectory. HAND 3:251–256. https://doi.org/10.1007/s11552-008-9092-4
13. Muneer M, Alborno Y (2023) Ulnar Nerve Injury during Treatment of Fourth and Fifth Metacarpal Fractures: A Case Report and Anatomical Review. Plast Reconstr Surg Glob Open 11:e4979. https://doi.org/10.1097/GOX.0000000000004979
14. Earle AS, Vlastou C (1980) Crossed fingers and other tests of u1nar nerve motor function. J Hand Surg Am 5:560–565. https://doi.org/10.1016/S0363-5023(80)80106-7
15. Węgiel A, Zielinska N, Tubbs RS, Olewnik Ł (2022) Possible points of compression of the ulnar nerve: Tricks and traps that await clinicians from an anatomical point of view. Clinical Anatomy 35:155–173. https://doi.org/10.1002/ca.23798
16. Maynou C, Demondion X, Mestdagh H (2001) Compression du nerf ulnaire et pseudarthrose des bases métacarpiennes médiales. Chir Main 20:307–311. https://doi.org/10.1016/S1297-3203(01)00051-8

DECLARATIONS

Funding

The authors received no funding for this work.

Ethics Approval

Ethical approval was not required for this study in accordance with the institutional requirements of MultiMedica Group. The study was conducted in accordance with the principles of the Declaration of Helsinki.

Consent to Participate

Written informed consent was obtained from the patient.

Consent for Publication

Written informed consent was obtained from the patient for publication of the clinical information and accompanying images.