Research Square

Preprints are preliminary reports that have not undergone peer review. They should not be considered conclusive, used to inform clinical practice, or referenced by the media as validated information.

Neural correlates of cognitive enhancement after probiotic supplementation

Sara Kim
Chosun University
Sarang Kang
Chosun University
Yu Yong Choi
Chonnam National University Hospital
Kang-Ho Choi
Chonnam National University Hospital
Kun Ho Lee
leekho@chosun.ac.kr

Chosun University

Article

Keywords: Probiotics, Gut–brain axis, Cognitive impairment, Structural MRI, Cortical morphometry

Posted Date: October 14th, 2026

DOI: https://doi.org/10.21203/rs.3.rs-11045321/v1

License: This work is licensed under a Creative Commons Attribution 4.0 International License. Read Full License

Additional Declarations: No competing interests reported.

Abstract

A previous randomized, double-blind, placebo-controlled clinical trial demonstrated that multistrain probiotic supplementation improved visuospatial cognitive performance in older adults with early cognitive impairment. Participants from a randomized, double-blind, placebo-controlled trial (N = 68; probiotic, n = 32; placebo, n = 36) underwent T1-weighted magnetic resonance imaging at baseline and after 52 weeks. Cortical surface area and thickness were quantified using FreeSurfer-based surface morphometry. Between-group differences in longitudinal changes were assessed using t-tests and analysis of covariance adjusted for baseline values and demographic covariates. Compared with placebo, the probiotic group showed increased surface area in the left lingual gyrus (+ 21.53 vs. −54.39 mm^2, $p = 3.12 \times 10^{-4}$) and cuneus (+ 5.31 vs. −26.28 mm^2, p = 0.002). Cortical thickness decreased modestly in these regions in the probiotic group. Structural changes in the lingual gyrus and cuneus were associated with visuospatial cognitive performance. Multistrain probiotic supplementation was associated with region-specific longitudinal cortical changes in the left lingual gyrus and cuneus, particularly in cortical surface area. These morphometric changes were associated with visuospatial cognitive performance in older adults with early cognitive impairment.

INTRODUCTION

Population aging has led to a substantial increase in the prevalence of cognitive impairment and dementia worldwide. Alzheimer's disease is characterized by progressive cognitive decline accompanied by structural and functional brain alterations. Despite advances in symptomatic treatment, currently available therapies provide limited effects on disease progression, and increasing attention has therefore been directed toward potentially modifiable biological factors associated with neurodegeneration and cognitive decline [1,2].

Recent evidence suggests that gut microbiota may contribute to bidirectional communication between the gastrointestinal tract and the central nervous system through the gut–brain axis [3–5]. Experimental studies have reported associations between microbiome-related pathways and neuroinflammatory signaling, immune regulation, synaptic function, and neuronal activity [4,6]. Based on these observations, probiotic supplementation has emerged as a potential intervention for cognitive impairment and neurodegenerative disorders. Several clinical studies have suggested that probiotic treatment may influence cognitive performance and circulating biomarkers associated with neurodegeneration in older adults with cognitive impairment [7–9]. However, findings across studies remain variable, and the neurobiological correlates underlying cognitive changes associated with probiotic intervention are not fully understood.

Magnetic resonance imaging (MRI) provides a noninvasive approach for evaluating structural brain alterations associated with aging and neurodegeneration [10,11]. In particular, cortical morphometric analyses using structural MRI have been widely applied to investigate regional brain vulnerability and longitudinal structural change in individuals with mild cognitive impairment and Alzheimer’s disease [11,12]. Although cognitive outcomes have been evaluated in several probiotic intervention studies, relatively few investigations have examined whether probiotic-associated cognitive changes are accompanied by measurable structural brain alterations.

In a previous randomized, double-blind, placebo-controlled clinical trial, multistrain probiotic supplementation selectively improved visuospatial cognitive performance in older adults with early cognitive impairment [13]. However, whether these cognitive changes were associated with longitudinal structural brain changes remained unclear. The present study was therefore conducted as an ancillary MRI investigation of the parent randomized clinical trial. Using longitudinal structural MRI acquired at baseline and after 52 weeks of supplementation, we examined whether probiotic supplementation was associated with regional cortical morphometric changes and whether these structural alterations were related to longitudinal cognitive performance.

METHODS

Study design, participants, and intervention

This ancillary neuroimaging study evaluated longitudinal structural MRI changes in a subset of participants from a previously completed randomized, double-blind, placebo-controlled trial of multistrain probiotic supplementation in adults aged 60 years or older with early cognitive decline related to aging [13]. The present ancillary study did not involve separate randomization or treatment allocation. The parent trial was prospectively registered with the Clinical Research Information Service (CRiS, Registration No. KCT0009453; https://cris.nih.go.kr/) and recruited participants from the Gwangju Alzheimer’s and Related Dementias (GARD) cohort, an ongoing longitudinal registry described previously[14].

Eligible participants in the parent trial were aged $\geq$ 60 years, had age-related mild cognitive decline according to the registered eligibility criteria, and had a baseline Mini-Mental State Examination (MMSE) score of $\leq$ 27. All participants were required to be capable of

completing neuropsychological assessments and to provide written informed consent. Detailed methods of the parent trial, including participant selection, randomization, and clinical outcomes, have been reported previously [13].

Participants received either a multistrain probiotic formulation containing *Bifidobacterium animalis* subsp. *lactis*, *Limosilactobacillus fermentum*, and *Levilactobacillus brevis*, or a matched placebo once daily during the study period. Participants who completed the initial 24-week parent trial and provided written informed consent for continued follow-up were followed longitudinally. For the ancillary MRI analysis, participants with baseline MRI data who underwent repeat MRI at week 52 were included. T1-weighted MRI scans were obtained at baseline and at week 52 to assess longitudinal changes in cortical structure following the intervention period. Participants with analyzable MRI data at both time points and meeting predefined imaging quality-control criteria were included in the final analysis.

The parent trial was approved by the Institutional Review Board of Chonnam National University Hospital (IRB No. CNUH-2023-072), and the ancillary MRI study received separate approval from the same board (IRB No. CNUH-2024-067). Written informed consent for MRI procedures was obtained directly from all participants.

MRI acquisition

Structural MRI scans were acquired at baseline and at the 52-week follow-up using a 3.0-Tesla Siemens Skyra MRI system (Siemens Healthcare, Erlangen, Germany) equipped with a 20-channel head coil. High-resolution T1-weighted images were obtained using a three-dimensional magnetization-prepared rapid gradient-echo (3D MPRAGE) sequence with the following acquisition parameters: repetition time (TR) = 2300 ms, echo time (TE) = 2.143 ms, inversion time (TI) = 900 ms, flip angle = 9°, field of view = 256 mm, and isotropic voxel resolution of 0.8 × 0.8 × 0.8 mm^3. To ensure measurement consistency across time points, identical scanner hardware, acquisition protocols, and imaging parameters were maintained throughout the study. Standardized head positioning procedures were applied, and all scans underwent routine quality assurance checks to minimize motion and technical artifacts.

Image processing and analysis

Cortical reconstruction and volumetric segmentation were performed using the FreeSurfer software package (version 6.0; Martinos Center for Biomedical Imaging, Massachusetts General Hospital, Boston, MA, USA) based on T1-weighted images. A longitudinal within-subject template–based processing framework implemented in FreeSurfer was applied to improve measurement robustness and reliability and to enhance sensitivity for detecting subtle structural differences between baseline and follow-up scans. The automated processing pipeline included motion correction, removal of non-brain tissue, intensity normalization, Talairach transformation, segmentation of gray and white matter structures, and reconstruction of the gray–white matter and pial cortical surfaces. Regional cortical surface area (mm^2) and cortical thickness (mm) were extracted across the entire cerebral cortex based on automated parcellation. Regions were defined according to the Desikan–Killiany–Tourville (DKT) cortical atlas. All processed images were visually inspected for segmentation accuracy, and minor manual corrections were performed when necessary, according to standard FreeSurfer quality control procedures. After visual inspection of segmentation outputs, participants with major reconstruction errors were excluded from analysis.

Cognitive assessments

Neuropsychological testing was administered at baseline and at week 52 by trained psychologists blinded to treatment allocation. Cognitive measures included the Mini–Mental State Examination (MMSE) [15], the Rey–Osterrieth Complex Figure Test (ROCF; Copy, Immediate Recall, and Delayed Recall) [16], and the Korean version of the Consortium to Establish a Registry for Alzheimer's Disease neuropsychological battery (CERAD-K) [17]. Clinical evaluations and diagnostic classifications were performed by a neurologist specializing in cognitive disorders.

Statistical analysis

Statistical analyses were performed using SPSS software (version 29.0; IBM Corp., Armonk, NY, USA). Baseline demographic and clinical characteristics were compared between groups using independent t-tests for continuous variables and chi-square tests for categorical variables. For brain structural outcomes, region-of-interest analyses were conducted. Within-group changes from baseline to 52 weeks were evaluated using paired t-tests. Between-group differences in longitudinal change scores were assessed using independent t-tests (P_2), followed by analysis of covariance (ANCOVA) as the primary analysis (P_3). ANCOVA models compared between-group differences while adjusting for baseline values, age, sex, education level, and total intracranial volume. Exploratory associations between regional brain structural changes and cognitive performance within the test group were examined using Pearson correlation analyses. Given the

exploratory nature of the structure-function correlations, no correction for multiple comparisons was applied. Statistical significance was set at $p < 0.05$ (two-tailed).

RESULTS

Baseline Characteristics

A total of 68 participants with available baseline and 52-week data were included in the final analysis, comprising 32 participants in the test group and 36 participants in the placebo group (Table 1). No statistically significant differences at baseline were observed across demographic, genetic, or clinical variables.

Table 1
Baseline demographics and clinical characteristics of study participants

Total, N	**Placebo**	**Test**	**P**
	36	**32**	
Male/Female, N	12/24	9/23	0.643
Age, M (SD)	74.14 (5.3)	74.16 (4.9)	0.989
APOE e4 carrier, N (%)	20 (55.6)	17 (53.1)	0.841
Education level, M (SD)	9.42 (3.8)	8.34 (4.1)	0.264
MMSE, M (SD)	25.19 (1.8)	24.91 (2.7)	0.599

Abbreviations: N, number of participants; M, mean; SD, standard deviation; APOE, Apolipoprotein E; MMSE, mini-mental state examination; P-values were calculated analyzing the independent t-test for continuous variables, and chi-square test for categorical variables.

Longitudinal structural MRI changes in cortical surface area and thickness

Significant longitudinal structural changes were observed in the lingual and cuneus cortices following 52 weeks of probiotic supplementation. In the test group, the left lingual surface area increased from 2971.38 ± 378.27 mm^2 at baseline to 2992.91 ± 399.67 mm^2 at 52 weeks, corresponding to a mean change of 21.53 ± 98.37 mm^2, whereas the placebo group showed a significant reduction from 2996.06 ± 346.94 mm^2 to 2941.67 ± 332.88 mm^2 (change: −54.39 ± 59.26 mm^2; between-group comparison, $P = 2.70 \times 10^{-4}$; ANCOVA-adjusted $P = 3.12 \times 10^{-4}$). Similarly, the left cuneus surface area was slightly increased in the test group (1954.50 ± 277.72 mm^2 to 1959.81 ± 281.90 mm^2; change: 5.31 ± 36.97 mm^2), whereas the placebo group demonstrated a marked reduction over time (2006.67 ± 236.29 mm^2 to 1980.39 ± 224.89 mm^2; change: −26.28 ± 39.15 mm^2). These longitudinal changes were significantly different between groups ($P = 0.001$; ANCOVA-adjusted $P = 0.002$) (Table 2 **and** Fig. 1A).

Table 2
Results of ROI between the groups at baseline and after 52 weeks

	Placebo				Test				P2	P3
	Baseline	52 weeks	Difference	P1	Baseline	52 weeks	Difference	P1		
(L) Lingual surface (mm^2)	2996.06 (346.94)	2941.67 (332.88)	-54.39 (59.26)	3.46×10^{-6}***	2971.38 (378.27)	2992.91 (399.67)	21.53 (98.37)	0.225	2.70×10^{-4}***	3.12×10^{-4}***
(L) Cuneus surface (mm^2)	2006.67 (236.29)	1980.39 (224.89)	-26.28 (39.15)	2.89×10^{-4}***	1954.50 (277.72)	1959.81 (281.90)	5.31 (36.97)	0.422	0.001**	0.002**
(L) Lingual thickness (mm)	1.99 (0.11)	2.00 (0.09)	0.01 (0.04)	0.447	1.99 (0.11)	1.95 (0.11)	-0.04 (0.07)	0.001**	0.001**	$4.02\times^{-4}$***
(L) Cuneus thickness (mm)	1.98 (0.11)	1.98 (0.11)	0.00 (0.05)	0.671	1.94 (0.11)	1.91 (0.10)	-0.03 (0.05)	0.006**	0.006**	0.005**

P1: the paired T-test between baseline and 52 weeks within each group; P2: the independent t-test for change value(post-pre/yrs) between the groups; P3: the ANCOVA adj, age, sex, baseline, icv, yrs) *P < 0.05, **P < 0.01, ***P < 0.001

In contrast to the surface area findings, cortical thickness in both regions decreased in the probiotic-treated group. The left lingual thickness decreased from 1.99 ± 0.11 mm to 1.95 ± 0.11 mm (change: −0.04 ± 0.07 mm; P = 0.001), while the placebo group exhibited a slight increase from 1.99 ± 0.11 mm to 2.00 ± 0.09 mm (change: 0.01 ± 0.04 mm). Likewise, left cuneus thickness decreased in the test group from 1.94 ± 0.11 mm to 1.91 ± 0.10 mm (change: −0.03 ± 0.05 mm; P = 0.006), whereas minimal change was observed in the placebo group (change: 0.00 ± 0.05 mm) (Table 2 **and** Fig. 1B).

Three-dimensional cortical rendering demonstrated that the lingual and cuneus regions exhibiting increased surface area in the test group were located in close anatomical proximity within the occipital cortex (Fig. 1C).

Associations between cortical structural changes and cognitive performance

Exploratory correlation analyses were performed within the test group to investigate associations between longitudinal cortical structural changes and changes in cognitive performance over 52 weeks (Fig. 2). As shown in the correlation heatmap (Fig. 2A), significant structure–function associations were predominantly observed in posterior cortical regions and were mainly related to visuospatial cognitive measures. Changes in left lingual surface area were positively correlated with changes in ROCF Copy scores (r = 0.364, P = 0.044), indicating that greater preservation or increase in lingual surface area was associated with improved visuoconstructional performance (Fig. 2B). In addition, longitudinal reductions in left cuneus cortical thickness were associated with improvements in CERAD-J5 z-scores (r = − 0.443, P = 0.013) and CERAD-J8 z-scores (r = − 0.357, P = 0.049) (Fig. 2C–D). Overall, the observed structure–function relationships were primarily linked to visuospatial and visual memory domains.

Overlap between cognitive outcomes in the parent trial and ancillary study

Cognitive assessments related to visuoconstructional and visual memory function, including ROCF Copy, CERAD-J5, and CERAD-J8, were included in both the parent randomized clinical trial and the present ancillary study (Fig. 3). These measures corresponded to the cognitive domains showing significant associations with longitudinal structural changes in the lingual and cuneus regions. In contrast, CDR scores, which showed significant changes in the parent trial, were not available in the ancillary study.

DISCUSSION

In this ancillary MRI study, 52 weeks of multistrain probiotic supplementation was associated with longitudinal structural changes in the lingual and cuneus regions. Compared with the placebo group, participants receiving probiotic supplementation showed relative preservation and modest increases in cortical surface area within these posterior cortical regions, whereas the placebo group demonstrated progressive reductions over time. In contrast, cortical thickness in the lingual and cuneus regions showed slight decreases in the probiotic group. In

addition, longitudinal structural changes in these regions were associated with visuospatial and visual memory performance, including ROCF Copy and CERAD-based cognitive measures.

The lingual gyrus and cuneus are key components of the posterior visual association cortex and have been implicated in visuospatial integration, visuoconstructional processing, and visual memory function [18]. Studies using functional and structural neuroimaging have demonstrated that these posterior cortical regions are involved in higher-order visual cognitive processes beyond primary visual perception, particularly spatial organization and visual memory retrieval [19,20]. Previous neuroimaging studies have shown that posterior cortical regions are vulnerable to structural alterations during aging and neurodegenerative processes, particularly in Alzheimer's disease and mild cognitive impairment [21,22]. Structural abnormalities involving posterior cortical systems have also been associated with visuospatial dysfunction and visual memory impairment in Alzheimer's disease-related disorders [22]. Consistent with these observations, the cognitive measures associated with longitudinal cortical structural changes in the present study, including ROCF Copy, CERAD-J5, and CERAD-J8, primarily reflect visuoconstructional and visual memory functions. The associations observed between posterior cortical structural changes and visuospatial cognitive measures in the present study are therefore consistent with the known functional roles of the lingual and cuneus regions.

Different longitudinal patterns were observed between cortical surface area and cortical thickness within the same regions. Participants in the probiotic group demonstrated relative preservation or increases in cortical surface area together with modest reductions in cortical thickness. Cortical thickness and cortical surface area represent distinct morphometric features reflecting different aspects of cortical organization and may exhibit differential longitudinal trajectories during aging and neurodegenerative progression [23,24]. Accordingly, these morphometric measures may capture different aspects of structural brain change. In addition, recent evidence indicates that localized increases in cortical thickness may also occur in Alzheimer's disease under specific biological or methodological conditions, suggesting that longitudinal cortical morphometry may not always follow a uniform degenerative pattern [25]. Therefore, the longitudinal morphometric patterns observed in the present study should be interpreted cautiously, particularly given the exploratory nature of the analysis and the relatively small sample size.

The observed structure–function relationships were primarily localized to posterior cortical regions associated with visuospatial cognition. Notably, ROCF Copy, CERAD-J5, and CERAD-J8, which demonstrated significant associations with MRI-derived structural changes in the present study, were also included among the cognitive outcomes evaluated in the parent randomized clinical trial. These overlapping findings across the independently conducted parent trial and ancillary study may support the reproducibility of the observed visuospatial cognitive associations.

Several limitations should be considered when interpreting the present findings. First, the MRI analysis was conducted in a subset of participants from the parent randomized clinical trial, resulting in a relatively modest sample size that may limit statistical power and the generalizability of the observed morphometric associations. Replication in larger neuroimaging cohorts will therefore be important to confirm the regional specificity of these findings. Second, structural MRI was obtained at baseline and at a single follow-up time point after 52 weeks of supplementation. Although this design allows comparison of interval structural differences between groups, it does not capture intermediate trajectories of cortical change or the temporal dynamics of morphometric variation. Studies incorporating multiple imaging time points would help clarify whether the observed differences reflect preservation, delayed atrophy, or transient structural variability within posterior cortical regions. Third, the present analysis focused on structural morphometry and did not include molecular neuroimaging capable of directly assessing underlying neurodegenerative processes in the brain. While the parent clinical trial reported changes in plasma biomarkers related to neurodegeneration, the absence of molecular imaging (e.g., tau or amyloid PET) limits the ability to relate structural variation to specific pathological mechanisms. Finally, because this investigation represents an ancillary neuroimaging analysis derived from the parent randomized controlled trial, certain methodological considerations described in that study—such as sample size constraints and potential cognitive retest effects—remain relevant and should be interpreted within the broader context of the original trial design [13]. Further studies incorporating larger imaging cohorts, repeated longitudinal neuroimaging assessments, and multimodal biomarker approaches may help clarify the biological and clinical significance of the observed posterior cortical structural changes.

In conclusion, long-term probiotic supplementation was associated with longitudinal structural changes in the lingual and cuneus regions in older adults with early cognitive impairment. These posterior cortical structural changes were associated with visuospatial and visual memory-related cognitive measures. Further investigation will be required to determine whether these structural alterations are reproducible and clinically relevant in larger populations.

Abbreviations

ANCOVA

analysis of covariance
APOE
apolipoprotein E
CERAD-K
Korean version of the Consortium to Establish a Registry for Alzheimer's Disease neuropsychological battery
GARD
Gwangju Alzheimer's Disease and Related Dementias cohort
MMSE
Mini–Mental State Examination
MPRAGE
magnetization-prepared rapid gradient-echo
MRI
magnetic resonance imaging
ROCF
Rey–Osterrieth Complex Figure Test
ROI
region of interest.

Declarations

Ethics approval and consent to participate

Participants in the present ancillary neuroimaging study were recruited from a previously published randomized, double-blind, placebo-controlled clinical trial. The parent clinical trial was prospectively registered with the Clinical Research Information Service (CRIS), Republic of Korea (Registration No. KCT0009453; https://cris.nih.go.kr), a WHO International Clinical Trials Registry Platform (WHO ICTRP) Primary Registry. The ancillary study received approval from the Institutional Review Board of Chonnam National University Hospital (IRB No. CNUH-2024-067) and was conducted in accordance with the principles of the Declaration of Helsinki. The parent clinical trial was approved by the same Institutional Review Board (IRB No. CNUH-2023-072), and written informed consent was obtained from all participants prior to enrollment.

Consent for publication

Not applicable

Competing interests

The author(s) declare no competing interests.

Funding

This study was supported by a grant of the Korea Health Technology R&D Project through the Korea Health Industry Development Institute (KHIDI), funded by the Ministry of Health & Welfare, Republic of Korea (grant number: RS-2022-KH129598), and research fund from Chosun University.

Author Contribution

K.H.L. and K.H.C. designed the research. S. Kim, S. Kang, and Y.Y.C. performed the statistical analyses. S. Kim, S. Kang, Y.Y.C., and K.H.L. interpreted the data. S. Kang and Y.Y.C. prepared the figures. S. Kim, S. Kang and Y.Y.C. drafted the manuscript. K.H.L., K.H.C., Y.Y.C., S. Kim, and S. Kang critically revised the manuscript for important intellectual content. All authors read and approved the final manuscript.

Acknowledgement

The authors gratefully acknowledge the members of the Gwangju Alzheimer’s & Related Dementias (GARD) cohort research group and the staff of Chonnam National University Hospital for their support in conducting this study. We also sincerely thank all study participants for their valuable contributions.

Data Availability

The datasets generated and analyzed during the current study are not publicly available due to institutional privacy regulations but are available from the corresponding author upon reasonable request.

References

1. Jack, C. R. Jr. et al. NIA-AA Research Framework: Toward a biological definition of Alzheimer's disease. *Alzheimers Dement.* **14**, 535–562. 10.1016/j.jalz.2018.02.018 (2018).
2. Scheltens, P. et al. Alzheimer's disease. *Lancet (London England)*. **397**, 1577–1590. 10.1016/s0140-6736(20)32205-4 (2021).
3. Cryan, J. F. et al. The Microbiota-Gut-Brain Axis. *Physiol. Rev.* **99**, 1877–2013. 10.1152/physrev.00018.2018 (2019).
4. Fung, T. C., Olson, C. A. & Hsiao, E. Y. Interactions between the microbiota, immune and nervous systems in health and disease. *Nat. Neurosci.* **20**, 145–155. 10.1038/nn.4476 (2017).
5. O'Riordan, K. J., Moloney, G. M., Keane, L., Clarke, G. & Cryan, J. F. The gut microbiota-immune-brain axis: Therapeutic implications. *Cell. Rep. Med.* **6**, 101982. 10.1016/j.xcrm.2025.101982 (2025).
6. Morais, L. H., Schreiber, H. L. & Mazmanian, S. K. t. The gut microbiota-brain axis in behaviour and brain disorders. *Nature reviews. Microbiology* 19, 241–255, (2021). 10.1038/s41579-020-00460-0
7. Akbari, E. et al. Effect of Probiotic Supplementation on Cognitive Function and Metabolic Status in Alzheimer's Disease: A Randomized, Double-Blind and Controlled Trial. *Front. Aging Neurosci.* **8**, 256. 10.3389/fnagi.2016.00256 (2016).
8. Zhu, G., Zhao, J., Zhang, H., Chen, W. & Wang, G. Probiotics for Mild Cognitive Impairment and Alzheimer's Disease: A Systematic Review and Meta-Analysis. *Foods* **10** 10.3390/foods10071672 (2021).
9. Leblhuber, F., Steiner, K., Schuetz, B., Fuchs, D. & Gostner, J. M. Probiotic Supplementation in Patients with Alzheimer's Dementia - An Explorative Intervention Study. *Curr. Alzheimer Res.* **15**, 1106–1113. 10.2174/1389200219666180813144834 (2018).
10. Frisoni, G. B., Fox, N. C., Jack, C. R. Jr., Scheltens, P. & Thompson, P. M. The clinical use of structural MRI in Alzheimer disease. *Nat. reviews Neurol.* **6**, 67–77. 10.1038/nrneurol.2009.215 (2010).
11. Dickerson, B. C. & Wolk, D. A. MRI cortical thickness biomarker predicts AD-like CSF and cognitive decline in normal adults. *Neurology* **78**, 84–90. 10.1212/WNL.0b013e31823efc6c (2012).
12. Hogstrom, L. J., Westlye, L. T., Walhovd, K. B. & Fjell, A. M. The structure of the cerebral cortex across adult life: age-related patterns of surface area, thickness, and gyrification. *Cerebral cortex (New York, N.Y.*:) 23, 2521–2530,) 23, 2521–2530, (1991). 10.1093/cercor/bhs231 (2013).
13. Seo, E. H. et al. Multistrain probiotics modulate tau pathology and preserve visuospatial cognition in early cognitive impairment: A double-blind, randomized, placebo-controlled trial. **0**, 13872877261477084, (2026). 10.1177/13872877261477084
14. Choi, K. Y. et al. The Gwangju Alzheimer's & Related Dementias (GARD) cohort: Over a decade of Asia's largest longitudinal multimodal study. *Alzheimers & Dementia* **22**, doi:ARTN e70981.
15. 15 1002/alz.70981 et al. Shin, M. S., Park, S. Y., Park, S. R., Seol, S. H. & Kwon, J. S. Clinical and empirical applications of the Rey-Osterrieth Complex Figure Test. *Nat Protoc* 1, 892–899, (2026). 10.1038/nprot.2006.115 (2006). 17 Lee, J. H. et al. Development of the Korean Version of the Consortium to Establish a Registry for Alzheimer's Disease Assessment Packet (CERAD-K) clinical and neuropsychological assessment batteries. 57, (2002). 18 Palejwala, A. H. et al. Anatomy and White Matter Connections of the Lingual Gyrus and Cuneus. *World Neurosurg* 151, e426-e437, doi:10.1016/j.wneu.2021.04.050 (2021). 19 Steel, A., Billings, M. M., Silson, E. H. & Robertson, C. E. A network linking scene perception and spatial memory systems in posterior cerebral cortex. *Nature communications* 12, 2632, doi:10.1038/s41467-021-22848-z (2021). 20 Xu, Y. The Posterior Parietal Cortex in Adaptive Visual Processing. *Trends in neurosciences* 41, 806–822, doi:10.1016/j.tins.2018.07.012 (2018). 21 Wu, B.-S. et al. Cortical structure and the risk for Alzheimer’s disease: a bidirectional Mendelian randomization study. 11, 476 (2021). 22 Singh, V. et al Spatial patterns of cortical thinning in mild cognitive impairment and Alzheimer's disease. *Brain* 129, 2885–2893, doi:10.1093/brain/awl256%J Brain (2006). 23 Xiong, R. M. et al. The pattern of cortical thickness underlying disruptive behaviors in Alzheimer's disease. *Psychoradiology* 2, 113–120, doi:10.1093/psyrad/kkac017 (2022). 24 Li, C. et al. Alterations of whole-brain cortical area and thickness in mild cognitive impairment

and Alzheimer's disease. *Journal of Alzheimer's disease: JAD* 27, 281–290, doi:10.3233/jad-2011-110497 (2011). 25 Phan, T. X. et al. Increased Cortical Thickness in Alzheimer's Disease. *Annals of neurology* 95, 929–940, doi:10.1002/ana.26894 (2024).

Figures

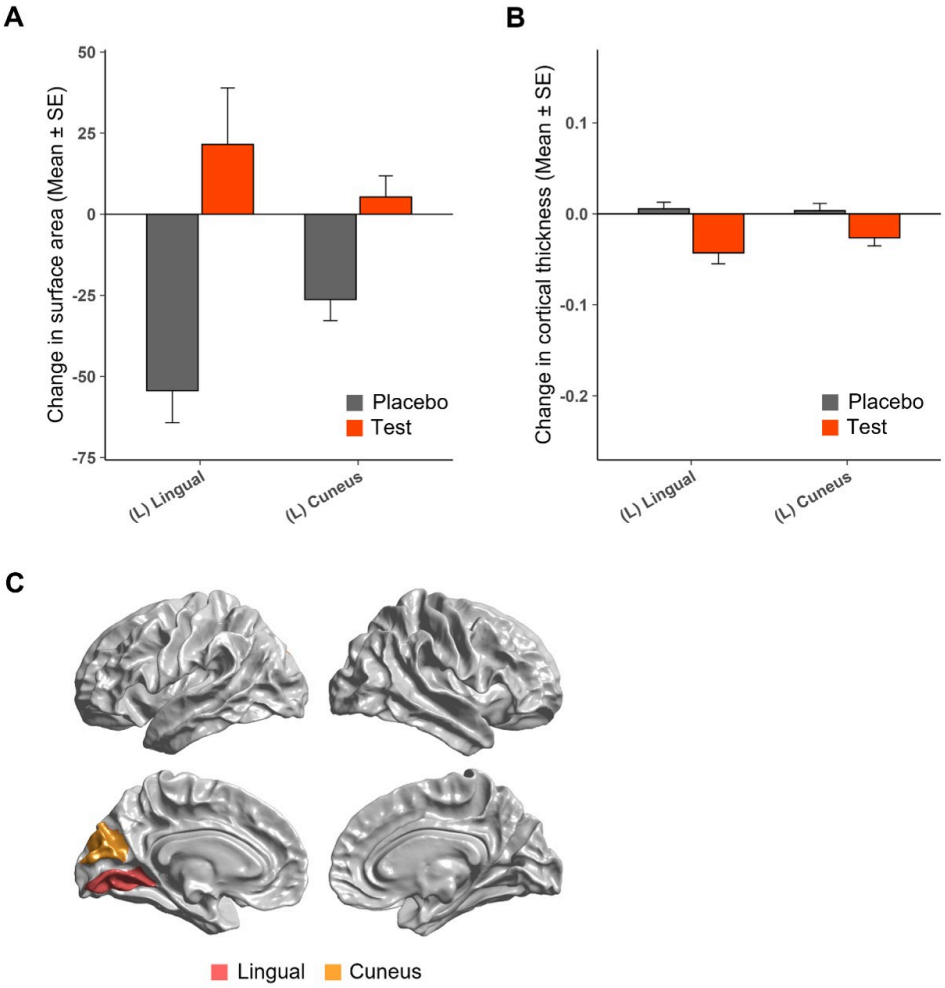

Figure 1

Figure 1

Changes in regional cortical morphology from baseline to 52 weeks in the test and placebo groups.
Bar plots (A–B) show mean changes (± SE) from baseline to 52 weeks in cortical surface area and cortical thickness in the test (red) and

placebo (grey) groups. Panel A shows changes in cortical surface area (mm²) in the left lingual and left cuneus regions. Panel B shows changes in cortical thickness (mm) in the same regions. Panel C presents cortical surface renderings indicating the anatomical locations of the left lingual and left cuneus regions of interest. Error bars indicate standard errors (SE).

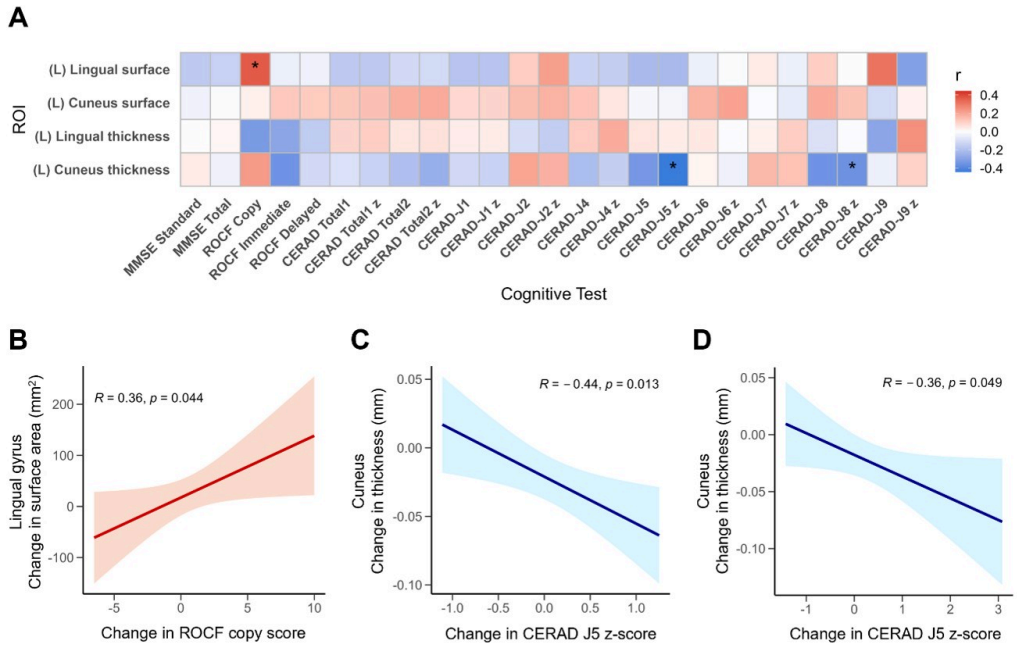

Figure 2

Figure 2

Associations between posterior cortical structural changes and cognitive performance in the test group.

Panel A shows a correlation heatmap illustrating associations between regional cortical changes and cognitive test performance within the test group (n = 31); asterisks indicate statistically significant correlations (*p < 0.05). Scatter plots (B–D) show associations between

regional structural changes and cognitive scores. Panel B shows the relationship between changes in left lingual cortical surface area and ROCF Copy scores. Panel C shows the relationship between changes in left cuneus cortical thickness and CERAD-J5 z-scores. Panel D shows the relationship between changes in left cuneus cortical thickness and CERAD-J8 z-scores. Shaded areas represent 95% confidence intervals.

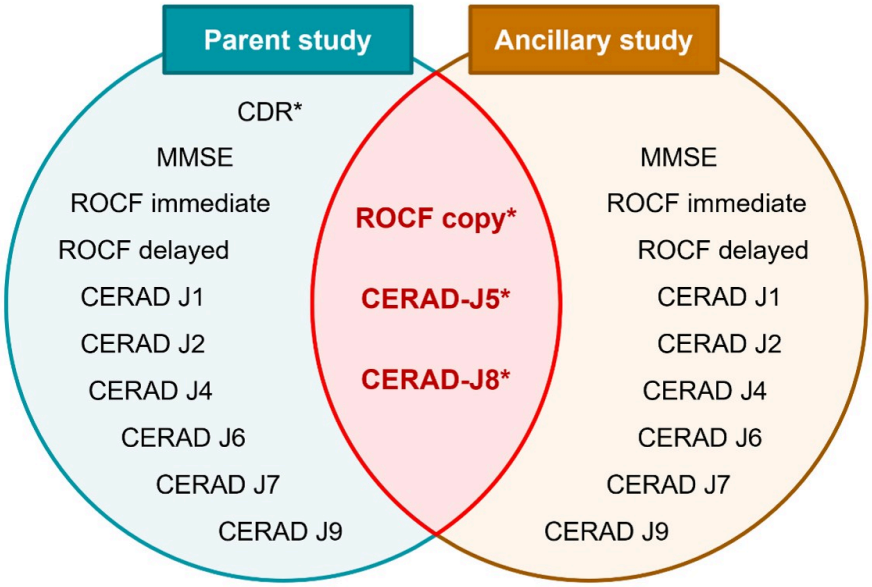

Figure 3

Figure 3

Overlap of cognitive assessments between the parent clinical trial and the ancillary neuroimaging study.

Venn diagram illustrating cognitive assessments evaluated in the parent randomized clinical trial and the ancillary neuroimaging study. The overlapping region highlights cognitive measures that showed significant improvement in both studies, specifically ROCF Copy, CERAD-J5, and CERAD-J8, which were subsequently examined in exploratory structure–function analyses. Asterisks (*) indicate cognitive measures that demonstrated statistically significant improvement in both study phases.