Research Square

Preprints are preliminary reports that have not undergone peer review. They should not be considered conclusive, used to inform clinical practice, or referenced by the media as validated information.

Malnutrition-associated reversible splenial lesion syndrome after metabolic surgery: a case report

Yun Wen
Southern Medical University Shenzhen Hospital
Mianjun Hong
Southern Medical University Shenzhen Hospital
Yonghang He
Southern Medical University Shenzhen Hospital
Bo Yi
Southern Medical University Shenzhen Hospital
Quanlian Huang
Southern Medical University Shenzhen Hospital
Ruofan Ning
Southern Medical University Shenzhen Hospital
Weiwei Ge
Southern Medical University Shenzhen Hospital
Yong Wang
wangyong123@smu.edu.cn

Southern Medical University Shenzhen Hospital

Case Report

Keywords: Reversible splenial lesion syndrome, Metabolic surgery, Malnutrition, Electrolyte disturbance, Cytotoxic lesions of the corpus callosum, Case report

Posted Date: October 15th, 2026

DOI: https://doi.org/10.21203/rs.3.rs-11009908/v1

License: This work is licensed under a Creative Commons Attribution 4.0 International License. Read Full License

Additional Declarations: No competing interests reported.

Abstract

Background

Reversible splenial lesion syndrome (RESLES) is a rare clinicoradiological entity characterized by an oval, reversible lesion in the splenium of the corpus callosum (SCC), with diagnosis relying primarily on magnetic resonance imaging (MRI). The etiologic spectrum is wide and suggests a “final common pathway” triggered by diverse systemic insults. Metabolic surgery, while effective for weight reduction, can precipitate severe malnutrition and internal environmental perturbations. Here we report a case of RESLES associated with malnutrition after sleeve gastrectomy, which is rarely described in the literature.

Case presentation

A 14-year-old female with no previous neurological disorders presented with nausea, vomiting, and oliguria one month after undergoing sleeve gastrectomy. Persistent inadequate oral intake post-surgery led to severe malnutrition, dehydration, and acute kidney injury. Laboratory evaluation revealed profound electrolyte disturbances, specifically severe hypokalemia (nadir 2.52 mmol/L), and marked azotemia (creatinine 1451.3 μmol/L). Cranial MRI demonstrated an ovoid lesion (10 × 12 mm) in the SCC with isointensity on T1-weighted images, slight hyperintensity on T2-weighted images, and restricted diffusion on DWI, consistent with RESLES. After one month of intensive treatment—including hemodialysis, fluid resuscitation, electrolyte and vitamin supplementation, and anti-infective therapy—her symptoms resolved completely, and follow-up MRI showed total resolution of the lesion without neurological sequelae.

Conclusions

Metabolic and osmotic perturbations associated with malnutrition after metabolic surgery may trigger RESLES. Timely identification and correction of the underlying causes yield a favorable prognosis. Clinicians should maintain a high index of suspicion for RESLES in post-bariatric patients presenting with neurological symptoms.

Background

Reversible splenial lesion syndrome (RESLES) is a rare clinicoradiological entity characterized by an ovoid or round lesion in the splenium of the corpus callosum (SCC), with increased signal on isotropic diffusion-weighted imaging (DWI) and abnormally low signal on apparent diffusion coefficient (ADC) maps, high signal intensity on T2-weighted imaging, and no gadolinium enhancement. The lesion typically resolves within days to weeks [1, 2]. RESLES is described under several overlapping terms, including mild encephalitis/encephalopathy with a reversible splenial lesion (MERS), transient splenial lesion or “boomerang sign,” and is often discussed within the spectrum of cytotoxic lesions of the

corpus callosum (CLOCCs)[2, 3]. Although terminology varies across disciplines, these labels converge on a shared imaging phenotype—an SCC-predominant lesion with restricted diffusion and clinical reversibility—supporting a mechanism of reversible intramyelin or glial cell edema rather than true demyelination or infarction [4].

The etiologic spectrum of RESLES is wide and suggests a “final common pathway” phenomenon triggered by different systemic insults. While infections are commonly reported, RESLES has also been observed with metabolic and electrolyte disturbances, drug- or toxin-related encephalopathy, and systemic organ dysfunction [5]. Notably, alterations in fluid balance and osmolality—either due to dehydration, rapid correction of metabolic abnormalities, or hyperosmolar therapies—have been proposed as relevant mechanistic contributors [6]. These observations support the plausibility that profound metabolic changes occurring during weight-loss and metabolic surgery may precipitate RESLES, particularly in the presence of dehydration, electrolyte shifts, renal dysfunction, or inflammatory stress.

Metabolic surgery, including sleeve gastrectomy and Roux-en-Y gastric bypass, is more effective than behavioral, dietary, or pharmacological interventions for sustained weight loss [7]. However, postoperative complications such as nausea, vomiting, and inadequate oral intake can lead to severe malnutrition, dehydration, and electrolyte imbalances. When such patients present with neurological or psychiatric symptoms, RESLES should be considered in the differential diagnosis. Here we report a case of RESLES associated with malnutrition after sleeve gastrectomy, exploring the potential mechanisms linking metabolic surgery to this rare clinicoradiological syndrome.

Case presentation

A 14-year-old female with a history of depression, hypertension, severe fatty liver disease, sleep apnea syndrome, and hyperlipidemia underwent sleeve gastrectomy for weight reduction on October 16, 2025. She had been obese for many years and had previously attempted diet and exercise with subsequent weight regain. The surgery was performed without immediate complications, and she was discharged one week postoperatively.

After discharge, the patient did not adhere to the prescribed nutritional regimen and consumed a large amount of beverages. One month later, she presented to our hospital with nausea, vomiting, and oliguria. A timeline of relevant data from the episode of care is presented in Fig. 1. On admission, her vital signs were: temperature 36.8°C, pulse rate 122 bpm, respiratory rate 16 breaths/min, and blood pressure 124/70 mmHg. Physical examination revealed mild dysarthria, hyperactive bilateral biceps and patellar reflexes (+++), and mild instability in finger-to-nose and heel-to-knee tests. Limb muscle strength was Grade V but with decreased endurance during sustained voluntary movements. No meningeal irritation signs were present.

Laboratory results on admission showed a white blood cell count of 30.86 × 10^9/L (normal range: 3.5–9.5 × 10^9/L), absolute neutrophil count 27.4 × 10^9/L (normal range: 1.8–6.3 × 10^9/L), hemoglobin 164

g/L, platelet count 546 × 10^9/L, creatine kinase 558 U/L, urea > 42.8 mmol/L, creatinine 1451.3 μmol/L, and uric acid 1600.6 μmol/L. Coagulation function and initial electrolyte levels were essentially normal. On the third day of hospitalization, serum potassium was 3.10 mmol/L (normal range: 3.5–5.5 mmol/L). Despite oral potassium supplementation, serum potassium dropped to 2.52 mmol/L on the seventh day. Subsequent oral and intravenous potassium supplementation gradually restored serum potassium levels, which normalized by the 28th day of hospitalization. Serum sodium fluctuated slightly around 135 mmol/L. After initiating hemodialysis on the ninth day post-admission, blood urea nitrogen decreased to 4.6 mmol/L and serum creatinine to 168 μmol/L. Renal function subsequently normalized. After antibiotic treatment for inflammation, blood tests returned to normal by the 9th day of hospitalization. Vitamin B1 was 12.05 ng/mL (normal range: 0.22–2.65 ng/mL), and vitamin B12 was 0.36 pg/mL (normal range: 0.18–0.914 ng/mL).

Cranial MRI revealed a localized oval lesion in the corpus callosum region, measuring approximately 10 × 12 mm, with isointensity on T1-weighted images, slight hyperintensity on T2-weighted images, and hyperintensity on DWI (Fig. 2). The lesion had well-defined borders, was centrally located, and showed no enhancement. No boomerang sign was observed. The imaging findings were classified as Type 1 RESLES (confined to the SCC).

Based on the patient's history, symptoms, laboratory tests, and cranial MRI, she was diagnosed with RESLES. She received targeted treatments including hemodialysis, anti-infective therapy, electrolyte and vitamin supplementation, and fluid replacement. The patient's symptoms improved significantly; she was able to eat independently, her mental status recovered, and laboratory test results returned to nearly normal levels. On the 46th day of hospitalization, a repeat cranial MRI revealed no evidence of the original lesion in the corpus callosum (Fig. 3). At the six-month follow-up, the patient remained stable, and repeat brain MRI showed no abnormalities (Fig. 4).

Discussion and conclusions

This case describes a 14-year-old female who developed RESLES following sleeve gastrectomy, presenting with nausea, vomiting, and oliguria, and subsequently neurological symptoms including blurred vision, diplopia, dizziness, drowsiness, and gait instability. Initial biochemical analysis revealed hemoconcentration and prerenal acute kidney injury; however, no significant electrolyte imbalances were initially detected due to the concentrated blood state. Following hemodialysis and supportive care, serum electrolyte abnormalities emerged, accompanied by neurological symptoms. Cranial MRI demonstrated findings consistent with RESLES. After one month of conservative management, the patient's clinical symptoms resolved completely, and follow-up MRI showed total resolution of the previously observed lesion.

We propose that the combination of restricted intake, intractable vomiting, and acute renal failure precipitated a cascade of metabolic insults culminating in RESLES via two synergistic pathways: osmotic stress and bioenergetic failure. First, osmotic stress plays a central role. The patient

experienced significant fluid and electrolyte shifts. As proposed by Yang et al. in the context of hyperosmolar therapy, rapid fluctuations in serum osmolality can mechanically stress the blood-brain barrier and disrupt water homeostasis in astrocytes, which express high levels of aquaporin-4 (AQP4)[4]. This disturbance facilitates the influx of water into the intracellular compartment, manifesting as cytotoxic edema on DWI. Second, severe nutritional deprivation creates a state of bioenergetic failure akin to refeeding syndrome physiology[8]. Depletion of glucose, the brain's primary fuel, alongside deficiencies in phosphate and magnesium—critical cofactors for ATP synthesis—can impair Na^+/K^+-ATPase pump function. Pump failure leads to intracellular accumulation of sodium and subsequent water retention [5]. Furthermore, energy depletion compromises the reuptake of glutamate by astrocytes, potentially triggering excitotoxicity. Cerimagic et al. suggest that this excitotoxic accumulation of glutamate, coupled with osmotic imbalance, leads to reversible intracellular swelling (CLOCCs) [3]. The splenium of the corpus callosum is particularly vulnerable to these insults due to its high density of cytokine receptors, glutamate receptors, and water channels [9]. Therefore, we hypothesize that the “metabolic storm” induced by malnutrition after weight-loss intervention acted as a systemic trigger, overwhelming the regulatory capacity of splenial cells and resulting in the transient lesion observed.

The manifestations of RESLES completely recover with effective treatment. While the manifestation of multiple sclerosis (MS)-related lesions in MRI is irreversible, the pathogenesis involves true demyelination. Acute infarctions of the corpus callosum exhibit hyperintensity on DWI sequences, followed by the formation and atrophy of glial cells eventually. Secondly, symptoms caused by MS, such as numbness in the limbs and speech disorders, do not gradually recover over time [2]. Wernicke's encephalopathy is a disease caused by vitamin B1 deficiency, with typical clinical manifestations known as the “triad”: mental and consciousness disorders, ocular motor disorders, and ataxia. MRI findings reveal bilateral symmetric abnormal signal intensity lesions primarily involving the mammillary bodies, thalamus, periventricular regions, and periventricular areas of the midbrain aqueduct[10]. In our patient, vitamin B1 and B12 levels were within normal or elevated ranges, and the lesion distribution was not typical of Wernicke's encephalopathy. The etiology of RESLES is diverse; however, these factors jointly lead to the appearance of “cytotoxic edema-like” changes in the SCC, characterized by high signal intensity on DWI and low signal intensity on ADC map. Such changes usually disappear after effective treatment, and the resulting symptoms also disappear without any serious sequelae.

After active symptomatic treatment, including hemodialysis, parenteral nutrition support, and antiemetic therapy, the patient's symptoms improved and gradually disappeared. The patient resumed enteral nutrition. Follow-up head MRI showed no abnormal findings. No hormone therapy was used in our patient. Regarding whether hormone therapy affects prognosis, opinions in the relevant literature are not unified. Future studies are needed to prove whether hormone therapy is necessary and whether it may lead to a poor prognosis [11]. The RESLES refers to a rare but distinct clinicoradiological entity characterized by the MRI presentation of a single lesion in the SCC that completely or near-completely resolves on follow-up imaging within days to weeks and has a favorable clinical outcome [2]. In the largest pediatric retrospective cohort available (130 cases), Type 1 RESLES (confined to the SCC) predominated, and all lesions resolved on follow-up MRI within 3–50 days (median ~ 8 days), with

favorable neurodevelopmental outcomes reported during follow-up [12]. Dai et al. reported disappearance of lesions around 2 weeks [13]; Watanabe et al. reported lesions disappearing in 21 days [14]; Yang et al. noted no abnormalities at 29 days of follow-up[4]. Based on imaging findings, RESLES is classified into two types according to the extent of lesion spread. Type 1 RESLES lesions are limited to the SCC, while Type 2 lesions involve extensive white matter or the entire splenium, with Type 1 being the typical form of onset[15].

When individuals undergoing weight loss experience neurological or psychiatric symptoms or epileptic-like manifestations, MRI (including DWI and ADC) should be performed as soon as possible, with simultaneous screening for electrolyte levels, blood glucose, osmolarity, liver and kidney function, and vitamin status. A follow-up MRI completes the diagnostic workup. Despite the clinical insights provided by this case, several limitations must be acknowledged. First, as a single-patient observation, the findings lack generalizability to the wider population. Second, the lack of a control group means a definitive causal relationship cannot be established. Furthermore, the retrospective nature of the report may involve reporting bias. Finally, the short follow-up may limit our understanding of long-term outcomes. Future large-scale prospective studies are warranted to validate these observations.

In conclusion, the metabolic disorders and osmotic pressure fluctuations that occur after weight-loss/metabolic intervention may trigger RESLES/CLOCCs. Diagnosis can be made through typical MRI (DWI↑, ADC↓, SCC solitary lesions) combined with follow-up reversibility. Supportive treatment focusing on correcting the underlying cause usually has a good prognosis, but caution is required to avoid misdiagnosis as infarction or demyelinating diseases, and follow-up assessment for recurrence is recommended.

Declarations

Ethics approval and consent to participate

The requirement for ethical approval was waived by the Medical Ethics Committee of Shenzhen Hospital of Southern Medical University.

Consent for publication

Written informed consent for publication of this case report and any accompanying images was obtained from the patient and her legal guardian.

Competing interests

The authors declare no competing interests.

Funding

None.

Author Contribution

Yun Wen and Mianjun Hong drafted the manuscript and collected clinical data. Yonghang He, Bo Yi, Quanlian Huang, and Ruofan Ning contributed to obtaining clinical information and preparing the figures. Weiwei Ge and Yong Wang designed the study, supervised the work, and critically revised the manuscript. All authors read and approved the final manuscript.

Acknowledgements

Not applicable.

Data availability

No datasets were generated or analyzed during the current study.

References

1. Si W, Li Y, Du G. Case report: Rare Guillain-Barré syndrome variants and mild encephalitis/encephalopathy with a reversible splenial lesion as the para-infectious manifestations of SARS-CoV-2 infection. Front Immunol. 2024;15:1458231. 10.3389/fimmu.2024.1458231.
2. Mauritz M, Kliushnikova D, Otto F, Harrer A, Moser T, Radlberger RF, et al. Case report: Reversible splenial lesion syndrome preceding the onset of multiple sclerosis. Front Immunol. 2025;15:1517719. 10.3389/fimmu.2024.1517719.
3. Cerimagic D. Iatrogenic encephalopathy or reversible splenial lesion syndrome (RESLES)? Clin Neurol Neurosurg. 2023;235:108046; 10.1016/j.clineuro.2023.108046
4. Yang Q, Chang C-C, Liu M, Yu Y-Q. Sequential occurrence of eclampsia-associated posterior reversible encephalopathy syndrome and reversible splenial lesion syndrome (a case report): proposal of a novel pathogenesis for reversible splenial lesion syndrome. BMC Med Imaging. 2019;19(1:35). 10.1186/s12880-019-0323-7.
5. Garcia-Monco JC, Cortina IE, Ferreira E, Martínez A, Ruiz L, Cabrera A, et al. Reversible splenial lesion syndrome (RESLES): what's in a name? J Neuroimaging. 2011;21 2:e1–14. 10.1111/j.1552-6569.2008.00279.x.
6. D'Acierno M, Fenton RA, Hoorn EJ. The biology of water homeostasis. Nephrol Dial Transpl. 2025;40 4:632–40. 10.1093/ndt/gfae235.
7. Arterburn DE, Telem DA, Kushner RF, Courcoulas AP. Benefits and Risks of Bariatric Surgery in Adults: A Review. JAMA. 2020;324 9:879–87. 10.1001/jama.2020.12567.

8. Chowdhary PK, Kale SA, Shukla P. Refeeding Syndrome in Haemodialysis Patients. Indian J Nephrol. 2021;32 3:271–4. 10.4103/ijn.IJN_126_20.
9. Xu Z, Zhou Z, Jang W, Tian J, Hou G. Reversible splenial lesion syndrome with mental disorders as only manifestation. BMC Neurol. 2021;21(1:356). 10.1186/s12883-021-02391-6.
10. Bento MA, Vieira JB, Silva ML, Camolas J. Case report: Wernicke-Korsakoff syndrome after bariatric surgery. Front Nutr. 2024;10:1321275. 10.3389/fnut.2023.1321275.
11. Wang H-X, Li Y-D, Liang J, Xue Y-Z, Zhu L, Xiong T-W, et al. Altitude-related features and prognosis in patients with reversible splenial lesion syndrome. Ann Med. 2024;56(1:2401107). 10.1080/07853890.2024.2401107.
12. Chen H, Yu X, Chen Y, Wu H, Wu Z, Zhong J, et al. Reversible splenial lesion syndrome in children: a retrospective study of 130 cases. Front Neurol. 2023;14:1241549. 10.3389/fneur.2023.1241549.
13. Dai P, Sun J, Yu Z, Zhang T, Wen Z, Jian T, et al. Case report: Reversible splenial lesion syndrome caused by diquat poisoning. Front Neurol. 2023;14:1178272. 10.3389/fneur.2023.1178272.
14. Watanabe T, Matsuda T, Kitagata R, Tajima I, Ono H, Hirano K, et al. Transient renal dysfunction with reversible splenial lesion. Pediatr Int. 2014;56 5:e68–71. 10.1111/ped.12412.
15. Zhang X, Chen N, Guo J, Li S, Xu J, Zhu W, et al. Reversible splenial lesion syndrome in children: clinical analysis and summary of a case series. J Int Med Res. 2020;48 4:300060520914202. 10.1177/0300060520914202.

Figures

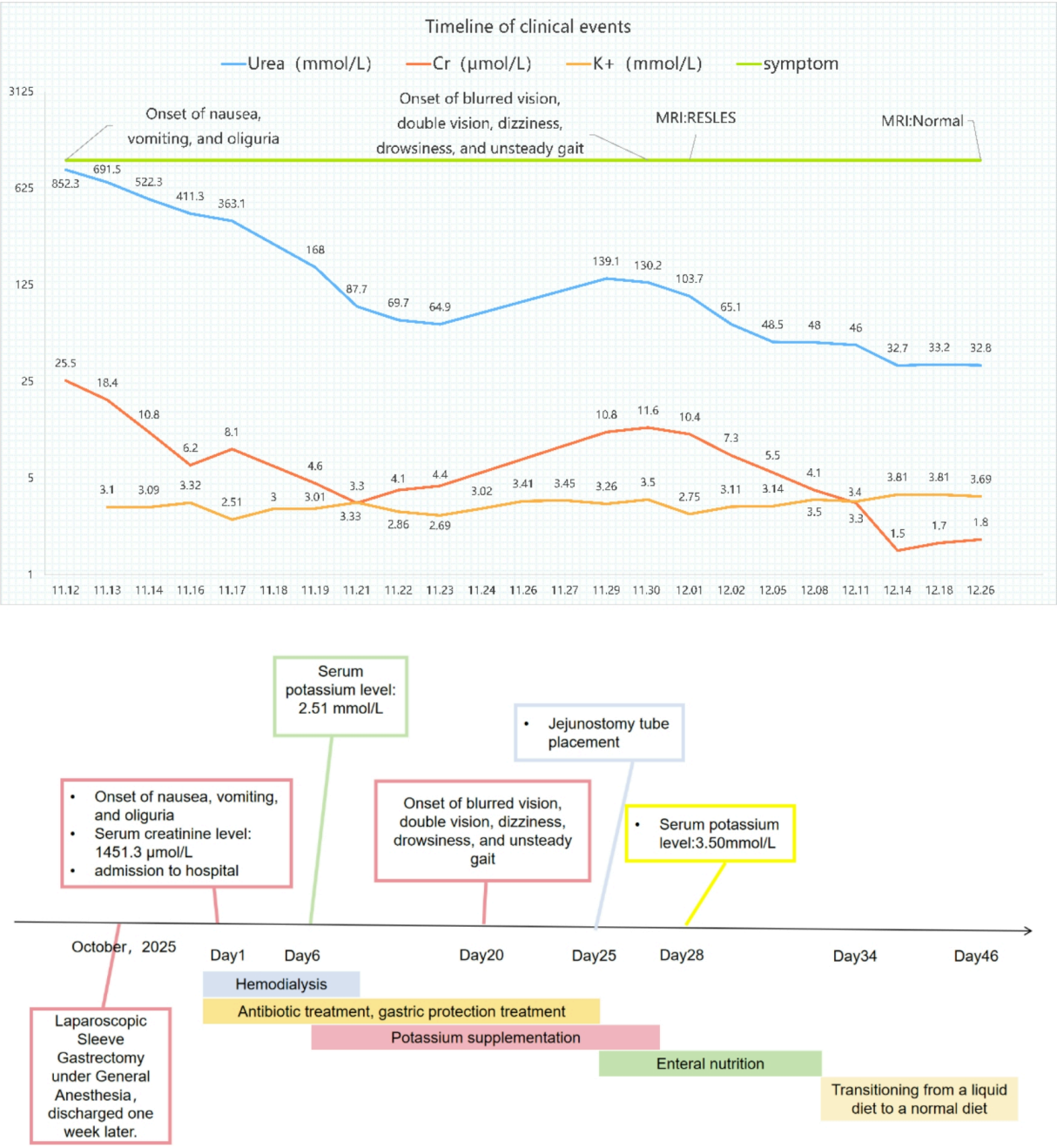

Figure 1

Timeline of clinical events. Dynamic changes in serum urea, creatinine, potassium, and clinical symptoms. Schematic overview of the clinical course and therapeutic interventions.

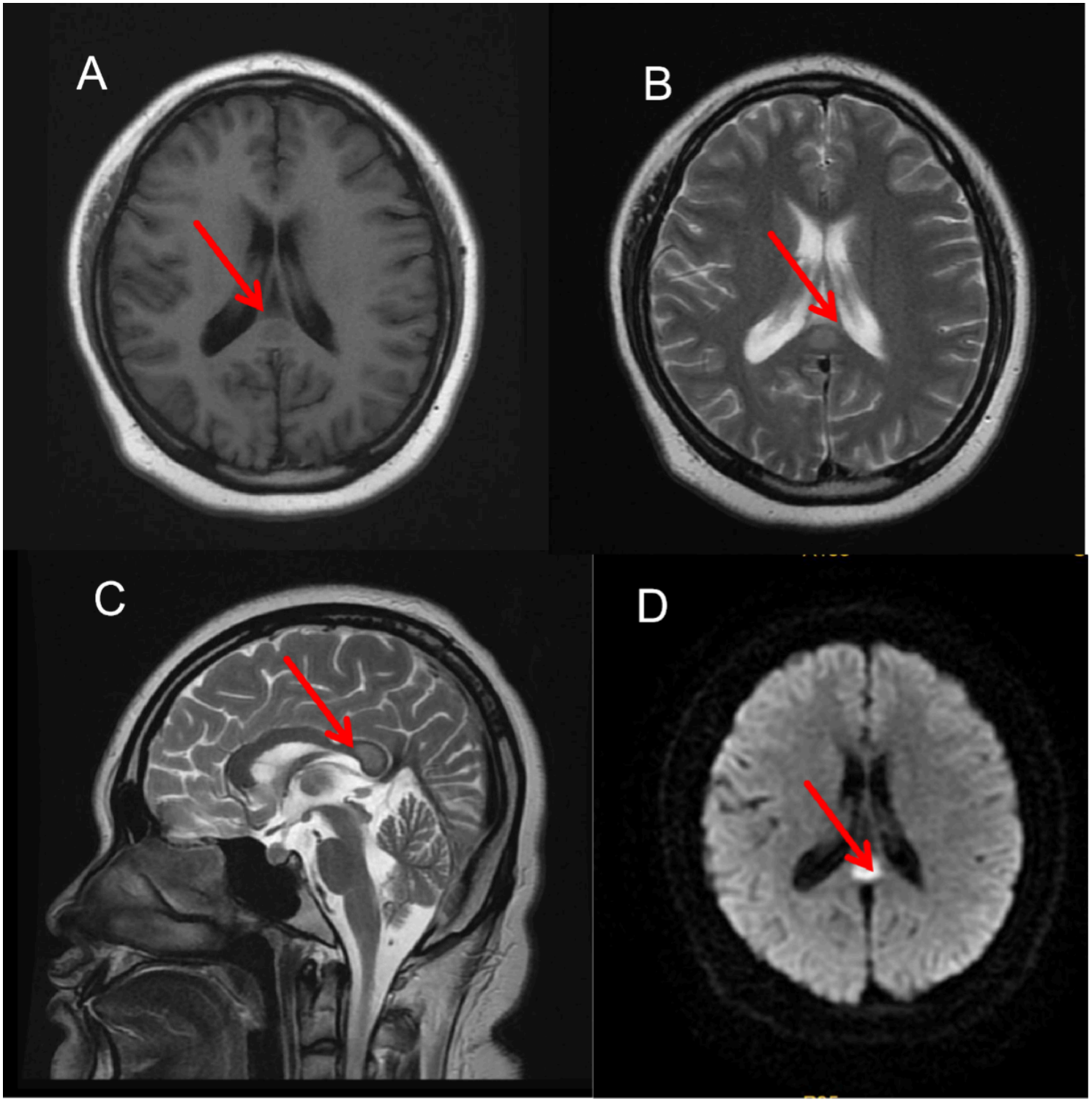

Figure 2

Cranial MRI at the onset of neurological symptoms. (A) Axial T1-weighted image (T1WI); (B) axial T2-weighted image (T2WI); (C) sagittal T2WI;(D) Diffusion-weighted image.

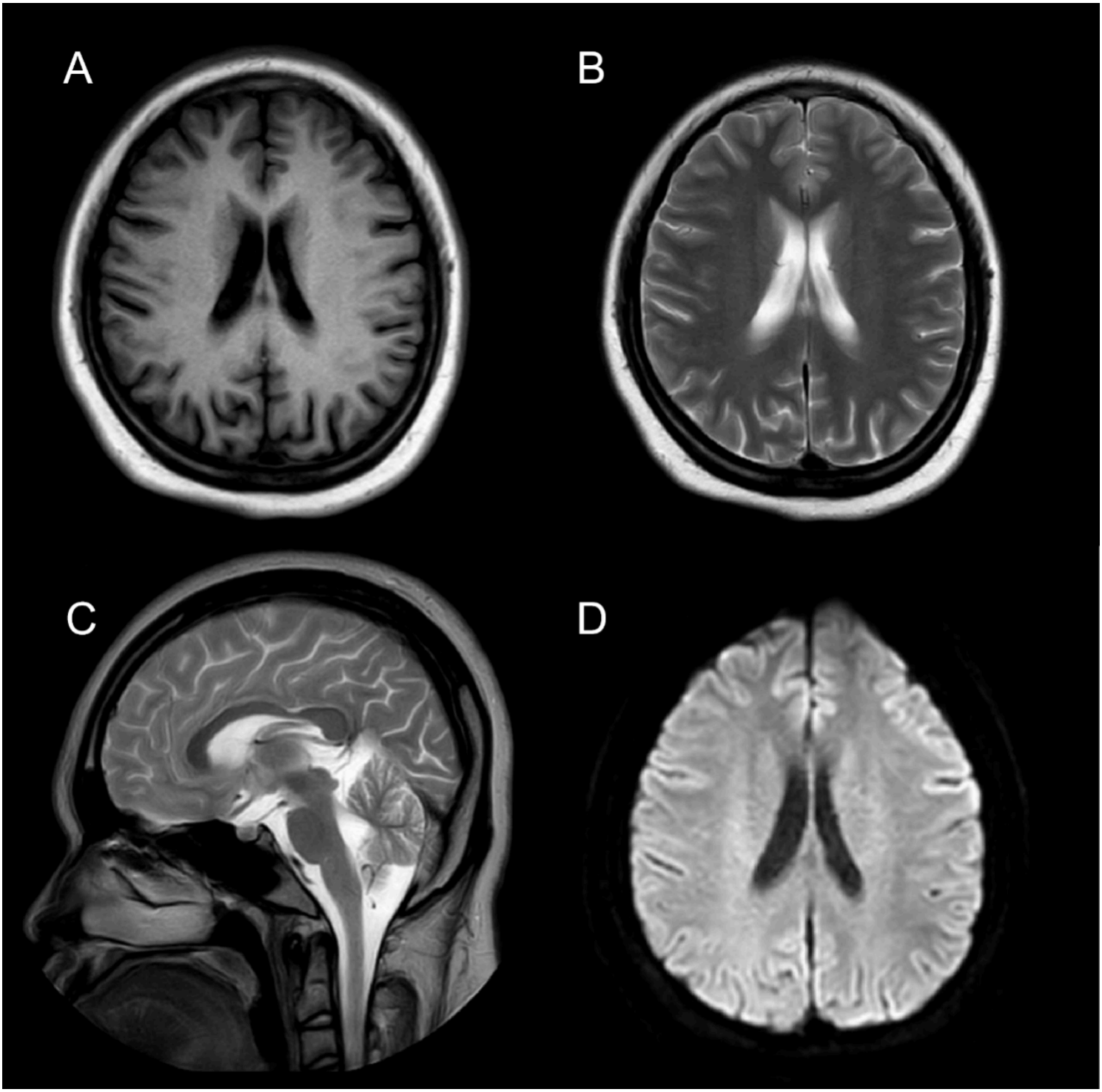

Figure 3

Follow-up cranial MRI on hospital day 46 (before discharge). (A) Axial T1WI; (B) axial T2WI; (C) sagittal T2WI; (D) DWI. The previously identified splenial lesion had completely resolved, with no residual abnormal signal or restricted diffusion, and no other significant intracranial abnormality.

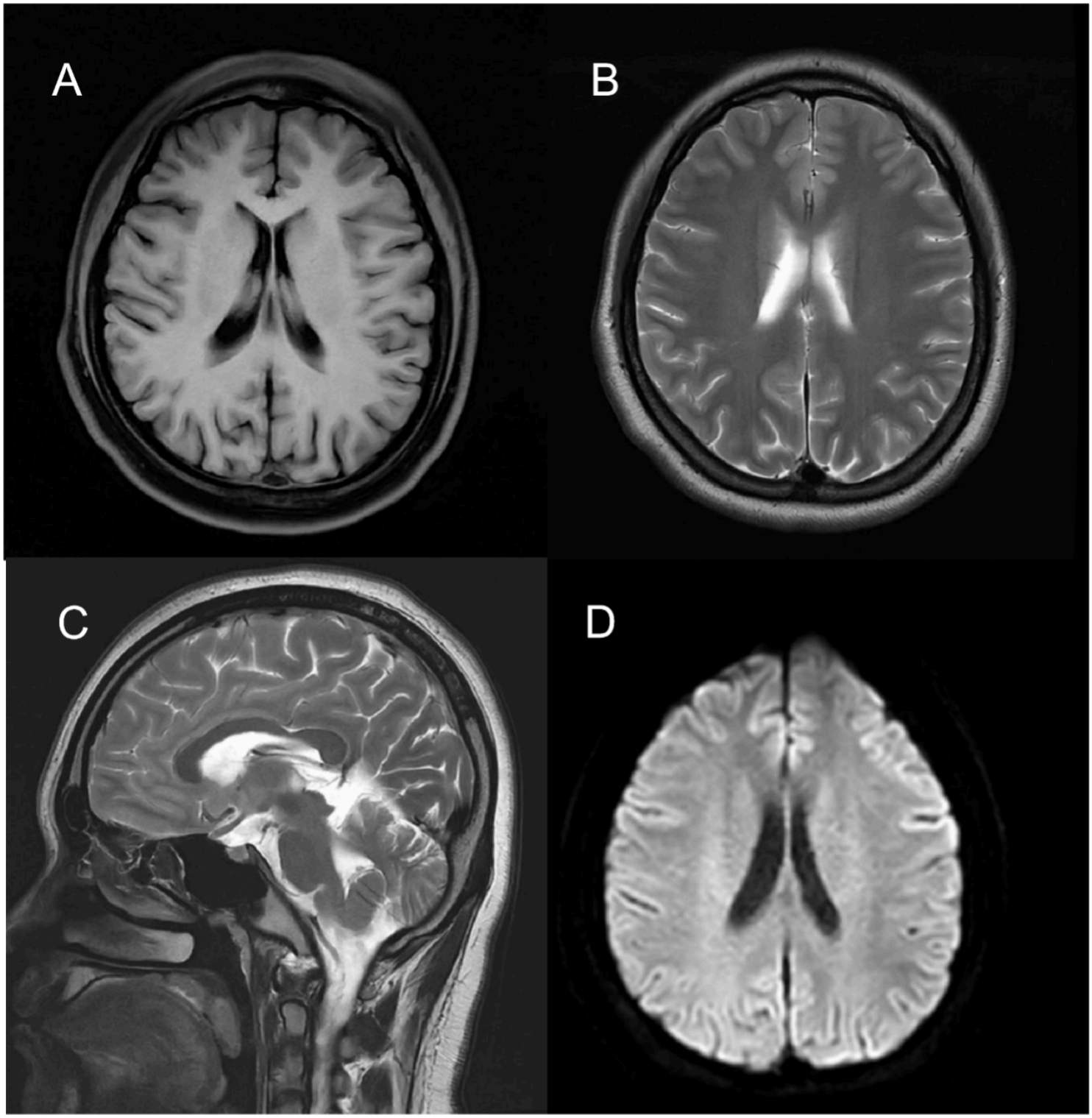

Figure 4

Cranial MRI at the 6-month follow-up.(A) Axial T1WI; (B) axial T2WI.; (C)sagittal T2WI; (D) DWI. Findings were unremarkable, showing no residual lesion or recurrence of RESLES in the corpus callosum.