Research Square

Preprints are preliminary reports that have not undergone peer review.
They should not be considered conclusive, used to inform clinical practice,
or referenced by the media as validated information.

Feasibility of Exclusive Endoscopic Transcanal Sleeve Resection of External Auditory Canal Cancer

Gerard Lapina
Yonsei University
Ludovica Battilocchi
Yonsei University
Jeong Gum Lee
Yonsei University
In Seok Moon
ismoonmd@yuhs.ac

Yonsei University

Research Article

Keywords: minimally invasive surgery, natural orifice endoscopic surgery, external auditory canal, squamous cell carcinoma

Posted Date: November 26th, 2026

DOI: https://doi.org/10.21203/rs.3.rs-10951528/v1

License: This work is licensed under a Creative Commons Attribution 4.0 International License.
Read Full License

Additional Declarations: No competing interests reported.

Feasibility of Exclusive Endoscopic Transcanal Sleeve Resection of External Auditory Canal Cancer

Gerard Lapina[1], Ludovica Battilocchi[1], Jeong Gum Lee[1], In Seok Moon[1*]

[1]Department of Otorhinolaryngology, Yonsei University College of Medicine, Seoul, Republic of Korea

***Corresponding author:** In Seok Moon, MD, PhD

Department of Otorhinolaryngology, Yonsei University College of Medicine, 50-1 Yonsei-ro, Seodaemun-gu, Seoul 03722, Republic of Korea

Tel: +82-2-2228-3626; Fax: +82-2-393-0580

Email: ismoonmd@yuhs.ac

Abstract

Objective: Sleeve resection is used to treat early-stage malignancies of the external auditory canal (EAC). The utilization of endoscopes facilitates the resection of ear canal tumors with sound oncological margins, enabling proper visualization without the need for a retroauricular incision. We analyzed the feasibility and outcomes of endoscopic sleeve resection in patients with early-stage EAC malignancies.

Study Design: Retrospective review.

Setting: Tertiary Hospital

Patients: This retrospective case series included seven patients diagnosed with early-stage EAC malignancy.

Intervention: Exclusive endoscopic transcanal sleeve resection (EETSR).

Main outcome measures: The tumor control rate, ear canal patency, tympanic membrane status, and hearing outcome data were collected and analyzed postoperatively.

Results: All patients underwent complete resection without any major complications, and no recurrences were observed on video-otoscopy or postoperative magnetic resonance imaging (MRI). Tympanic membrane damage was not encountered, and the patency of the ear canal was well maintained. Hearing thresholds did not deteriorate postoperatively.

Conclusion: Endoscopic sleeve resection can markedly improve quality of life with a tumor control rate similar to that of lateral temporal bone resection in early-stage cancer.

Keywords: minimally invasive surgery, natural orifice endoscopic surgery, external auditory canal, squamous cell carcinoma

Introduction

Primary malignancies affecting the external auditory canal (EAC) are rare but potentially life-threatening, with an annual occurrence of 1–6 per million worldwide [1]. The most common histological type is squamous cell carcinoma, which accounts for only 0.2% of all head and neck malignancies [2]. The complex anatomy of the EAC and temporal bone, coupled with the invasive nature of this disease, has resulted in poor prognosis in these patients, especially in advanced cases [3].

Traditionally, early diagnosis of EAC malignancy has been challenging because of its rarity and non-specific early symptoms, such as otalgia, otorrhea, and/or hearing loss [4]. However, in recent years, there has been a growing trend towards early detection and less invasive management options for EAC malignancy due to increased awareness among the otolaryngological community and recent advances in otoendoscopy coupled with better imaging techniques, such as magnetic resonance imaging (MRI) [5]. According to the Modified Pittsburgh classification, early-stage EAC malignancies are classified as T1 or T2 tumors.

The recommended treatment options for this cancer stage include en-bloc sleeve resection, especially for T1 tumors, and lateral temporal bone resection (LTBR) for T1 or T2 tumors [6]. However, the latter entails a cul-de-sac procedure for the EAC and has hearing and cosmetic disadvantages [7]. Classical microscopic sleeve resection techniques involve post-auricular incisions [8, 9].

In the last decade, there has been a rapid increase in performing endoscopic ear surgery to manage middle ear and lateral skull base diseases in children and adults. However, there is little evidence for its utility for malignant neoplasms in the EAC [10]. Therefore, we evaluated the utility and feasibility of endoscopy for sleeve resection of EAC primary malignancies.

Materials and Methods

This retrospective study included patients with pathologically confirmed EAC malignancy who underwent endoscopic sleeve resection by a senior surgeon (In Seok Moon) between April 2016 and June 2023. Locoregional and distant metastases were also ruled out in all patients using preoperative

positron emission tomography (PET) scans. Exclusive endoscopic transcanal sleeve resection (EETSR) for EAC malignancy was performed in seven patients. Postoperative surveillance was performed via endoscopy and MRI.

Surgical technique

The sleeve resection technique was adapted from a previous study [8]. A 0-degree endoscope with a 3 mm diameter and 14 cm length (Stryker, Kalamazoo, USA) was used for all patients. It was connected to an endoscopy tower system (Visera 4 K UHD OTV-S400; Olympus Europe SE & Co. KG, Hamburg, Germany) and projected onto a 55-inch 4 K 2D LCD medical monitor (LMD-X550MD, Sony, Tokyo, Japan). An endoscope was used exclusively for resection, as shown in Figure 1 and Video Supplement 1.

The medial boundary for surgical resection was the tympanic membrane, and an adequate margin was ensured via direct endoscopic visualization and confirmed with a frozen section. After removing the specimen (Figure 2), drilling of the EAC bone underlying the tumor was performed to achieve further margins (Video Supplement 1). The exposed bone was then covered with an acellular dermal matrix (MegaDerm; L&C BIO Inc., Seongnam, Korea) and healed well after several months (Figure 3).

Results

Endoscopic sleeve resection was performed in seven patients with EAC malignancies during the study period. All tumors were successfully excised en bloc, and the final specimen is shown in Figure 2. No major intraoperative or immediate postoperative complications were observed. The median age of patients who underwent surgical excision was 72.3 years. Squamous cell carcinoma was histopathologically confirmed in all patients before endoscopic sleeve resection. Our series included four males and three females.

Throughout the follow-up period (3–38 months), no recurrence was detected in any patient. The patient with the longest follow-up period (38 months) showed complete resection with no signs of

recurrence upon surveillance, as observed in the video otoscopy performed before surgery and 37 months postoperatively (Figure 3).

None of the surgeries resulted in unintentional tympanic membrane damage, and the patients maintained their hearing thresholds before and after the procedure (Table 1). However, in patient nº6, the tympanic membrane had to be sacrificed as the tumor was just adjacent to it. This was immediately reconstructed using acellular dermal matrix. No cases of iatrogenic facial nerve paralysis were observed.

Discussion

Despite the rarity of EAC malignancy and the paucity of guidelines, local tumor extension is a crucial prognostic factor for this disease [11]. Our study also suggested that patients with T1 disease have a relatively good prognosis when adequate local disease control is achieved. In our preliminary results of patients followed up during a period of 3–38 months, none showed residual or recurrent disease. This is comparable with previous studies showing that the 2-year disease-free survival rate of patients with T1 or T2 disease ranges from 80% to100% [12, 13].

Management of early-stage EAC malignancy is centered on sleeve resection or LTBR via a retroauricular approach with the aid of a microscope [14], which results in an overall survival rate of 77%–100% [15-17]. However, few studies have emphasized the importance of preserving hearing function in patients undergoing LTBR and cul-de-sac closure of the EAC. This approach results in conductive hearing loss and may affect patients' quality of life [17]. Fujita et al. attempted to preclude cul-de-sac closure after LTBR and reconstruct the ear canal with a full-thickness skin graft.

However, some patients experienced chronic granulation, lateralization of the tympanic membrane, otorrhea, and/or stenosis [18]. In patient nº3, the malignancy was found only in the hearing ear. Hence, the hearing status needed to be preserved and achieved with EETSR. Another circumstance in which this minimally invasive approach was deemed advantageous was in patient nº5, who had many comorbidities that did not make the patient a good candidate for general anesthesia; the procedure was successfully performed under local anesthesia with no issues encountered. In our series, most patients had a good postoperative recovery and only one experienced transient ear canal stenosis that resolved

after meatal packing and 2 months of ear mold application.

Recently, there has been an increasing trend towards utilizing endoscopes for managing ear diseases, and indications are constantly evolving into a wider field [19]. The authors maximized the advantages of the endoscopic approach established in previous studies, such as improved visualization of the tumor and its margins while maintaining minimal access[20, 21]. Oncological margins were achieved while maintaining the structural integrity of the tympanic membrane in 6 out of the 7 patients. Of note, the tympanic membrane was intentionally sacrificed in 1 patient because of the tumor's proximity to it but was easily reconstructed using acellular dermal matrix and had good healing post-operatively. Based on the textbook by Gopen, the tympanic membrane in sleeve resection could either be preserved, resected, or superficial layer stripped depending on the pathology [22]. Additionally, the authors also decided to adhere to the principle that the minimum margin in managing squamous cell carcinoma should be 5mm making it necessary to sacrifice the tympanic membrane in special circumstances wherein the tumor is too near to it [23]. Hence, the endoscope has facilitated both the preservation and/or reconstruction of the TM resulting to hearing preservation as the computed pure-tone averages were similar postoperatively.

In addition, the patency of the ear canal was maintained, which was cosmetically acceptable after surgery. Our series demonstrated that endoscopic sleeve resection is feasible for achieving adequate oncologic control of early-stage EAC cancer while maintaining structural and functional anatomy. One limitation of this study is the rarity of the disease, which is why the authors suggest a multicenter prospective study that will further strengthen the body of evidence in utilizing this approach for early-stage EAC malignancies.

In conclusion, managing early EAC malignancies is shifting towards early detection and minimally invasive management. This transformative approach can improve the prognosis, preserve auditory function, and enhance the quality of life of patients affected by this rare but significant disease.

Declarations

Ethics approval and consent to participate

This study was approved by the Institutional Review Board of Yonsei University College of Medicine, Severance Hospital (IRB No. 4-2023-1051) and was conducted in accordance with the Declaration of Helsinki. Due to the retrospective nature of the study, the requirement for informed consent was waived by the Institutional Review Board of Yonsei University College of Medicine, Severance Hospital.

Consent for publication

Not applicable. The clinical images and surgical video included in this article do not contain any identifiable patient information.

Availability of data and materials

The datasets used and/or analysed during the current study are available from the corresponding author on reasonable request.

Competing interests

The authors declare that they have no competing interests.

Funding

This research was supported by the National Research Foundation of Korea (NRF) (grant number RS-2023-00253371) awarded to In Seok Moon.

Authors' contributions

GL, LB, JGL and ISM contributed equally to this work, including study conception and design, data collection, analysis and interpretation, and drafting and critical revision of the manuscript. All authors read and approved the final manuscript.

REFERENCES

1. Lohnherr, V., et al., *Long-term analysis of prognostic risk factors impacting surgical outcomes in patients with external auditory canal carcinoma.* Eur Arch Otorhinolaryngol, 2023. **280**(6): p. 2965-2974.
2. Ouaz, K., et al., *Cancer of the external auditory canal.* Eur Ann Otorhinolaryngol Head Neck Dis, 2013. **130**(4): p. 175-82.
3. Lobo, D., J.L. Llorente, and C. Suarez, *Squamous cell carcinoma of the external auditory canal.* Skull Base, 2008. **18**(3): p. 167-72.
4. Gidley, P.W., *Managing malignancies of the external auditory canal.* Expert Rev Anticancer Ther, 2009. **9**(9): p. 1277-82.
5. Hashi, N., et al., *The role of radiotherapy in treating squamous cell carcinoma of the external auditory canal, especially in early stages of disease.* Radiother Oncol, 2000. **56**(2): p. 221-5.
6. Allanson, B.M., et al., *Squamous Cell Carcinoma of the External Auditory Canal and Temporal Bone: An Update.* Head Neck Pathol, 2018. **12**(3): p. 407-418.
7. You, P., et al., *Quality of Life After Modified Rambo Ear Canal Closure in Pediatric and Adult Patients.* Otolaryngol Head Neck Surg, 2023. **168**(4): p. 814-820.
8. Gal, T.J., et al., *Reconstruction after temporal bone resection.* Laryngoscope, 1998. **108**(4 Pt 1): p. 476-81.
9. Shiga, K., et al., *Multi-institutional Survey of Squamous Cell Carcinoma of the External Auditory Canal in Japan.* Laryngoscope, 2021. **131**(3): p. E870-E874.
10. Emre, I.E., et al., *Endoscopic ear surgery.* J Otol, 2020. **15**(1): p. 27-32.
11. Ito, M., M. Hatano, and T. Yoshizaki, *Prognostic factors for squamous cell carcinoma of the temporal bone: extensive bone involvement or extensive soft tissue involvement?* Acta Otolaryngol, 2009. **129**(11): p. 1313-9.
12. Chang, C.H., et al., *Treatments and outcomes of malignant tumors of external auditory canal.* Am J Otolaryngol, 2009. **30**(1): p. 44-8.
13. Moody, S.A., B.E. Hirsch, and E.N. Myers, *Squamous cell carcinoma of the external auditory*

canal: an evaluation of a staging system. Am J Otol, 2000. **21**(4): p. 582-8.

14. Mehta, G.U., et al., *Temporal bone resection for lateral skull-base malignancies.* J Neurooncol, 2020. **150**(3): p. 437-444.

15. Kunst, H., J.P. Lavieille, and H. Marres, *Squamous cell carcinoma of the temporal bone: results and management.* Otol Neurotol, 2008. **29**(4): p. 549-52.

16. Nyrop, M. and A. Grontved, *Cancer of the external auditory canal.* Arch Otolaryngol Head Neck Surg, 2002. **128**(7): p. 834-7.

17. Oya, R., et al., *Surgery With or Without Postoperative Radiation Therapy for Early-stage External Auditory Canal Squamous Cell Carcinoma: A Meta-analysis.* Otol Neurotol, 2017. **38**(9): p. 1333-1338.

18. Fujita, T., et al., *Reconstruction of the external auditory canal using full-thickness rolled-up skin graft after lateral temporal bone resection for T1 and T2 external auditory canal cancer.* Auris Nasus Larynx, 2021. **48**(5): p. 830-833.

19. Nogueira, J.F., et al., *Future of Endoscopic Ear Surgery.* Otolaryngol Clin North Am, 2021. **54**(1): p. 221-231.

20. Nair, S. and J.G. Aishwarya, *Endoscopic Ear Surgery: Our Experience.* Indian J Otolaryngol Head Neck Surg, 2022. **74**(Suppl 1): p. 263-271.

21. Preyer, S. and P. Agha-Mir-Salim, *[Endoscopic ear surgery-more than a complement to the microscope?].* HNO, 2021. **69**(10): p. 777-778.

22. Gopen Q. *Fundamental Otology Pediatric & Adult Practice.* Jaypee Brothers Medical Publishers, 2013 p. 382

23. Stratigos, A., et al., *Diagnosis and treatment of invasive squamous cell carcinoma of the skin: European consensus-based interdisciplinary guideline.* Eur J Cancer, 2015. **51**(14): p. 1989-2007.

Figure legends

Figure 1. Schematic drawing of the procedure.

Figure 2. Surgical specimen of the external auditory canal epithelium removed en-bloc.

Figure 3. A: Pre-operative view of tumor on the left. B: Postoperative view of EAC (36 months) upon follow-up.

*(*tumor)*

List of Supplemental Digital Content

Video Supplement 1. Surgical Video of 2 cases

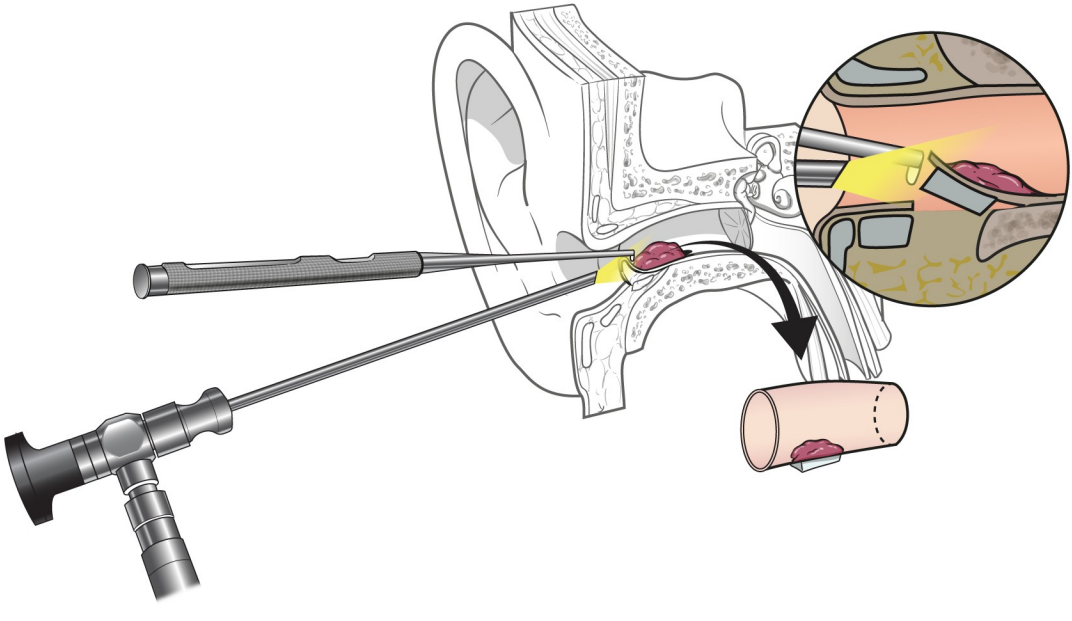


Rt. EAC
3
4
5
6
7
8
9
10
11
12
laus
Sterile Surgical Rul
2
3
4

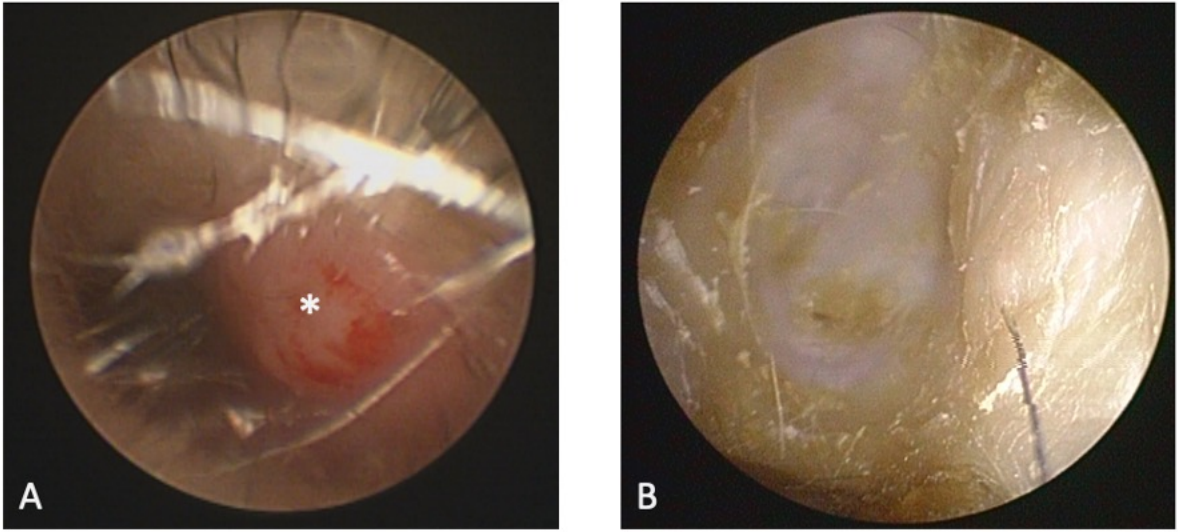
A
*
B

Table 1. Patient demographics and surgical outcomes

Patient	Pittsburgh stage (T)	Pathology	Tumor resection	Facial palsy	PTA pre-op (dB)	PTA post-op (dB)	Postoperative drum status	Postoperative EAC status	Recurrence	Follow-up period
1	I	SCC	Complete	None	26	25	Intact	Intact	None	38
2	I	SCC	Complete	None	46	50	Intact	Intact	None	14
3	I	SCC	Complete	None	20	23	Intact	Intact	None	13
4	I	SCC	Complete	None	25	27	Intact	Intact	None	9
5	I	SCC	Complete	None	14	18	Intact	Intact	None	6
6	I	SCC	Complete	None	10	17	Intact	Intact	None	3
7	I	SCC	Complete	None	25	24	Intact	Intact	None	3

Supplementary Files

This is a list of supplementary files associated with this preprint. Click to download.

- Videosupplement1.mp4