Research Square

Preprints are preliminary reports that have not undergone peer review.
They should not be considered conclusive, used to inform clinical practice,
or referenced by the media as validated information.

Extranodal Rosai Dorfman Disease: An Unusual Course Without Nodal or Systemic Involvement- Case report

Vadisha Bhat

vadishbhat@nitte.edu.in

Nitte (Deemed to be University), KS Hegde Medical Academy

Biniyam Kolathingal

Nitte (Deemed to be University), KS Hegde Medical Academy

Sanabel Gloria D'souza

Nitte (Deemed to be University), KS Hegde Medical Academy

Shubha P bhat

Nitte (Deemed to be University), KS Hegde Medical Academy

Case Report

Keywords: Rosai Dorfman disease, Extranodal, nasal cavity, Epistaxis, Eyelid

Posted Date: September 24th, 2026

DOI: https://doi.org/10.21203/rs.3.rs-10927389/v1

License: This work is licensed under a Creative Commons Attribution 4.0 International License.
Read Full License

Additional Declarations: No competing interests reported.

Abstract

Introduction:

Rosai–Dorfman disease (RDD) is a rare benign non-Langerhans cell histiocytic disorder that typically presents with painless cervical lymphadenopathy. Isolated extranodal disease involving the head and neck is uncommon, while recurrent multifocal disease without nodal or systemic involvement is exceptionally rare. We report a unique case of recurrent multifocal extranodal RDD confined to the sinonasal tract and eyelid.

Case Report:

A woman in her late 50s presented with recurrent nasal obstruction and epistaxis. Evaluation revealed a mass in the right nasal cavity, which was excised endoscopically. Histopathological examination established the diagnosis of extranodal RDD. During a 3-year follow-up, she experienced sequential recurrences involving the contralateral nasal cavity, nasal septum, anterior ethmoid sinus, and left lower eyelid. Each lesion was managed successfully with complete surgical excision, and histopathology consistently confirmed recurrent RDD. Despite multifocal recurrences, there was no evidence of cervical lymphadenopathy, systemic symptoms, or radiological features of aggressive disease. The patient remained symptom-free following each surgery and did not require systemic therapy.

Conclusion

This case highlights an unusual presentation of recurrent multifocal extranodal RDD involving the sinonasal tract and eyelid in the absence of nodal or systemic disease. Although recurrence is uncommon, RDD should be considered in the differential diagnosis of recurrent sinonasal masses. Histopathological confirmation remains essential for diagnosis, and complete surgical excision can provide excellent long-term disease control in patients with localized recurrent extranodal disease, avoiding the need for systemic treatment.

Introduction

Rosai–Dorfman disease (RDD) is an uncommon histiocytic disorder, historically referred to as sinus histiocytosis with massive lymphadenopathy (SHML). This condition was first noted by Destombes in 1965 and later defined by Rosai and Dorfman in 1969, who described its hallmark presentation and established its initial nomenclature.[1,2] The 1987 Working Group of the Histiocyte Society subsequently categorized RDD as a form of non-Langerhans cell histiocytosis. Despite extensive study, its etiology and underlying pathogenesis remain poorly understood, and it is considered a benign, non-neoplastic proliferative disorder.[3] Classically, RDD manifests as painless, massive, bilateral cervical lymphadenopathy, often accompanied by systemic features such as fever, leukocytosis, elevated

erythrocyte sedimentation rate, and polyclonal hypergammaglobulinemia.[4] Although it predominantly affects children and adolescents, cases have been documented across all age groups. While cervical lymph nodes are the most frequently involved, the disease may affect other peripheral or central nodal regions.

Extranodal manifestations occur in approximately 43% of cases and commonly involve the nasal and oral cavities, tonsils, salivary glands, orbit, and skin.[2] The incidence of extranodal involvement ranges from 28% to 43%, with the skin and subcutaneous tissue being the most common sites.[3] Nasal and/or paranasal sinus involvement is found to be relatively rare (18%).[5] The clinical course is variable; although many patients experience spontaneous remission, others may develop recurrent or persistent disease, and rarely, involvement of vital organs can lead to significant complications.

Diagnosis relies on histopathological evaluation, characterized by sheets of large histiocytes exhibiting emperipolesis, with intact lymphocytes or erythrocytes within their cytoplasm.[5] Immunohistochemistry further aids diagnosis: histiocytes typically express S-100 protein and CD68, but lack CD1a, distinguishing RDD from Langerhans cell histiocytosis.

We report a case of a middle-aged woman who presented to our department with nasal obstruction and recurrent epistaxis and was diagnosed with extranodal Rosai Dorfman Disease.

Case presentation

A middle-aged woman in her late 50s presented to our department in the year 2023 with complaints of right-sided nasal obstruction and recurrent episodes of epistaxis. Nasal examination revealed a normal external nasal contour. Anterior rhinoscopy demonstrated a pink, polypoidal mass occupying the right nasal cavity. Clinically, a diagnosis of Angiomatous polyp was made. Contrast-enhanced CT(CECT) of the nose and paranasal sinuses revealed a well-defined, enhancing soft-tissue lesion in the right anterior nasal cavity causing near-total obstruction, abutting the middle turbinate and nasal septum without evidence of bony erosion or intracranial extension. (Fig. 1)

She underwent coblator-assisted endoscopic excision of the mass under general anesthesia. The polypoidal mass arising from the anterior nasal septum and the anterior end of the inferior turbinate was identified and completely excised. Histopathology revealed sheets of large histiocytes exhibiting emperipolesis within a mixed inflammatory background, suggestive of Rosai–Dorfman disease (RDD). (Fig. 2) Her postoperative recovery was uneventful, and she was on regular follow-up.

One year later, in 2024, she returned with new-onset left-sided nasal obstruction and recurrent epistaxis occurring two to three times per week. Examination revealed a Polypoidal mass in the left nasal cavity, obscuring the left inferior turbinate. CECT demonstrated a Lobulated soft tissue density lesion along the nasal septum, filling in both nasal cavities, with obliteration of the right middle meatus and extending into the right anterior ethmoid cells, causing bowing of the ethmoid sinus walls. (Fig. 3)

She underwent Endoscopic excision of the mass involving the right middle meatus, anterior ethmoid, along with a left-sided lesion infiltrating the cartilaginous and bony septum. The mass was excised using a Coblator along with the upper one-third of the cartilaginous and bony septum. Histopathology confirmed RDD. The postoperative course was uneventful, with complete resolution of her symptoms.

In mid-2025, she developed a new complaint of a gradually progressive, painless swelling of the left lower eyelid. Examination showed a 1.5 cm × 1 cm firm, mobile, non-tender cystic lesion below the eyelid margin, without lymphadenopathy or ocular movement restriction. (Fig. 4)

Ultrasonography of the orbit revealed a well-defined cystic lesion within the soft tissue plane. The swelling was excised under local anesthesia, and histopathology demonstrated features consistent with RDD, indicating a new extranodal site of involvement. (Fig. 5a, 5b)

Her most recent presentation occurred in October 2025 with bilateral epistaxis over three days, each episode lasting approximately 5 minutes. Nasal examination revealed a Polypoidal reddish mass seen arising from the right inferior turbinate and corresponding nasal septum. (Fig. 6a). She underwent coblator-assisted endoscopic excision under general anesthesia. Friable mass seen arising from the remaining part of the nasal septum, the inferior turbinate, and the floor of the nasal cavity. Histopathological examination once again confirmed RDD. She recovered well postoperatively, and follow-up endoscopy demonstrated healthy, well-healed nasal cavities. (Fig. 6b). She has been on regular follow-up for the past 8 months, without any evidence of local recurrence.

Across these three years, the patient exhibited multifocal, relapsing extranodal Rosai–Dorfman disease with sequential involvement of the nasal cavity, paranasal sinuses, and eyelid.

Discussion

Rosai–Dorfman disease (RDD) is a rare, non-Langerhans cell histiocytosis that classically presents with massive, painless cervical lymphadenopathy and characteristic histiocytes demonstrating emperipolesis. [1-2] Extranodal involvement occurs in approximately 40% of cases and is often more fibrotic, less cellular, and typically limited to a single anatomical site. [3,4] In contrast, the present case demonstrates an exceptionally rare pattern of multifocal, progressive, and relapsing extranodal RDD involving the nasal cavity, paranasal sinuses, nasal septum, and eyelid over three years, an evolution seldom reported in literature.

Classically, RDD affects younger individuals and is frequently associated with systemic symptoms such as fever, leukocytosis, and elevated ESR. However, our patient—a woman in her late 50s—remained systemically asymptomatic at all presentations, with no lymphadenopathy or organ involvement. This sharply deviates from the typical nodal RDD and aligns with the less common, isolated extranodal phenotype.[3,4] The absence of systemic involvement despite repeated recurrences contrasts with

published cases, in which multifocal or relapsing disease frequently coexists with immune dysregulation or hematologic abnormalities.[4,7]

Sinonasal RDD itself is uncommon, but when present, it typically appears as a unilateral mass causing nasal obstruction or epistaxis and usually responds well to excision. Recurrence after complete removal is reported but remains infrequent.[6] The bilateral progression, repeated relapses, and eventual development of a new extranodal site (eyelid) in this patient represent an unusual migratory disease pattern. Orbital or eyelid involvement in RDD is documented but is usually a primary ophthalmic manifestation or occurs in the setting of disseminated disease.[8] Thus, sequential evolution from unilateral sinonasal disease → bilateral sinonasal disease → eyelid involvement, as seen here, is extremely rare and expands the known clinical spectrum of extranodal RDD.

Radiologically, the progressive extension into bilateral nasal cavities and anterior ethmoid cells, with septal infiltration but without aggressive bony destruction, reflects a slowly evolving inflammatory process rather than malignant behavior. This is unusual, as many cases with similar sinonasal involvement exhibit more destructive imaging findings or systemic associations.[9]

Modern literature has increasingly emphasized the role of molecular testing following the discovery of recurrent MAPK/ERK pathway mutations, including KRAS, NRAS, ARAF, and MAP2K1, in a subset of RDD patients.[10] These insights have led to successful use of targeted therapies, particularly MEK inhibitors, in recurrent, refractory, or multifocal disease. Reports suggest considering targeted therapy when lesions are unresectable, progressive, or symptomatic despite surgery.[10]

Despite meeting several criteria that would warrant molecular testing or targeted therapy—namely, multiple recurrences, multifocality, and new-site involvement—our patient achieved complete symptom resolution with surgery alone, without the need for systemic corticosteroids, immunosuppression, or targeted agents. Her favorable outcome supports the continued role of lesion-directed surgical management in localized yet relapsing extranodal RDD, especially when systemic features are absent and surgical access is feasible.

Overall, this case makes a significant contribution to the current literature by highlighting a rare, multifocal, relapsing extranodal variant of RDD that remained localized, surgically manageable, and free from systemic progression over three years. It highlights the need for long-term surveillance, as even seemingly limited extranodal disease can recur or migrate to new anatomical sites.

Conclusion: This is an unusual presentation of recurrent multifocal extranodal RDD involving the sinonasal tract and eyelid, in the absence of nodal or systemic disease. Although recurrence is uncommon, RDD should be considered in the differential diagnosis of recurrent sinonasal masses. Histopathological confirmation remains essential for diagnosis, and complete surgical excision can provide excellent long-term disease control in patients with localized recurrent extranodal disease, avoiding the need for systemic treatment.

Patient perspectives: The patient felt disturbed due to multiple recurrences. However, each recurrence gave her some relief. The absence of systemic involvement despite local recurrence gave her reassurance about the overall prognosis.

Declarations

1. Funding: Nil
2. Conflicts of interest/Competing interests- Nil
3. Ethics approval- Not applicable
4. Consent to participate- Consent obtained from the patient to participate
5. Written Consent for publication- Consent obtained from the patient to publish
6. Availability of data and material – data available with the corresponding author
7. Code availability- Not applicable
8. Author contributions:

Dr. Biniyam K: Concept, design, Data collection, writing, review, final approval

Dr. Sanabel Gloria Dsouza: Concept, design, Data collection, Literature review, writing, review

Dr. Shubha P. Bhat: Data collection, writing, review, final approval

Dr Vadisha Bhat: critical revision of the manuscript, Supervision, final review, final approval

References

1. Foucar E, Rosai J, Dorfman RF. Sinus histiocytosis with massive lymphadenopathy: current status and future directions. *Arch Pathol Lab Med.* 1990;114(11):1103–10.
2. Gupta M, Singh S, Khanna M, Kudesia M. Rosai-Dorfman disease: a comprehensive review. *Clin Med Insights Pathol.* 2015;8:CMIP.S22874.
3. Abla O, Jacobsen E, Picarsic J, Krenova Z, Jaffe R, Emile JF, et al. Consensus recommendations for the diagnosis and clinical management of Rosai-Dorfman disease. *Blood.* 2018;131(26):2877–90.
4. Bhat SP, Prasad HLK, Bhandary BSK, Baikunje S, Bhat V. Metachronous Nodal and Nasal Rosai Dorfman Disease Presenting with Chronic Renal Failure. Clin Rhinol An Int J 2013;6(3):139-143
5. Zhang T, Wu J, Han D, Zhou B, Ma Y, Sun Y. Rosai–Dorfman disease of the nasal cavity and paranasal sinus: a retrospective study of 10 cases. *Allergy Rhinol.* 2020;11:1–7.
6. Dalia S, Sagatys E, Sokol L, Kubal T. Rosai–Dorfman disease: tumor biology, clinical features, pathology, and treatment. *Cancer Control.* 2014;21(4):322–7.
7. Konrad C, Griepentrog GJ, White VA, Rootman J. Ophthalmic Rosai–Dorfman disease: new reports and a literature review. *Surv Ophthalmol.* 2011;56(4):284–9.

8. Zhang Q, Liu Y, Yan B, Zhou P, Liu H. Clinical characteristics and outcomes of relapsed and refractory Rosai–Dorfman disease: a single-center experience. *Ann Med.* 2023;55(1):391–8.
9. Dagna L, Ferrero E, Garrido GJ, Doglioni C, Schilirò D, Lanzani C, et al. Targeted therapy in Rosai–Dorfman disease: a systematic review. *J Allergy Clin Immunol Pract.* 2022;10(5):1164–73.
10. O'Malley DP, Singh Z, Peng S, Hutchison RE. Rosai–Dorfman disease treated with MEK inhibitor: case report and review. *Hematol Oncol Stem Cell Ther.* 2021;14(1):61–6.

Figures

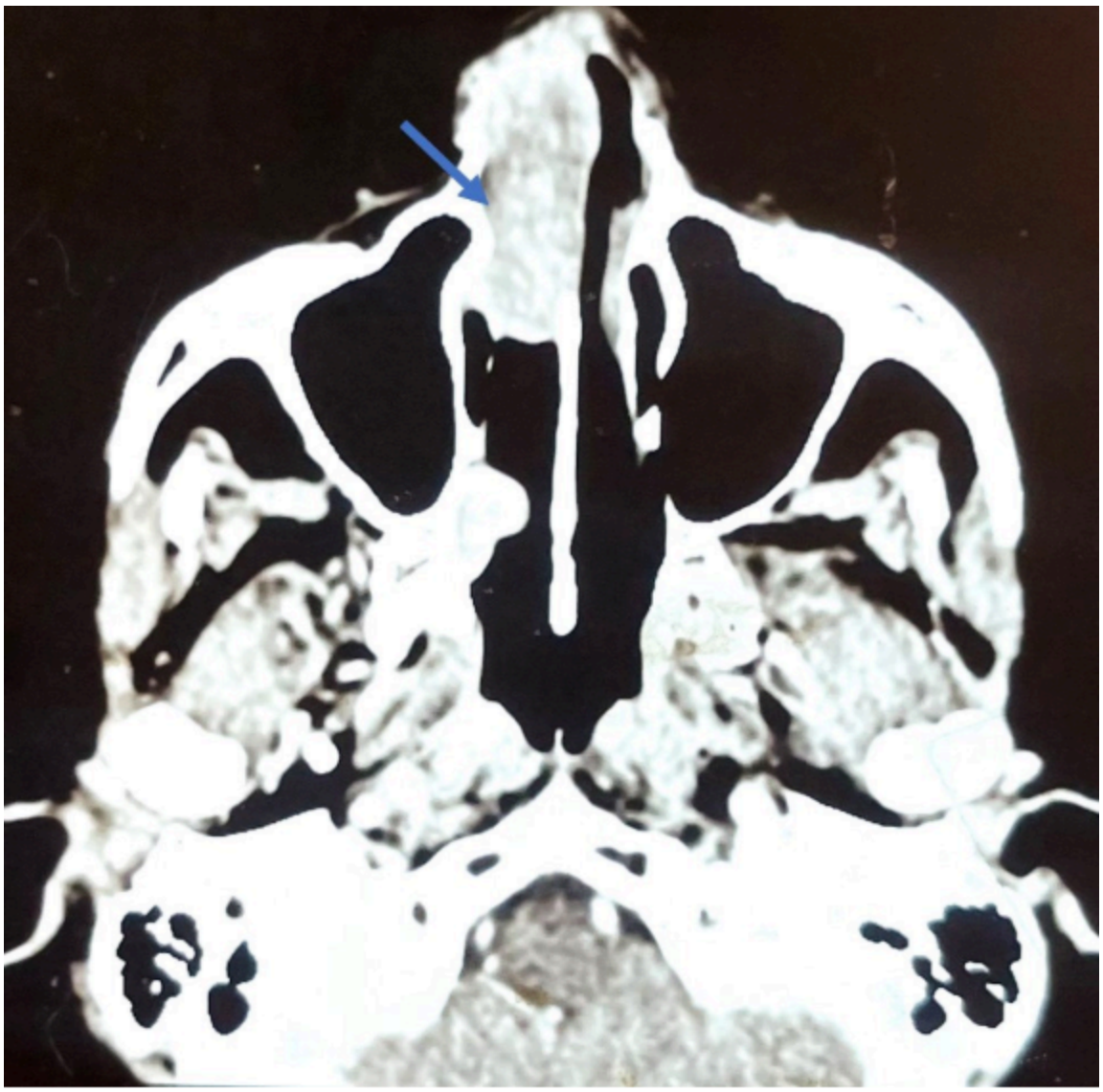

Figure 1

CECT Nose and PNS showing soft-tissue lesion in the right anterior nasal cavity

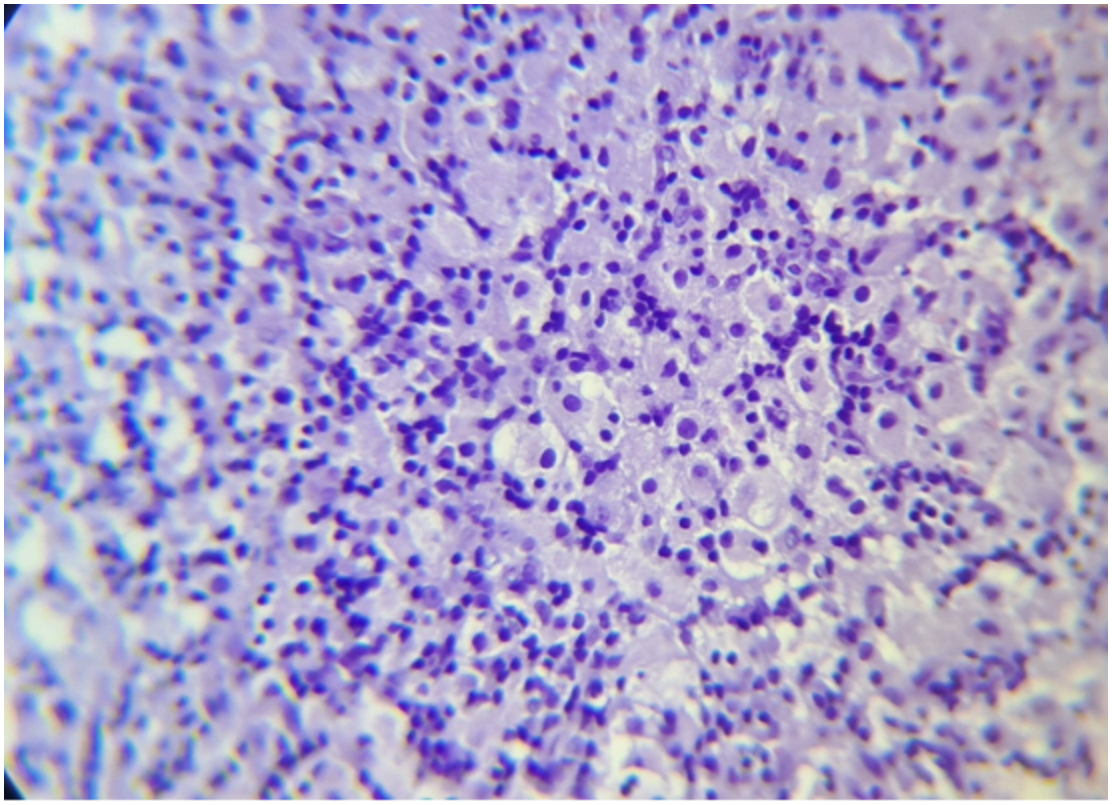

Figure 2

Histopathology showing sheets of large histiocytes exhibiting emperipolesis within a mixed inflammatory background (H&E, 40X)

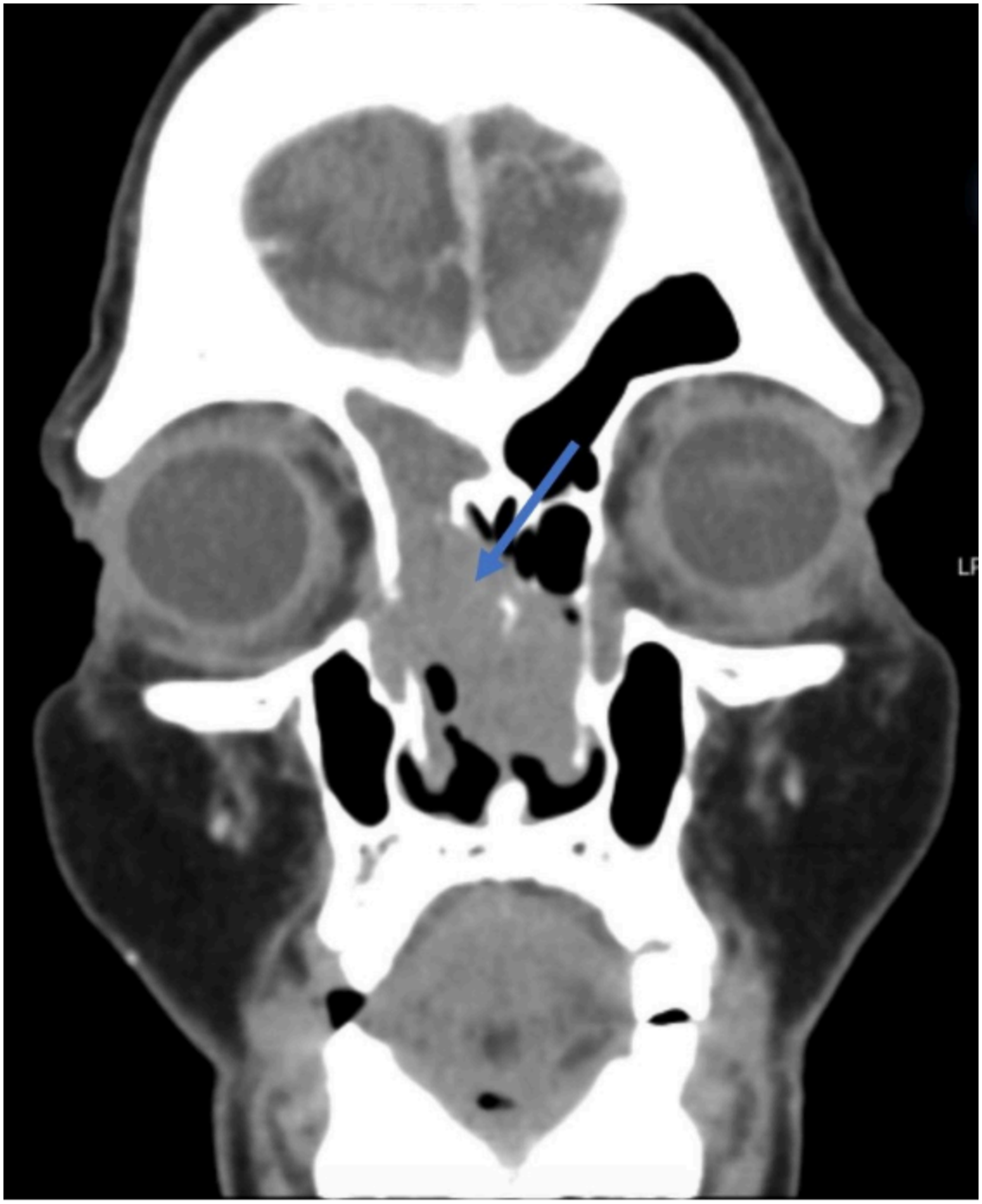

Figure 3

CECT NOSE and PNS showing soft tissue density lesion along the nasal septum, filling in bilateral nasal cavities, along with obliteration of the right middle meatus and extending into the right anterior ethmoid cells, causing bowing of the ethmoid sinus walls

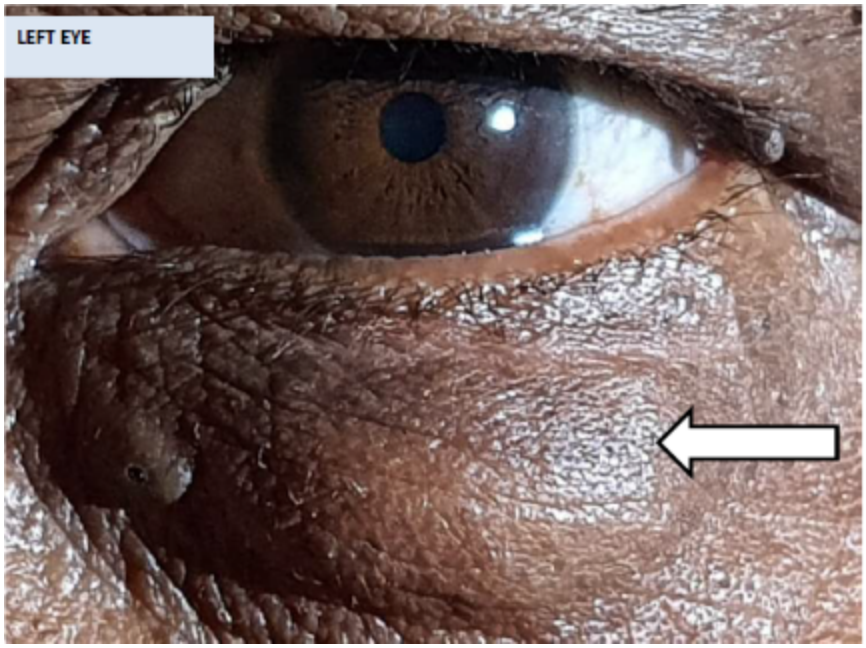

Figure 4

Clinical image showing a non-tender cystic lesion on the left eyelid

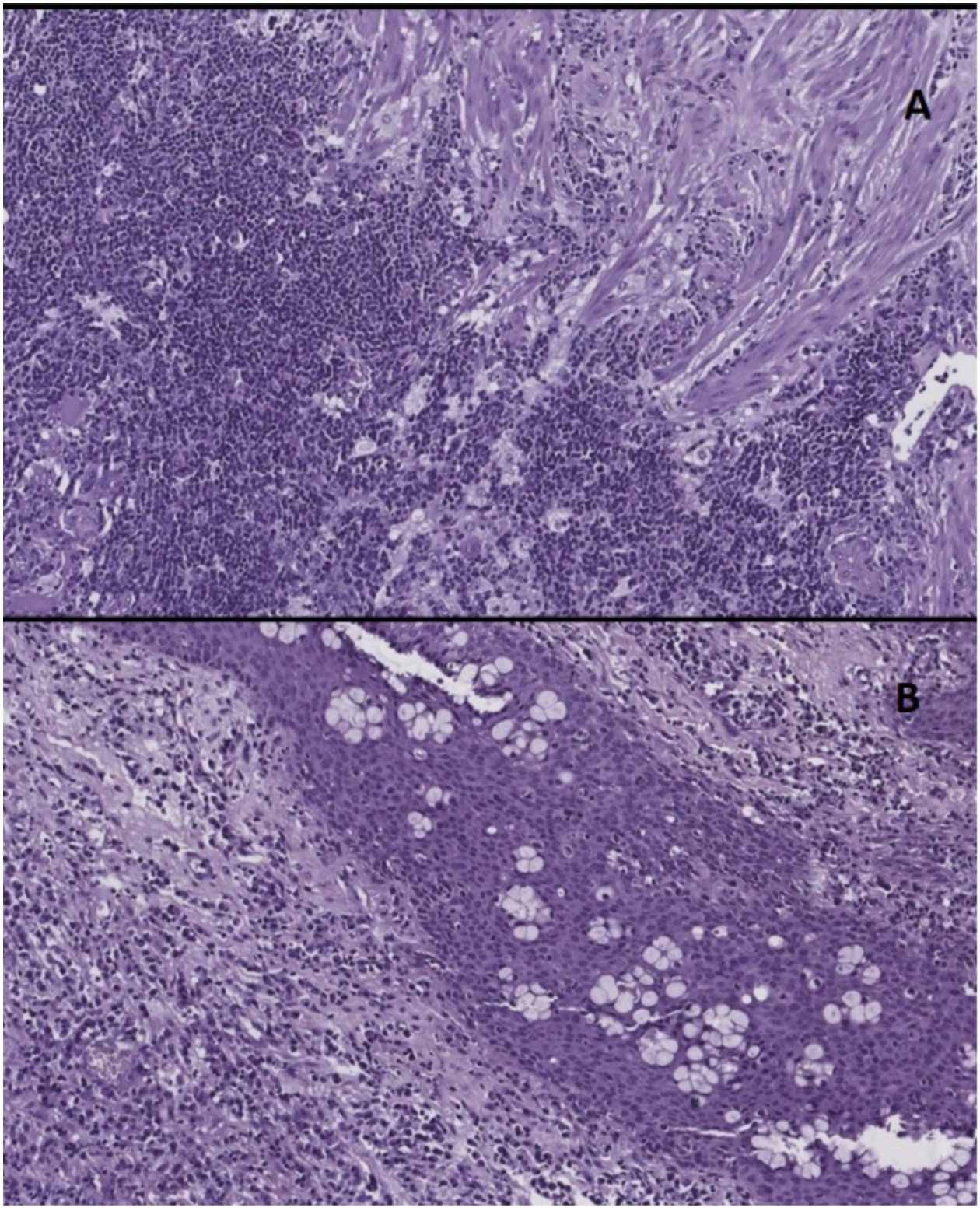

Figure 5

Histopathology A- fibrocollagenous tissue with sheets of dense lymphocytic infiltrate along with histiocytes engulfing lymphocytes (H&E, 10X). B- stratified squamous epithelium admixed with goblet cells with stroma showing lymphocytes (H&E, 10X)

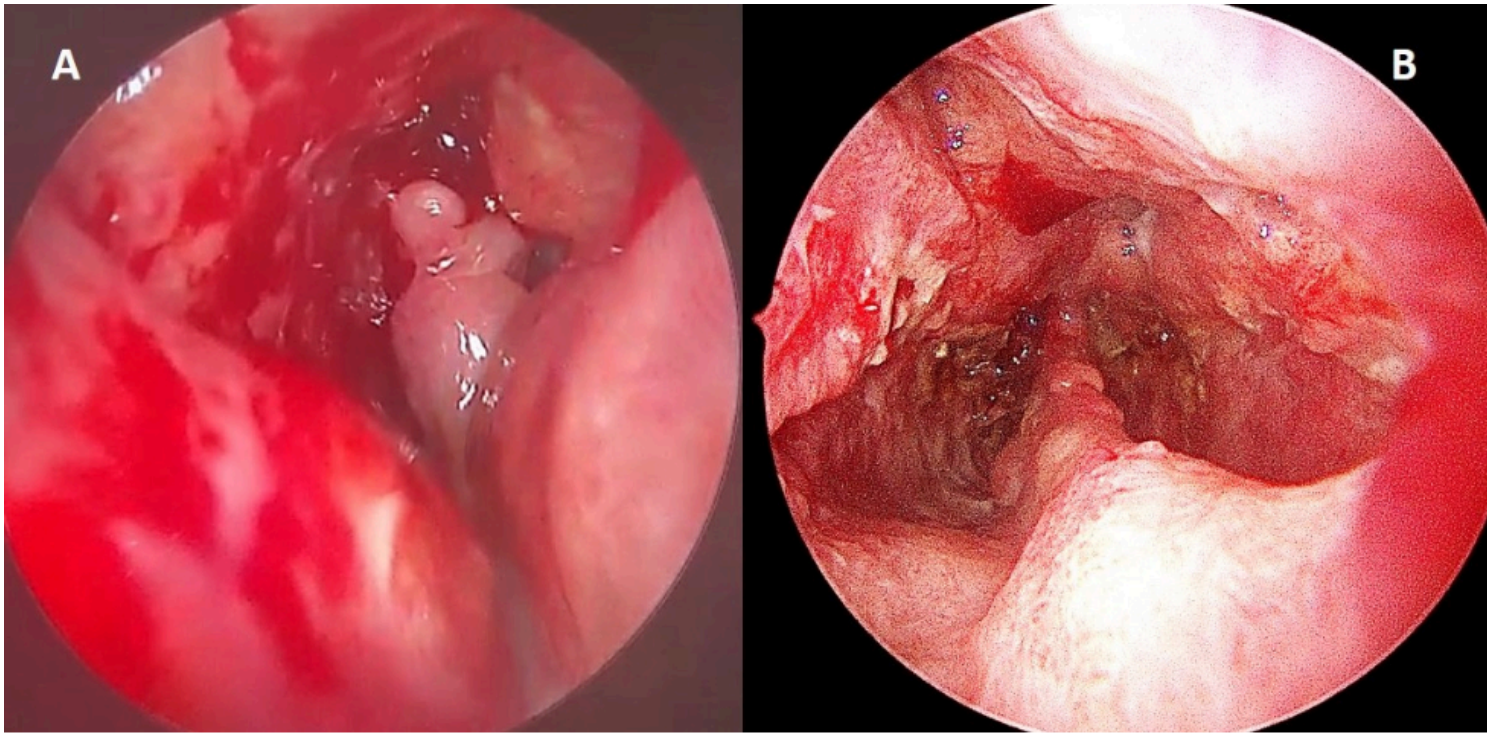

Figure 6

A - Polypoidal reddish mass seen arising from the right inferior turbinate and corresponding nasal septum on Diagnostic nasal endoscopy. B- postoperative image showing bilateral nasal cavity with remnant of the nasal septum