Research Square

Preprints are preliminary reports that have not undergone peer review.
They should not be considered conclusive, used to inform clinical practice,
or referenced by the media as validated information.

Thoracoscopic-Guided versus Ultrasound-Guided Thoracic Paravertebral Nerve Block in Uniport Video-Assisted Thoracoscopic Surgery: A Randomized Controlled Trial

Long-fei Zhu
Daping Hospital
Yi-ju Xie
Daping Hospital
Ling-min Zhang
Daping Hospital
Chun-jian Zuo
Daping Hospital
Yuan-lin Deng
Daping Hospital
Bin Jiang
ray_miller@126.com

Daping Hospital

Research Article

Keywords: thoracic paravertebral nerve block, postoperative analgesia, thoracoscopic-guided, ultrasound-guided, uniport video-assisted thoracoscopic surgery

Posted Date: October 14th, 2026

DOI: https://doi.org/10.21203/rs.3.rs-10873570/v1

License: This work is licensed under a Creative Commons Attribution 4.0 International License.
Read Full License

Additional Declarations: No competing interests reported.

Abstract

Background

Although effective, ultrasound-guided thoracic paravertebral block (USG-TPVB) is technically challenging and highly dependent on operator skill and equipment. Thoracoscopic-guided thoracic paravertebral block (TSG-TPVB) offers procedural simplicity and is being increasingly used as an alternative. This study compares the efficacy and safety of TSG-TPVB against USG-TPVB in patients undergoing uniport video-assisted thoracic surgery (uni-VATS).

Methods

Patients undergoing uni-VATS were randomly assigned to either the TSG-TPVB group (n = 41) or the USG-TPVB group (n = 40). The primary outcome was the patient's pain intensity, which was assessed using the visual analog scale (VAS) at different postoperative time points, with group differences evaluated against a noninferiority margin of 5 points (Δ). The duration of the TPVB procedure, TPVB-related complications and other indicators were also analyzed.

Results

TSG-TPVB was found to be noninferior to USG-TPVB in terms of patients' resting and cough-evoked pain intensity throughout the postoperative period. Notably, compared with the USG-TPVB group, the TSG-TPVB group had a significantly shorter procedure duration (138.05 ± 34.96 vs. 219.25 ± 35.67 seconds, $P < 0.001$) and a lower incidence of complications ($P = 0.001$). No significant differences were found in the frequency of rescue analgesia, the number of PCA activations, or other related indicators.

Conclusions

TSG-TPVB demonstrated noninferior analgesic efficacy up to 72 hours postoperatively and was associated with fewer complications and greater operational efficiency. Its straightforward technique and short learning curve make it an easily adoptable option for routine clinical practice.

Trial registration:

This study was registered with the Chinese Clinical Trial Registry on August 2, 2021 (registration No. ChiCTR2100049416).

Background

Uniport video-assisted thoracoscopic surgery (Uni-VATS) has been increasingly adopted since 2011 and is theoretically associated with less tissue injury and intercostal nerve compression than conventional multiportal approaches, which should translate into lower postoperative pain [1, 2]. However, acute postoperative pain following uniVATS remains a common issue and a significant clinical challenge that is frequently underestimated and inadequately managed, ultimately hindering rapid recovery [3–5].

Thoracic paravertebral block (TPVB) is recommended as the first-line regional analgesic technique in this setting. Nevertheless, ultrasound-guided TPVB (USG-TPVB) is inherently constrained by significant technical and equipment requirements, a longer learning curve, extended procedure duration, and non-negligible risks of vascular injury and unintended pleural leakage [6–8]. These limitations are particularly magnified in high-volume thoracic surgical practice. To address these shortcomings, the surgeon-performed thoracoscopic-guided TPVB (TSG-TPVB) has recently emerged as a pragmatic alternative, offering direct real-time visualization of the critical anatomical landmarks and theoretically improving safety while avoiding the technical pitfalls of ultrasound reliance [9–12].

However, robust prospective comparative data for TSG-TPVB specifically within a uni-VATS lobectomy/segmentectomy cohort remain scarce, which prompted the design of this randomized controlled trial comparing TSG-TPVB against the standard anesthesiologist-administered approach.

Methods

Study Design

This single-center, patient-blinded, prospective randomized controlled trial was conducted at Daping Hospital of the Army Medical University, Chongqing, China—a tertiary referral center with high thoracic surgical volume.The trial was performed in full accordance with the Declaration of Helsinki. The study protocol was reviewed and approved by the Ethics Committee of the Daping Hospital (approval code No. 2021(77); approval date 5 July 2021). This study was registered with the Chinese Clinical Trial Registry on August 2, 2021 (registration No. ChiCTR2100049416; available at: https://www.chictr.org.cn/searchprojEN.html). And patient enrollment began on September 1, 2023. Adhering to Consolidated Standards of Reporting Trials (CONSORT) guidelines, written informed consent was obtained from all participants.

Inclusion and Exclusion Criteria

Patients who were scheduled to undergo pulmonary surgical procedures were screened for inclusion in this study if they met the following criteria: (1) scheduled for uni-VATS lobectomy or segmentectomy because of suspected malignancy or benign lesions, and (2) age between 18 and 75 years. The exclusion criteria included (1) conversion to thoracotomy or multiport VATS during the procedure; (2) contraindications to TPVB; (3) severe cardiocerebrovascular disease, hepatic or renal insufficiency; (4) previous ipsilateral thoracic surgery; (5) history of chronic pain, psychiatric disorders, or long-term

analgesic use; (6) severe thoracic or spinal deformities; (7) chronic alcohol abuse; (8) endotracheal extubation occurring more than 2 hours after completion of surgery; (9) need for invasive procedures or reoperation due to severe complications; and (10) refusal to use a patient-controlled analgesia (PCA) device.

Randomization and Blinding

Patients were randomly allocated (1:1) to the USG-TPVB or TSG-TPVB group by an unblinded nurse using random numbers generated with SPSS Version 26.0 (IBM Corp., Armonk, NY, USA). Randomization assignments sealed in opaque envelopes were opened by an anesthesiologist after the patient entered the operating room; subsequently, either an anesthesiologist or a surgeon performed USG-TPVB or TSG-TPVB according to the assignment. The researchers who performed the aforementioned procedures were not involved in the data collection or outcome assessment.

Anesthesia Management

General anesthesia was induced with 0.05 mg/kg midazolam, 0.3 mg/kg etomidate, 5 μg/kg sufentanil, and 0.15 mg/kg cisatracurium. A double-lumen endotracheal tube was inserted under direct laryngoscopy. Correct placement of the tube was confirmed by fiberoptic bronchoscopy, after which mechanical ventilation was initiated. Intraoperative anesthesia was maintained with propofol, remifentanil, cisatracurium, and sevoflurane, ensuring a BIS value within the range of 40–60. In addition, sufentanil (0.1–0.2 μg/kg) was injected intravenously 3 minutes before the skin incision was made.

Postoperatively, all patients received PCA. The regimen consisted of sufentanil citrate (50 μg), dezocine (15 mg), and tropisetron hydrochloride (5 mg), diluted in 170 ml of 0.9% saline. The pump was programmed with a continuous background infusion of 2 ml/h, a supplemental bolus dose of 4 mL, and a lockout interval of 15 minutes. Rescue analgesia was administered if the resting pain VAS score remained ≥ 4 at 15 minutes after a 4 mL supplemental bolus. The protocol was as follows: oral tramadol hydrochloride 50 mg was administered as the first intervention. If analgesia remains insufficient after administration, an intramuscular injection of 50 mg pethidine hydrochloride is given.

Surgical Procedures

All patients underwent uni-VATS via a 4-cm incision in the fifth intercostal space at the midaxillary line. A sterile incision sleeve was used to protect the surgical incision. On the basis of CT imaging, tumor characteristics, and assessments of vascular and bronchial anatomy, the surgeon decided whether to perform a lobectomy or a segmentectomy. A drainage tube (24 Fr) was placed at the fifth intercostal incision.

Thoracic Paravertebral Nerve Block

TSG-TPVB Group

Paravertebral block was performed prior to the start of the primary surgical procedure in the TSG-TPVB group. Under thoracoscopic guidance, a 22-gauge scalp needle with an extension tube was inserted vertically into the parietal pleura at the T4–T6 intercostal levels, 0.5 cm lateral to the sympathetic chain, to a depth of 0.5–1 cm, to access the corresponding paravertebral spaces (Fig. 1A) [12]. After confirming the absence of blood and cerebrospinal fluid on aspiration, 10 mL of 0.5% ropivacaine hydrochloride was slowly injected into each paravertebral space for a total volume of 30 mL (Fig. 1B).

USG-TPVB Group

A high-frequency linear ultrasound transducer was placed longitudinally along the patient's midline at the T4–T6 level. The transducer was then shifted slightly in a cephalad direction, approximately 2–3 cm above the initial level, until a sharp image of the adjacent transverse processes, the corresponding paravertebral space, and the pleura was obtained. A 20-gauge nerve block needle was inserted into the paravertebral space using the out-of-plane technique (Fig. 1C). After confirming negative aspiration for blood, cerebrospinal fluid and air, 10 mL of 0.5% ropivacaine hydrochloride was slowly injected into each paravertebral space. Downward movement of the pleura was observed as a sign of correct spread (Fig. 1D).

Outcomes

The primary outcomes were the patient's resting and cough-evoked pain intensity of the patient, which was assessed using the VAS score at 12, 24, 48, and 72 hours postoperatively. Secondary outcomes included the number of effective PCA activations, the frequency of rescue analgesia administration, the duration of the TPVB procedure in both groups, complications associated with TPVB, the length of stay in the postanesthesia care unit, the duration of endotracheal extubation, the time to first ambulation postoperatively and predischarge assessments of anxiety and depression (using the 7-item Generalized Anxiety Disorder (GAD-7) scale and the 9-item Patient Health Questionnaire (PHQ-9)).

Additionally, we routinely collected white blood cell count, neutrophil count, neutrophil percentage, and platelet count preoperatively and on postoperative days (PODs) 1 and 3. We also measured inflammatory markers, such as C-reactive protein (CRP) and interleukin-6 (IL-6).

Sample Size Estimation

The pretrial results showed that, the resting VAS scores at 12 hours postoperatively was 34.8 ± 9.0 in the USG-TPVB group and 31.5 ± 12.1 in the TSG-TPVB group. In consultation with statistical experts and based on the evidence from the literature, a noninferiority margin of 5.0 was established [11]. This margin was deemed clinically acceptable as it reflects real-world practice and controls type II error rates. To achieve 90% power with a 0.025 significance level, 36 participants per group were needed. Accounting for an estimated 10% dropout rate, the final sample size was set at 80 patients.

Harms Assessment

Adverse events were systematically monitored and documented throughout the trial period. Both anticipated and unanticipated adverse reactions were promptly treated and recorded in detail. In the present study, three patients in the TSG-TPVB group and two in the control group experienced analgesic-related nausea and vomiting, all of which were promptly treated and resolved without further complications. No other complications or serious adverse events occurred, and no participants withdrew from the study due to adverse events.

Statistical Analysis

All the statistical tests were performed using SPSS software. Continuous variables following normal distribution are reported as mean ± SD, with inter-group comparisons analyzed by independent t tests. Repeated-measures ANOVA was used to assess within-group differences. Non-normally distributed data are presented as medians (IQRs) and were analyzed by the Kruskal–Wallis test. For the categorical variables, χ^2/Fisher's exact tests were used for group comparisons. The significance threshold was $p < 0.05$.

Results

Participant Flow and Recruitment

Between September 1, 2023 to June 30, 2024, a total of 391 patients were assessed for eligibility, and 92 were randomized. The USG-TPVB group comprised 45 patients, and the TSG-TPVB group comprised 47. In the USG-TPVB group, 5 patients were excluded from the final analysis (2 converted to multiport VATS, 1 to wedge resection, 1 had delayed extubation > 2 h after surgery, and 1 required an invasive procedure), leaving 40 patients for analysis. In the TSG-TPVB group, 6 patients were excluded (2 converted to multiport VATS, 1 to thoracotomy, 2 to wedge resection, and 1 required an invasive procedure), resulting in 41 analyzed patients. The participant flow is summarized in Fig. 2.

Baseline Characteristics and Perioperative Metrics

As presented in Table 1, there were no statistically significant differences between the two groups in terms of baseline characteristics. Similarly, the perioperative metrics, including the duration of surgery, pathological stage, and postoperative length of stay, were comparable between the two cohorts (Table 2).

Table 1
Demographic Characteristics of Patients in the Two Groups

Age (years)	**USG-TPVB group (n = 40)**	**TSG-TPVB group (n = 41)**	***P* Value**
	60.53 ± 7.89	**58.44 ± 10.79**	**0.324**
Gender (%)			0.745
Male	19 (47.50)	18 (43.90)	
Female	21 (52.50)	23 (56.10)	
BMI (kg/m^2)	24.42 ± 2.46	24.42 ± 2.68	0.997
Smoking history			0.678
Yes	11 (27.50)	13 (31.71)	
No	29 (72.50)	28 (68.29)	
Smoking history, pack-years	37.27 ± 19.67	35.15 ± 27.46	0.833
FEV1, % of predicted	104.72 ± 19.59	102.95 ± 18.70	0.678
FEV1/FVC ratio, %	80.31 ± 7.94	80.69 ± 7.85	0.829
MVV (L/min)	86.92 ± 24.47	87.50 ± 21.89	0.911
Comorbidity (%)			0.832
Hypertension	10 (25.00)	10 (24.39)	
Diabetes	2 (5.00)	5 (12.20)	
Coronary heart disease	1 (2.50)	2 (4.88)	
COPD	4 (10.00)	6 (14.63)	
Others	5 (12.50)	3 (7.32)	
Tumor size (cm)	2.19 ± 0.96	2.06 ± 1.13	0.597
Preoperative GAD-7 score	1.85 ± 1.69	1.83 ± 1.73	0.957
Preoperative PHQ-9 score	2.53 ± 1.97	2.34 ± 2.33	0.703
Location, n (%)			0.692
RUL	18 (45.00)	17 (41.46)	
RML	2 (5.00)	6 (14.63)	

COPD, chronic obstructive pulmonary disease; FEV1, forced expiratory volume in 1 second; FVC, forced vital capacity; GAD-7, 7-item generalized anxiety disorder questionnaire; LLL, left lower lobe; LUL, left upper lobe; MVV, maximum voluntary ventilation; PHQ-9, 9-item patient health questionnaire; RLL, right lower lobe; RML, right middle lobe; RUL, right upper lobe.

Age (years)	**USG-TPVB group (n = 40)**	**TSG-TPVB group (n = 41)**	***P* Value**
	60.53 ± 7.89	**58.44 ± 10.79**	**0.324**
RLL	7 (17.50)	5 (12.20)	
LUL	10 (25.00)	10 (24.39)	
LLL	3 (7.50)	3 (7.32)	

COPD, chronic obstructive pulmonary disease; FEV1, forced expiratory volume in 1 second; FVC, forced vital capacity; GAD-7, 7-item generalized anxiety disorder questionnaire; LLL, left lower lobe; LUL, left upper lobe; MVV, maximum voluntary ventilation; PHQ-9, 9-item patient health questionnaire; RLL, right lower lobe; RML, right middle lobe; RUL, right upper lobe.

Table 2
Perioperative Outcomes of the USG-TPVB and TSG-TPVB group

Lung resection, n (%)	**USG-TPVB group (n = 40)**	**TSG-TPVB group (n = 41)**	***P*-value**
			1.000
Lobectomy	30 (75.00)	31 (75.61)	
Segmentectomy	10 (25.00)	10 (24.39)	
Duration of surgery (min), median (IQR)	110.00 (96.00, 140.00)	125.00 (100.00, 145.00)	0.302
Intraoperative blood loss (mL), median (IQR)	40.00 (20.00, 50.00)	40.00 (20.00, 50.00)	0.809
Number of lymph node dissections, median (IQR)	5.00 (2.00, 13.00)	5.00 (2.00, 9.00)	0.411
Histologic type, n (%)			0.747
Adenocarcinoma in situ	7 (17.50)	6 (14.63)	
Microinvasive adenocarcinoma	4 (10.00)	5 (12.20)	
Infiltrating adenocarcinoma	17 (42.50)	23 (56.10)	
Squamous cell carcinoma	2 (5.00)	1 (2.44)	
Other malignant diseases	1 (2.50)	0	
Benign diseases	9 (22.50)	6 (14.63)	
Pathologic stage, n (%)			0.414
Tis	7 (17.50)	6 (14.63)	
A1	6 (15.00)	6 (14.63)	
A2	7 (17.50)	3 (7.32)	
A3	5 (12.50)	6 (14.63)	
B	4 (10.00)	10 (24.39)	
A	0	1 (2.44)	
B	0	2 (4.88)	
A	2 (5.00)	1 (2.44)	
Duration of chest tube (days), median (IQR)	3.00 (2.00, 4.00)	3.00 (2.00, 3.00)	0.127

Lung resection, n (%)	USG-TPVB group (n = 40)	TSG-TPVB group (n = 41)	*P*-value
			1.000
Total drainage volume (ml), median (IQR)	410.00 (260.00, 700.00)	380.00 (245.00, 570.00)	0.152
Post-operative complications, n (%)	6 (15.00)	6 (14.63)	0.875
Air leak > 5 days	4 (10.00)	2 (4.88)	
Pneumonia	1 (2.50)	2 (4.88)	
Atelectasis	0	1 (2.44)	
Others	1 (2.50)	1 (2.44)	
Hospital stay (days), median (IQR)	5.00 (4.00, 6.00)	5.00 (4.00, 5.50)	0.555
Readmission before day 30, n (%)	0	1 (2.44)	1.000

Pain Intensity

Compared with the USG-TPVB group, the TSG-TPVB group was not inferior in terms of postoperative VAS scores at 12 hours, with similar scores observed both at rest (31.36 ± 12.67 vs. 34.75 ± 12.40, P = 0.243) and during coughing (49.27 ± 14.03 vs. 53.75 ± 11.92, P = 0.126). The between-group difference was − 4.48 (95% CI: -10.15 to 1.18), with the upper limit of the confidence interval (CI) not exceeding the predefined noninferiority margin of 5 points (Δ), as shown in Fig. 3. At subsequent time points (24, 48, and 72 hours postoperatively), the differences in VAS scores between the two groups were all within the non-inferiority margin, indicating the noninferiority of the TSG-TPVB throughout the entire postoperative period (Supplemental Table 1). The TSG-TPVB group even exhibited more favorable VAS scores both at rest and during coughing at 48 hours postoperatively. The dynamic changes in mean VAS scores at various time points are shown in Supplemental Fig. 1.

Secondary Outcomes

As shown in Table 3, the duration of the TPVB procedure was significantly shorter in the TSG-TPVB group (138.05 ± 34.96 vs. 219.25 ± 35.67 seconds, P < 0.001). In addition, significant differences in complication rates were observed between the groups: the incidences of local hematoma (5.00% vs. 0%) and accidental intrapleural leakage or injection (17.50% vs. 0%) were both greater in the USG-TPVB group (P = 0.001) (Fig. 4). No significant differences were found in the other postoperative recovery parameters. The GAD-7 and PHQ-9 scores were comparable between the USG-TPVB and TSG-TPVB cohorts (3.40 ± 2.64 vs. 3.00 ± 1.82, P = 0.428 and 4.98 ± 2.95 vs. 4.02 ± 2.01, P = 0.093, respectively). Finally, as shown in Supplemental Fig. 2, both groups demonstrated comparable postoperative inflammatory responses.

Table 3
Secondary Outcome Measurements

Duration of TPVB procedure (sec)	**USG-TPVB group (n = 40)**	**TSG-TPVB group (n = 41)**	***P*-value**
	219.25 ± 35.67	**138.05 ± 34.96**	**< 0.001**
Complications following TPVB, n (%)	9 (22.50)	0	0.001
Local hematoma	2 (5.00)	0	
Accidental intrapleural leakage or injection	7 (17.50)	0	
Nerve root injury	0	0	
PCA compression number, median (IQR)			
6h	1.00 (0, 2.00)	1.00 (0, 3.00)	0.381
12h	1.00 (1.00, 2.00)	1.00 (0, 2.00)	0.895
24h	1.50 (0, 2.00)	1.00 (0, 2.00)	0.270
48h	0 (0, 2.00)	0 (0, 1.00)	0.111
72h	0 (0, 1.00)	0 (0, 1.00)	0.987
Number of rescue analgesic events (IQR)	1.00 (0, 2.00)	1.00 (1.00, 2.00)	0.252
Duration from surgery completion to extubation (min), median (IQR)	35.00 (30.00, 60.00)	40.00 (25.00, 65.00)	0.936
Duration in PACU (min), median (IQR)	95.00 (65.00, 110.00)	85.00 (67.00, 110.00)	0.784
Ambulation time (hours), median (IQR)	18.00 (16.00, 20.00)	19.00 (17.00, 20.00)	0.165
Pre-discharge GAD-7 score	3.40 ± 2.64	3.00 ± 1.82	0.428
Pre-discharge PHQ-9 score	4.98 ± 2.95	4.02 ± 2.01	0.093
Adverse reactions related to analgesia, n (%)	4 (10.00)	4 (9.76)	0.836
Nausea and vomiting	2 (5.00)	3 (7.32)	
Dizziness	2 (5.00)	0	
Drowsiness	1 (2.50)	1 (2.44)	

GAD-7, 7-item generalized anxiety disorder questionnaire; IQR, interquartile range; PACU, Postanesthesia care unit; PHQ-9, 9-item patient health questionnaire; sec, second.

Discussion

This study demonstrated the noninferior postoperative analgesic efficacy of TSG-TPVB compared with that of USG-TPVB. Specifically, during the entire postoperative period, the intensities of resting pain and cough-evoked pain assessed using the VAS were comparable between patients who received the two methods. The trends in inflammatory markers paralleled the VAS scores, with no significant intergroup differences at any time point, further supporting the noninferiority of TSG-TPVB to USG-TPVB in terms of analgesic efficacy. Second, TSG-TPVB significantly shortened the procedure time and markedly reduced the incidence of block-related complications, thereby indicating superior operational efficiency and a favourable safety profile.

USG-TPVB is currently recommended as the first-line regional analgesic technique for thoracoscopic surgery [6, 13, 14]. However, this conventional approach carries several inherent drawbacks. First, despite the improved safety afforded by ultrasound, the risk of complications still is not negligible. In fact, this study was motivated by our repeated clinical observations of complications associated with USG-TPVB, including local hematoma, pleural puncture, and subsequent unintentional intrapleural leakage. Concerns regarding these complications have significantly limited its broader adoption [15, 16].

Although ultrasound guidance has reduced the incidences of pneumothorax and pleural puncture to reported rates of 0.26% and 0.6%, respectively, these figures are likely to be underestimates, as existing studies typically confirm cases only in symptomatic or clinically suspected patients rather than through systematic screening [17, 18]. This potential underdiagnosis may account for the notably higher incidence of such complications in present study. Moreover, color doppler often fails to display intravascular flow when the ultrasound beam is perpendicular to the blood flow, and limited resolution further compounds this limitation [19]. And the out-of-plane needle approach provides only a cross-sectional view of the needle tip, hindering shaft tracking and precise trajectory control. Misalignments and repeated needle adjustments can lead to unintended vascular injuries as well.

In contrast, the TSG-TPVB effectively addresses the aforementioned issues. With the magnified and clear view provided by thoracoscopy, surgeons can accurately identify vessels and deliberately avoid them by performing the block within an avascular area. Besides, thoracoscopy provides direct visualization of critical anatomical landmarks and involves fewer tissue layers to traverse, thereby significantly enhancing safety. With respect to TSG-TPVB, in the event of oozing of blood or leakage of local anesthetics at the puncture site, gentle gauze compression is usually sufficient to control bleeding or prevent further leakage. This differs from USG-TPVB, which does not support such secondary interventions.

Besides, a substantial learning curve exists for USG-TPVB. Recent studies have confirmed that practitioners perceive thoracic paravertebral block as a technically challenging procedure with a steep learning curve, and the learning curve for mastering TPVB is notably higher than that for other regional analgesic methods [20, 21]. Ultrasound guidance only simplifies the identification of the paravertebral space, while accessing the space remains technically challenging. Moreover, USG-TPVB demands not only proficiency in ultrasound operation but also thorough familiarity with the relevant anatomy, which

requires structured simulation training and extensive clinical practice. In contrast, TSG-TPVB is easier to learn and perform. Thoracoscopy offers full exposure of the intercostal space, enabling rapid, accurate needle placement. The needle path is shorter and crosses fewer tissue layers, which reduces the need for redirection and improves first-attempt success. The procedure is highly intuitive and can be readily mastered by thoracic surgeons after a brief period of supervised instruction, without requiring additional training or prolonged mentorship.

A shorter procedure time reflects greater procedural simplicity, which translates to reduced preparation and improved operating room efficiency, thereby representing an important practical considerations. Consistent with the findings of Li *et al.*, TSG-TPVB significantly shortened the procedure duration in this study [22]. Owing to the long puncture path and the involvement of multiple tissue layers, even highly proficient anesthesiologists cannot avoid repeated needle adjustments, making the procedure more time-consuming. Xu *et al.* reported that nine patients in the USG-TPVB group required ≥ 2 needle adjustments to reach the paravertebral space, resulting in a significantly lower first-puncture success rate than in the TSG-TPVB group [15]. Additionally, the dorsal-to-ventral force during ultrasound imaging and needle insertion often causes anterior leaning, necessitating repositioning after TPVB. Such repeated adjustments indicate room for improvement in time and personnel efficiency. These results demonstrate that TSG-TPVB is not only simple and convenient to perform, but also time-efficient.

To our knowledge, this study represents the largest sample size to date from a prospective, randomized controlled trial to compare the efficacy and safety between TSG-TPVB and USG-TPVB in patients undergoing uni-VATS. Unlike previous studies, We restricted enrolment to uni-VATS lobectomy and segmentectomy, excluding wedge resections (which have shorter operative times) and also robotic and multiport VATS cases to avoid bias from different surgical platforms and incision numbers [11, 23]. The results of the study were also in line with those of Tong *et al*. and Hegazy *et al*., although it should be noted that the studies were limited by their relatively small sample sizes [9, 10].

This study has several limitations due to inherent design constraints. First, despite meeting the minimum sample size, this single-center study had a relatively small sample. Large-sample multicenter studies are needed to generalize the findings. Second, only short-term perioperative outcomes were assessed, and hence the impact on chronic pain could not be evaluated.

Conclusions

In conclusion, for patients undergoing uni-VATS, compared with conventional USG-TPVB, TSG-TPVB offers noninferior analgesic efficacy with a lower risk of complications and higher procedural efficiency. Given that USG-TPVB relies heavily on ultrasound equipment and entails a longer learning curve, TSG-TPVB offers a practical alternative that is easier to integrate into routine practice, particularly in settings where training resources or equipment availability are limited.

Declarations

Ethical approval

The study protocol was reviewed and approved by the Ethics Committee of the Daping Hospital (approval code No. 2021(77); approval date 5 July 2021). Written informed consent was obtained from all participants.

Consent for publication

Not applicable.

Competing interests

The authors declare no competing interests.

Funding:

None declared.

Author Contribution

Guarantor of the integrity of the entire study: B. J. Study concepts and design: B. J., L.F. Z. Literature research: L.M. Z. Project administration: L.F. Z., Y. X. Data acquisition: C. Z., Y. D. Data analysis: C. Z., Y. D. Statistical analysis: L.F. Z. Manuscript preparation: L.F. Z., Y. X. and B. J. Manuscript review: All authors.

Acknowledgement

The authors are indebted to all of the people whose names were not included in the author list but who participated in our study.

Data Availability

The datasets generated and analyzed during the present study are available from the corresponding author on reasonable request.

Abbreviations

BIS, bispectral index

BMI, body mass index

CI, confidence interval

COPD, chronic obstructive pulmonary disease

FEV1, forced expiratory volume in 1 second

FVC, forced vital capacity

GAD-7, 7-item Generalized Anxiety Disorder

IQR, interquartile range

LLL, left lower lobe

LUL, left upper lobe

MVV, maximum voluntary ventilation

PACU, post-anesthesia care unit

PCA, patient-controlled analgesia

PHQ-9, 9-item Patient Health Questionnaire

POD, postoperative days

RLL, right lower lobe

RML, right middle lobe

RUL, right upper lobe

SD, standard deviation

TPVB, Thoracic paravertebral nerve block

TSG-TPVB, thoracoscopic-guided thoracic paravertebral nerve block

Uni-VATS, uniport video-assisted thoracoscopic surgery

USG-TPVB, ultrasound-guided thoracic paravertebral nerve block

VAS, visual analog scale

VATS, video-assisted thoracoscopic surgery

References

1. Gonzalez-Rivas D, de la Torre M, Fernandez R, Mosquera VX. Single-port video-assisted thoracoscopic left upper lobectomy. *Interact Cardiovasc Thorac Surg*. 2011;13(5):539–541.
2. Han D, Cao Y, Wu H, *et al*. Uniportal video-assisted thoracic surgery for the treatment of lung cancer: a consensus report from Chinese Society for Thoracic and Cardiovascular Surgery (CSTCVS) and Chinese Association of Thoracic Surgeons (CATS). *Transl Lung Cancer Res*. 2020;9(4):971–987.
3. Wang L, Ge L, Ren Y. Advantages and feasibility of intercostal nerve block in uniportal video-assisted thoracoscopic surgery (VATS). *Postgrad Med*. 2023;135(5):472–479.
4. Wu CF, Hsieh MJ, Liu HP, *et al*. Management of post-operative pain by placement of an intraoperative intercostal catheter after single port video-assisted thoracoscopic surgery: a propensity-score matched study. *J Thorac Dis*. 2016;8(6):1087–1093.
5. Maxwell C, Nicoara A. New developments in the treatment of acute pain after thoracic surgery. *Curr Opin Anaesthesiol*. 2014;27(1):6–11.
6. Feray S, Lubach J, Joshi GP, Bonnet F, Van de Velde M. PROSPECT Working Group of the European Society of Regional Anaesthesia and Pain Therapy. PROSPECT guidelines for video-assisted thoracoscopic surgery: a systematic review and procedure-specific postoperative pain management recommendations. *Anaesthesia*. 2022;77(3):311–325.
7. Termpornlert S, Sakura S, Aoyama Y, Wittayapairoj A, Kishimoto K, Saito Y. Distribution of injectate administered through a catheter inserted by three different approaches to ultrasound-guided thoracic paravertebral block: a prospective observational study. *Reg Anesth Pain Med*. 2020;45(11):866–871.
8. Karakaya MA, Yapici D, Bingül ES, Turhan Ö, Şentürk M. Pro's and con's of different blocks for postoperative analgesia after video-assisted thoracic surgery. *Curr Opin Anaesthesiol*. 2025;38(1):65–70.
9. Tong Y, Wu J, Wu X, Mo Y, Wang F. Analgesic Efficacy of Thoracoscopic Direct-View Versus Ultrasound-Guided Thoracic Paravertebral Block in Multi-Port Video-Assisted Thoracoscopic Lung Surgery: A Randomized Controlled Non-Inferiority Study. *Drug Des Devel Ther*. 2025;19:1825–1838.
10. Hegazy MA, Awad G, Abdellatif A, Saleh ME, Sanad M. Ultrasound versus thoracoscopic-guided paravertebral block during thoracotomy. *Asian Cardiovasc Thorac Ann*. 2021;29(2):98–104.
11. Chenesseau J, Fourdrain A, Pastene B, *et al*. Effectiveness of Surgeon-Performed Paravertebral Block Analgesia for Minimally Invasive Thoracic Surgery: A Randomized Clinical Trial. *JAMA Surg*. 2023;158(12):1255–1263.
12. Wu KW, Deng SY, Zhang XF, Zheng DW, Hu LH. Thoracoscopy-guided thoracic paravertebral block using dexmedetomidine in combination with ropivacaine for postoperative analgesia after thoracoscopic radical resection of lung cancer: a randomized controlled trial. *J Cancer Res Clin Oncol*. 2025;151(5):158.
13. Piccioni F, Segat M, Falini S, *et al*. Enhanced recovery pathways in thoracic surgery from Italian VATS Group: perioperative analgesia protocols. J Thorac Dis. 2018;10(Suppl 4):S555-S563.

14. Manici M, Salgın B, Söğüt MS, *et al*. Can Rhomboid Intercostal Block Be an Alternative to Paravertebral Block in Video-Assisted Thoracoscopic Surgery? A Randomized Prospective Study. Diagnostics (Basel). 2024;14(19):2129.
15. Xu X, Zhang M, Li Y, Du JH, He JX, Hu LH. Comparison of postoperative analgesia by thoracoscopic-guided thoracic paravertebral block and thoracoscopic-guided intercostal nerve block in uniportal video-asssited thoracic surgery: a prospective randomized controlled trial. *World J Surg Oncol*. 2024;22(1):238.
16. Niesen AD, Jacob AK, Law LA, Sviggum HP, Johnson RL. Complication rate of ultrasound-guided paravertebral block for breast surgery. *Reg Anesth Pain Med*. 2020;45(10):813–817.
17. Barrington MJ, Uda Y. Did ultrasound fulfill the promise of safety in regional anesthesia? *Curr Opin Anaesthesiol*. 2018;31(5):649–655.
18. Yoshida K, Tanaka S, Itakura Y, Yoshizawa S, Inoue S. Simple strategy to minimize the risk of pneumothorax in thoracic paravertebral block. *Reg Anesth Pain Med*. 2025 May 15:rapm-2025-106711.
19. Ardon AE, Lee J, Franco CD, Riutort KT, Greengrass RA. Paravertebral block: anatomy and relevant safety issues. *Korean J Anesthesiol*. 2020;73(5):394–400.
20. Khot PP, Desai SN, Bale SP, Aradhya BN. Comparison of ultrasound-guided paravertebral block versus erector spinae plane block for postoperative analgesia after percutaneous nephrolithotomy - A randomised, double-blind, controlled study. Indian J Anaesth. 2023;67(12):1110–1115.
21. Agarwal S, Bharati SJ, Bhatnagar S, *et al*. The comparison of the efficacy of ultrasound-guided paravertebral block versus erector spinae plane block for postoperative analgesia in modified radical mastectomy: A randomized controlled trial. Saudi J Anaesth. 2021 Apr-Jun;15(2):137–143.
22. Li Y, Wei L, Du JH, He JX, Xu X, Hu LH. Comparison of thoracoscopic-guided intercostal nerve block and ultrasound-guided intercostal nerve block in postoperative analgesia of uniportal video-assisted lobectomy: a pilot randomized controlled trial. Int J Surg. 2025;111(2):1995–2001.
23. Hu L, Xu X, Tian H, He J. Effect of Single-Injection Thoracic Paravertebral Block via the Intrathoracic Approach for Analgesia After Single-Port Video-Assisted Thoracoscopic Lung Wedge Resection: A Randomized Controlled Trial. Pain Ther. 2021;10(1):433–442.

Figures

Figure 1

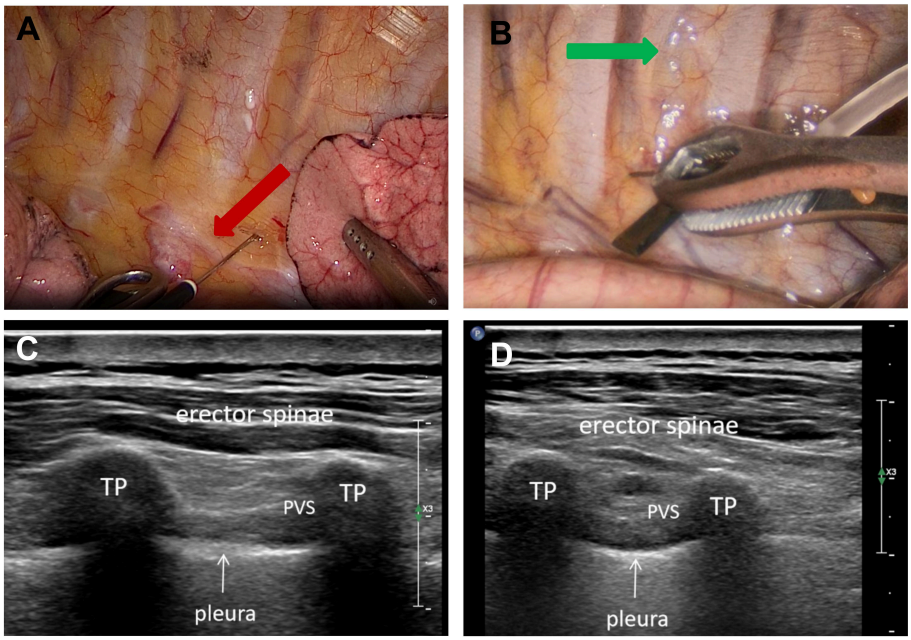

Figure 1

Thoracic Paravertebral Block (A) Needle inserted 0.5 cm lateral to the sympathetic chain (red arrow) at 0.5–1 cm depth. (B) Elevated parietal pleura after TSG-TPVB indicates correct local anesthetic spread (green arrow). (C) Ultrasound-guided thoracic paravertebral block (before the block procedure). (D) The downward movement of the pleura following USG-TPVB indicates correct spread of the local anesthetic.

Figure 2

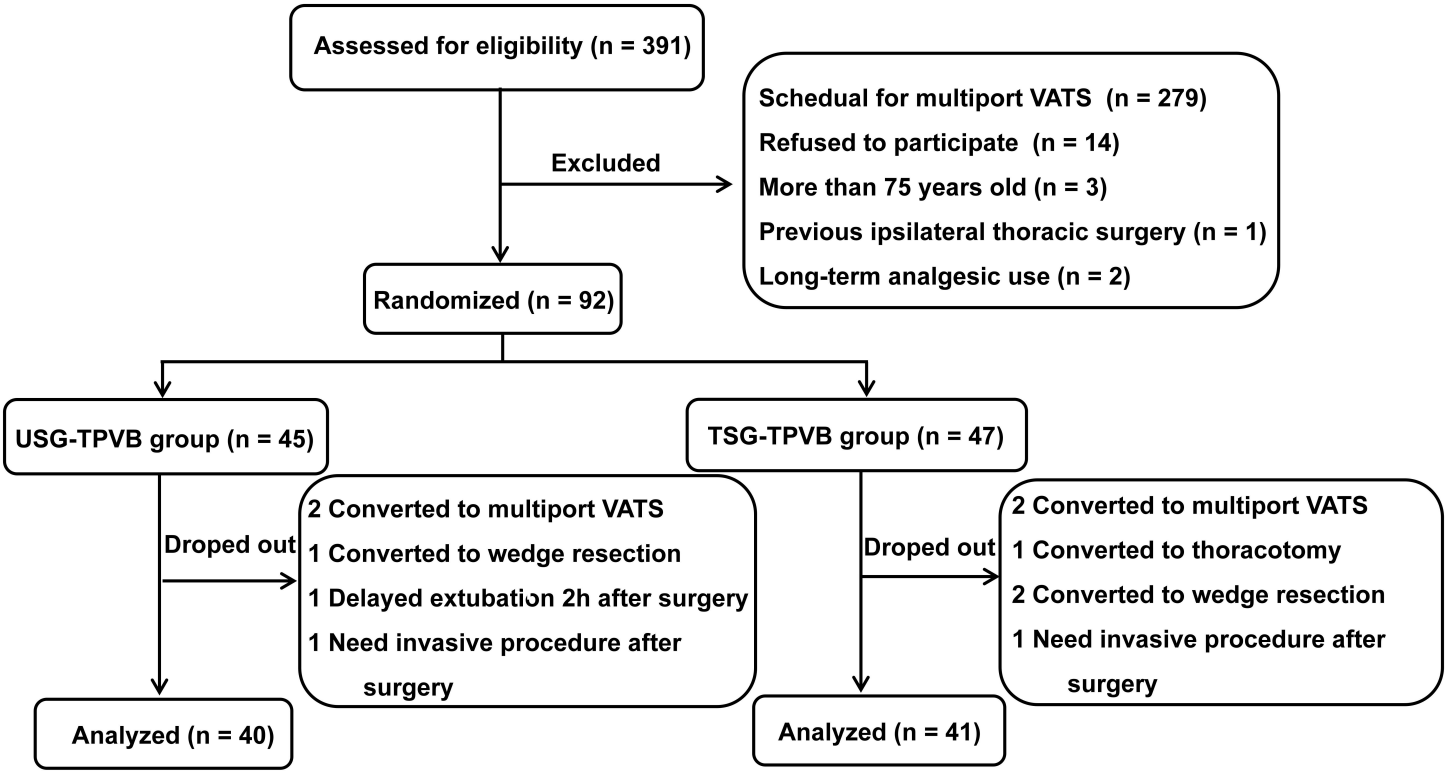

Figure 2

Consolidated Standards of Reporting Trials (CONSORT) flowchart for the trial.

Figure 3

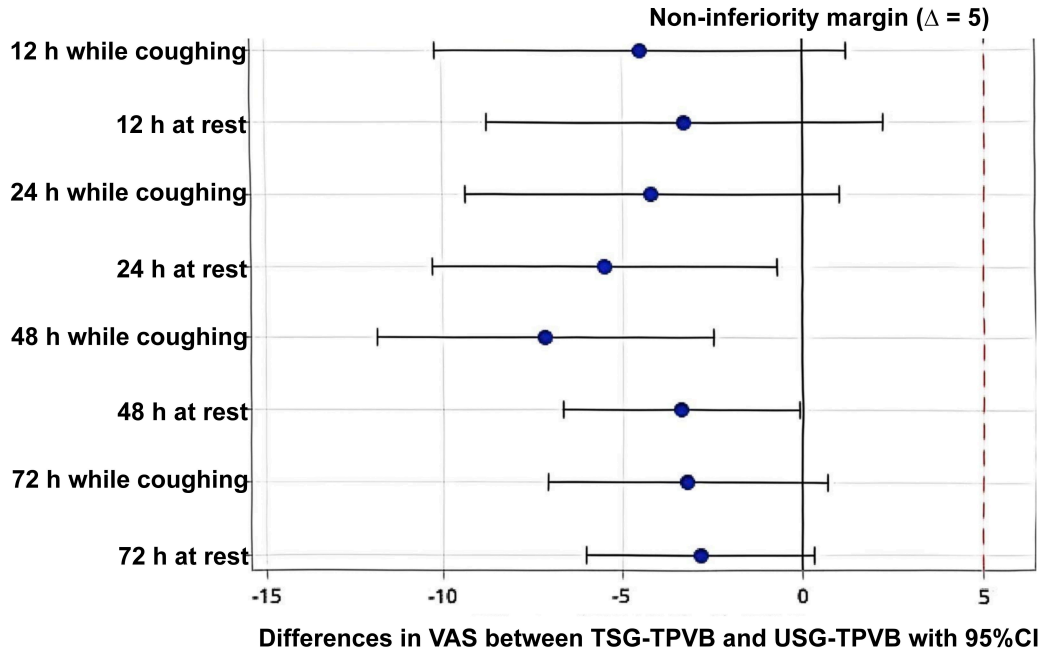

Figure 3

Noninferiority assessment for primary outcomes. Noninferiority of the TSG-TPVB was established, as all confidence intervals lie to the left of the noninferiority margin (Δ= 5, red line). CI, confidence interval.

Figure 4

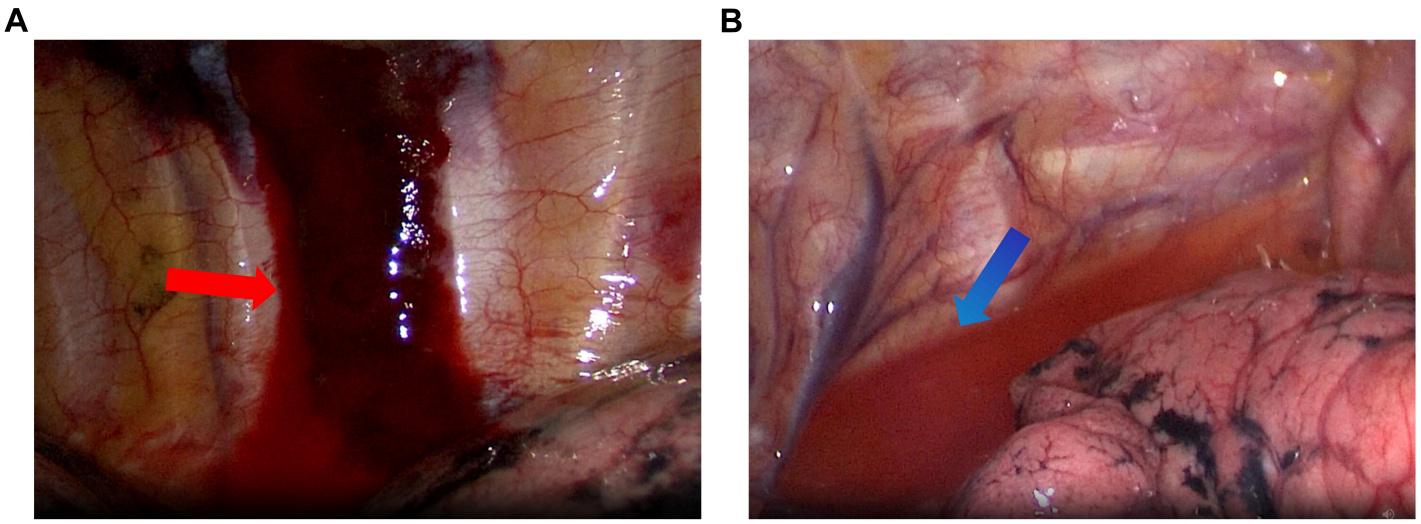

Figure 4

Complications associated with the USG-TPVB approach. (A) Local hematoma (Red arrow); (B) Accidental intrapleural leakage (Blue arrow).

Supplementary Files

This is a list of supplementary files associated with this preprint. Click to download.

- SupplementalFigure101.jpg
- SupplementalFigure201.jpg
- SupplementalTable1.docx
- SupplementalFigureLegends.docx
- CONSORTchecklist.docx