Research Square

Preprints are preliminary reports that have not undergone peer review.
They should not be considered conclusive, used to inform clinical practice,
or referenced by the media as validated information.

Ultrasound-Guided Precise Acupotomy for Chronic Plantar Fasciitis: A Single-Center Randomized Controlled Trial Focused on Long-Term Effect and Recurrence Rate

Xixi Ye
The Second Affiliated Hospital of Wenzhou Medical University
Kaiping Li
lkp67@163.com

Nanjing university of Chinese medince
Yi Zhou
The Second Affiliated Hospital of Wenzhou Medical University
Zhilin Zhao
The Second Affiliated Hospital of Wenzhou Medical University
Wenhao Zheng
The Second Affiliated Hospital of Wenzhou Medical University
Wennuan Pan
Zhejiang University City College
Tingting Chen
The Second Affiliated Hospital of Wenzhou Medical University

Research Article

Keywords: Acupotomy, Needle-knife, Plantar Fasciitis, VAS, Corticosteroid Injection, Musculoskeletal Ultrasound

Posted Date: September 22nd, 2026

DOI: https://doi.org/10.21203/rs.3.rs-10862950/v1

License: This work is licensed under a Creative Commons Attribution 4.0 International License.
Read Full License

Additional Declarations: No competing interests reported.

Abstract

Background Plantar fasciitis (PF) is a prevalent musculoskeletal condition characterized by localized pain at the calcaneal attachment of the plantar fascia. Its etiology is multifactorial and Treatment methods are diverse.Ultrasound-guided acupotomy is prevalent in recent years for plantar fasciitis .The study aimed To observe the improvement in pain and foot function following ultrasound-guided acupotomy for plantar fasciitis and to evaluate its clinical efficacy and recurrence rate. Methods Patients diagnosed with plantar fasciitis in the Department of Orthopedics at the Second Affiliated Hospital of Wenzhou Medical University between January 2023 and December 2025 were selected. Those who met the inclusion criteria were randomly divided into a experimental group, n=48 and control group, n=47. Both groups received treatment once a week for two weeks. The Visual Analogue Score (VAS), American Orthopaedic Foot & Ankle Society (AOFAS) score, and plantar fascia thickness were assessed and analyzed before treatment, as well as at 1 week, 3 months, and 6 months after treatment. The clinical efficacy, recurrence rate and safety of the two methods were compared. Results (1) At 1 week, 3 months, and 6 months after treatment, both groups showed significantly lower VAS scores and plantar fascia thickness compared to before treatment, and significantly higher AOFAS scores (all $P < 0.05$). (2) At 3 and 6 months after treatment, the experimental group had lower VAS scores and plantar fascia thickness than the control group, and significantly higher AOFAS scores (all $P < 0.05$). (3) At 3 and 6 months after treatment, VAS scores in both groups were higher than those at 1 week after treatment, while plantar fascia thickness in the experimental group was further reduced compared to that at 1 week (all $P < 0.05$). (4) At 6 months after treatment, the VAS score in the control group was higher than that at 3 months, the plantar fascia thickness in the experimental group was greater than that at 3 months, and the AOFAS score in the experimental group was lower than that at 1 week (all $P < 0.05$). (5) The overall efficacy of the experimental group was superior to that of the control group ($P < 0.05$). (6)The recurrence rate in the experimental group was lower than that in the control group Conclusions Both acupotomy methods are effective in treating plantar fasciitis, but ultrasound-guided acupotomy provides better long-term pain control, functional improvement, higer recovery and higer safety., with lowe recurrence rate. Trial registration Chinese Clinical Trial Registry Number: ChiCTR2300074714.August 14th, 2023.

Introduction

Plantar fasciitis (PF) is a prevalent musculoskeletal condition characterized by localized pain at the calcaneal attachment of the plantar fascia. Its etiology is multifactorial, and the clinical presentation is typically marked by severe morning pain upon weight-bearing, gait disturbances, and focal tenderness at the plantar heel. As one of the most frequent causes of chronic heel pain, PF significantly impacts patients' daily activities and quality of life [1].Plantar fasciitis can be managed with a variety of approaches [2], Common options include rest and activity modification, non-steroidal anti-inflammatory drug, shockwave therapy, orthotic devices, silver needle therapy, rehabilitation exercises, platelet-rich plasma (PRP) injections, local corticosteroid injections. Traditional Chinese Medicine methods, such as herbal fumigation, acupuncture, massage, and small needle-knife therapy, are also used. In more severe cases, surgery may be considered. All these methods can achieve certain clinical therapeutic effects.

Among them, local corticosteroid injection [3] offers good short-term effects, is convenient administer, and is relatively low-cost, which contributes to its widespread use. However, its long-term effects is limited, and recurrence rates are high. One study reported [4] that for plantar fasciitis, corticosteroid injection showed no significant advantage over a placebo at 3- and 6-month follow-ups. Furthermore, repeated injections may lead to degenerative changes in the plantar fascia, making it more fragile and even increasing the risk of rupture.Therefore, in clinical practice, there is a growing interest in finding alternative treatment options.

In China, acupotomy therapy, also called needle-knife therapy, has achieved positive outcomes in treating plantar fasciitis (PF) [5]. The acupotomy is an innovative instrument—its shaft is as fine as a filiform acupuncture needle, with a miniature blade at the tip (Fig. 1). It preserves the traditional effects of acupuncture in promoting meridian flow and harmonizing qi and blood, while It also incorporates the functions of modern surgical scalpels in loosening soft tissue adhesions and contractures, as well as regulating mechanical balance of soft tissue .It is widely applied in managing chronic musculoskeletal pain. However, conventional acupotomy manipulation is mostly performed “blindly.” The cutting and releasing process carries a certain risk of local tissue trauma, and its precision remains debatable. The advancement of musculoskeletal ultrasound has offered a key visual guidance strategy for acupotomy therapy. Under real-time, dynamic ultrasound visualization, the acupotomy can accurately target the plantar fascia lesion, effectively avoid surrounding nerves and vessels, and allow direct observation of the release effect during the procedure. This enhances the safety and controllability of the treatment and significantly improves clinical efficacy. By reviewing the relevant randomized controlled trials [6, 7, 8] on acupotomy therapy for plantar fasciitis conducted both domestically and internationally over the past three years, it was found that there are still many deficiencies in the current research: most of the acupotomy treatments still employ blind puncture techniques, or lacking quantitative ultrasound morphological indicators for follow-up, with the follow-up period typically being only 3 months, and there is also a lack of data on recurrence-related outcomes.

This study aimed to compare the clinical efficacy, ultrasound morphological changes and long-term recurrence between ultrasound-guided visualized acupotomy and conventional blind acupotomy for chronic plantar fasciitis, to provide quantitative clinic evidence for minimally invasive fascia release.

Methods

Study design and participants

This study employs a single-blind design. Preoperative and postoperative assessments are conducted by independent physicians who are blinded to group allocation, thereby minimizing evaluator-related subjective bias and ensuring the objectivity of data recording and interpretation.

This prospective, randomized control study was per-formed From January 2023 to June 2025, 100 patients diagnosed with plantar fasciitis were recruited from the Department of Orthopedics at Hospital

o. Participants were randomly assigned to either the experimental or control group using a random number table, with 50 patients in each group. A prospective study design was employed. The study protocol was reviewed and approved by the Ethics Committee of. The study strictly adhered to the provisions of the Helsinki Declaration and to CONSORT guidelines. All Participants approved to provided written informed consent.

Diagnostic Criteria refer to「Diagnosis and treatment of plantar fasciitis」by Goff JD [9], comprising the following key indicators: (1) Pain in the heel area when stepping down for the first time after getting up in the morning or after sitting for a long time (2) Significant pain at the medial calcaneal tubercle and the origin of the plantar fascia.; (3) Characteristic antalgic gait with pain exacerbation during active foot dorsiflexion; (4) Clinically significant tenderness along the plantar fascial aponeurosis, most pronounced at the medial calcaneal insertion site; (5)Ultrasound or MRI examinations can reveal thickening of the plantar fascia and abnormal edema bands.

Inclusion Criteria (1) Meet the diagnostic criteria; (2) Aged 20–70 years, with symptoms lasting more than 1 month; (3) Understand the study details and are willing to follow the procedures; (4) Have signed the informed consent form; (5) VAS ≥ 4 and plantar fascia thickness ≥ 4 mm on ultrasound.

Exclusion criteria (1) Foot or ankle fractures or skin lesions; (2)Active severe visceral disease or major impairment of heart, liver, or kidney function; (3) Severe osteoporosis, bone tuberculosis, or advanced cancer; (4) Severe diabetes or allergy to drugs such as triamcinolone or lidocaine; (5) Spontaneous bleeding tendency or coagulation disorders like hemophilia or thrombocytopenia; (6) Received other relevant treatments within 2 weeks that may affect observation in this study; (7) Psychiatric disorders or severe cognitive impairment affecting cooperation.

Sample size calculation

A two-sided hypothesis test was conducted with a significance level of $\alpha = 0.05$ and a statistical power of $1-\beta = 0.80$. Based on data from previous literature and preliminary clinical observations, the anticipated recovery rate in the experimental group ($P1$) was estimated at 56%, compared to 29% in the control group ($P2$). Using PASS software for sample size calculation, a minimum total sample size of 82 participants was required, with 41 individuals per group. To account for a projected dropout rate of 10%, the sample size was increased by 18 participants, resulting in a target enrollment of 50 participants per group, totaling 100 participants.

Intervention

Equipment and consumables: The Siemens ACUSON OXANA2 color Doppler ultrasound diagnostic instrument was used, with a linear probe of frequency 11–13 MHz; The acupotomy was selected from Jiangxi Laozongyi Instrument Company, model B, with a specification of 0.8 mm *60.0 mm.

Experimental Group (Visualization Group) Procedure: (1) The patient is positioned in the prone position with the ankle exposed. A small pillow is placed anterior to the ankle joint to elevate the heel. (2) Surface marking: The lateral and medial tubercles of the calcaneus and the tender points on the plantar aspect of the heel are identified and marked. A trained musculoskeletal ultrasound operator uses the probe to locate areas of plantar fascia inflammation, thickening, or calcification, marks these regions, and measures fascial thickness. (3) Disinfection: Disinfect the area within 10 cm of the surgical site three times with iodophor.(4) Anesthesia: Sterile gloves are worn. A 5 ml solution is prepared by mixing 3 ml of 1% lidocaine with 2 ml of triamcinolone acetonide (20 mg). A coupling agent is applied to the ultrasound probe, which is then covered with a sterile sheath. Under real-time ultrasound guidance, the needle is inserted 3–4 cm away from the marked point, with depth carefully controlled, and local infiltration anesthesia is administered at the target site. A volume of 1.5 ml is injected at each location.(5) Musculoskeletal ultrasound-guided acupotomy treatment: Following local anesthesia, a sterile disposable acupotomy (Laozongyi brand, 0.8*65 mm) is used. The blade is aligned parallel to the longitudinal axis of the body and inserted perpendicularly into the skin Under continuous ultrasound guidance, both in-plane and out-of-plane imaging techniques are employed to dynamically monitor the needle trajectory in real time during plantar fascia release. Upon completion, the puncture site is compressed with gauze for 2 minutes and covered with an adhesive dressing. The procedure is repeated once weekly, with two sessions comprising one treatment course. The operation is illustrated in Fig .2 and 3.

Control Group (Blind Group) Procedure: (1) The patient is positioned in the prone position with the ankle exposed. A small pillow is placed anterior to the ankle joint to elevate the heel. (2) Surface marking: The lateral and medial tubercles of the calcaneus and the tender points on the plantar aspect of the heel are identified and marked. A trained musculoskeletal ultrasound operator uses the probe to locate areas of plantar fascia inflammation, thickening, or calcification, marks these regions, and measures fascial thickness.(3) Disinfection: Disinfect the area within 10 cm of the surgical site three times with iodophor. (4) Anesthesia: Sterile gloves are worn. A 5ml solution is prepared by mixing 3ml of 1% lidocaine with 2ml of triamcinolone acetonide (20 mg). Local infiltration anesthesia is administered with 1.5 ml injected at each site. (5) Acupotomy treatment: Following local anesthesia, a sterile disposable acupotomy (Laozongyi brand, 0.8×65 mm) is used. The blade is aligned parallel to the longitudinal axis of the body and inserted perpendicularly into the skin. The four-step acupotomy insertion technique is strictly followed for tissue release:lateral and medial tubercles of the calcaneus : acupotomy passes through the skin, the fat pad on the sole of the foot, and the plantar fascia. When it reaches the bone surface, three longitudinal incisions are made for release, and then the needle is withdrawn.Heel tender point: The same four-step technique is applied for release. After completion, the puncture site is compressed with gauze for 2 minutes, then covered with an adhesive dressing. The procedure is repeated once weekly, with two sessions constituting one treatment course.

Clinical Evaluation

Primary outcome measure

Morning First Step Pain assessed using the Visual Analogue Scale (VAS) [10]: Pain intensity is represented by a 100-mm horizontal line divided into 10 equal segments. The scale ranges from 0 (no pain) to 10 (extreme pain), with scores of 1–3 indicating mild pain, 4–6 moderate pain, and 7–9 severe pain. Assessments are performed before treatment and at 1 week, 3 months, and 6 months post-treatment.

Second outcome measure

American Orthopaedic Foot and Ankle Society Ankle-Hindfoot Scale [11] (AOFAS): The total score is 100 points. It evaluates pain severity, functional status, ambulatory ability, support requirements, maximum walking distance, surface tolerance during walking, gait abnormalities, limitation of dorsiflexion and plantarflexion, inversion and eversion range of motion, ankle-hindfoot stability, and foot alignment. Higher scores indicate better foot function. Data are collected before treatment and at 1 week, 3 months, and 6 months post-treatment.

Ultrasound Examination: Plantar fascia thickness is measured and recorded in both groups before treatment and at each follow-up time point (1 week, 3 months, and 6 months post-treatment.).

Efficacy Evaluation Criteria [12]: Clinical outcomes are classified as excellent (complete resolution of symptoms), good (marked symptom relief with occasional discomfort), fair (partial improvement), or poor (no significant improvement or worsening). The clinical cure rate is calculated as (number of cured patients / total number of patients) × 100%. Treatment efficacy is evaluated at 6 months post-treatment.

Recurrence rate: Recurrence was defined by the following criteria: (1) VAS scores decreased compare with baseline (2) During follow-up, the VAS scores rebounded to ≥ 4 points. After a 6-month follow-up,the total number of recurrence cases was counted. The recurrence rate is calculated as (the total number of recurrence / total number of patients) × 100%.

Statistical Analysis

All data are analyzed using SPSS 23.0. Quantitative variables are expressed as mean±standard deviation. For normally distributed data, intergroup comparisons are performed using the independent samples t-test, while intragroup comparisons across multiple time points are analyzed using repeated measures analysis of variance, with post hoc pairwise comparisons where appropriate. Categorical data are analyzed using the chi-square (χ^2) test. For ordinal outcome data such as efficacy ratings, the Wilcoxon rank sum test is used to assess statistical significance. When p-value < 0.05 is considered statistically significant.

Results

112 patients were assessed for eligibility, with 12 patients excluded from the trial (Fig. 4), 100 were included in this study. Of the initial sample, 2 cases in the experimental group (final n = 48) and 3 in the control group (final n = 47) were lost to follow-up. Accordingly, 95 patients underwent randomization. The flow diagram demonstrates the enrolment of patients, randomization, allocation to groups, disposition status, and analysis. No significant differences were found in baseline data such as age, gender, and disease duration between the groups, confirming their comparability (see Table 1).

Table 1
Comparison of baseline data between the two groups

Characteristic	**Experimental group(N = 48)**	**Control group(N = 47)**	**χ^2/T**	***P*-value**
Sex				
Man/woman	28/20	23/24	χ^2 = 0.84	0.36
age				
Years	50.62 ± 12.57	48.40 ± 9.95	T = 0.95	0.34
Range	28–73	30–69		
Durationof symptoms				
months	5.22 ± 4.02	5.57 ± 4.43	T=-0.40	0.69
Range	1/16	1/8		
Side				
Left/right	22/26	19/28	χ^2 = 0.54	*0.46*
BMI,kg/m^2	24.8 ± 2.5	24.1 ± 2.3	1.43	0.1561

Morning First Step Pain assessed using the Visual Analogue Scale (VAS)

See Table 2, Fig. 5, Main effect of time:F(Main Effect of Time) = 225.83, $P < 0.01$, indicating that the pain scores of patients in both groups changed significantly over time, the treatment had a clear analgesic effect overall.Main effect of group:F(Main Effect of Group) = 4.675, $P = 0.033$, showing an overall difference in pain scores between the experimental group and the control group, with the experimental group demonstrating better overall pain control. Time×group interaction: F(Group×Time Interaction) = 2.374, $P = 0.75$. The interaction was not significant ($P > 0.05$), indicating that the trends of change over time were generally consistent between the two groups. Post-Hoc Pairwise Comparisons: Within-Group

Comparisons: VAS scores at 1 week, 3 months, and 6 months post-treatment were significantly lower than the pre-treatment scores in both groups (P^*<0.05). At both 3 and 6 months post-treatment, VAS scores were significantly higher than those at 1 week post-treatment in both groups (P^1 < 0.05). In the control group, the VAS score at 6 months post-treatment was significantly higher than that at 3 months post-treatment (P^2 < 0.05). Between-Group Comparisons: VAS scores in the experimental group were significantly lower than those in the control group at both 3 and 6 months post-treatment (P < 0.05).

Table 2
Comparison of VAS between the two groups

Prior	**Experimental group(N = 48)**	**Controlgroup(N = 47)**	**T**	***P*-value**
	6.40 ± 1.21	**6.62 ± 1.13**	**-0.917**	**0.362**
One week	1.08 ± 1.67*	1.29±.160*	-0.638	0.525
Threemonths	1.52 ± 1.96*[1]	2.47 ± 2.30*[1]	-2.163	0.033
Six months	1.65 ± 2.11*[1]	2.83 ± 2.49*[12]	-2.504	0.014
F(Main Effect of Time),*P*-value	F = 225.83, P < 0.01			
F(Main Effect of group),*P*-value	F = 4.675, P = 0.033			
F(Group×Time Interaction),*P*-value	F = 2.374, P = 0.75			

Note: Compared with the treatment before same group, P^*<0.05;Compared with 1 week after the treatment in same group, P^1 < 0.05Compared with 3 months after the treatment in same group, P^2 < 0.05

AOFAS Scores

See Table 3, Fig. 6, Main effect of time:F (Main Effect of Time) = 145.672, P < 0.01, indicating that the functional scores of patients in both groups improved significantly over time, suggesting an overall treatment effect.Main Effect of Group:F (Main Effect of Group) = 3.360, P = 0.070. This shows that, on average across time points, the AOFAS scores did not differ significantly between the experimental and control groups.Group × Time Interaction:F (Group × Time Interaction) = 3.538, P = 0.018. This indicates that the trend of change in AOFAS scores over time differed between the experimental and control groups, meaning there was a significant difference in their functional recovery trajectories. Post-Hoc Pairwise Comparisons: Within-group comparisons: AOFAS scores at 1 week, 3 months, and 6 months post-treatment were significantly higher than pre-treatment scores in both groups (P^* < 0.05). In the control group, AOFAS scores at 3 months and 6 months were significantly lower than those at 1 week post-treatment (P^1 < 0.05). In the experimental group, AOFAS scores at 6 months were significantly lower

than those at 1 week post-treatment ($P^1 < 0.05$). Between-group comparisons: AOFAS scores in the experimental group were significantly higher than those in the control group at both 3 months and 6 months post-treatment ($P < 0.05$).

Table 3
Comparison of AOFAS between the two groups

Prior	**Experimental group(N = 48)**	**Control group(N = 47)**	**T**	***P*-value**
	61.81 ± 12.43	**59.06 ± 10.75**	**1.152**	**0.252**
One week	90.35 ± 11.51*	90.27 ± 10.37*	0.034	0.97
Threemonths	87.52 ± 13.51*	81.81 ± 14.08*[1]	2.018	0.046
Six months	86.96 ± 14.50*[1]	79.96 ± 15.31*[1]	2.289	0.024
F(Main Effect of Time),*P*-value	F = 145.672, P < 0.01			
F(Main Effect of group),*P*-value	F = 3.360, P = 0.070			
F(Group × Time Interaction),*P*-value	F = 3.538, P = 0.018			
Note: Compared with the treatment before same group, P^*<0.05;Compared with the control group, $P^\#$ <0.05Compared with 1 week after the treatment in same group, $P^1 < 0.05$				

Plantar Fascia Thickness

See Table 4, Figs. 7, Main Effect of Time: F(Main Effect of Time) = 269.116, $P < 0.01$, indicating that the plantar fascia thickness in both groups of patients changed significantly over time, meaning the treatments were effective in significantly reducing the thickness. Main Effect of Group:F(Main Effect of group) = 5.592, $P = 0.020$, showing that the fascia thickness in the experimental group was significantly thinner overall compared to the control group.Group × Time Interaction: F(Group × Time Interaction) = 4.992, $P = 0.003$, suggesting that the trends in plantar fascia thickness over time were statistically significantly different between the experimental and control groups. Post-Hoc Pairwise Comparisons:Within-group comparisons: In both groups, plantar fascia thickness at 1 week, 3 months, and 6 months post-treatment was significantly lower than that before treatment (P^*<0.05). In the experimental group, thickness at 3 and 6 months post-treatment was significantly lower than that at 1 week post-treatment ($P^1 < 0.05$). Furthermore, in the experimental group, thickness at 6 months post-treatment was significantly greater than that at 3 months post-treatment ($P^2 < 0.05$).Between-group comparisons:At both 3 and 6 months post-treatment, plantar fascia thickness in the experimental group was significantly lower than that in the control group ($P < 0.05$).

Table 4
Comparison of Plantar Fascia Thickness between the two groups

Prior	**Experimental group(N = 48)**	**Control group(N = 47)**	**T**	***P*-value**
	5.40 ± 0.71	**5.37 ± 0.70**	**0.211**	**0.833**
One week	3.08 ± 0.80*	3.14±.0.82	-0.357	0.722
Three months	2.52 ± 0.44*[1]	3.05 ± 0.83	-3.87	0.000
Six months	2.66 ± 0.63*[12]	3.14 ± 0.89	-2.966	0.004
F(Main Effect of Time),*P*-value	F = 269.116, P < 0.01			
F(Main Effect of group),*P*-value	F = 5.592, P = 0.020			
F(Group × Time Interaction),*P*-value	F = 4.992, P = 0.003			

Note: Compared with the treatment before same group, P^{*}<0.05;Compared with 1 week after the treatment in same group, P^{1} < 0.05Compared with 3 months after the treatment in same group, P^{2} < 0.05

Efficacy Observation

See Table 5, At 6 months after treatment, there was a statistically significant difference in efficacy between the experimental group and the control group, the experimental group showing superior outcomes. The recovery rate in the experimental group (47.9%) was higher than that in the control group (29.8%) ($\chi^2 = 4.258$, $P = 0.036 < 0.05$), showing a statistically significant difference.

Table 5
Comparison of Efficacy between the two groups

Excellent	**Experimental group(N = 48)**	**Control group(N = 47)**
	23	**14**
Good	9	7
Fair	8	11
Poor	8	15
Z	−2.192	
P	0.025	

Recurrence rate

See Table 6, At 6 months after treatment, there was a statistically significant difference in recurrence rate between the experimental group and the control group. The recurrence rate in the experimental group (12.50%) was lower than that in the control group (31.91%) ($\chi^2 = 5.119$, $P = 0.027 < 0.05$).

Table 6
Comparison of recurrence rate between the two groups

One week	**Experimental group(N = 48)**	**Control group(N = 47)**
	1	**0**
Three months	3	11
Six months	2	4
Total	6	15
Recurrence rate	12.50%	31.91%
χ^2	5.199	
P	0.027	

Safety Evaluation

The safety evaluation showed a statistically significant difference in postoperative swelling between the groups, occurring in 1 case (experimental) and 3 cases (control). These cases were manageable with rest or minimal intervention, and no other adverse events like skin allergies or nerve injuries occurred.

Discussion

Plantar fasciitis is the primary cause of heel pain, responsible for approximately 80% of cases [13]. It is highly prevalent among middle-aged people aged 40 to 60, and in recent years, there has been a trend of affecting younger individuals [14]. The mean age in our study fell within this range. The etiology is multifactorial [15, 16], often linked to increased age, higher body mass index, prolonged weight-bearing, inappropriate footwear, rapid increases in activity levels, or overexercise (e.g., overuse, poor technique, high intensity, fatigue). These factors can disrupt the foot arch structure or biomechanical balance, leading to degenerative changes in the plantar fascia and repetitive microtrauma at the calcaneal insertion. This process triggers aseptic inflammation, edema, thickening, adhesion, and increased tension in the plantar fascia [17].

In both the experimental and control groups, VAS scores and plantar fascia thickness measured at 1 week, 3 months, and 6 months after treatment were lower than pre-treatment values, while AOFAS scores were higher. These findings indicate notable pain relief, functional improvement, and inflammation control in both groups. The key reason is that acupotomy and steroid hormones played a the crucial role. Acupotomy targets the degenerative mechanism of plantar fasciitis, which often involves adhesion, contraction, and elevated tension [18]. The technique cuts, releases, and strips

affected tissues, reducing tension and decreasing strain on connected tendons and muscles. This alleviates the high-stress state of the plantar fascia. The microtrauma induced by the needle tip promotes local bleeding and exudation of platelets and fibrin, enhancing local blood supply. By converting chronic aseptic inflammation into an acute inflammatory state, it stimulates tissue repair and helps restore normal biomechanical function. Thus, acupotomy effectively reduces pain, improve foot function and supports short- and long-term efficacy.

One week after treatment, there were no significant differences in VAS score, AOFAS score, or plantar fascia thickness between the experimental and control groups. A possible explanation is that corticosteroid injections can rapidly reduce the aseptic inflammation caused by chronic plantar fascia injury, alleviating pain and swelling in a short time. According to a report [19] by A. M. McMillan and K. B. Landorf, dexamethasone that injection is a safe and effective short-term treatment for plantar fasciitis, offering better pain relief than a placebo after four weeks. Shortly after treatment, abnormal swelling of the plantar fascia is also reduced, and this effect can last for several months. Although the control group was not guided by ultrasound, the short-term effect could still be achieved through the infiltration of local injection fluid. Corticosteroid injection is widely used in orthopedics and remains a first-line treatment for plantar fasciitis [20]. On one hand, [21, 22] corticosteroids work by suppressing the release or activation of inflammatory factors like interleukins, chemokines, and prostaglandins. They also inhibit cell division and slow down fibroblast synthesis, which helps prevent the formation of granulation tissue and inflammatory adhesions. Additionally, they may reduce the risk of scar and adhesion reformation after a acupotomy xtherapy. As a result, corticosteroids can be a useful auxiliary treatment when applied appropriately. Studies have reported moderate evidence supporting corticosteroid injections for short-term pain relief (up to one month), but evidence for long-term benefit remains very limited [23]. Corticosteroid have no significant improvement effect on degenerative diseases and cannot promote tissue regeneration. This is also the reason why the treatment of PF with simple corticosteroid hormone injections has a short-lasting effect.

Considering the pathophysiology of plantar fasciitis, acupotomy combined with limited corticosteroid injection appears to be a safe and effective strategy. It may reduce the risk of plantar fascia rupture, local infection, or fat pad atrophy [24], and also improve short- and long-term effects. The therapeutic effects of both groups at 3 months and 6 months after treatment were superior to those before treatment, which can prove this viewpoint. No fat pad atrophy was detected on ultrasound or clinical inspection.

At the 3- and 6-month follow-ups, the VAS scores and the thickness of the plantar fascia in the experimental group were lower than those in the control group, while the AOFAS score was higher in the experimental group. Moreover, the recovery rate was higher and the recurrence rate was lower in the experimental group.These results suggest that ultrasound-guided acupotomy offers better short- and long-term outcomes compared to traditional acupotomy. The experimental group also experienced less postoperative swelling, indicating a better safety profile. We attribute this advantage mainly to the precise positioning by musculoskeletal ultrasound. Ultrasound imaging in plantar fasciitis typically

shows[25] thickening of the plantar fascia, reduced echogenicity, blurred margins, perifascial edema, localized fluid, and sometimes heel spurs. A meta-analysis by McMillan et al. [26] involving 23 studies reported that the plantar fascia in PF patients was 2.16 mm thicker on average than in controls (95% CI: 1.60–2.71 mm, $P < 0.001$). A plantar fascia thickness exceeding 4.0 mm was strongly predictive of PF (OR = 105.11, 95% CI: 3.09–3577.28, P = 0.01), supporting its use as a diagnostic criterion. Our study also recorded a mean plantar fascia thickness above 5 mm, consistent with previous literature.The 2014 clinical practice guidelines from the American Physical Therapy Association elevated the recommendation for using ultrasound imaging to diagnose and evaluate plantar fasciitis to Level III [27]. In the diagnosis of chronic plantar fasciitis, musculoskeletal ultrasound can be used to measure the thickness of the plantar fascia and assess the severity of fasciitis. Although its image clarity is not as high as that of MRI, the measurement results are largely consistent with MRI findings [28]. In acupotomy treatment for plantar fasciitis, the primary target is the plantar fascia, which aligns well with the focus of ultrasound. Under ultrasound guidance, the thickened and edematous pathological areas of the plantar fascia can be accurately identified [29], along with clear visualization of surrounding nerves, ligaments, tendons, blood vessels, and their anatomical relationships. During the procedure, clinicians can also monitor in real time and dynamically guide the depth of acupotomy insertion, ensuring it reaches the affected site precisely. This approach helps direct the extent and degree of release, minimizes unnecessary cutting, reduces the scope of tissue disruption, decreases postoperative swelling and pain, and enhances accuracy in release—which may contribute to lower recurrence rates and improved long-term outcomes.

The control group received traditional blind acupotomy therapy. This method carries a certain degree of uncertainty. During the procedure, the clinician relies on anatomical landmarks and tender points to locate the affected tissue and uses the sense of resistance felt through the needle to determine whether the plantar fascia layer has been reached and whether adequate release has been achieved. This approach theoretically increases the risk of injuring surrounding structures, such as the medial calcaneal branches of the tibial nerve and posterior tibial artery, the abductor hallucis muscle, and the medial/lateral plantar arteries, veins, and nerves, potentially leading to iatrogenic trauma. This is also a major reason why acupotomy techniques have not been widely adopted in clinical practice. Performing acupotomy therapy without imaging guidance is comparable to operating in a "black box"—even with solid anatomical knowledge, unpredictable anatomical variations pose significant risks, which partly explains the limited efficacy of traditional blind acupotomy treatment for plantar fasciitis.

No nerve or vascular injuries occurred in this trial, likely because the operator was an experienced acupotomy practitioner and the sample size was relatively small. For less experienced operators, ultrasound-guided treatment is recommended to improve safety.

limitaions

This study also has some limitaions. Firstly, It did not include a single corticosteroid injections and single acupotomy placebo group. If such groups had been included, a more comprehensive explanation of the

short-term efficacy of corticosteroid injections and the long-term efficacy of acupotomy in treating plantar fasciitis. Secondly, It is not a double-blind trial, which may affect the results. Lastly, The sample size is still not large enough. The follow-up period should be extended to one year.

Conclusion

In summary, based on this clinical trial, ultrasound-guided acupotomy therapy represents a safer and more effective approach. Most hospitals are equipped with musculoskeletal ultrasound equipment. This plan can be standardized and promoted to save medical costs.

Declarations

Funding

This work was supported by Wenzhou City's Basic Research Project(NO.Y20220261) and Zhejiang Provincial Natural Science Foundation (NO.LQ24H06008).

Author Contribution

Xixi Ye and Kaiping Li made substantial contributions to the concept and design of the study and wrote the manuscript. Yi Zhou and Zhilin Zhao assisted with research and protocol design. Wenhao Zheng,Wennuan Pan and Tingting Chen helped with the data analysis and revised the manuscript. All authors read and approved the final manuscript.

Abbreviations

PF Plantar fasciitis

VAS Visual Analogue Scale

PRP platelet-rich plasma

AOFAS American Orthopaedic Foot and Ankle Society Ankle-Hindfoot Scale

SPSS Statistical productand service solutions

References

1. Ulusoy A, Cerrahoglu L, Orguc S (2017) Magnetic Resonance Imaging and Clinical Outcomes of Laser Therapy, Ultrasound Therapy, and Extracorporeal Shock Wave Therapy for Treatment of Plantar Fasciitis: A Randomized Controlled Trial. J Foot Ankle Surg 56(4):762–767

2. Li H, Lv H, Lin T (2018) Comparison of efficacy of eight treatments for plantar fasciitis: A network meta-analysis. J Cell Physiol 234(1):860–870
3. Speed CA (2007) Injection therapies for soft-tissue lesions. Best Pract Res Clin Rheumatol 21(2):333–347
4. Crawford F, Atkins D, Young P, Edwards J (1999) Steroid injection for heel pain: evidence of short-term effectiveness. A randomized controlled trial. Rheumatology (Oxford) 38(10):974–977
5. Yuan Shibo; Luo Guofeng; Liu Yongde (2025) Zhong Jingjing; Liu Huilin; Mao Qiangjian; Chi Zhenhai.Advances in Clinical Research on Needling Therapy for Plantar Fasciitis. Hebei J Traditional Chin Med 47(2):340–344
6. Wang W, Kang J, Wang X et al (2026) Efficacy of acupuncture for chronic recalcitrant plantar fasciitis: A randomized trial. Complement Ther Med 97:103329
7. Liu F, Guo GX (2025) Clinical value of musculoskeletal ultrasound-guided acupotomy versus conventional acupotomy in the treatment of plantar fasciitis based on foot function[J]. Clin Med 45(12):37–40
8. Gan XH (2022) Observation on short-term therapeutic effect of acupotomy combined with Chinese herbal fumigation-washing for calcaneal pain syndrome. [Master's thesis]. Hubei University of Chinese Medicine
9. Goff JD, Crawford R (2011) Diagnosis and treatment of plantar fasciitis. Am Fam Physician 84(6):676–682
10. Chiarotto A, Maxwell LJ, Ostelo RW, Boers M, Tugwell P, Terwee CB (2019) Measurement Properties of Visual Analogue Scale, Numeric Rating Scale, and Pain Severity Subscale of the Brief Pain Inventory in Patients With Low Back Pain: A Systematic Review. J Pain 20(3):245–263
11. Ferreira GF, Sevilla D, Oliveira CN et al (2021) Comparison of the effect of hyaluronic acid injection versus extracorporeal shockwave therapy on chronic plantar fasciitis: Protocol for a randomized controlled trial. PLoS ONE 16(6):e0250768 Published 2021 Jun 24
12. State Administration of Traditional Chinese Medicine (1994) Criteria of Diagnosis and Therapeutic Effect of Diseases and Syndromes in Traditional Chinese Medicine: ZY/T001.1-001.9-94*. Nanjing University, Nanjing, pp 29–30
13. Kim DH, Lee Y (2023) Effect of Dynamic Taping versus Kinesiology Taping on Pain, Foot Function, Balance, and Foot Pressure in 3 Groups of Plantar Fasciitis Patients: A Randomized Clinical Study. Med Sci Monit 29:e941043 Published 2023 Nov 2. 10.12659/MSM.941043
14. Zhou J, Wu F, Guo J Clinical value of ultrasound-guided local acupuncture combined with compound betamethasone injection for plantar fasciitis.joural of china Clinic Medical Imaging,2022, 33(12): 879–882
15. Belhan O, Kaya M, Gurger M (2019) The thickness of heel fat-pad in patients with plantar fasciitis. Acta Orthop Traumatol Turc 53(6):463–467
16. van Leeuwen KD, Rogers J, Winzenberg T, van Middelkoop M (2016) Higher body mass index is associated with plantar fasciopathy/'plantar fasciitis': systematic review and meta-analysis of

various clinical and imaging risk factors. Br J Sports Med 50(16):972–981

17. Yueshan Y, Qingfu W, Yufeng M et al (2016) Effects of needle knife surgery on plantar stress for treating calcaneodynia. J Beijing Univ Traditional Chin Med 39(05):413–416
18. Ye XX (2018) Clinical contrastive study of different types of operating method of acupotmy treatment for carpal tunnel sydrome[[Master's thesis]]. Nan Jing University of Traditional Chinese Medicine
19. Raissi G, Arbabi A, Rafiei M et al (2023) Ultrasound-Guided Injection of Dextrose Versus Corticosteroid in Chronic Plantar Fasciitis Management: A Randomized, Double-Blind Clinical Trial. Foot Ankle Spec 16(1):9–19
20. Li S, Wang K, Sun H et al (2018) Clinical effects of extracorporeal shock-wave therapy and ultrasound-guided local corticosteroid injections for plantar fasciitis in adults: A meta-analysis of randomized controlled trials. Med (Baltim) 97(50):e13687
21. Whittaker GA, Munteanu SE, Menz HB, Bonanno DR, Gerrard JM, Landorf KB (2019) Corticosteroid injection for plantar heel pain: a systematic review and meta-analysis. BMC Musculoskelet Disord 20(1):378 Published 2019 Aug 17
22. Babaei-Ghazani A, Karimi N, Forogh B et al (2019) Comparison of Ultrasound-Guided Local Ozone (O2-O3) Injection vs Corticosteroid Injection in the Treatment of Chronic Plantar Fasciitis: A Randomized Clinical Trial. Pain Med 20(2):314–322
23. Moosmayer S, Ekeberg OM, Hallgren HB et al (2023) Ultrasound guided lavage with corticosteroid injection versus sham lavage with and without corticosteroid injection for calcific tendinopathy of shoulder: randomised double blinded multi-arm study. BMJ 383:e076447 Published 2023 Oct 11
24. Gusenoff JA, Mitchell RT, Jeong K, Wukich DK, Gusenoff BR (2016) Autologous Fat Grafting for Pedal Fat Pad Atrophy: A Prospective Randomized Clinical Trial. Plast Reconstr Surg 138(5):1099–1108
25. Sheng TT, Zhang Z, Lu TT (2022) ,Advances in the Application of Musculoskeletal Ultrasound in the Diagnosis and Treatment of Plantar Fasciitis. Shangdong Med Joural 62(11):95–97
26. McMillan AM, Landorf KB, Barrett JT, Menz HB, Bird AR (2009) Diagnostic imaging for chronic plantar heel pain: a systematic review and meta-analysis. J Foot Ankle Res 2:32 Published 2009 Nov 13
27. Martin RL, Davenport TE, Reischl SF et al (2014) Heel pain□plantar fasciitis: revision 2014. J Orthop Sports Phys Ther 44(11):A1–A33
28. Xu YP, Chen Z (2022) Y,Study on the Application of Musculoskeletal Ultrasound in the Evaluation of Chronic Plantar Fasciitis.Joural of integrated Traditional Chinese and Western Medicine. 32(05):34–36
29. Sillevis R, Shamus E, Mouttet B, THE MANAGEMENT OF PLANTAR FASCIITIS WITH A MUSCULOSKELETAL ULTRASOUND IMAGING GUIDED, APPROACH FOR INSTRUMENT ASSISTED SOFT TISSUE MOBILIZATION IN A RUNNER (2020) A CASE REPORT. Int J Sports Phys Ther 15(2):274–286

Figures



Figure 1

Needle-knife shape



Figure 2

Under ultrasound guidance, the needle-knife operation process was observed in real time and dynamically to loosen the plantar fascia.

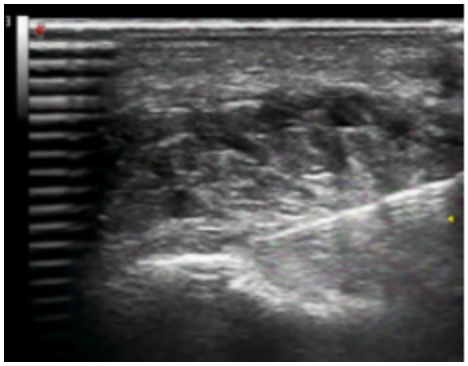

Figure 3

Musculoskeletal ultrasound images, the needle-knife is loosening the plantar fascia.

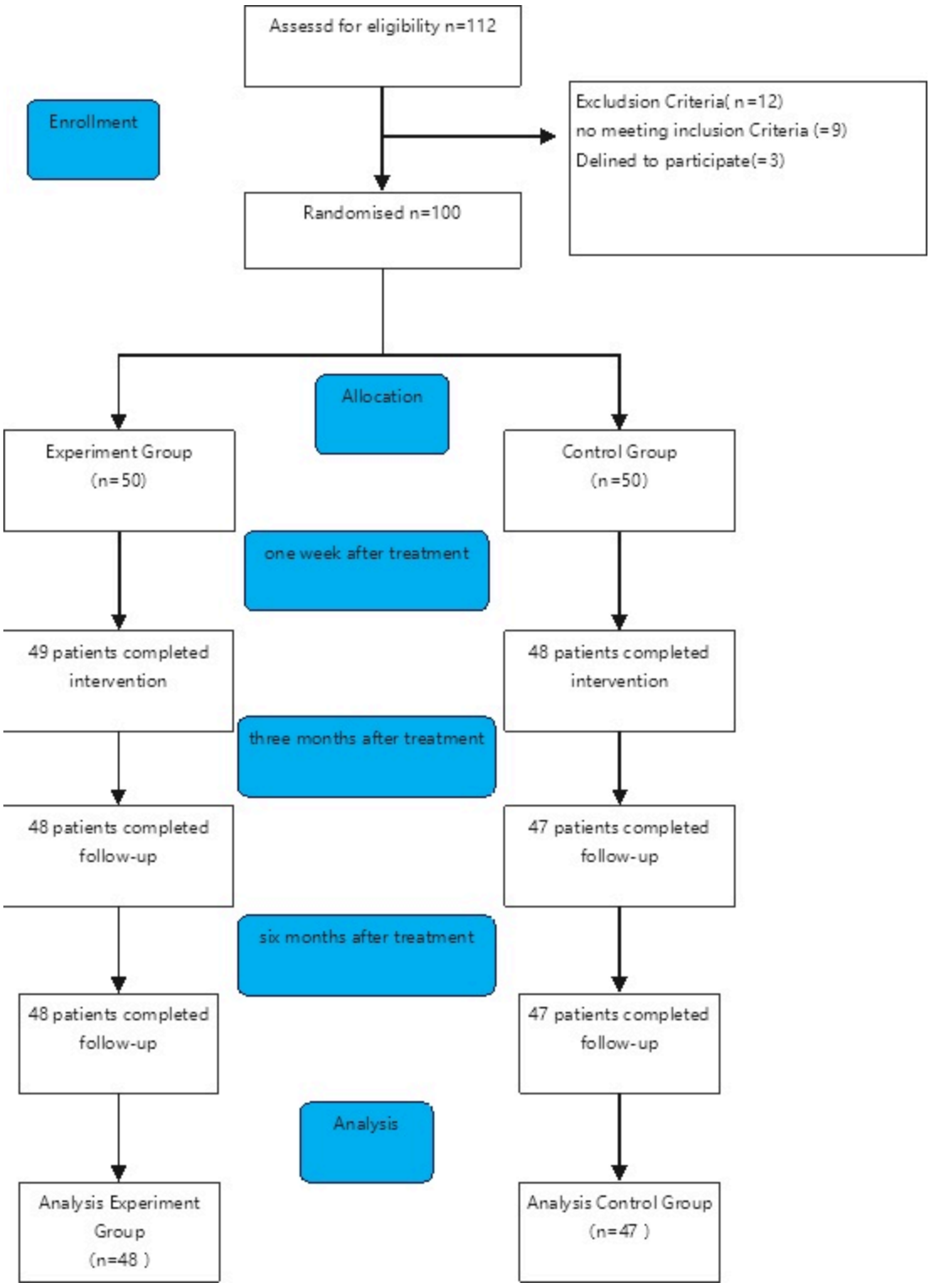

Figure 4

Flowchart for patients eligibility

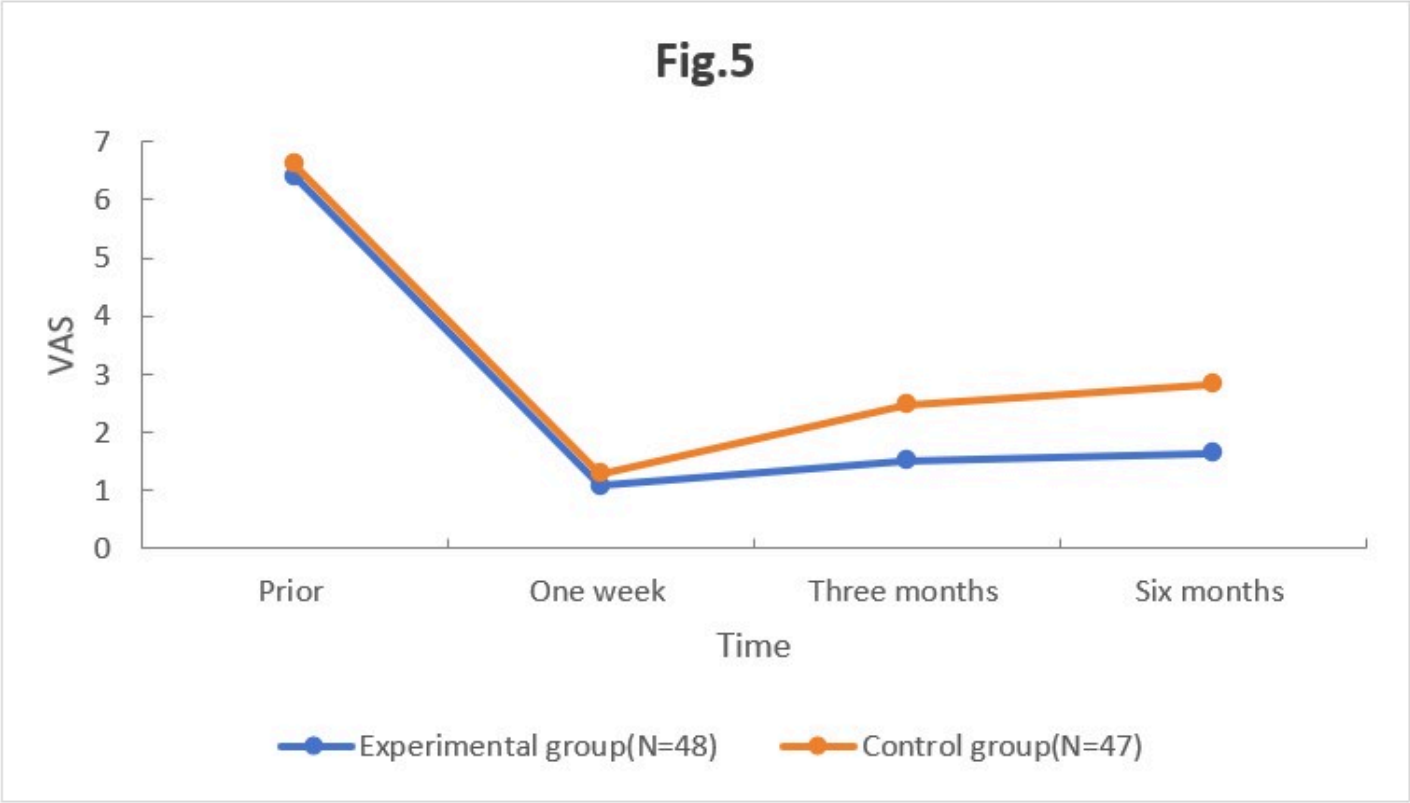

Figure 5

Mean VAS of pain in two group during differen time

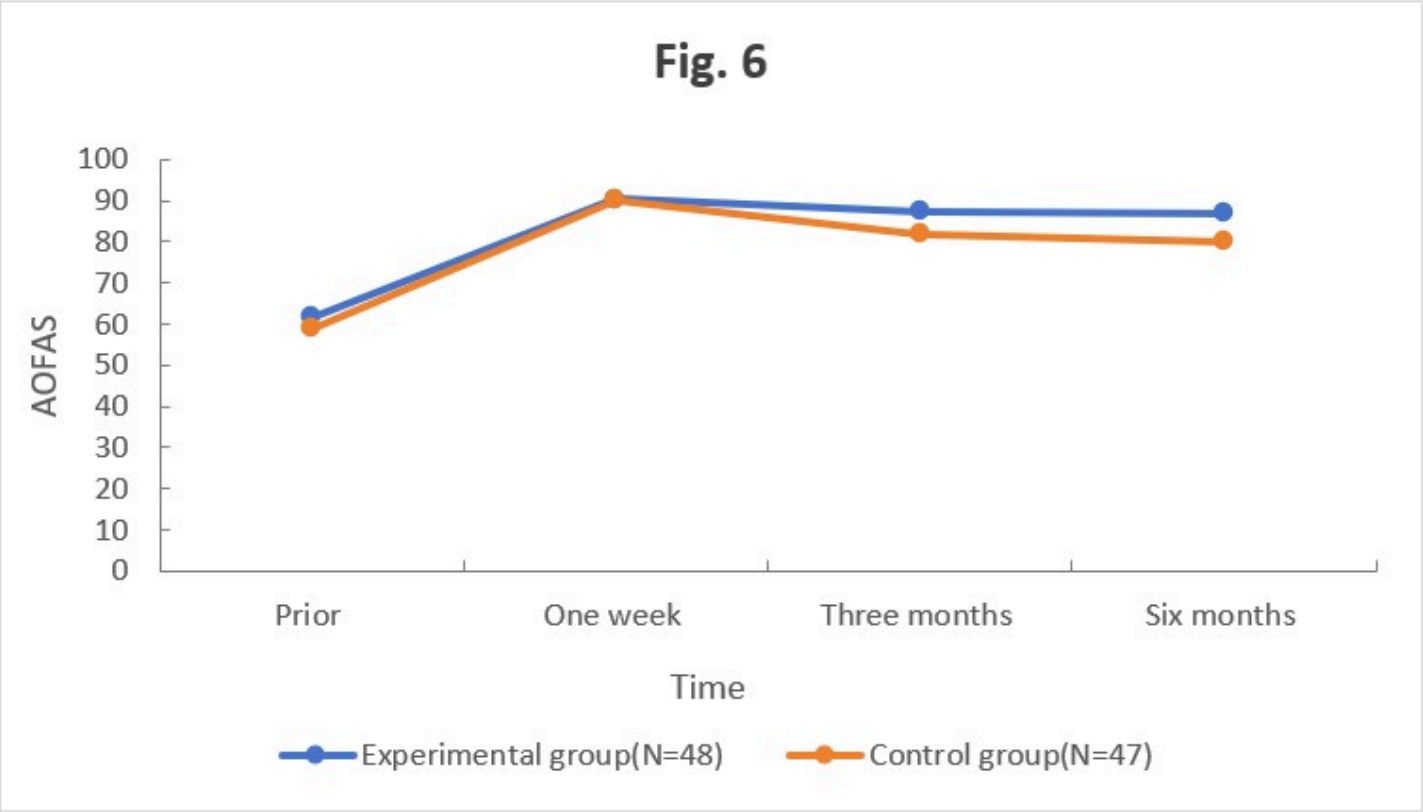

Figure 6

Mean AOFAS in two group during differen time

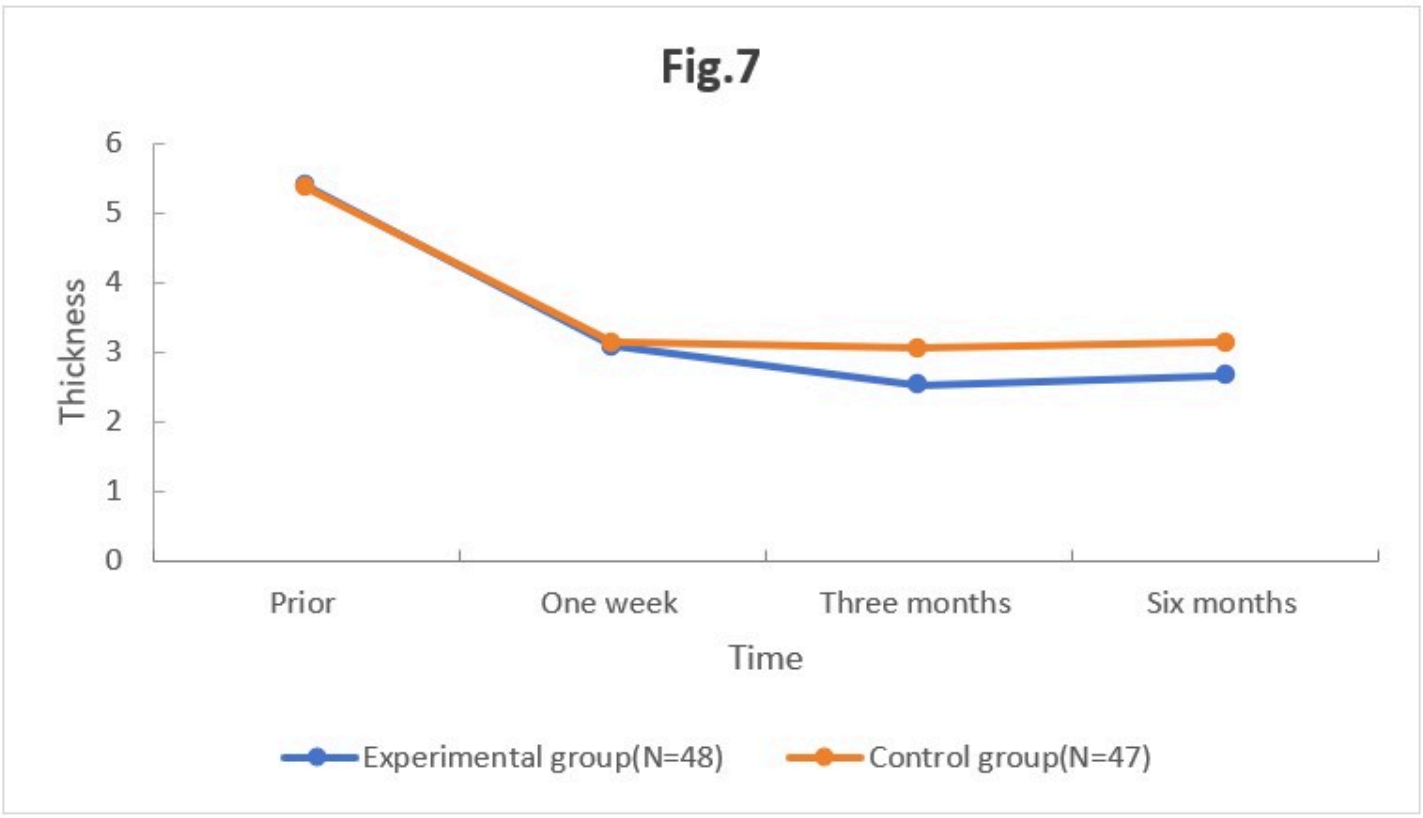

Figure 7

Mean Plantar Fascia Thickness in two group during differen time